

Trauma to the cranial nerves

Col Harjinder S Bhatoe M Ch

Department of Neurosurgery
Army Hospital (R & R)
Delhi Cantt 110010. New Delhi

Abstract: Cranial nerve injury is often an overlooked aspect of neurotrauma, which is diagnosed later in the course of recovery. Most of these injuries do not require active intervention in the acute stage. Cranial nerve injuries are important cause of morbidity, which requires long-term management, repeated surgical procedures or reconstructive measures. Management of optic nerve injury remains controversial, and injury to lower cranial nerves may influence the ultimate outcome due to paralysis of aerodigestive passage. Cranial nerve injury in the setting of head injury should be diagnosed early, so that appropriate treatment can be planned early.

Keywords: cranial nerve, head injury, facial injury, optic nerve injury

Cranial nerve injury is an important component of neurotrauma, which may not be readily apparent in the emergency room where the patient is brought in after having sustained head injury. The incidence of cranial nerve injury in craniocerebral trauma varies between 5 and 23 percent¹. Initial evaluation by history and clinical and neurological evaluation effectively assesses the sensorium, cortical function and haemodynamic status. Added to this, a rapid evaluation of ocular movements, pupils, facial symmetry and laryngeal function establishes the functional integrity of the cranial nerves. Complete evaluation of individual cranial nerves, a time-consuming and elaborate exercise even in a conscious patient, may not be feasible in a comatose patient or in one with altered sensorium. Subjective information cannot be obtained in an unconscious patient, and history from witnesses, other medical personnel and police can supply valuable information.

Cranial nerves, along with major arteries and bridging veins, act as anchors to the brain in a sea of cerebrospinal fluid. Injury to the cranial nerves can occur by shearing forces, rapid acceleration/deceleration, injury to the skull base, penetrating craniocerebral injuries, especially those through the skull base and as a sequel to various surgical procedures. Table 1 gives rapid clinical assessment of

head injured patient for cranial nerve injury.

Table 1

Nasal bleed/CSF rhinorrhoea
Finger counting each eye separately
Pupillary light reflex for afferent pupillary defect
Ptosis, proptosis
Complaint of diplopia: Assessment of ocular movements
Corneal reflex
Poor eye closure, facial weakness and asymmetry
Ear bleed/CSF otorrhoea
Hearing impairment: Haemotympanum, rupture of tympanic membrane
Hoarseness of voice, inability to cough: indirect laryngoscopy for vocal cord movements
Difficulty in swallowing
Difficulty in articulating words

OLFACTORY NERVE

Head injury is the commonest cause of loss of olfaction, due to disruption of the olfactory fibers prior to their decussation^{2,3}, and olfactory nerve is the commonest cranial nerve damaged in head injury⁴. Diagnosis of posttraumatic anosmia may not be of importance in immediate management. However, it may assume medicolegal importance, especially if the patient vocation involves culinary arts and aromatic compounds.

Mechanism of injury

Olfaction is impaired due to injury to the olfactory nerve

Address for Correspondence:

Col Harjinder S Bhatoe M Ch
Department of Neurosurgery
Army Hospital (Research & Referral)
Delhi Cantt 110010. New Delhi
Tel: 011-28638095, 28638096
Fax: 011-25681893
E-mail: hsbhatoe@indiatimes.com; harjinderbhatoe@yahoo.co.in

filaments at the cribriform plate, or due to injury to the olfactory bulb or the olfactory tracts (Figs 1-3). The olfactory nerve filaments can get torn by fractures involving the cribriform plate of the ethmoid (Fig 4). Frontal or occipital blows can shear off the olfactory filaments by shearing or stretching of these nerve fibers. A frontal

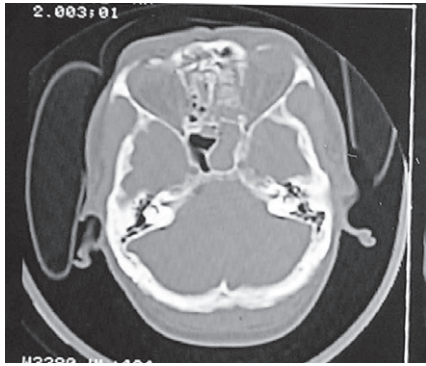


Fig 1: CT showing fracture of the ethmoid

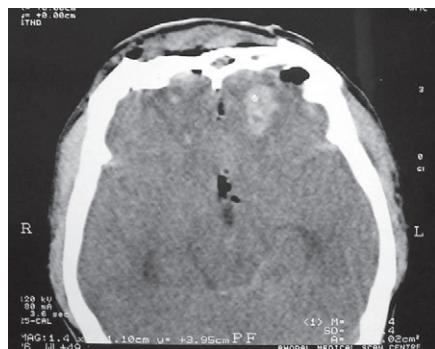


Fig 2: CT showing depressed bifrontal fracture with underlying contusion of brain

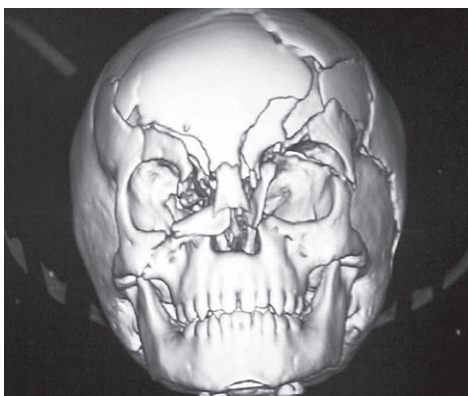


Fig 3: CT reconstruction of fracture of anterior skull base and nasoethmoid complex

impact produces less impact than side or occipital impact². With or without fracture of the cribriform plate, these direct and contrecoup injuries produce severe acceleration/deceleration forces that avulse the olfactory nerve roots.

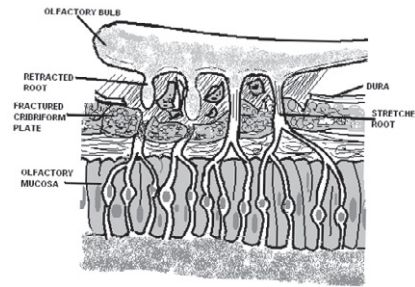


Fig 4: Diagrammatic representation of injury to olfactory filaments

Fractures in the region can lacerate the filaments. Olfaction can also be impaired by oedema, haematoma or ischaemia. Closed head injury can produce impairment of olfactory recognition despite preserved olfactory detection, in injury to orbitofrontal and temporal lobes⁵. Olfactory nerves and tracts can also get iatrogenically injured in various surgical procedures involving the anterior skull base. Anosmia can occur after surgery on anterior communicating artery aneurysm, following radiotherapy to the anterior skull base and after anterior interhemispheric approach. Craniocerebral missile injuries involving the anterior skull base can cause olfactory nerve damage.

Diagnosis: Olfactory nerve damage is suspected in the presence of nasal bleed, periorbital ecchymosis, proptosis and CSF rhinorrhoea in the setting of craniocerebral injury. CSF rhinorrhoea occurs due to fracture in the cribriform plate or frontal sinus with dural tear, and is a risk factor for development of post-traumatic meningitis. Even a conscious patient may be unaware of anosmia or hyposmia. More often the patients complains of altered taste sensation. Parosmia (a distorted sense of smell) sometimes accompanies hyposmia, and may be permanent⁶.

Course: In traumatic brain injury with olfactory nerve dysfunction, nearly 40% recover their olfaction. Most of these patients recover within three months, and may continue upto two years⁷. Early recovery implies the compressive effects of local haematoma, contusion, etc., while delayed recovery occurs from regeneration and migration of neurons from olfactory mucosa to the olfactory bulb. Severe disruption of lamina cribrosa and fibrosis can prevent such reconnection, making anosmia permanent⁸.

OPTIC NERVE AND CHIASM

The optic nerve is about 4.5 to 5.0 cm in length, of which the intraorbital segment is the longest, and the intraocular segment is the shortest. The intracanalicular

portion (contained within the bony optic canal of the sphenoid) measures about 5 to 7 mm and is relatively immobile owing to the fusion of the dural sheath of the nerve to the periosteum. The intracranial segment measures about 9 to 10 mm and joins with the opposite optic nerve to form the optic chiasm. Blindness following head injury was observed nearly two millennia ago, when Hippocrates first noted, "...dimness of vision occurs in injuries of the brow and those placed slightly above"⁹. Optic nerve injury was first demonstrated in an autopsy by Berlin in 1879¹⁰; the autopsy demonstrated optic canal fracture and optic sheath hemorrhage. Hughes in 1962 described various types of optic nerve injury and hypothesized the pathogenesis of the nerve damage by microvascular thrombosis and ischaemia¹¹.

Incidence: Optic nerve injury is described as a rare injury,¹² with only few series reported in literature^{13,14,15}. A large series from India¹⁶ reported an incidence of 2.78%.

Mechanism: The mechanism of injury is obvious in cases of direct injury involving the orbit and globe. However, in patients with closed head injury, the mechanism and pathogenesis remain unclear. Anderson et al in experimental studies on dried human skulls inferred that increased loads on the brow region led to stresses being concentrated in the region of optic foramen¹⁷. Adding to this observation, Gross et al suggested that acute downward displacement of the orbital wall occurs after a blow to the brow region; with release of the load, the soft tissues exhibit oscillation for a longer period as compared to the bony optic canal¹⁸. Such oscillations cause stretch on the optic nerve, leading to injury to intraneural microvasculature as well as to the nerve fibers, and ultimately, intracanalicular compression of the nerve. Severe frontal impact can also cause fracture in the region of sella and clinoids, resulting in chiasmal injury. The chiasmal injury can result from compressive, contusive, mechanical or ischaemic damage¹⁹.

Classification: Based on their autopsy study, Walsh and Lindenberg²⁰ classified optic nerve injury into primary and secondary injury.

A. Primary :

- (a) Optic nerve concussion
- (b) Contusion or laceration
- (c) Haematoma : Intraneural or optic nerve sheath
- (d) Optic nerve avulsion: Partial or complete

B. Secondary:

- (a) Edema
- (b) Ischaemia
- (c) Microvascular thrombosis
- (d) Infarction of the nerve

Diagnosis: Loss of vision is complained of by conscious patients with optic nerve injury. A history of loss of consciousness is elicited in nearly 90% cases.¹⁴ Associated epistaxis (Maurer's triad: head injury, epistaxis due to traumatic pseudoaneurysm of internal carotid artery, unocular blindness) should alert the clinician to the possibility of accompanying optic nerve injury^{21,22}. Diagnosis is difficult in patients with severe head injury with altered sensorium. Marcus-Gunn pupil (afferent pupillary defect) is seen in isolated optic nerve injury: bright light shone on the normal side elicits a consensual reflex on the affected side, while light shone on the injured side elicits pupillary dilatation. Mydriasis indicates associated oculomotor nerve injury, and a diagnosis can be established by visual evoked potential (VEP) recording. Fundus examination is unremarkable in posterior injury during the initial examination soon after injury. Optic atrophy sets about 4-6 weeks. In the rare instance of optic nerve avulsion at the globe, funduscopy reveals a hole in the retina at the site of optic disc. Delayed visual deterioration indicates secondary factors like ischaemia, oedema, compression, etc, usually of the intracanalicular segment. Field defects can be demonstrated in opticochiasmal injury. Monocular field defects (altitudinal, temporal) have been described²³. High resolution computed tomography shows fracture of the optic canal is present, while MRI shows the integrity of the nerve with intrinsic changes in signal intensity. VEP play an important role in management and prognostication in optic nerve injury²³.

Management: No other cranial nerve injury has been dogged by unresolved controversy in management (operative versus conservative) as the optic nerve, and this injury has a direct bearing on the quality of life in a conscious patient. Mahapatra and Bhatia were first to carry out protocol based prospective study and established the role of visual evoked potentials in the management²³. They performed studies following different protocols, and showed spontaneous visual recovery in 51-57% cases on conservative management. The regime followed is:

1. All patients are given megadoses of dexamethasone

(initial dose of 0.75 mg/kg, followed by 0.33 mg/kg every six hours for next 24 hours)²⁴. Steroids are beneficial by reducing cellular edema, membrane stabilizing action and by reducing circulatory spasm. Recovery rates are varied in different studies, ranging from 30 to 100% following conservative regime^{10,25}.

2. No patient is operated within three weeks. VEP is recorded every week.
3. In cases of visual recovery or in cases with no perception of light, no surgery is carried out.
4. In patients with partial recovery which becomes static, optic nerve decompression can be carried out.
5. In cases identifiable bony fragments and haematomas are present, optic nerve decompression is carried out at the earliest opportunity²⁶.

Chiasmal injury: Chiasmal injury is rare, seen in 0.3% of all cases with head injury¹⁹. It is often associated with severe acceleration-deceleration strain, hence, it is likely that the low incidence of chiasmal injury is related to overall survival from severe head injury. Severe frontal impact can cause fracture in the region of sella and clinoids. There may be multiple facial fractures, causing separation of the optic foramina and splitting of the chiasm²⁷. Skull base fracture can extend to the sella and clinoids, and cause direct injury to the chiasm. Interruption to blood supply of chiasm can occur leading to visual interruption and hypothalamic dysfunction²⁸.

The injury is diagnosed once the level of consciousness improves and visual deficits are noticed. Bitemporal field defects are noted, and in case of associated optic nerve injury, there will be visual loss in that eye. Funduscopy reveals pallor of the optic disc on the nasal side. Other cranial nerves may also be involved. Management is restricted to relief of compressive lesion – bony fragment or a haematoma.

OCULOMOTOR NERVE

Head trauma accounts for 8-16% of all oculomotor palsies^{29,30}, and oculomotor palsy is seen in 2.9% of all head injuries, including those patients with multiple cranial nerve involvement¹⁶. Of all the cranial nerves, oculomotor palsy in a patient with head injury imparts a sense of urgency in imaging and management owing to the possibility of an expanding intracranial haematoma in such a patient.

Anatomical features: The oculomotor nerve arises from its nucleus in the midbrain. Each of these nuclei has subnuclei that innervate individual ocular muscles. The fibers destined for superior rectus arise from the opposite nucleus and decussate in the midline. Rest of the muscles are innervated by their nuclei that are on the same side. The oculomotor fascicles pass through the red nucleus and emerge from the midbrain through the cerebral peduncle, in the interpeduncular fossa. In the subarachnoid space, the oculomotor nerve passes between the superior cerebellar and posterior cerebral arteries, coursing forward near the medial aspect of uncus of the temporal lobe. It enters the lateral wall of cavernous sinus along with trochlear and ophthalmic nerves. At the superior orbital fissure, the nerve divides into a superior and an inferior divisions. In the orbit, the superior division innervates the superior rectus and levator palabrae superioris, while the inferior division innervates the inferior and medial recti and the inferior oblique. In addition, the inferior division carries the presynaptic parasympathetic outflow to the ciliary ganglion (sphincter pupillae and ciliary muscles).

Mechanism of injury: Midbrain haematoma in the tectal region can present with oculomotor palsy (Fig 5). Oculomotor palsy often results from compression of the nerve at the tentorial hiatus by uncus in trantentorial herniation (Fig 6). Avulsion or stretching of the nerve at mesencephalo-pontine junction can also result in isolated oculomotor palsy³¹. More often, oculomotor palsy occurs together with that of other ocular motor nerves contained in the cavernous sinus in case of skull base fracture. Injury at superior orbital fissure, orbit or maxillofacial injury can result in injury to superior or inferior divisions of the nerve.

Diagnosis: In the setting of head injury, unilateral mydriasis (Hutchison's pupil) assumes ominous importance as a pointer to ipsilateral supratentorial

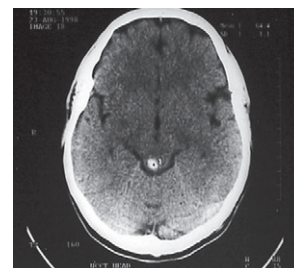


Fig 5: Dorsal midbrain haematoma in a patient with oculomotor palsy

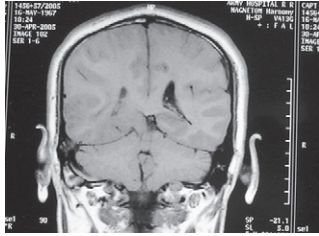


Fig 6: Coronal MRI showing transtentorial herniation

expanding haematoma. Invariably, this is accompanied by concurrent alteration in sensorium. Mydriasis may be accompanied by ptosis and extraocular muscle weakness. An avulsion or stretch injury is suggested by the rapid recovery of consciousness in an otherwise complete motor palsy³². The injury may be relatively mild³³. In a patient with proptosis, time should be allowed for the swelling to regress before ocular movements can be assessed. Detection of ocular pulsations and bruit over the eyeball makes the diagnosis of a caroticocavernous fistula obvious. The nerve can be injured in its course in the brainstem also by shearing injury. A lesion at the red nucleus will give rise to contralateral rest tremor with ipsilateral oculomotor palsy (Benedikt syndrome). A lesion at the cerebral peduncle will result in ipsilateral oculomotor palsy with contralateral hemiparesis (Weber syndrome). A nuclear lesion will manifest as bilateral ptosis, contralateral superior rectus palsy and ipsilateral weakness of remaining ocular muscles supplied by the oculomotor nerve.

Course: Ocular motility should be assessed after improvement in the level of consciousness, and resolution of periorbital swelling. Palsy due to a compressive lesion is likely to resolve on removal of the lesion, while injury to the fascicles is likely to give rise to aberrant regeneration, where axons terminate in inappropriate structures. Such a regeneration can result in elevation of ptotic lid on adduction, and a pupil that is poorly reactive to light but constricts with adduction³⁴. Management of unresolved oculomotor palsy is difficult, and extraocular muscle surgery can achieve binocular vision in primary position and also in reading position.

TROCHLEAR NERVE

The incidence of trochlear nerve injury is 2.14% in head injuries¹⁶, and the injury is often accompanied by injury to other ocular motor nerves.

Anatomical features: Trochlear nerve is a thin, slender nerve and is the longest of all ocular motor nerves. After

its origin in the midbrain, it decussates in the anterior medullary velum, and is the only cranial nerve to exit dorsally. In its subarachnoid course, it sweeps laterally around the midbrain in the cisterna ambiens, or in the free edge of the tentorium. It penetrates the dura below the posterior clinoid process to enter the lateral wall of the cavernous sinus. It enters the orbit through the superior orbital fissure and ends by supplying the superior oblique muscle.

Mechanism: Trochlear nerve may be injured in isolation in its subarachnoid course. A sudden deceleration impact or blow to the head may cause the brain to move back, and the brainstem to impact against the tentorium, resulting in trochlear nerve injury (Fig 7). The injury can occur in dorsal midbrain, or in the free edge of the tentorium. Bilateral trochlear nerve injury is always due to trauma^{35,36}, and has been reported after child abuse involving violent shaking³⁷.

Diagnosis: Diagnosis of trochlear nerve injury is made generally in a conscious and cooperative patient. The patient complains of diplopia with a perceived slant in the environment, which is compensated by adopting the characteristic head tilt (Bielchowsky). These patients will have difficulty in descending the stairs and in reading newspaper or a book. The head will be tilted away from the affected eye (Fig 7). Examination reveals hypertropia (higher affected eye) that worsens on lateral gaze. Bilateral trochlear palsy is diagnosed by the presence of alternating hyperdeviation (upward deviation of one eye) in various positions of upward gaze (Fig 8). In a concomitant oculomotor palsy, trochlear palsy can be suspected from absence of intorsion.

Management: Spontaneous recovery occurs in 65% patients with unilateral trochlear palsy³⁸. Use of eye patch or prisms pasted onto spectacles can be useful for achieving binocular single vision. In case of incomplete recovery after 12 months, corrective ocular muscle surgery can be carried out.

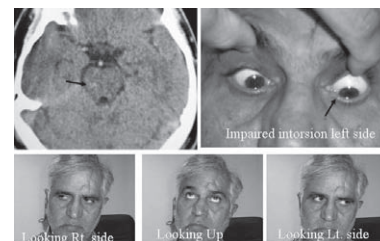


Fig 7: Patient with unilateral trochlear palsy. CT shows a haematoma in the brainstem

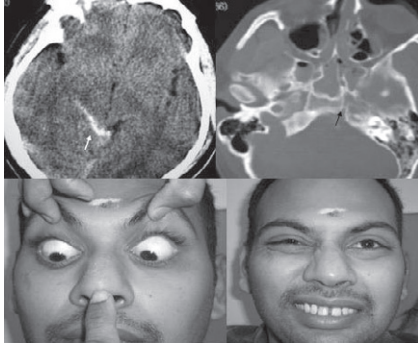


Fig 8. Patient with bilateral trochlear palsy and left facial palsy. CT shows blood in the basal cisterns.

ABDUCENS NERVE

Head injury accounts for nearly 3–15% of abducens palsies³⁰. In a recent series from India the incidence has been found to be 3.02%, majority of whom had multiple cranial nerve injury¹⁶, making it the most frequently injured ocular motor nerve.

Course: Abducens nerve emerges from the horizontal sulcus between the pons and medulla, lateral to corticospinal bundles. It courses in the prepontine cistern close to the anterior inferior cerebellar artery, and enters the Dorello's canal beneath the petroclinoid ligament. In the cavernous sinus, it lies between the intracavernous segment of internal carotid artery medially, and ophthalmic division of the trigeminal nerve laterally. It enters the orbit through the superior orbital fissure to innervate the lateral rectus muscle.

Mechanism: The long intradural course, its passage over the petrous ridge with its relative fixity under the petroclinoid ligament and to the cavernous sinus makes it vulnerable to stretch or tear³⁹. Hyperextension trauma to cervical spine can also cause abducens nerve palsy, accompanied with lower cranial palsies⁴⁰.

Diagnosis: A conscious patient complains of diplopia on distant fixation, and examination of ocular movements reveals convergence of visual axes, and lateral rectus palsy. In an unconscious patient, the eyeball can be seen adducted, with no abduction on oculocephalic response.

Management: Lateral rectus palsy may recover completely or incompletely. Diplopia may be corrected by prisms, or by botulinum therapy for antagonist medial rectus to achieve binocular vision. Ocular muscle surgery is offered in cases of persistence of lateral rectus palsy after 6–12 months.

TRIGEMINAL NERVE AND GANGLION

Branches of trigeminal nerve are often injured during severe maxillofacial and skull base injury, as these nerves exit the various foramina from the skull.

Mechanism: The supraorbital and infraorbital nerves are injured in trauma to the forehead, orbit and maxilla. The inferior dental branch and the mandibular division can be injured in fractures of the mandible. Skull base injury with injury to the cavernous sinus region can result in ocular motor dysfunction with sensory impairment over ophthalmic division. Closed or penetrating injuries can cause injury to the ganglion⁴¹. Skull fractures involving the middle fossa can extend into the foramen ovale and foramen rotundum and damage the exiting nerves. O'Connell suggested that the trigeminal nerve is especially vulnerable where the sensory root angulates as it passes through the dural foramen proximal to the Meckel's cave⁴².

Diagnosis: Sensation along the cutaneous distribution of the involved nerve is affected. Sometimes, troublesome hyperpathia can occur in the distribution of the nerve. Corneal anesthesia should be looked for, since the eye requires to be protected against exposure keratitis and corneal ulceration in such cases.

Management: The treatment of injuries to the peripheral branches is expectant. Hyperalgesia can be treated with carbamazepine or gabapentin. Alternatively, in intractable cases, the involved root can be sectioned or radiofrequency ablation of the ganglion can be done, to relieve pain.

PETROUS FRACTURES

Although injury to the facial and vestibulocochlear nerves is common after head injury and there is voluminous literature on the topic, there is no unanimity on their management. Temporal bone fracture is a frequent accompaniment to their injury, and it would be pertinent to briefly review this fracture here.

Temporal bone fracture: Temporal bone fractures have been diagnosed more often in the post-CT era, since these are difficult to visualize on skull radiographs. The compactness, presence of cavities and canals, and the oblique orientation of the petrous predisposes to its fracture. Petrous fractures have been described in orientation to the long axis of the petrous pyramid. Accordingly, these have been classified as follows⁴³:

- i. Transverse or vertical
- ii. Longitudinal or horizontal
- iii. Oblique

Transverse fractures: These fractures account for nearly 30% of all petrous fractures⁴⁴. These result from occipital blows and occur at right angles to the petrous pyramid. Medial fractures occur near the internal acoustic meatus, and lateral fractures occur close to the bony labyrinth (Fig 9). Seventh and eighth nerve injury occurs in nearly 50% of the cases, and haemotympanum is often observed on otoscopy.

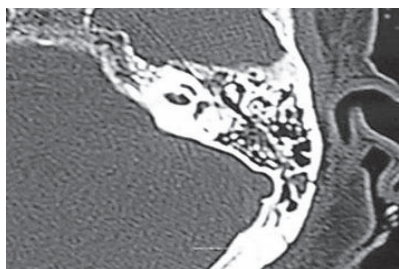


Fig 9: CT showing transverse fracture of the petrous

Longitudinal fractures: These are more common as compared to transverse fractures, accounting for about 70% of all cases of petrous fractures. Fracture line runs parallel to the longitudinal axis of the petrous, sparing the nerves (Fig 10). There is however, disruption of ossicular chain with conductive deafness. The fracture line can extend into the clivus and opposite temporal pyramid. Laceration of tympanic membrane can result in cerebrospinal fluid otorrhoea.

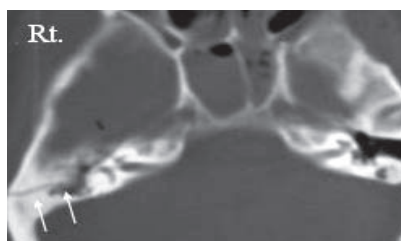


Fig 10: CT showing longitudinal fracture of the petrous

Oblique fractures: Oblique fractures are rare and occur due to a combination of force vectors that produce longitudinal and transverse fractures. Fracture dislocation of the entire petrous pyramid too has been reported⁴⁵. There is extensive basal dural tear with otorrhagia, CSF otorrhoea and meningitis.

FACIAL NERVE

Trauma is the second most common cause of facial

paralysis after Bell's palsy⁴⁶.

Anatomical features: After its exit from the brainstem. The facial nerve courses through the cerebellopontine angle to the petrous bone. It is relatively fixed at the geniculate ganglion. In the labyrinthine segment, the nerve occupies 80% of the cross-sectional area of the surrounding facial canal between the meatal foramen and geniculate fossa.⁴⁷ In contrast, the nerve occupies less than 75% of the facial canal as it passes peripherally through the larger tympanic and vertical segments of the canal. The meatal foramen is formed by dense periotic bone and confluence of vertical and horizontal crests of lateral internal auditory canal. Thus, the meatal foramen constitutes of a physiological bottle-neck especially in the presence of edema or injury of the facial nerve.

Mechanism: Head injury is a deceleration injury, and facial nerve is injured at its site of tethering; at the geniculate ganglion, where it is tethered by the greater superficial petrosal nerve. The shearing force results in intraneural contusion, edema and hemorrhage. Transection can occur in severe cases. The meatal foramen due to its narrow size in the labyrinthine segment is another site of compression (Figs 11 & 12). Fracture of the otic capsule indicates severe trauma, and the facial nerve damage is generally complete in such cases⁴⁸. Facial palsy can be seen in 45% to 50% of patients with gunshot wound⁴⁹. Missile fragment enters from the lateral or inferior aspect of the temporal bone, and as it lodges in the bone, it dissipates its energy, damages the facial nerve. The extratemporal facial nerve, the stylomastoid foramen and the vertical segment are the sites most often injured⁵⁰. The nerve is generally completely transected.

Immediate paralysis occurs due to transection or other form of severe neural trauma, and carries a worse prognosis. Delayed paralysis (after 24 hours of injury), on the other hand, occurs due to nerve edema and

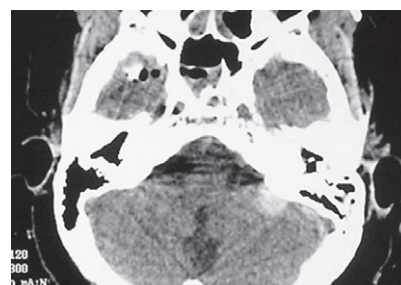


Fig 11: CT showing subdural haematoma at the cerebellopontine angle in a patient with head injury and facial palsy

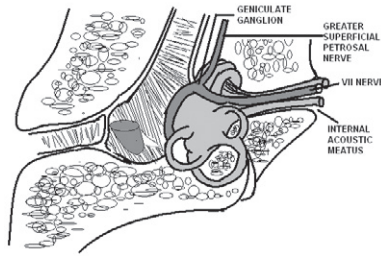


Fig 12: Diagram of the intratemporal course of facial nerve

swelling of the nerve within its sheath or epineurium, and carries a better prognosis. Delayed paralysis can also occur due to external compression by an expanding haematoma or oedema of loose fibrous tissue and periosteum between the nerve and the bony canal.⁵¹ Bilateral paralysis is also reported^{52,53}.

Diagnosis: Generally facial asymmetry is obvious in a conscious patient. In an unconscious patient, there is incomplete eye closure with Bell's phenomenon, and blowing in and out of cheek with breathing. Bleeding from ear, CSF otorrhoea, Battle sign and hearing impairment are other features that should alert the physician to the possibility of a facial nerve injury. Detailed evaluation of secretomotor and taste sensations can be done when the patient is conscious and cooperative for such evaluation.

Topographic localization of site of injury: The site of injury can be ascertained by Schirmer's test, submandibular salivary flow, stapedial reflex and electrogustometry. However, in contemporary practice, high resolution CT and electrical testing studies (electroneurography, maximal stimulation test) effectively delineate the site of injury.

Management: Management of traumatic facial palsy continues to be controversial, with no unanimity on the indications and timing for surgical intervention. Turner⁵⁴ reported on the natural history of immediate and delayed traumatic facial paralysis, with satisfactory return of facial function in eighty-two percent of delayed facial palsy. Patients with immediate paralysis had good recovery in fifty three percent cases. Even incomplete recovery may be functionally acceptable. Patient should be reassured and a watchful expectancy management instituted. Care is taken to avoid exposure keratitis and dryness of the cornea.

Earlier teaching of waiting for three weeks (time when neuron's metabolism is maximized) has now run out of

favour, with findings of experimental studies advocating early surgery. Decompression of the facial nerve improves recovery if performed within 48 hours, and slitting of the epineurium does not confer any benefit⁵⁵. Presence or absence of anacusis determines the approach to decompression of the facial nerve. In anacusis, tranabyrinthine approach is used, since it allows excellent access to the entire intratemporal segment of the nerve. In the presence of hearing, a combined transmastoid-middle fossa approach which permits access to perigeniculate and vertical segments of the nerve is used⁵⁵. Results of facial nerve grafting appear to favour early repair over delayed grafting, and there is no evidence that waiting 21 days improves surgical outcome.

Sequelae and recovery: Anatomically intact facial nerve has a higher potential for recovery. There may be unpleasant sequelae of recovery, in the form of dysacusis, ageusia, epiphora, gustatory lacrimation. Late sequelae can be in the form of facial contractures, tics, spasm and synkinesis. Recovery from facial palsy is graded according to House-Brackmann grading system (Table 2)

Table 2: Grading of recovery from facial paralysis (House Brackmann⁵⁶)

Grade I	NORMAL Normal facial function in all areas
Grade II	MILD DYSFUNCTION Gross: slight weakness noticeable on close inspection. May have synkinesis, At rest: normal symmetry and tone, Motion: forehead, moderate-to-good function. Eye closure complete. Mouth, slight asymmetry
Grade III	MODERATE DYSFUNCTION Gross: Obvious but not disfiguring difference between the two sides. Noticeable but not severe synkinesis, contracture or hemifacial spasm, or both. At rest, normal symmetry and tone. Motion: Forehead, slight-to-moderate movement. Eye, complete closure with effort. Mouth, slightly weak with maximum effort.
Grade IV	MODERATELY SEVERE DYSFUNCTION Gross: Obvious weakness or disfiguring asymmetry, or both. At rest, normal symmetry and tone. Motion: Forehead, none. Eye, incomplete closure. Mouth, asymmetric with maximum effort
Grade V	SEVERE DYSFUNCTION Gross: Only barely perceptible motion. At rest, asymmetry, Motion: Forehead, none. Eye, incomplete closure. Mouth, slight movement
Grade VI	TOTAL PARALYSIS No movement

Perinatal facial palsy: Absence of mastoid process places vertical segment of the facial nerve at risk. Extracranial facial nerve palsy can occur in cases of prolonged labor, due to compression of face against the maternal sacrum. Facial nerve injury can also occur in association with forceps delivery. The baby may have haemotympanum, periauricular ecchymosis and asymmetric crying facies. Electromyographic evidence of preserved or worsening neuromuscular activity is diagnostic⁵⁸. The condition should be differentiated from congenital facial palsy, which has a developmental etiology and is associated with maldevelopment of structures of first and second branchial arches. Spontaneous recovery occurs in most of the cases⁵⁹.

VESTIBULOCOCHLEAR NERVE

Following head injury, hearing loss can occur due to damage to the nerve, endorgan or the conducting elements.

Mechanism: Transverse fractures of the petrous can damage the anterior portion of the vestibule and the cochlea. These organs can suffer concussion also. Injury can occur with damage to central auditory pathways in the brainstem. Pressure waves generated by a blow to the head damage the hair cells in the cochlea and cause high frequency hearing loss and tinnitus⁶⁰. Besides the fracture of the bony otic capsule, the nerve can be damaged at the internal acoustic meatus.

Diagnosis: In a patient with altered sensorium, ear bleed, CSF otorrhoea and Battle sign should arouse the suspicion of eighth nerve injury. In a conscious patient, a thorough medical history should include information on vertigo, nausea, tinnitus and impaired hearing. Otoscopic examination might reveal haemotympanum or presence of CSF in the middle ear (*liquor tympanum*). Facial palsy often coexists the injury. Conscious patient should undergo audiometric testing, caloric testing (if the tympanic membrane is intact) and brainstem-evoked responses.

Course and Management: Conductive deafness usually shows useful recovery and is amenable to surgical intervention. However, sensorineural deafness shows poor recovery, especially if the hearing loss has been complete. Tinnitus is usually self-limiting and requires no more treatment than reassurance. However, labyrinthine symptoms (vertigo, nausea, dizziness) may persist, and may require treatment with labyrinthine

sedatives. A patient with persisting labyrinthine symptoms should be investigated for perilymphatic fistula⁶¹.

GLOSSOPHARYNGEAL, VAGUS AND ACCESSORY NERVES

This trio of lower cranial nerves is injured together due to their close proximity with one another in the jugular foramen.

Mechanism: These nerves, after exiting the brainstem enter the jugular foramen, and a fracture of this region injures the three nerves (Fig 13). The injury is uncommon, due to infrequent injury to the posterior skull base as compared to that of the anterior and the middle skull base. More often, however, the nerves are injured in their extracranial course due to stab or gunshot injuries, or due to stretch in falls from height. Occipital condyle fracture too can lead to injury to ninth and tenth nerves⁶².

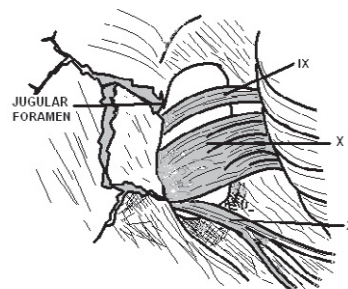


Fig 13: Diagrammatic representation of injury at jugular foramen

Diagnosis: Injury to the ninth, tenth and eleventh nerves is underestimated, as it may not be readily apparent in the setting of head injury. Patient has dysphonia, dysphagia, depressed gag reflex, ipsilateral palatal palsy with paralysis of trapezius and sternocleidomastoid muscles (Vernet syndrome). Indirect laryngoscopy confirms ipsilateral vocal cord palsy. This is accompanied by loss of sensation over the posterior third of tongue, soft palate, uvula and larynx. A lesion outside the skull is likely to affect the cervical sympathetic, and the clinical picture includes a Horner's syndrome (Villaret's syndrome).

Course: Prognosis is generally favorable in cases not accompanied by skull base fracture. These patients, if swallowing is impaired causing aspiration, are fed by nasogastric tube. Once swallowing is reestablished, oral feeding can be resumed. If risk of aspiration persists, these patients will require alternative enteral feeding

(long-term nasogastric tube feeds with soft tubes, percutaneous endoscopic gastrostomy or feeding jejunostomy) to maintain hydration and nutritional intake. Detailed evaluation by swallowing therapist will be required for long-term care and management.

HYPOGLOSSAL NERVE

Hypoglossal nerve is one of the least injured nerves in head injury. It arises from a nucleus column in the floor of the fourth ventricle derived from the same embryonal cell groups as the nuclei of III, IV and VI nerves. The rootlets join in a dural sleeve and the nerve enters the tough bony hypoglossal canal medial to the occipital condyle. As it emerges from the condylar canal, the nerve passes between the jugular vein and carotid artery, and courses anteriorly on the hyoglossus, supplying the muscles of the tongue. It receives sympathetic fibers from superior cervical ganglion, some fibers from the vagus and from motor roots of C1 and C2 via ansa cervicalis.

Mechanism: Fractures of the occipital condyle can damage the hypoglossal nerve as it passes medial to the condyle. Hypoglossal palsy can occur late, after an apparently minor head trauma and condylar injury^{63,64,65}. More often, hypoglossal nerve is injured in the course of surgery on the neck, while operating on the submandibular gland and on C2/C3 cervical disc. Bilateral injury is also described⁶⁶.

Diagnosis: Patients with occipital condyle injury often complain of cervicgia, with difficulty in moving the food bolus in the mouth. Speech is slurred. Clinically, tongue movements are absent on the side of injury, with deviation of the protruded tongue to the injured side. Recovery is expected in mild injuries.

COLLET-SICARD SYNDROME

The Collet-Sicard syndrome comprises of a clinical picture of collective damage to the last four cranial nerves. The syndrome was described first by Collet in 1916 in an artillery non-commissioned officer following a shrapnel injury to the neck and skull base⁶⁷. The syndrome can result from injury in the region of jugular foramen and condylar canal. There is dysphonia, bovine cough, nasal regurgitation of fluids or episodes of aspiration with choking. Weakness of sternocleidomastoid and trapezium is seen along with homolateral tongue wasting. Deep aching pain in the region of ear indicates damage to the ninth and tenth nerves. A Horner's syndrome often accompanies an

extracranial lesion.

Collet-Sicard syndrome has been reported only thrice after head injury^{68,69,70}. There is extensive fracture of the posterior skull base with involvement of condylar canals, jugular foramen, clivus⁶⁹. Mild cases show recovery, while in severe and complete injuries, prognosis for recovery is poor. Paralysis of lower four cranial nerves together with that of abducens nerve has been reported after hyperextension injury to cervical spine^{40,71}.

Acknowledgements

Dr Purav Patel for Figs 7 and 8

REFERENCES

1. Keane JR, Baloh RW. Post-traumatic cranial neuropathies. In, Evans RW (ed). *The Neurology of Trauma*. Philadelphia: Saunders, 1992: 849-68.
2. Doty RL, Yousem DM, Pham LT, et al. Olfactory dysfunction in patients with head trauma. *Arch Neurol* 1997; 54: 1131-40.
3. Schecter PJ, Henkin R. Abnormalities of taste and smell after head trauma. *J Neurol Neurosurg Psychiat* 1974; 37: 802-10.
4. Sumner D. Post-traumatic anosmia. *Brain* 1964; 87:107-20.
5. Levin HS, High WM, Elsnberg HM. Impairment of olfactory recognition after closed head injury. *Brain* 1985; 108: 579-91.
6. Sumner D. Disturbance of the senses of smell and taste after head injuries. In, Vinken PJ, Bruyn BW (eds). *Handbook of Clinical Neurology Vol 24: Injuries of the Brain and Skull Part 2*. Amsterdam: Elsevier, 1976: 1-25.
7. Jovic JN, Bajcetic D, Vucinic MD, Ocic G. Chemosensory impairment in missile head injury. *Proceedings of International Conference on Military Medicine*, 2002.
8. Jafek BW, Eller PM, Esses BA, Moran DT. Post-traumatic anosmia. *Arch Neurol* 1989; 46:300-4.
9. Gjerris F. Traumatic lesion of visual pathway. In, Vinken PJ, Bruyn GW (Eds). *Handbook of Clinical Neurology Vol 24*. North Holland Publishing Company, Amsterdam: 1976, pp 24-57.
10. Mahapatra AK. Current management of optic nerve injury. *Progress in Clinical Neurosciences* 1997; 12:345-52.
11. Hughes B. Indirect injury of optic nerve and chiasm. *Bull John Hop Hosp* 1962; 111:98-126.
12. Crompton MR. Visual lesions in head injury. *Brain* 1970; 93:785-92.

13. Fukado Y. Microsurgical transthemoidal optic nerve decompression. Experience with 750 cases. In, Janetta P, Samii M (eds). Cranial Nerves. Springer-Verlag 1981: pp 125-8.
14. Mahapatra AK, Tandon DA, Bhatia R, Banerji AK. Optic nerve injury: A prospective study of 100 patients. *Neurol India* 1992; 40:17-21.
15. Mahapatra AK. Rationale of optic nerve decompression in optic nerve injury. *Ind J Neurotrauma* 2004; 1:33-6.
16. Patel P, Kalyanaraman S, Reginald J, et al. Post-traumatic cranial nerve injury. *Ind J Neurotrauma* 2005; 2:27-32.
17. Anderson RA, Panje WR, Gross CE. Optic nerve blindness following blunt forehead trauma. *Ophthalmology* 1982; 89:445-55.
18. Gross CE, DeKock JR, Panje WR, et al. Evidence for orbital deformity that may contribute to monocular blindness following minor frontal head trauma. *J Neurosurg* 1981; 55:963-6.
19. Neetens A. Traumatic bitemporal hemianopsia. *Neuroophthalmology* 1992; 12:375-83.
20. Walsh FB, Lindenberg R. In, Die Veranderugen ges. Schnervan beci indirectem trauma. Entwicklung and Fortschritt in der Angenheilkundge-Fortbildung skurs tur Augenarzte. Hamburg, 1962. Fredinand, Enke Verlag, 1963.
21. Bhatoe HS, Suryanarayana KV, Gill HS. Recurrent massive epistaxis due to traumatic intracavernous internal carotid artery aneurysm. *J Laryngol Otolology* 1995; 109:650-2.
22. Maurer MY, Mills M, German WJ. Triad of unilateral blindness, orbital fracture and massive epistaxis in head injury. *J Neurosurg* 1961; 18:837-46.
23. Mahapatra AK, Tandon DA. A prospective study of 250 patients with optic nerve injury. In, Madjid Samii (Ed). Skull Base: Anatomy, Radiology and Management. S Karger Basel 1994: pp 305-9.
24. Spoor TC, Hartel WC, Lensink DB, Wilkinson MJ. Treatment of traumatic optic neuropathy. *Am J Ophthalmol* 1990; 110:665-9.
25. Matsuzaki H, Kunita M, Kawai K. Optic nerve damage in head trauma: Clinical and experimental studies. *Jpn J Ophthalmol* 1982; 26:447-61.
26. Guy J, Sherwood M, Day AL. Surgical treatment of progressive visual loss in traumatic optic neuropathy. *J Neurosurg* 1989; 70:799-801.
27. Osterberg G. Traumatic bitemporal hemianopsia (sagittal tearing of the optic chiasma). *Acta Ophthalmol* 1938; 16:466-474.
28. Traquir HM, Dott NM, Russell WR. Traumatic lesions of the optic chiasma. *Brain* 1935; 58:398-411.
29. Rucker CW. The causes of paralysis of the third, fourth and sixth nerves. *Am J Ophthalmol* 1966; 61: 1293-8.
30. Rush JA, Younge BR. Paralysis of cranial nerve III, IV and VI. Cause and prognosis in 1000 cases. *Arch Ophthalmol* 1981; 99: 76-80.
31. McCormick WF. Pathology of closed head injury. In, Wilkins RH, Rengachary SS (eds). Neurosurgery Vol 2. McGraw-Hill, New York: 1996: 2639-2666.
32. Memon MY, Paine KWE. Direct injury of the oculomotor nerve in craniocerebral trauma. *J Neurosurg* 1971; 35:461-4.
33. Chen CC, Pai YM, Wang RF, Wang TL, Chang CF. Isolated oculomotor nerve palsy from head trauma. *Br J Sports Med* 2005; 39:234.
34. Walsh FB. Third nerve regeneration. *Br J Ophthalmol* 1957; 41:577-98.
35. Younge BR, Sutula F. Analysis of trochlear nerve palsies. Diagnosis, etiology and treatment. *Mayo Clin Proc* 1977; 52:11-18.
36. Lee J, Flynn JT. Bilateral superior oblique palsies. *Br J Ophthalmol* 1982; 69:508-13.
37. Cackett P, Fleck B, Mulhivill A. Bilateral fourth nerve palsy occurring after shaking injury in infancy. *Journal AAPOS* 2004; 8:280-1.
38. Sydnor CF, Seaber JH, Buckley EG. Traumatic superior oblique palsies. *Ophthalmology* 1982; 89:134-8.
39. Arias MJ. Bilateral traumatic abducens nerve palsy without skull fracture and with cervical spine fracture: Case report and review of literature. *Neurosurgery* 1985; 16:232-4.
40. Rosa L, Carol M, Bellegarrigue R, Ducker TB. Multiple cranial nerve palsies due to hyperextension injury to the cervical spine. Case report. *J Neurosurg* 1984; 61:172-3.
41. Jefferson G, Schorstein J. Injuries to the trigeminal nerve, its ganglion and its division. *Br J Surg* 1955; 42:561-81.
42. O'Connell JEA. Trigeminal false localizing signs and their causation. *Brain* 1978; 101:119-42.
43. Toglia JU, Katinsky S. Neuro-otological aspects of closed head injury. In, Vinken PJ, Bruyn GW (Eds). Handbook of Clinical neurology Vol 24. New York: Elsevier, 1976: 119-40.
44. Tos M. Fractures of the temporal bone. The course and sequelae in 248 fractures of the petrous temporal bone.

- Ugeskr Laeger* 1971; 133:1449-56.
45. DeVilliers JC. Fracture dislocation of the petrous temporal bone. *J Neurol Neurosurg Psychiat* 1971; 34:105-6.
 46. Turel Keki E, Sharma NK, Verghese Joy, Desai Sanjeev. Post-traumatic facial palsy: Treatment options and strategies. *Ind J Neurotrauma* 2005; 2:33-4.
 47. Fisch U. Total facial nerve decompression and electroneurography. In, Silverstein H, Norrell H (Eds). *Neurological surgery of the ear*. Birmingham, Aesculapius: 1977.
 48. Harker LA, McCabe BF. Temporal bone fractures and facial nerve injury. *Otolaryngol Clin N Amer* 1974; 7:425-31.
 49. Duncan NO, Coker NJ, Jenkins HA, Canalis RF. Gunshot injuries of the temporal bone. *Otolaryngol Head Neck Surg* 1986; 94:47-55.
 50. Coker NJ, Kendall KA, Jenkins HA, Alford BR. Traumatic intratemporal facial nerve injury: Management rationale for preservation of function. *Otolaryngol Head Neck Surg* 1987; 97: 262-9.
 51. Uetsuka H. Compression of the facial nerve. *Arch Otolaryngol* 1972; 95:346-9.
 52. Anjaneyulu A, Rao M, Mohandas S. Bilateral facial nerve palsy following head injury. *Neurology India* 1993; 41:238-9.
 53. Prusty GK. Post-traumatic bilateral facial palsy. *Neurology India* 1991; 6:290-1.
 54. Turner JWA. Facial palsy in closed head injuries. *Lancet* 1944; 246:756-7.
 55. Kelly KE, Tami TA. Temporal bone and skull base trauma. In, Jackler RK, Brackmann DE (Eds). *Neurotology*. Mosby, St Louis: 1994, pp 1127-1147.
 56. House JW, Brackmann DE. Facial nerve grading system. *Otolaryngol Head Neck Surg* 1985; 93:146-7.
 57. May M. Disorders in newborns and children. In, May M (Ed): *The facial nerve*. New York, Thieme Stratton, 1986.
 58. Smith IM, Murray JAM, Cull RE, Slattery J. Facial weakness: A comparison of clinical and photographic methods of observation. *Arch Otolaryngol Head Neck* 1991; 117:906-9.
 59. Cohn BT, Brahms MA, Cohn M. Injury to the eleventh cranial nerve in a high school wrestler. *Orth Rev* 1986; 15:590-5.
 60. Schuknecht HF. Mechanisms of inner ear injury from blows to the head. *Ann Otol Rhinol Laryngol* 1969; 78:253-62.
 61. Fee GA. Traumatic perilymphatic fistulas. *Arch Otolaryngol* 1968; 88:477-80.
 62. Urculo E, Errazola M, Arrazola M Jr, et al. Delayed glossopharyngeal and vagus nerve paralysis following occipital condyle fracture. *J Neurosurg* 1996; 84:522-5.
 63. Orbay T, Aykol S, Seckin Z, et al. Hypoglossal nerve palsy following fracture of occipital condyle. *Surg Neurol* 1989; 31:402-4.
 64. Indira Devi B, Dubey S, Shetty S, Jaiswal VK, Jaikumar PN. Fracture occipital condyle with isolated 12th. Nerve paresis. *Neurology India* 2000; 48:93-94.
 65. Delamont RS, Boyle RS. Traumatic hypoglossal nerve palsy. *Clin Exp Neurol* 1989; 26:239-41.
 66. Kervick MM, Bredfelt RC, Sheridan CD, Monroe AD. Bilateral injury to the hypoglossal nerve. *Arch Phy Med Rehab* 1977; 58:578-82.
 67. Collet FJ. Sur un nouveau syndrome paralytique pharyngolarynge par blessure de guerre. *Lyon Med* 1916; 124:121-9.
 68. Hashimoto T, Watanabe O, Takase M, et al. Collet-Sicard syndrome after minor head injury. *Neurosurgery* 1988; 23:367-70.
 69. Sharma BS, Mahajan RK, Bhatia S, Khosla VK. Collet-Sicard syndrome after closed head injury. *Clin Neurol Neurosurg* 1994; 96:197-8.
 70. Mohanty SK, Barrios M, Fishbone H, et al. Irreversible injury of cranial nerves 9 through 12 (Collet Sicard syndrome). *J Neurosurg* 1973; 38:86-88.
 71. Maclean JG, Taylor A. Combined lower cranial nerve injury. Complication of upper cervical or basal skull fracture. *J Roy Coll Surg Edin* 1991; 36:188-9.