



Journal of Coloproctology

www.jcol.org.br



Case report

Unusual finding after resection of rectal adenocarcinoma: report of two cases

Natalia Pranzetti Vieira^{a,*}, Maria de Lourdes Setsuko Ayrizono^{b,c},
Débora Helena Gonçalves Rossi^{b,c}, Priscilla de Sene Portel Oliveira^{b,c,d}, Raquel Franco Leal^b,
João José Fagundes^{b,c}, Cláudio Saddy Rodrigues Coy^{b,c}

^aDepartament of Coloproctology of Universidade Estadual de Campinas (UNICAMP), Campinas, SP, Brazil

^bDepartament of Surgery, Service of Coloproctology, Faculdade de Ciências Médicas, UNICAMP, Campinas, SP, Brazil

^cBrazilian Society of Coloproctology (SBCP), Rio de Janeiro, RJ, Brazil

^dHospital Estadual de Sumaré, Sumaré, SP, Brazil

ARTICLE INFO

Article history:

Received 13 March 2013

Accepted 24 April 2013

Keywords:

Desmoid tumor

Rectal adenocarcinoma

Pelvic recurrence

ABSTRACT

Pelvic recurrence after resection of rectal adenocarcinoma is a feared complication and is associated with a worse prognosis and low resectability rates. The differential diagnosis is difficult, as biopsy is seldom performed preoperatively. We report two cases of desmoid pelvic tumor after resection of rectal adenocarcinoma. Therapeutic options and literature review are described.

© 2013 Elsevier Editora Ltda. Este é um artigo Open Access sob a licença de [CC BY-NC-ND](#)

Achado incomum após ressecção de adenocarcinoma do reto: relato de dois casos

RESUMO

O aparecimento de tumor pélvico após ressecção de adenocarcinoma de reto é complicação temida e está associado à pior prognóstico e baixos índices de ressecabilidade. O diagnóstico diferencial é difícil, pois o diagnóstico histológico usualmente não é realizado no pré-operatório. São relatados dois casos em que houve o aparecimento de tumor pélvico após a ressecção de adenocarcinoma de reto, com diagnóstico histológico de tumor desmóide. As condutas adotadas e revisão da literatura são descritas.

© 2013 Elsevier Editora Ltda. Este é um artigo Open Access sob a licença de [CC BY-NC-ND](#)

Palavras-chave:

Tumor desmóide

Adenocarcinoma de reto

Recidiva pélvica

* Corresponding author.

E-mail: nana_pv@hotmail.com (N.P. Vieira)

Introduction

The postoperative follow-up of rectal adenocarcinoma aims at the identification of metastasis and local recurrence. The latter has been reported between 3% and 35%,¹ is difficult to be confirmed histologically in the preoperative period and has low rates of resectability. We report two cases in which pelvic recurrence of adenocarcinoma was suspected, but which were actually desmoid tumors (DTs).

Case reports

Case 1

NBS, female, 74 years old, submitted to abdominoperineal resection for rectal adenocarcinoma. The patient had pelvic infection and perineal suture dehiscence in the immediate postoperative period, showing good resolution with medical therapy. Four months after the surgery, she reported pelvic pain without alterations in the physical examination. She underwent a computed tomography (CT) screening of the abdomen and pelvis, which identified a heterogeneous lesion with hypodense center, irregular and poorly defined borders, measuring 5 cm in diameter, located in the pelvic region.

Positron-emission computed tomography (PET-CT) was performed, which showed areas of increased uptake in the presacral region, measuring 6.0 × 4.0 cm, with sacrococcygeal bone invasion, suggestive of neoplastic recurrence (Fig. 1). The carcinoembryonic antigen (CEA) was normal (0.2 ng / dL). It was then assumed that it was a recurrence of the primary lesion. Surgical resection was proposed and, at surgery, a new CT scan showed no evidence of distant metastases, disclosing the presence of the same lesion in the sacral region, with a slight increase in size (Fig. 2). Posterior approach was used for the surgical procedure and the lesion was resected together with the sacral vertebrae S4 and S5, with free macroscopic margins. Primary closure of the wound was performed. The patient recovered uneventfully and was discharged on the seventh postoperative day. Histopathological examination

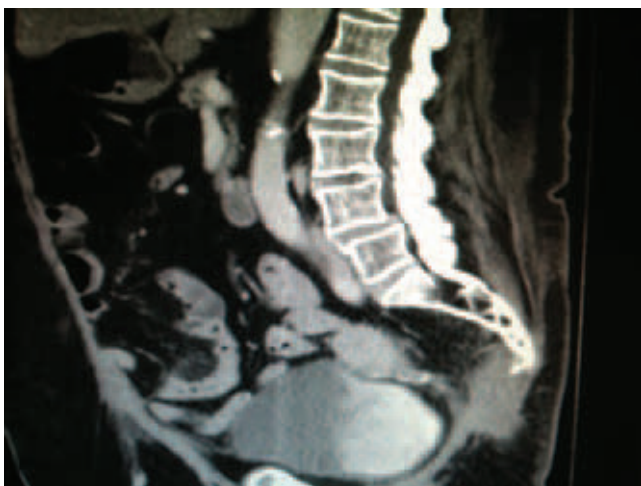

Fig. 1 – CT - sagittal view – tumor lesion aspect.

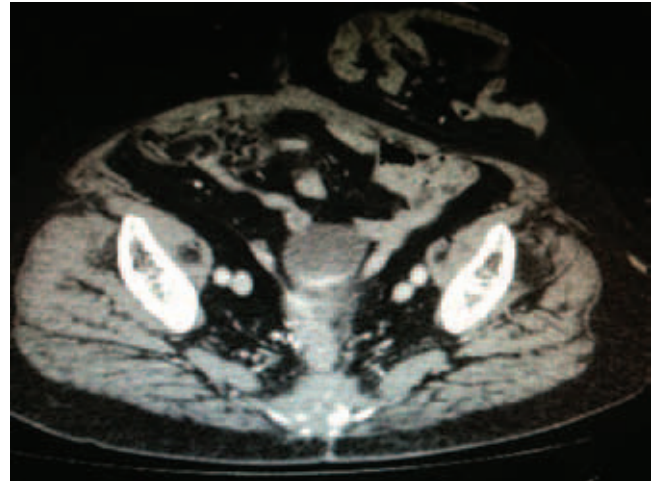


Fig. 2 – CT - axial view - presacral tumor lesion.

showed the tumor was a DT, involving soft tissue and adjacent bone tissue, measuring 9.0 × 7.0 × 4.0 cm, with free margins. The patient is being followed on an outpatient basis and has no evidence of recurrence after six months postoperatively.

Case 2

MFB, 63 years old, female, was submitted to rectosigmoidectomy with coloanal anastomosis for rectal adenocarcinoma. She developed pelvic suppuration and underwent another lowering surgical procedure after 12 months. Five months after the second surgery, the patient had pelvic pain and a presacral pelvic lesion was diagnosed by CT. PET-CT was performed, which showed areas of increased uptake in the presacral region, measuring 6.0 cm. CEA levels were also normal (3 ng/dL). As the patient refused surgical treatment, a CT-guided percutaneous biopsy was performed with histological diagnosis of DT. Treatment with tamoxifen was started and after two months there was partial regression of the lesion and disappearance of symptoms.

Discussion

This report describes two cases of rectal adenocarcinoma that evolved with pelvic tumors, of which histological analysis showed they were desmoid tumors.

DT, also known as deep fibromatosis, is a non-encapsulated tumor that originates from the fibroblasts of musculoaponeurotic tissues. It was first described in 1832, later receiving the name of desmoid to identify its macroscopic appearance (from the Greek word *desmos*, meaning tendon or ligament).^{2,3,4} DTs account for to 0.03% of all cancers and 3% of all soft tissue tumors. The estimated incidence in the general population is 2-4 new cases per million per year.^{4,5,6} Its peak incidence is between 25 and 35 years old, with a female predominance of 2:1.^{5,6,7,8}

Its etiology is not well known, but, in general, it is related to mutations in the activation of beta-catenin (for sporadic tumors) and APC gene mutations.^{9,10} These tumors are locally

aggressive, with no potential for the development of metastases, eventually causing deformity of the adjacent organs, pain and organic dysfunction, depending on the affected area.^{2,10,12}

DTs may be solitary or multiple and can occur anywhere, including the trunk, extremities and abdomen. Currently, it is known that these tumors may be sporadic or related to Familial Adenomatous Polyposis (FAP) and are more commonly found in the abdominal cavity of these patients.^{3,5,7,13} Another group described is represented by young women and the influence of estrogen is important in these cases.^{9,14} This evidence is confirmed by the higher incidence of DT in women during their reproductive life, due to apparent tendency of tumors developing during pregnancy or shortly after, by its occasional disappearance after menopause, the experimental production of similar lesions in animals treated with estrogen administration and the benefit of antiestrogen therapy in patients with this type of tumor.^{5,11}

Its natural history and clinical behavior is unpredictable, ranging from fast-growing forms to indolent tumors and may remain stable.^{5,13} Spontaneous regression of this neoplasm is rare and has been reported in approximately 5% of cases.⁹ Imaging techniques, including ultrasound, CT and magnetic resonance imaging (MRI) are used for the diagnosis and evaluation of these lesions.^{5,15,16} The CT is important to assess intra-abdominal lesions; MRI is preferable to assess extremities, head and neck, chest and abdominal wall.⁹ PET-CT has become increasingly important to predict prognosis of these lesions and assess their aggressiveness, as well as to aid in determining the best treatment for these patients.¹⁷ A biopsy is usually required to confirm the diagnosis.^{2,9}

Some aspects are common in both cases, such as the presence of pelvic infection postoperatively, relatively early onset of lesions (before the sixth month postoperatively) and low values of CEA. In most cases in which the presence of a pelvic tumor after surgery is observed, histological investigation is not performed or resection is not possible, and thus, it may be supposed that the occurrence of postoperative DT is higher.

Considering that surgical resection in cases of pelvic lesions is difficult and DT has a high recurrence rate,^{7,11} albeit responsive to pharmacological treatment, histological diagnosis becomes essential to establish the differential diagnosis, as the conduct and prognosis may change completely. Among the drugs used are non-steroidal anti-inflammatory drugs (NSAIDs), antihormonal therapy and chemotherapy.^{11,13,18,19}

Drug therapy aims to induce remission, decrease the size of lesions, their morbidity and recurrence rates. In general, NSAIDs (Sulindac and Indomethacin) and estrogen receptor modulators (usually tamoxifen) are considered first-line drugs to treat DTs. The tumor does not need to have a positive estrogen receptor to respond to tamoxifen. Aromatase inhibitors also appear to have important effect on the disease, but further studies are needed to verify that, as there are currently no randomized studies to prove their efficacy. Approximately half of the DTs show complete or partial response to drug therapy; however, it is difficult to prove whether this is due to treatment or biological behavior of the lesion. Drug therapy can also be used together with surgical treatment as an adjuvant therapy.³

The use of chemotherapy has also shown to be controversial. Recently validated, this treatment modality may be

considered when there are specific indications, usually after failure of the non-cytotoxic treatment in patients with unresectable tumors, patients considered unfit for surgery or those with residual disease.¹³ Moreover, chemotherapy may be used as neoadjuvant therapy to reduce tumor size preoperatively, or as palliative treatment. The more effective and less toxic chemotherapy regimen is the combination of methotrexate and vinblastine or doxorubicin and dacarbazine.³

The use of radiation therapy in the treatment of DT is also controversial. It is not known if there are benefits to using radiotherapy after surgical treatment of lesions with compromised margins, aiming at preventing relapses. However, radiation therapy has been used in patients with unresectable disease or, eventually, as adjuvant therapy after incomplete tumor resection. The recommended dose is 50-60 Gy in 5-7 weeks, with 1.8-2 Gy per fraction.⁴ However, it may be contraindicated in patients previously submitted to neoadjuvant therapy.

In DTs, the definition of optimal treatment is controversial and, considering their rarity, there are few consistent publications in the literature, most with a small number of cases, making it difficult to establish definitive behaviors. The simple observation seems to be a reasonable option for asymptomatic and mildly symptomatic patients, who should be followed through imaging methods. Tumors that remain stable or decrease in size generally do not require any treatment.^{3,11}

Local resection, which has been recommended for a long time for the treatment of DT, has been the treatment of choice for most authors. This resection should be wide and include the margins, as these tumors usually show non-palpable extensions to adjacent organs, hindering the intraoperative assessment of disease extension.^{4,6,8,9,13,18,19} The safety margin should be 1 cm.¹⁵ Although some authors have reported that the involvement of the surgical margin does not change the rate of local recurrence,²⁰ others have clearly shown that the surgical margin status is the most significant single factor in determining the rate of local recurrence in patients treated surgically,⁹ which may be decisive in the evolution of pelvic lesions.

Because this is a rare tumor, its diagnosis is still difficult and little hypothesized. Thus, the possibility of developing a desmoid tumor in the pelvis must then be considered.

Conflicts of interest

The authors declare no conflicts of interest.

REFERENCES

1. Leal RF, Ayrisono MLS, Fagundes JJ, Oliveira PSP, Ângelo SN, Coy CSR, Góes JRN. Recidiva Pélvica de Adenocarcinoma de Reto - Abordagem Cirúrgica. *Rev bras Coloproct*, 2008;28(1): 040-045.
2. Shinagare AB, Ramaya NH, Jagannathan JP, Krajewski KM, Giardino AA, Butrynski JE, et al. A to Z of Desmoid Tumors. *Am J Roentgenol*, 2011;197(6): 1008-1014.
3. Sakorafas GH, Nissotakis C, Peros G. Abdominal Desmoid Tumors. *Surg Oncol*, 2007;16(2): 131-142.
4. Escobar C, Munker R, Thomas JO, Li BD, Burton GV. Update on desmoid tumors. *Ann Oncol*, 2012;23(3): 562-569.

5. Wanjeri JK, Opeya CJO. A massive abdominal wall desmoid tumor occurring in a laparotomy scar: a case report. *World J Surg Oncol*, 2011;9(35): 1-4.
6. Kasper B, Strbel P, Hohenberger. Desmoid tumors: clinical features and treatment options for advanced disease. *Oncologist*, 2011;16(5): 682-693.
7. Bertani E, Chiappa A, Testori A, Mazzarol G, Biffi R, MARTELLA S. Desmoid Tumors of the Anterior Abdominal Wall: Results from a Monocentric Surgical Experience and Review of the Literature. *Ann Surg Oncol*, 2009;16(6): 1642-1649.
8. Spiridakis K, Panagiotakis G, Grigoraki M, Kokinnos I, Papadakis T, Kokkinakis T, et al. Isolated giant mesenteric fibromatosis (intra-abdominal desmoid tumors). Case report. *G Chir*, 2008;29(10): 413-416.
9. Bonvalot S, Desai A, Coppola S, Pechoux CL, Terrier P, Domont J, et al. The treatment of desmoid tumors: a stepwise clinical approach. *Ann Oncol*, 2012;22(10): 158-166.
10. Leal RF, Silva PV, Ayrizono MLS, Fagundes JJ, Amstalden EM, Coy CS. Desmoid tumor in patients with familial adenomatous polyposis. *Arq Gastroenterol*, 2010;47(4): 373-378.
11. Valejo FAM, Tiezzi DG, Nai GA. Tumor desmoide abdomino-pélvico. *Rev Bras Ginecol Obstet*, 2008;31(1): 35-40.
12. Duggal A, Dickinson IC, Sommerville S, Gallie P. The management of extra-abdominal desmoids tumours. *Int Orthop*, 2004;28(4): 252-256.
13. Camargo VP, Keohan ML, Adamo DR, Antonescu CR, Brennan MF, Singer S, et al. *Cancer*, 2010;116(9): 2258-2265.
14. Oguz M, Bedirli A, Gultekin A, Dursun A, Menten BB. *Dis Colon Rectum*, 2006;49(9): 1445-1448.
15. Lee JC, Thomas JM, Phillips S, Fisher C, Moskovic E. *Am J Roentgenol*, 2006;186(1): 247-254.
16. Sinha A, Hansmann A, Bhandari S, Gupta A, Burling D, Rana S, et al. Imaging assessment of desmoid tumours in familial adenomatous polyposis: is state-of-the-art 1.5 T MRI better than 64-MDCT?. *Br J Radiol*, 2012;85(1015): 254-261.
17. Kasper B, Dimitrakopoulou-Strauss A, Strauss LG, Hohenberger P. Positron emission tomography in patients with aggressive fibromatosis/desmoid tumours undergoing therapy with imatinib. *Eur J Nucl Med Mol Imaging*, 2010;37(10): 1876-1882.
18. Melis M, Zager JS, Sondak V. Multimodality Management of Desmoid Tumors: How Important Is a Negative Surgical Margin?. *J Surg Oncol*, 2008;98(8): 594-602.
19. Middleton SB, Phillips RKS. Surgery for Large Intra-Abdominal Desmoid Tumors. *Dis Colon Rectum*, 2000;43(12): 1759-1762.
20. Merchant BN, Lewis JJ, Woodruff JM, Leung DH, Brennan MF. Extremity and trunk desmoid tumors: a multifacial analysis of outcome. *Cancer*, 1999;86(10): 2045-2052.