



Journal of Coloproctology

www.jcol.org.br



Technical Note

Transanal Endoscopic Proctectomy: a new approach to the total excision of the mesorectum[☆]



Carlos Ramon Silveira Mendes^{a,b,c,*}, Luciano Santana de Miranda Ferreira^{a,c},
Ricardo Aguiar Sapucaia^{a,c}, Meyline Andrade Lima^{a,c}, Eduardo Costa Cobas^{a,c},
Sergio Eduardo Alonso Araujo^{c,d,e}

^a Service of Coloproctology, Hospital Santa Izabel, Santa Casa de Misericórdia da Bahia, Salvador, BA, Brazil

^b Residence Program in Coloproctology, Hospital Geral Roberto Santos, Salvador, BA, Brazil

^c Sociedade Brasileira de Coloproctologia, Brazil

^d Department of Gastroenterology, Medicine School, Universidade de São Paulo (USP), São Paulo, SP, Brazil

^e Service of Colon and Rectum Surgery, Hospital das Clínicas, Medicine School, Universidade de São Paulo (USP), São Paulo, SP, Brazil

ARTICLE INFO

Article history:

Received 9 March 2015

Accepted 8 June 2015

Available online 2 July 2015

Keywords:

Minimally invasive surgery

Rectal cancer

Transanal endoscopic microsurgery

Proctectomy

ABSTRACT

Introduction: Colorectal cancer is a serious public health problem. In 1982, Heald managed to reduce mortality by standardizing the total excision of mesorectum. The use of transanal endoscopic microsurgery has emerged to allow resection of rectal tumors as a minimally invasive method. With the association of Transanal Endoscopic Operation with total excision of mesorectum, it was possible to develop a new approach for total excision of mesorectum. **Surgical technique:** The procedure is started by the perineal time with Transanal Endoscopic Operation device; introduction of Transanal Endoscopic Operation system follows, with exposure of the lesion with a circumferential incision at a distance between 2 and 4 cm from distal tumor margin after making a purse string suture to close the rectal stump. Then, dissection is carried out by the posterior portion until reaching the presacral avascular fascia, completing the mesorectal circumferential dissection until the peritoneal reflection. After this step, a laparoscopic procedure is performed with the use of three trocars, with mobilization of splenic flexure and ligation of the inferior mesenteric artery, as well as confection of a protective ileostomy. Then, transanal removal of the surgical specimen is performed, and the procedure goes on with a coloanal anastomosis.

© 2015 Sociedade Brasileira de Coloproctologia. Published by Elsevier Editora Ltda. All rights reserved.

[☆] This work was conducted at Hospital Santa Izabel, Santa Casa de Misericórdia da Bahia, Salvador, BA, Brazil.

* Corresponding author at: Residence Program in Coloproctology, Hospital Geral Roberto Santos, Salvador, BA, Brazil.

E-mail: proctoramom@hotmail.com (C.R.S. Mendes).

<http://dx.doi.org/10.1016/j.jcol.2015.06.003>

2237-9363/© 2015 Sociedade Brasileira de Coloproctologia. Published by Elsevier Editora Ltda. All rights reserved.

Protectomia Endoscópica Transanal (TaETM): Uma nova abordagem para excisão total do mesoreto

R E S U M O

Palavras-chave:

Cirurgia minimamente invasiva
Cancer de reto
Microcirurgia endoscópica transanal
Protectomia

Introdução: O câncer colorretal é um sério problema de saúde pública. Em 1982, Heald conseguiu reduzir a mortalidade com a padronização da excisão total do mesoreto. O uso da Microcirurgia endoscópica transanal surgiu para proporcionar ressecções de tumores de reto como método minimamente invasivo. Com a associação do TEO a ETM foi possível desenvolver uma nova abordagem para ETM.

Técnica cirúrgica: O procedimento é iniciado pelo tempo perineal com o aparelho de TEO. Em seguida o sistema TEO é introduzido, com exposição da lesão por meio de uma incisão circunferencial a cerca de 2 a 4 cm da margem distal do tumor após a confecção de sutura em bolsa com fechamento do coto retal. Em seguida, faz-se dissecação pela porção posterior até a fásia avascular pré-sacral, completando a dissecação circunferencial do mesoreto até atingir a reflexão peritoneal. Após essa etapa, faz-se laparoscópica com utilização de três trocateres, com mobilização do ângulo esplênico e ligadura da artéria mesentérica inferior, e também a confecção de uma ileostomia protetora. O espécime cirúrgico é retirado pela via transanal, e o procedimento tem continuidade com uma anastomose coloanal.

© 2015 Sociedade Brasileira de Coloproctologia. Publicado por Elsevier Editora Ltda.
Todos os direitos reservados.

Introduction

Colorectal cancer (CRC) is a serious health problem worldwide. It is known that 25% of CRC cases are located in the rectum.^{1,2}

In 1982, Heald et al. proposed a standardization of total excision of mesorectum (TEM), whose initial results were surprising in terms of local recurrence.³ Through standardization of the technique, these authors managed to reduce local recurrence to less than 10% and increase the overall survival for 80%. The transabdominal-transanal (TATA) technique described by Marks^{4,5} improved the quality of life for patients who would be submitted to abdominoperineal amputation, enabling its realization by laparoscopy.

The transanal endoscopic microsurgery (TEM) was introduced in 1983 by G. Buess as a minimally invasive technique for the resection of adenomas and early rectal carcinomas.⁶⁻⁹

Using TATA technique, performing abdominal time by laparoscopy and perineal time with Transanal Endoscopic Operation (TEO; Storz, Tuttlingen, Germany) system, Transanal Endoscopic Proctectomy (TAEP) was established.

The quality of TEM with lymph node resection in pursuit of a single objective which is the RO resection, has promoting the search for new tactics and techniques. Obese patients with narrow pelvis with a fatty mesorectum which has a fibrosis plane mainly with a big prostate have hindered the resection by laparoscopy.

TAEP emerged as an alternative for difficult cases of rectal adenocarcinoma.

This is a technique that is performed by transanal route; in it, one circumferential rectal incision with dissection of the whole rectum together with the mesorectum to the abdominal cavity is carried out. The abdominal period is developed

by laparoscopy to release the splenic flexure and by inferior mesenteric artery and vein ligation.

Surgical technique

In February 2014, one of the first cases in Brazil of TAEP for treatment of rectal tumor was conducted at Hospital Santa Izabel, Salvador – Bahia. Preoperatively, the patient filled and signed a free and informed consent form and was instructed regarding the procedure.

To perform the proctectomy, some preoperative measures were implemented, for example, mechanical bowel preparation and prophylactic antibiotic therapy during anesthetic induction.

Following general anesthesia, the patient is placed in lithotomy position.

The procedure is initiated by the perineal time, where the TEO system will be used. Next, digital expansion for introduction of TEO system, exposure of pectineal line with a circumferential incision 2–4 cm from the distal tumor margin, and a purse string suture with closure of the rectal stump with vicryl 3.0 is carried out (Fig. 1). Then, a circumferential demarcation of the rectum with the use of electrocautery is performed. Using a Harmonic scissors (Ethicon Endo-Surgery) the surgeon keep doing the dissection through the posterior portion to the avascular presacral fascia, completing the circumferential dissection through the mesorectum to reach the peritoneal reflection. After this step is completed, a laparoscopic procedure with an inventory of the cavity is carried out, with the use of three trocars (a 10-mm trocar in the umbilical region, another 11-mm trocar in the region where the ileostomy will be built, and a 5-mm trocar in the right flank). Then, the surgeon proceeds with mobilization of the splenic flexure and ligation of the inferior mesenteric artery, in

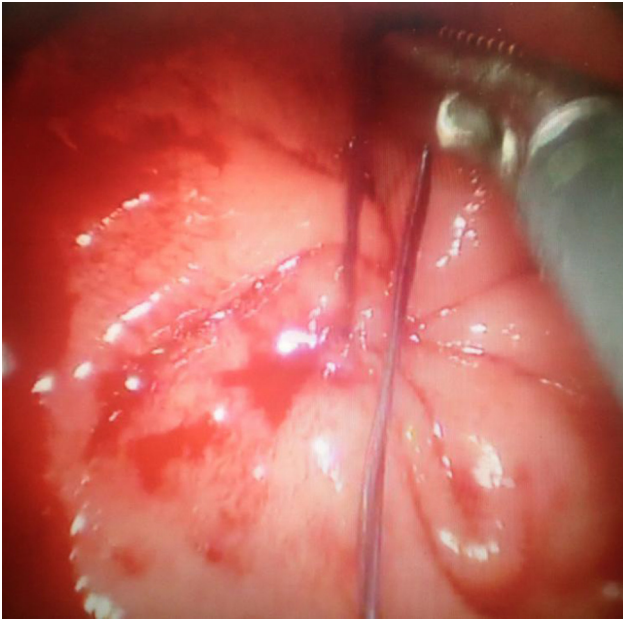


Fig. 1 – Closing of rectal lumen.

addition to making a protective ileostomy. The surgical specimen is removed (Fig. 2) by transanal route, and the procedure goes on with a manual coloanal anastomosis (Figs. 3 and 4).

Experimental and cadaveric models

The TATA resection technique was first described by Marks, as an alternative to abdominoperineal resection with permanent colostomy in patients with low rectal cancer. In 2010, Marks described his experience with TATA laparoscopically, reporting a case series of 79 patients with no perioperative mortality

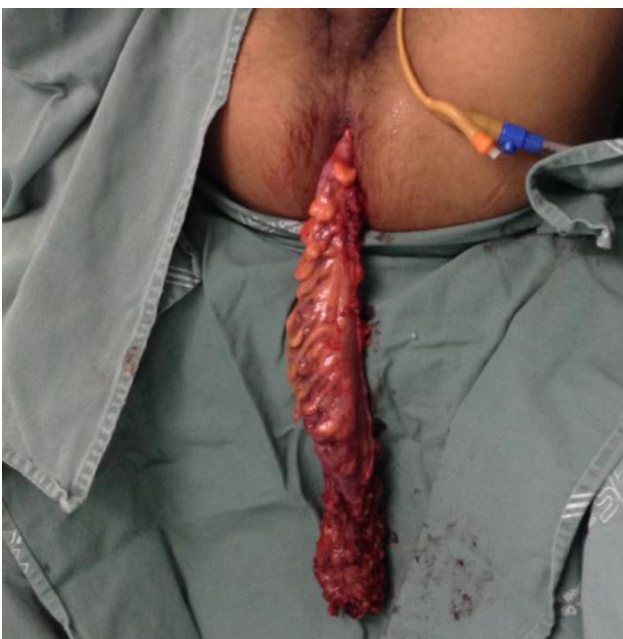

Fig. 2 – Removal of the surgical specimen.

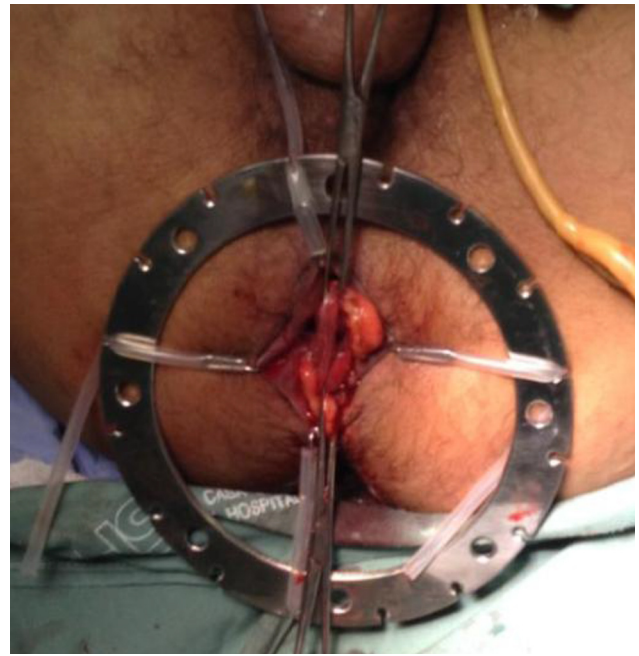


Fig. 3 – Coloanal anastomosis.

and low conversion (2.5%) and recurrence (2.5%) rates.⁴ With the advent of natural orifice endoscopic surgery (NOTES) and with the use of minimally invasive techniques for transanal tumor resection (TEM), the technique has been refined.

From that moment on, a demonstration of safety and applicability of TAEF started off, with the help of studies in pigs and human corpses.¹⁰⁻¹⁴

In 2010, Patricia¹⁰ published her experience in pigs using the rectoscope to perform TEM.

In 2013, McLemore held TAEF using minimally invasive transanal surgery (TAMIS) in a series of 5 human corpses (all male), with a surgical time of 200 (128-249) min. In the perianal time, this author used GelPOINT-Path; in the abdominal

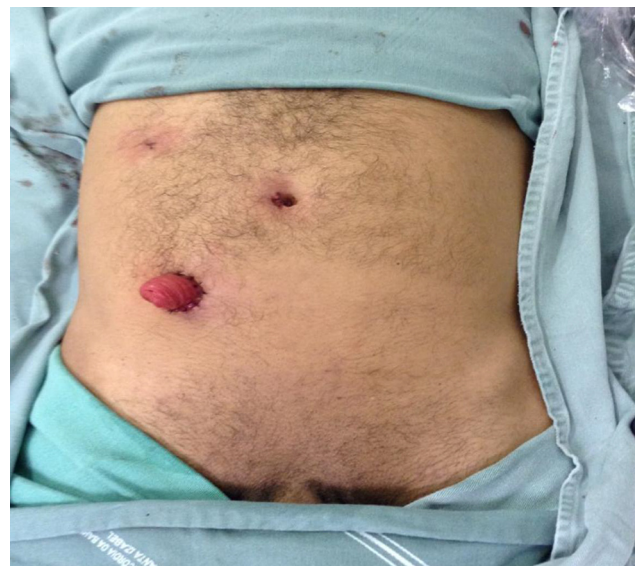

Fig. 4 – Final appearance.

access, the author used a GelPOINT in the region of the making of ileostomy and an accessory 5-mm trocar in the left inguinal region (site of pelvic drainage). As a complication, an injury to the splenic capsule occurred during surgery.¹⁵⁻¹⁸

In the same year, Telen et al.¹⁹ published the largest series in cadavers, with 32 cases and mean operative time of 5.1 h. In all specimens, it was possible to resect the intact rectum.

With the advent of robotics, new studies have been published, with robot use for access to the perineal time, in association with a single-portal device. The first report of this model was published by Atallah; this author conducted four days of experiments, showing that the use of the robot is feasible and safe; however, the cost of its use is still very high.^{20,21}

Clinical series

The first report of TAEP with the use of TEO platform was described in 2010 by Patricia et al.²² The patient was a woman of 76 years with adenocarcinoma of the rectum T2N2. The patient underwent a TAEP with surgical time of 4 h and 30 min. Abdominal access was performed through three portals (one 10-mm portal in the umbilical region, one 5-mm portal in the right flank, and one 2-mm portal in the left inguinal region). Coloanal manual anastomosis was performed, and the specimen was removed by transanal route; a protective ileostomy was made.

The post-surgical results revealed that the patient was with a T1N0 adenocarcinoma with 23 disease-free lymph nodes.

In 2012, the first series of cases in humans was published, with a total of 5 patients (3 males). The mean operative time was 175 (160-194) min, the patients had stage II or III adenocarcinoma. There was one intraoperative complication (pneumo-retroperitoneum) that made it difficult the surgical technique. Postoperatively, one prolonged ileus case and another case of pelvic abscess (which was externally drained) were reported.

In 2013, Lacy published his series of 20 patients with mean BMI of 25.3 and with adenoma and rectal adenocarcinoma. The operative time was 234 (150-325) min. There were no intraoperative complications. Postoperatively, a case of urinary retention, and also prolonged ileus, was reported; and one patient required readmission due to severe dehydration.

The largest series in humans was reported by Rouanet, with 30 cases. All patients were male. The criteria for use of TAEP technique were: adenocarcinoma carrier, presenting a thick mesorectum, or high body mass index (BMI), or tumor fibrosis, or a narrow pelvis (bi-tuberal distance <10 cm, bi-ischial distance <12 cm). The mean operative time was 304 (170-432) min. In the early series, two cases of urethral injury and a case of thromboembolism were reported. Subsequently, severe sepsis and one case of intestinal obstruction were diagnosed. The Quirke classification was used to analyze the mesorectum, and all patients were classified as grade 3.

Discussion

During laparoscopy, when TEM, recommended by Heald, is carried out, in some cases the surgeon has struggled to get an

upstanding specimen without causing harm to the mesorectum.

These difficulties arise mainly in male patients and also in obese patients.

Rouanet¹¹ after using TAEP, advocated some indications for its proper execution: being an adenocarcinoma carrier, and to meet one of the following criteria: thick mesorectum, high BMI, tumor fibrosis, a narrow pelvis (bi-tuberal distance <10 cm, bi-ischial distance <12 cm).

With these criteria, a upstanding piece of mesorectum was obtained. This suggests that this surgical approach is the best for these cases.

Today, for this procedure there are several ways to a perineal approach with TEO and TAMIS.^{23,24} In these studies, their authors proved that the use of the several tools equipment found in the market to carry out TAMIS is viable, and this is true also for the equipment for TEO.

The laparoscopic abdominal time has proven to be straightforward; one needs only to do the ligation of the inferior mesenteric vessels, besides the release of the splenic angle of the colon; to this end, one can resort to minilaparoscopy, to single portal technique, or even to multiportals. The complications so far encountered were minor, and all of them could be resolved. The most common complication was urethral injury, especially in the initial phase of the procedures, because of the difficulty in recognizing a new dissection plane.

When examining the surgical specimen, it was possible to obtain a wholesome piece in all cases, as recommended by Heald.

New technologies are emerging; and when they are well applied, should be used for the best treatment of the patient. And new studies are emerging, and new experiences have been tried, thus resulting in greater certainty in the application of TAEP techniques.

Conflicts of interest

The authors declare no conflicts of interest.

REFERENCES

1. Landis SH, Murray T, Bolden S, Wingo P. Cancer statistics. *CA Cancer J Clin.* 1999;49(1):8-31.
2. Mendes CRS, Sapucaia RA, Ferreira LSM. Surgical treatment of colorectal cancer: three year historical series of a health service in Salvador, Bahia. *Rev Bras Coloproctol.* 2010;30(4):440-3.
3. Heald RJ, Husband EM, Ryall PD. The mesorectum in rectal cancer surgery – the clue to pelvic recurrence? *Br J Surg.* 1982;69(10):613-6.
4. Marks GJ, Marks JH, Mohiuddin M, Brady L. Radical sphincter-preserving surgery with coloanal anastomosis following high-dose external irradiation for the very low lying rectal cancer. *Recent Results Cancer Res.* 1998;146:161-74.
5. Marks J, Mizrahi B, Dalane S, Nweze I, Marks G. Laparoscopic transanal abdominal transanal resection with sphincter preservation for rectal cancer in the distal 3 cm of the rectum after neoadjuvant therapy. *Surg Endosc.* 2010;24:2700-7.

6. Araujo SEA. Transanal endoscopic microsurgery: a Brazilian initial experience in private practice. *Hepato-Gastroenterology*. 2012;59:118.
7. Moore JS, Cataldo PA, Osler T, Hyman NH. Transanal endoscopic microsurgery is more effective than traditional transanal excision for resection of rectal masses. *Dis Colon Rectum*. 2008;51:1026-31.
8. Moraes RS, Malafaia O, Telles JEQ, Trippia MA, Buess GF, Coelho JCU. Microcirurgia endoscópica transanal no tratamento dos tumores do reto: estudo prospectivo em 50 pacientes. *Arq Gastroenterol*. 2008;45(4):268-74.
9. Trunzo JA, Delaney CP. Natural orifice proctectomy using a transanal endoscopic microsurgical technique in a porcine model. *Surg Innov*. 2010;17(1):48-52.
10. Sylla P, Sohn DK, Cizqiner S, Konuk Y, Turner BG, Gee DW, et al. Survival study of natural orifice transluminal endoscopic surgery for rectosigmoid resection using transanal endoscopic microsurgery with or without transgastric endoscopic assistance in swine model. *Surg Endosc*. 2010;24(8):2022-30.
11. Rouanet P, Mourregot A, Azar CC, Carrere S, Gutowski M, Quenet F, et al. Transanal endoscopic proctectomy: an innovative procedure for difficult resection of rectal tumors in men with narrow pelvis. *Dis Colon Rectum*. 2013;56:408-15.
12. McLemore EC, Coker AM, Devaraj B, Chakedis J, Maawy A, Inui T, et al. TAMIS-assisted laparoscopic low anterior resection with total mesorectal excision in a cadaveric series. *Surg Endosc*. 2013;27(9):3478-84.
13. de Lacy AM, Rattner DW, Adelsdorfer C, Tasende MM, Fernández M, Delgado S, et al. Transanal natural orifice transluminal endoscopic surgery (NOTES) rectal resection: "down-to-up" total mesorectal excision (TME) short-term outcomes in the first 20 cases. *Surg Endosc*. 2013;27(9):3165-72.
14. Nahas SC, Nahas CSR, Marques CFS, Dias AR, Pollara WM, Ceconello I. Transanal endoscopic microsurgery (TEM): a minimally invasive procedure for treatment of selected rectal neoplasms. *Arq Bras Cir Dig*. 2010;23(1):35-9.
15. Velthuis S, van den Boezem PB, van der Peet DL, Cuesta MA, Sietses C. Feasibility study of transanal total mesorectal excision. *Br J Surg*. 2013;100(6):828-31.
16. Sylla P, Willingham FF, Sohn DK, Gee D, Brugge WR, Rattner DW. NOTES rectosigmoid resection using transanal endoscopic microsurgery (TEM) with transgastric endoscopic assistance: a pilot study in swine. *J Gastrointest Surg*. 2008;12(10):1717-23.
17. Han Y, He YG, Zhang HB, Lv KZ, Zhang YJ, Lin MB, et al. Total laparoscopic sigmoid and rectal surgery in combination with transanal endoscopic microsurgery: a preliminary evaluation in China. *Surg Endosc*. 2013;27:518-24.
18. Bhattacharjee HK, Kirschniak A, Storz P, Wilhelm P, Kunert W. Transanal endoscopic microsurgery-based transanal access for colorectal surgery: experience on human cadavers. *J Laparoendosc Adv Surg Tech*. 2011;21:835-40.
19. Telen DA, Berger DL, Bordelanou LG, Rattner DW, Sylla P. Update on transanal NOTES for rectal cancer: transitioning to human trials. *Minim Invasive Surg*. 2012;2012:287613.
20. Atallah SB, Albert MR, Debeche-Adams TH, Larach SW. Robotic transanal minimally invasive surgery in a cadaveric model. *Tech Coloproctol*. 2011;15:461-4.
21. Araujo SE, Crawahaw B, Mendes CR, Delaney CP. Transanal total mesorectal excision: a systematic review of the experimental and clinical evidence. *Tech Coloproctol*. 2015;19(2):69-82.
22. Sylla P, Rattner DW, Delgado S, Lacy AM. Notes transanal rectal cancer resection using transanal endoscopic microsurgery and laparoscopic assistance. *Surg Endosc*. 2010;24:1205-10.
23. Mendes CRS, Ferreira LSM, Sapucaia RA, Lima MA, Araujo SEA, Silva MJM, et al. Transanal endoscopic microsurgery (TEM): initial experience. *J Coloproctol*. 2012;32(4):411-5.
24. Mendes CRS, Ferreira LSM, Sapucaia RA, Lima MA, Araujo SEA. Transanal minimally invasive surgery (TAMIS): technique and results from an initial experience. *J Coloproctol*. 2013;33(4):191-5.