



## Original Article

# Comparative evaluation of healing response between colo-colic invagination anastomosis and single-layer running suture. Experimental study in dogs



Miguel Augusto Arcoverde Nogueira<sup>a</sup>, Francisco Sérgio Pinheiro Regadas<sup>b,\*</sup>,  
Carlos Renato Sales Bezerra<sup>a,c,d</sup>, Wellington Ribeiro Figueiredo<sup>d,e</sup>,  
Erbert Portela Martins Filho<sup>e</sup>

<sup>a</sup> Universidade Estadual do Piauí (UESPI), Escola de Medicina, Teresina, PI, Brazil

<sup>b</sup> Universidade Federal do Ceará (UFC), Escola de Medicina, Fortaleza, CE, Brazil

<sup>c</sup> Programa de Cirurgia Abdominal, Universidade Estadual do Piauí (UESPI), Teresina, PI, Brazil

<sup>d</sup> Universidade Federal do Ceará (UFC), Fortaleza, CE, Brazil

<sup>e</sup> Faculdade Integral Diferencial (FacidDevry), Teresina, PI, Brazil

## ARTICLE INFO

## Article history:

Received 18 March 2016

Accepted 13 April 2016

Available online 27 May 2016

## Keywords:

Anastomosis

Wound Healing

Colon

## ABSTRACT

**Objective:** Evaluate healing response of colo-colic anastomosis by invagination vs. single-layer suture.

**Methods:** Sixty dogs were randomly distributed in two groups and anastomosed with single-layer suture (G-I, control) or by invagination and cardinal sutures (G-II, study). In the end, the animals were euthanized (10 from each group on POD7 and 20 on POD21) and the anastomosed segment was retrieved for histology and immunohistochemistry. Parameters included body weight, adhesions, edema, vasoproliferation, type I and III collagen, myeloperoxidase and nitric oxide. Findings were analyzed with Student's t test and the Mann-Whitney test.

**Results:** No animal died prior to euthanasia. The groups were similar with regard to all parameters: median weight 10.86 kg (G-I) and 9.98 kg (G-II) on POD7 ( $p=0.41$ ) and 11.86 kg (G-I) and 11.55 kg (G-II) on POD21 ( $p=0.71$ ); abdominal adhesions ( $p=0.7383$  POD7;  $p=0.5685$  POD21), level of edema ( $p=0.3006$  POD7;  $p=0.7990$  POD21), vasoproliferation ( $p=0.1191$  POD7;  $p=0.0758$  POD21), type I collagen ( $p=0.4591$  POD7;  $p=0.3357$  POD21), type III collagen ( $p=0.2166$  POD7;  $p=0.2712$  POD21), nitric oxide ( $p=0.3980$  POD7;  $p=0.4796$  POD21) and myeloperoxidase ( $p=0.580$  POD7;  $p=0.755$  POD21).

**Conclusion:** No significant difference in healing response was observed between the two anastomosis techniques (single-layer suture and invagination).

© 2016 Sociedade Brasileira de Coloproctologia. Published by Elsevier Editora Ltda. This is an open access article under the CC BY-NC-ND license (<http://creativecommons.org/licenses/by-nc-nd/4.0/>).

\* Corresponding author.

E-mail: [sregadas@hospitalsaocarlos.com.br](mailto:sregadas@hospitalsaocarlos.com.br) (F.S.P. Regadas).

<http://dx.doi.org/10.1016/j.jcol.2016.04.008>

2237-9363/© 2016 Sociedade Brasileira de Coloproctologia. Published by Elsevier Editora Ltda. This is an open access article under the CC BY-NC-ND license (<http://creativecommons.org/licenses/by-nc-nd/4.0/>).

## Avaliação comparativa da resposta cicatricial entre anastomose colóclica por invaginação e sutura contínua em plano único. Estudo experimental em cães

### R E S U M O

#### Palavras-chave:

Anastomose  
Cicatrização de ferida  
Cólon

**Objetivo:** Avaliar a resposta cicatricial da anastomose colóclica por invaginação *versus* sutura em plano único.

**Métodos:** Sessenta cães foram randomicamente distribuídos em dois grupos e anastomosados com sutura em plano único (G-I, controle) ou por invaginação e suturas cardinais (G-II, estudo). Ao final, os animais foram submetidos à eutanásia (10 de cada grupo no 7º dia do pós-operatório [DPO7] e 20 em DPO21) e o segmento anastomosado foi recuperado para estudos histológicos e imunistoquímicos. Os parâmetros foram: peso corpóreo, aderências, edema, vasoproliferação, colágeno dos tipos I e III, mieloperoxidase e óxido nítrico. Os achados foram analisados com os testes t de Student e de Mann-Whitney.

**Resultados:** Não ocorreram óbitos antes da eutanásia. Os grupos eram semelhantes com relação a todos os parâmetros considerados: peso mediano 10,86 Kg (G-I) e 9,98 Kg (G-II) em DPO7 ( $p=0,41$ ) e 11,86 Kg (G-I) e 11,55 Kg (G-II) em DPO21 ( $p=0,71$ ); aderências abdominais ( $p=0,7383$  DPO7;  $p=0,5685$  DPO21), nível de edema ( $p=0,3006$  DPO7;  $p=0,7990$  DPO21), vasoproliferação ( $p=0,1191$  DPO7;  $p=0,0758$  DPO21), colágeno tipo I ( $p=0,4591$  DPO7;  $p=0,3357$  DPO21), colágeno tipo III ( $p=0,2166$  DPO7;  $p=0,2712$  DPO21), óxido nítrico ( $p=0,3980$  DPO7;  $p=0,4796$  DPO21) e mieloperoxidase ( $p=0,580$  DPO7;  $p=0,755$  DPO21).

**Conclusão:** Não foi observada diferença significativa na resposta cicatricial entre as duas técnicas de anastomose (sutura em plano único e invaginação).

© 2016 Sociedade Brasileira de Coloproctologia. Publicado por Elsevier Editora Ltda. Este é um artigo Open Access sob uma licença CC BY-NC-ND (<http://creativecommons.org/licenses/by-nc-nd/4.0/>).

## Introduction

Colorectal surgery is one of the modalities of digestive system surgery most strongly associated with postoperative complications. Unsurprisingly, Hippocrates (460–377 BC) considered it unfeasible. In the sixteenth century, morbidity rates were still prohibitive, but prognosis improved considerably in the twentieth century with the advent of antibiotic therapy.<sup>1,2</sup>

Much effort has been put into improving the methods of colorectal anastomosis in order to reduce complications. Advances include new types of thread which induce less tissue inflammation, devices such as staplers and entirely novel surgical techniques. These advances have significantly reduced the rate of anastomotic dehiscence. Nevertheless, dehiscence remains an important risk factor for postoperative mortality in colorectal surgery.<sup>2-5</sup>

Anastomosis by invagination was first performed by Sonnenburg in the late nineteenth century,<sup>6</sup> but the case (ileocolic anastomosis) was not described in detail. More recently, a technique of gastroesophageal anastomosis based on the invagination of gastrointestinal tract segments was described in a patient with megaesophagus submitted to esophagectomy.<sup>7</sup>

Anastomosis by colo-colic invagination was recently evaluated in dogs with regard to inflammatory and healing parameters to determine the advantage of bowel preparation.<sup>8</sup>

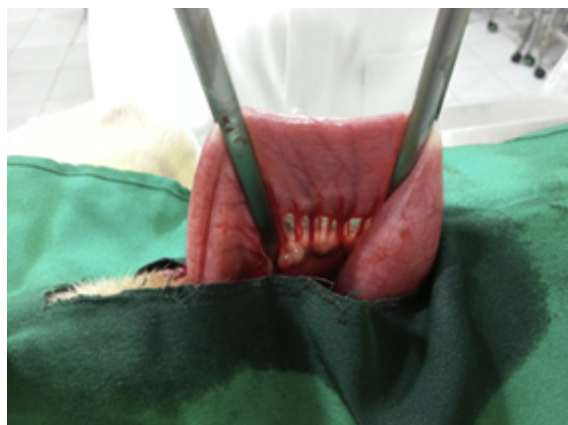The purpose of this experimental study is to evaluate the healing response of colo-colic invagination anastomosis comparing with single-layer running suture.

## Materials and methods

Sixty healthy female mongrel dogs (*Canis familiaris*) weighing 8.0–19.5 kg were used in this study. The animals were supplied by the municipal dog pound of Teresina (Piauí, Brazil) and quarantined for 15 days at a private veterinary clinic affiliated with the School of Medical Sciences of Piauí State University (UESPI). The animals were kept in separate cages, vaccinated against rabies and evaluated at baseline and perioperatively by a Veterinarian. After the quarantine, the animals were randomly distributed (Microsoft Excel®) in two groups of 30 animals each. In Group I (Control), the animals were submitted to end-to-end colo-colic anastomosis with single-layer running suture using polypropylene thread size 000 and in Group II (Study), the animals were submitted to end-to-end colo-colic anastomosis by invagination (introducing the proximal segment into the distal lumen), secured by four cardinal sutures using polypropylene thread size 000.

### Surgical technique

All the animals from both groups were submitted to preoperative bowel preparation (Rectal Enema) with 100 mL glycerin solution (12%) using a 14-French rectal catheter each 8 h during the 24 h before the procedure. It was kept a liquid diet (without residues) on the procedure's day. Prophylactic antibiotic was done (Penicillin 40,000 U/kg i.m. and Metronidazole 30 mg/kg i.v.) before the anesthesia and kept each



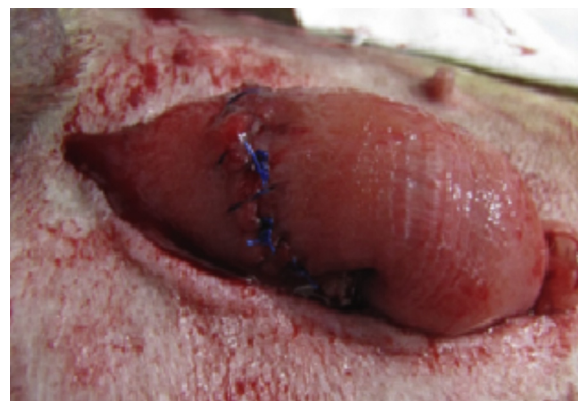**Fig. 1 – Colon identified at 20 cm from the anal margin and secured with a straight intestinal clamp.**

6 and 12 h respectively during the first 24 h after the procedure. Meloxicam (0.2 mg/kg s.c.) was done every 12 h for 3 days and Tramadol (2 mg/kg i.m.) was administered preoperatively and at each 4 h during the first 24 h after the procedure. Following anesthesia with propofol (5 mg/kg i.v.) and orotracheal intubation, the animals were placed on mechanical ventilation with isoflurane in a semi-closed circuit. The anesthetized animals were submitted to digital rectal examination to evaluate the bowel preparation according to the classification of O'Dwyer et al.<sup>9</sup> (excellent=no feces; good=minimal fecal residue; acceptable=liquid feces; soiled=solid feces). The grading was confirmed during the surgical procedure. Subsequently, the animals were placed in dorsal decubitus and the laparotomy was performed through a transumbilical, median incision measuring approximately 12 cm. The abdominal cavity was inspected to rule out hematogenic or gynecological disorders. Initially, the descending colon was identified at 20 cm from the anal margin and secured with a straight intestinal clamp (Fig. 1).

A linear transverse colotomy was performed using scissors. The animals from Group I were then submitted to colo-colic anastomosis, either with a single-layer running suture using polypropylene thread size 000 (Fig. 2) or by invagination in Group II, approximately 3 cm from the dissected mesocolon, inserting the proximal segment into the distal lumen and secured by four cardinal sutures using polypropylene thread size 000, involving all intestinal layers (Fig. 3). After the first postoperative evacuation, the animals were allowed access to standard feed and water *ad libitum*.

At the end of the study period, the animals were submitted to a second laparotomy to excise the anastomosed colon segment for histological and immunohistochemical analysis. The study parameters included body weight, presence of abdominal adhesions, edema, vasoproliferation, type I and III collagen, nitric oxide and myeloperoxidase. Subsequently, the animals were euthanized with 20% potassium chloride (i.v.) under anesthesia with ketamine. Ten from each group were euthanized on the 7th post-operative day (POD7) and twenty on the 21st post-operative day (POD21).

The findings were statistically analyzed using Student's t test (non-paired samples, parametric data) and the



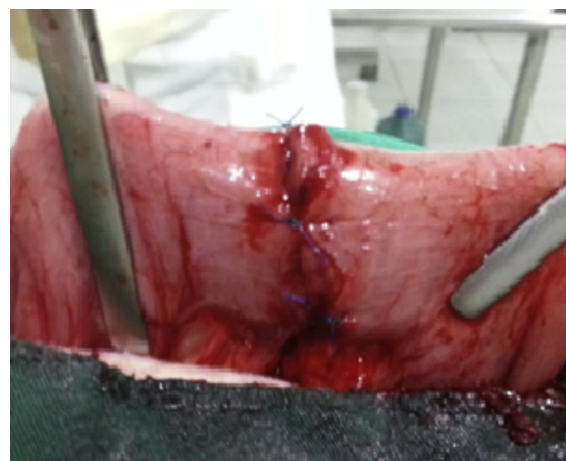
**Fig. 2 – The animals from Group I, submitted to colo-colic anastomosis with a single-layer running suture using polypropylene 000.**

Mann-Whitney test (non-parametric data). The level of statistical significance was set at 5% ( $p < 0.05$ ).

## Results

Body weight was statistically similar in both groups. The median weight was 10.86 kg and 9.98 kg in Groups I, II respectively on POD7 ( $p=0.41$ ) and 11.86 kg, 11.55 kg on POD21 ( $p=0.71$ ).

The abdominal adhesions incidence was statistically similar in both groups on POD7 ( $p=0.7383$ ) and POD21 ( $p=0.5685$ ), as well as for the levels of edema on POD7 ( $p=0.3006$ ); on POD21 ( $p=0.7990$ ), vasoproliferation on POD7 ( $p=0.1191$ ); on POD21 ( $p=0.0758$ ), type I collagen on POD7 ( $p=0.4591$ ); on POD21 ( $p=0.3357$ ), type III collagen on POD7 ( $p=0.2166$ ); on POD21 ( $p=0.2712$ ) and nitric oxide on POD7 ( $p=0.3980$ ) and POD21 ( $p=0.4796$ ). There wasn't also significant statistical difference of the myeloperoxidase levels between both groups on POD7 ( $p=0.580$ ) and POD21 ( $p=0.755$ ).



**Fig. 3 – The animals from Group II secured by four cardinal sutures using polypropylene thread size 000, involving all intestinal layers.**

## Discussion

There are many studies discussing about the surgical techniques currently used to perform colorectal anastomosis. All types of suture (single-layered, double-layered, running, interrupted) and the different types of thread used trying to reduce the adherence rates.<sup>10-12</sup> In this experimental study, it was used the invagination technique developed by Luchesi<sup>13</sup> which is performed by invaginating the transected proximal wall into the lumen of the distal colon and comparing with single-layer running suture anastomosis regarding to the healing response. None experimental study was found in literature using the inflammatory and healing markers to evaluate colocolic invagination anastomosis.

There wasn't statistical significant difference between the animals from both groups regarding the frequency of edema at the anastomosis site on POD 7 and POD21. Most animals from both groups presented very mild edema on POD7 and none on POD21 as previously demonstrated in another study<sup>14,15</sup> also demonstrated that edema tends to subside after POD14. So, based on the findings in this study, the surgical technique did not change the frequency and intensity of edema at the anastomosis site.

According with previous studies,<sup>8,16</sup> a good vascularization plays an important role on the viability of intestinal anastomosis. And in this study, there wasn't a significant statistical difference between both groups with regard to vasoproliferation on POD7 and POD21, suggesting that the surgical technique had no influence on the vascularization intensity, according with the findings previously demonstrated in another study.<sup>8</sup>

Moore et al.<sup>6</sup> demonstrated that anastomosis invaginating the proximal segment into the lumen of the distal colon does not increase the risk of contamination of the perianastomotic tissues and peritoneum. In this study, the groups did not differ significantly with regard the presence of abdominal adhesions according with another study.<sup>12</sup> Likewise, the amount of type I and III collagen at the anastomosis site on POD7 and POD21 was not significantly affected by the surgical technique used, as previously supported by Bezerra et al.<sup>8</sup>

Large amounts of iNOS are usually found inside macrophages up to one month after surgery.<sup>17</sup> Moreover, increased levels of nitric oxide may be observed in endothelial cells in the anastomoses area, even in the absence of macrophages.<sup>18</sup> Using immunohistochemistry exam, it was determined the levels of nitric oxide and myeloperoxidase in both groups of animals on POD7 and PODO21 but it was not found any significant difference between them, suggesting that the surgical technique has no measurable effect on these parameters as well.<sup>8</sup>

## Conclusion

It was not demonstrated in this experimental study any significant difference on healing response between colocolic invagination anastomosis with single-layer running suture.

## Conflicts of interest

The authors declare no conflicts of interest.

## REFERENCES

- Güenaga KF, Matos D, Wille-Jørgensen P. Preoperative mechanical bowel preparation in elective colorectal surgery. An update of systematic review of the literature and meta-analysis. *J Coloproctol*. 2012;32:7-17.
- Lins-Neto MAF, Leão MJR, Alves EC, Fontan AJ. Preparo Mecânico dos Cólon é uma Rotina Necessária. *Arq Bras Cir Dig*. 2012;25:25-8.
- Oliveira ALA, Jamel N, Lacombe DP, Gonçalves MD, Abílio EJ, Manso JEF, et al. Use of intraluminal protection in colonic anastomosis in dogs. *Acta Cir Bras*. 2007;22:57-62.
- Ricciardi R, Schoetz DJ, Read TE, Hall JF, Marcello PW, Roberts PL. Anastomotic leak testing after colorectal resection. *Arch Surg*. 2009;40:7-11.
- Torres Neto JR, Fakhouri R, Menezes MVA, Rrudente ACL, Monteiro JTS, Feitosa VLC. Estudo Histomorfométrico de Anastomoses Primárias de Cólon em Coelhos, com e sem Preparo Intestinal. *Rev bras Coloproct*. 2007;27:384-90.
- Moore WI, Forrest-Hamilton J. The Maylard-Sonnenburg method of intestinal anastomosis. *Brit Med J*. 1953;2:1407.
- Aquino JLB, Reis Neto JA, Murano CLPM, Camargo JGT. Tratamento do megaesôfago pela mucosectomia com conservação da túnica muscular esofágica por via cervicoabdominal. *Rev Col Bras Cir*. 2000;27:106-13.
- Bezerra CRS, Regadas FSP, Figueiredo WR, Nogueira MAA, Sousa PC, Leite CMGS, et al. Role of preoperative retrograde enema on inflammatory and healing parameters in colonic anastomosis: experimental study in dogs. *J Coloproctol*. 2014;34:193-7.
- O'Dwyer PJ, Conway MC, McDermott EW, O'Higgins NJ. Effect of mechanical bowel preparation on anastomotic integrity following low anterior resection in dog. *Br J Surg*. 1989;76:756-8.
- Halsted WS. Circular suture of the intestine: an experimental study. *Am J Med Sci*. 1887;94:436-64.
- Linn B, Cecil F, Conly P, Canaday WR Jr, Wolcott MW. Intestinal anastomosis by invagination and gluing. *Am J Surg*. 1966;111:197-9.
- Sousa PC [Dissertação de Mestrado - Universidade Federal do Ceará] Avaliação comparativa entre anastomoses colo-cólicas com sutura manual contínua e invaginação colo-cólica. estudo experimental em cães. Fortaleza; 2013. p. 45.
- Luchesi SMAD. Anastomose colo-cólica por invaginação da submucosa-mucosa cranial na seromuscular caudal: Estudo não experimental cão. *Acta Cir Bras*. 1987;2:14-8.
- Goes ACAM, Rodrigues LV, Meneses DB, Granjeiro MPF, Cavalcante ARMS. Análise histológica da cicatrização da anastomose colônica, em ratos, sob ação de enema de Aroeira-do-sertão (*Myracrodruon urundeuva* fr. all.) a 10%. *Acta Cir Bras*. 2005;20:144-53.
- Priolli DG, Margarido NF, Martinez, Rotta CM, Stephani SM. Edema quantification by computerized morphometry as na evaluation parameter for the resistance of colon anastomoses. *Acta Cir Bras*. 2003;18:398-405.
- Medeiros AC, Chacon DA, Aires Neto T, Lima FP, Trindade MC. Efeitos das vitaminas A e C em anastomoses intestinais de

- 
- ratos tratados com corticosteróides. *Acta Cir Bras.* 2003;18:28-32.
17. Puttini SMB [Dissertação de Mestrado – Universidade Federal de Brasília] Avaliação da Resposta Inflamatória Desencadeada pelas Telas de Polipropileno e Politetrafluoretileno Expandido Implantado no Espaço Intraperitoneal. Estudo Experimental em Camundongos. Brasília; 2006. p. 79.
18. Eiserich JP, Baldus S, Brennan ML, Ma W, Zhang C, Tousson A, et al. Myeloperoxidase, a leukocyte-derived vascular oxidase. *Science.* 2002;296:2391-4.