



## Case report

# Laparoscopic hemicolectomy for a patient with situs inversus totalis and colorectal cancer



**Maria Labalde Martínez\***, **Pilar Veguillas Redondo**, **Jorge Carlin Gatica**,  
**Jose Manuel Ramia Angel**

Hospital Universitario de Guadalajara, Departamento de Cirugía, Guadalajara, Spain

### ARTICLE INFO

#### Article history:

Received 6 February 2017

Accepted 28 February 2017

Available online 17 March 2017

#### Keywords:

Colorectal cancer

Situs inversus totalis

Laparoscopic surgery

Laparoscopic hemicolectomy

Congenital anomaly

### ABSTRACT

Situs inversus totalis is a congenital anatomic anomaly characterized by a complete inversion of thoracic and abdominal organs. We present a case of a 67 year-old patient diagnosed with situs inversus totalis in his childhood who was referred for a two-month history of hematoquezia. Ascending colon cancer where found and he underwent a laparoscopic hemicolectomy with radical lymphadenectomy. An exhaustive preoperative study and a detailed planning of laparoscopic surgery including positions of operator and assistants and trocar sites have been performed to be aware of anatomic challenges. The operating time was 120 min and blood loss was minimal. Histologic examination showed a well-differentiated adenocarcinoma with serosal invasion and without lymph nodes metastasis (pT3N0). The patient was discharged on postoperative 6th day without complications. Laparoscopic surgery for colon cancer in patients with situs inversus totalis could be more difficult nevertheless a safe and feasible procedure should be performed successfully.

© 2017 Sociedade Brasileira de Coloproctologia. Published by Elsevier Editora Ltda. This is an open access article under the CC BY-NC-ND license (<http://creativecommons.org/licenses/by-nc-nd/4.0/>).

### Colectomia laparoscópica para um paciente com situs inversus totalis e câncer colorretal

### RESUMO

Situs inversus totalis é uma anomalia anatômica consistindo em um investimento de órgãos abdominais. Nesse estudo, descrevemos um paciente, homem 67 anos, que foi diagnosticado com situs inversus totalis na infância. Apresentava sintomas de sangramento retal e foi diagnosticado com câncer de cólon direito e tratado cirurgicamente com recepção laparoscópica. Para a realização da colectomia laparoscópica precisamos de um estudo pré-operatória

#### Palavras-chave:

Câncer Colorretal

Situs inversus totalis

Cirurgia laparoscópica

Malformação congênita

\* Corresponding author.

E-mail: [marialm007@hotmail.com](mailto:marialm007@hotmail.com) (M.L. Martínez).

<http://dx.doi.org/10.1016/j.jcol.2017.02.004>

2237-9363/© 2017 Sociedade Brasileira de Coloproctologia. Published by Elsevier Editora Ltda. This is an open access article under the CC BY-NC-ND license (<http://creativecommons.org/licenses/by-nc-nd/4.0/>).

completa e um plano detalhado de cirurgia com localização do trocateres e cirurgões. A cirurgia durou 120 minutos e perde de sangue foi mínima. O resultado do exame patológico relatou adenocarcinoma (T3N0). Nosso paciente foi admitido por 7 dias e não apresentaram complicações. Para os pacientes com situs inversus totalis e câncer colorretal a recepção laparoscópica pode ser mais difícil mas eficaz e segura.

© 2017 Sociedade Brasileira de Coloproctologia. Publicado por Elsevier Editora Ltda. Este é um artigo Open Access sob uma licença CC BY-NC-ND (<http://creativecommons.org/licenses/by-nc-nd/4.0/>).

## Introduction

Situs inversus totalis (SIT) is a congenital anatomic anomaly characterized by a complete inversion of all thoracic and intra-abdominal organs that creates a mirror image of their normal locations. The incidence rate of SIT is 1 per 10,000–20,000 people and it is inherited in a simple autosomal recessive manner.<sup>1</sup> Surgical procedures in these patients, especially laparoscopic approaches, are more difficult because of concurrent unknown defects and different positions of the organs resulting in an uncommon view. We present a case of a patient with SIT and ascending colon cancer who underwent a laparoscopic hemicolectomy.

## Case report

A 67 year-old male with hypertension and diabetes mellitus was referred by his personal physician to the colorectal surgical department for a 2-months history of hematoquezia. He and several relatives had been diagnosed with SIT from early childhood. Physical examination was unremarkable. Laboratory examination confirmed anemia (red blood cell count,  $3.6 \times 10^6/\text{mm}^3$ ; haemoglobin, 9.2 g/dL; hematocrit 29.8%). A diagnosis of colon cancer was made after a complete colonoscopy revealed an ulcerative mass 90 cm from anal verge. Histologic exam of colonoscopy biopsy indicated adenocarcinoma. A chest X-ray showed dextrocardia and right-sided gastric air bubble (Fig. 1). Echocardiography also revealed dextrocardia without cardiac valvular pathology and cardiac malformation. Abdominal Computed tomography showed a complete transposition of abdominal viscera confirming SIT, a colonic mass located in ascending colon, which was inverted to the left side (Fig. 2) and no hepatic and peritoneal metastasis. The serum concentrations of carcinoembryonic antigen and Ca 19.9 were elevated (12.5 ng/mL, reference rate 0–4.9 ng/dL, and 30 U/mL, reference rate 0–37, respectively).

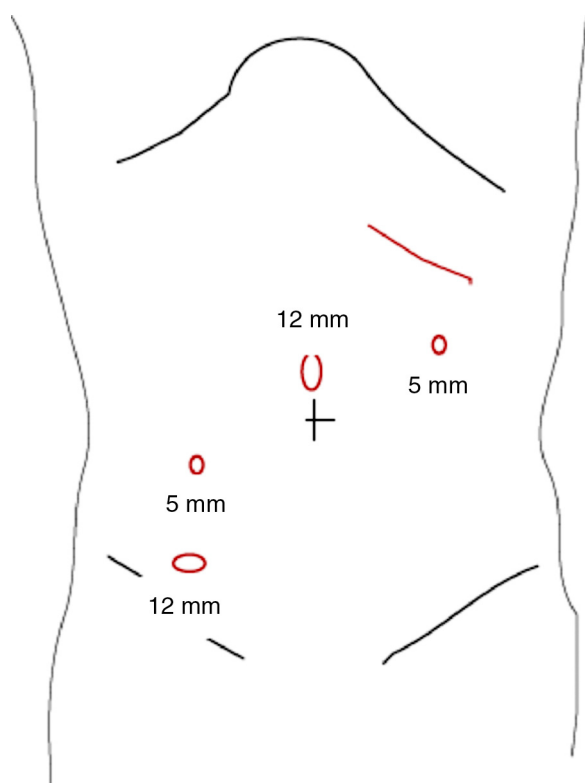
According to the findings above laparoscopic hemicolectomy was performed under general anesthesia in a lithotomy position tilted to the right and with his head down. The surgeon and the second assistant were situated at the right side of the patient and the first assistant was positioned on the left, which are opposite the positions used for a normal patient. Pneumoperitoneum was established above umbilicus using a Hasson trocar (12 mm optical trocar) for the camera inserted by open technique under direct vision. Trocars were placed in a mirror manner including a 12 mm trocar in the right iliac

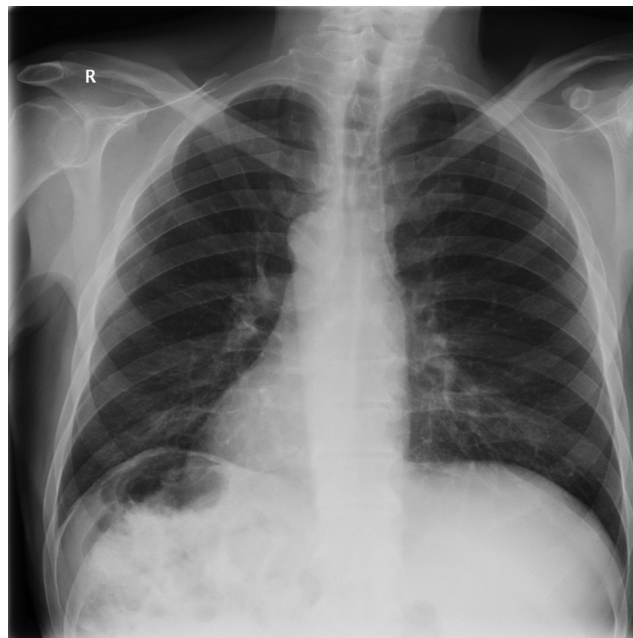

Fig. 1 – Chest X-ray showed dextrocardia and right-sided gastric air bubble.

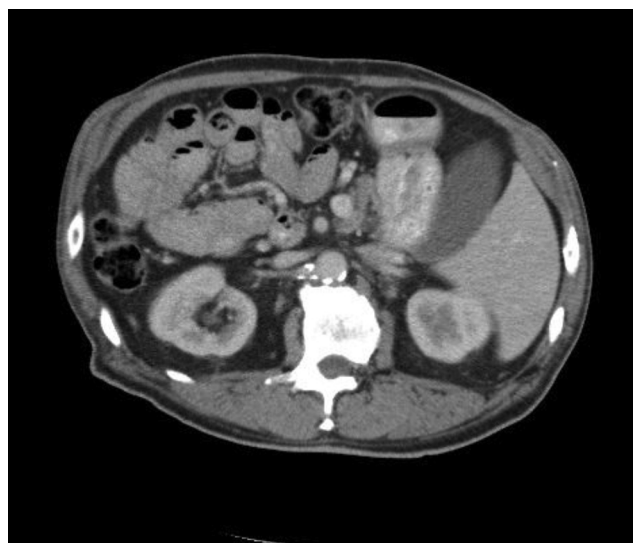

Fig. 2 – Abdominal computed tomography showed a colonic mass located in ascending colon, which was inverted on the left side.

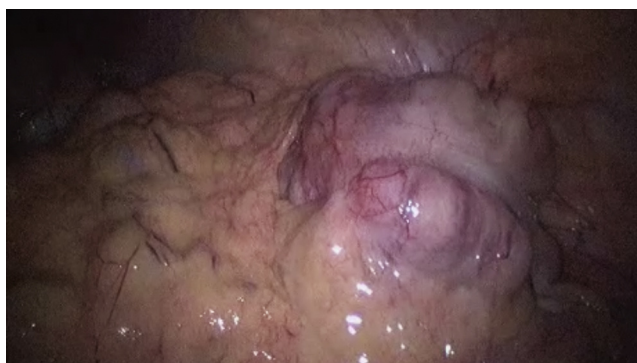

**Fig. 3 – Placement of trocars for laparoscopic right hemicolectomy in patients with situs inversus totalis.**

fossa and a 5 mm trocar in the left iliac fossa for the operator, and a 5 mm trocar in the left flank used by the first assistant for suction, irrigation and traction (Fig. 3).

Laparoscopic exploration of the abdominal cavity was carried out to allow visualization of the liver located on the left and the stomach and the spleen on the right demonstrating SIT. Others malformations were not found. The appendix, cecal and the colonic mass in the ascending colon were identified in the left side of abdominal cavity (Fig. 4).

The mesentery was incised caudal to the ileocolic vessels. A mesenteric window below the vessels was created searching the second part of duodenum. The ileocolic vessels were divided at its root after superior mesenteric vessels were exposed and radical lymphadenectomy around this area



**Fig. 4 – Laparoscopic view identifying colonic mass in the ascending colon located on the left of abdominal cavity.**

was performed. Dissection of the lymph nodes continued up to the root of the middle colic artery and the left branch of this artery was divided. A careful mobilization of the ascending colon including tumor was performed along Toldt's fascia medially to laterally to avoid bleeding.

Through a left subcostal incision the bowel was extracted. The reconstruction was carried out extracorporeally and a side-to-side functional anastomosis between the ileum and transverse colon was performed using a stapling method. Total operating time was 120 min, the blood loss was less than 100 mL and the patient was discharged on the 6th day after the operation without complications.

Histologic examination of the resected specimen showed a well-differentiated adenocarcinoma with serosal invasion, no metastasis to the sixty isolated lymph nodes and without venous, lymphatic and perineural invasion (pT3N0).<sup>2</sup> The patient did not receive adjuvant treatment and he is doing well without recurrence six months after colectomy.

## Discussion

SIT was first described in 1600 by Fabricius.<sup>3</sup> SIT refers to a complete inversion of all the thoracic and abdominal organs challenging the left and right aspects of the cavities and resulting in uncommon view. Laparoscopic surgery for colon cancer in SIT may be more difficult but safer procedure should be performed carefully.

SIT itself has no pathophysiologic significance and genetic predisposition has been established.<sup>4</sup> In this case, several members of patient's family present this condition suggesting genetic predisposition. Cardiac and intestinal malformations as well as other congenital anomalies can be associated with SIT.<sup>5</sup> Cases with SIT an asplenia, polysplenia, biliary atresia or intestinal malrotation have been reported.<sup>6</sup> This case is not associated with other malformations.

SIT itself is not a premalignant condition. In the literature review more than 50 cases of neoplasias in patients with SI have been described until nowadays.<sup>6-9</sup> There have been published several cases of SIT associated with synchronous and metachronous multiple gastrointestinal malignancies.<sup>10</sup> In the general population, the incidence of synchronous and metachronous colon cancer ranges from 3 to 8% and from 0.5 to 3.6% respectively, and these incidences do not seem to be higher in patients with SIT.<sup>11</sup> The diagnosis of malignancy in patient with SI may be sporadic but some authors have proposed a hypothesis that defends a possible relationship between unidentified genes affecting left-right axis arrangement and genes related to cancer susceptibility.<sup>12</sup>

Most cases of SIT are detected during medical check-ups using chest radiograph. Careful preoperative study is very important in these cases.<sup>13</sup> Apart from standard examination during a staging workup for colon cancer in which a chest radiograph, laboratories studies and thoracoabdominal computed tomography are included, patients with SIT who underwent surgery, needed an echocardiography to identify cardiac valvular pathology or cardiac malformation.<sup>14</sup>

Colonoscopy in patients with SIT and colorectal cancer may be more difficult technically. So it would be better the colonoscopists were aware of this status before

**Table 1 – Worldwide publications about laparoscopic colectomy for colon cancer in patients with SIT.**

Author	Year	Location	Diagnosis of SIT in the childhood	Other malformations	Complications	Blood loss (ml)	Operating time (min)	Discharge (postoperative day)
Fujiwara et al. <sup>13</sup>	2007	Ascending colon	Yes	No	None	60	191	10th
Kim WK et al. <sup>10</sup>	2011	Transverse and sigmoid colon	No	No	None	–	–	18th
Kim HJ et al. <sup>16</sup>	2011	Ascending colon	No	No	None	Minimal	119	7th
Sumi Y et al. <sup>17</sup>	2013	Transverse colon	Yes	No	None	230	402	16th
Yaegashi M et al. <sup>18</sup>	2015	Sigmoid colon	Yes	No	None	13	189	7th
Present case	2016	Ascending colon	Yes	No	None	100	120	6th

examination. Literature reports indicate that there were not more adverse events during colonoscopy in patients with SI but some authors have found a prolonged cecal intubation time.<sup>15</sup>

SIT and colorectal cancer may become easily detected with current radiologic and endoscopic methods of diagnosis but other unexpected anomalies could arise during surgery. For this reason, surgical techniques, especially laparoscopic procedures, are more difficult and complex and a detailed plan is needed for successful surgical treatment.

Only five laparoscopic procedures for colon cancer in patients with SIT have been published in the English literature<sup>10,13,16–18</sup> (Table 1). Principles of radical resection of the cancer and accompanying dissection of the lymph nodes were preserved. Authors emphasize the importance of an exhaustive preoperative study and a detailed planning of laparoscopic surgery including positions of operator and assistants, trocar sites and a careful surgical technique to be aware of anatomic challenges. Four patients have been diagnosed with SIT in the childhood. They were not found with any other malformations. No complications have been reported. Blood loss was minimal, total operating time and the hospital stay were comparable with that of patients with ordinary anatomical positions.

The trocar sites have to be carefully considered for SIT patients.<sup>16–19</sup> We proposed the use of four trocars to perform laparoscopic right hemicolectomy. In the present case, the surgeon was situated at the right side of the patient, opposite the usual side for surgery, the 12mm trocar was placed at the right iliac fossa for surgeon's right hand and the 5mm trocar was placed at the right flank for her left hand. We began by identifying and dividing the ileocolic vessels and then continued with the dissection mobilization of the ascending colon including tumor that was carried out medially to laterally to make the procedure more feasible. Some authors propose that a left-handed surgeon may have a technical advantage during laparoscopy in patients with SIT.<sup>20</sup> However, this condition could not preclude right-handed surgeons from performing the laparoscopic procedure in SIT patients accurately because surgeons have to employ rightly their dominant and non-dominant hands.

## Conclusion

Laparoscopic surgery for colon cancer in patients with SIT could be safely performed. A complete preoperative evaluation is important for successful surgical treatment. Because of anatomic challenges, laparoscopy requires a careful plan including positions of surgeons and trocar sites as well as a skillful technique.

## Conflicts of interest

The authors declare no conflicts of interest.

## REFERENCES

1. Mayo CW, Rice RG. Situs inversus totalis: a statistical review of data on 76 cases with special reference to disease of the biliary tract. *Arch Surg.* 1949;58:724–30.
2. Edge SB, Byrd DR, Compton CC, editors. *AJCC cancer staging manual (Colon and rectum)*. 7 ed. New York: Springer; 2010. p. 143–64.
3. Takei HT, Maxwell JG, Clancy TV, Tinsley EA. Laparoscopic cholecystectomy in situs inversus totalis. *J Laparoendosc Surg.* 1992;2:171–6.
4. Goi T, Kawasaki M, Yamazaki T, Koneri K, Katayama K, Hirose K, et al. Ascending colon cancer with hepatic metastasis and cholelithiasis in a patient with situs inversus totalis without any expression of UVRAG mRNA: report of a case. *Surg Today.* 2003;33:702–6.
5. Uchida H, Kawamura YJ, Takegami K, Matsuda K, Watanabe T, Masaki T, et al. Colon cancer complicated by vascular and intestinal anomaly. *Hepatogastroenterology.* 2004;51:156–8.
6. Zhu H, Yang K, Hu JK. Gastrectomy for gastric carcinoma with situs inversus totalis: case report and literature review. *Hippokratia.* 2015;19:360–2.
7. Iwamura T, Shibata N, Haraguchi Y, Hisashi Y, Nishikawa T, Yamada H, et al. Synchronous double cancer of the stomach and rectum with situs inversus totalis and polysplenia syndrome. *J Clin Gastroenterol.* 2001;33:148–53.
8. Patel RB, Gupta NR, Vasava NC, Khambholja JR, Chauhan S, Desai A. Situs inversus totalis (SIT) with hepatocellular carcinoma (HCC): a rare case report and review of 12 other cases. *Indian J Surg.* 2013;75:424–9.

9. Kyno D, Kimura Y, Imamura M, Uchiyama M, Ishii M, Meguro M, et al. Pancreaticoduodenectomy for biliary tract carcinoma with situs inversus totalis: difficulties and technical notes based on two cases. *World J Surg Oncol*. 2013;11:312.
10. Kim YW, Ryu H, Kim DS, Kim IY. Double primary malignancies associated with colon cancer in patients with situs inversus totalis: two case reports. *World J Surg Oncol*. 2011;9:109.
11. Park U, Yu CS, Kim HC, Jung YH, Hari KR, Kim JC. Metachronous colorectal cancer. *Colorectal Dis*. 2006;8:323-7.
12. Galiatsatos P, Kasprzak L, Chong G, Jass JR, Foulkes WD. Multiple primary malignancies in a patient with situs ambiguous. *Clin Genet*. 2006;69:528-31.
13. Fujiwara Y, Fukunaga Y, Higashino M, Tanimura S, Takemura M, Tanaka Y, et al. Laparoscopic hemicolectomy in a patient with situs inversus totalis. *World J Gastroenterol*. 2007;13:5035-7.
14. Francis R, Adam C, Device W, Ostrowski L, Lo C. Congenital heart disease and the specification of left-right asymmetry. *Am J Physiol Heart Circ Physiol*. 2012;302:2102-11.
15. Choi DH, Park JW, Kim BN, Han KS, Hong CW, Sohn DK, et al. Colonoscopy in situs inversus totalis patients. *Am J Gastroenterol*. 2008;103:1311-2.
16. Kim HJ, Choi GS, Park JS, Lim KH, Jang YS, Park SY. Laparoscopic right hemicolectomy with D3 lymph node dissection for a patient with situs inversus totalis: report a case. *Surg Today*. 2011;41:1528-42.
17. Sumi Y, Tomono A, Suzuki S, Kuroda D, Kakeji Y. Laparoscopic hemicolectomy in a patient with situs inversus totalis after open distal gastrectomy. *World J Gastroenterol Surg*. 2013;5:22-6.
18. Yaegashi M, Kimuza T, Takashi S, Sato T, Kawasaki Y, Otsuka K, et al. Laparoscopic sigmoidectomy for a patient with situs inversus totalis: effect of changing operator position. *Int Surg*. 2015;100:638-42.
19. Choi SI, Park SJ, Kang BM, Lee KY, Lee HC, Lee SH. Laparoscopic abdominoperineal resection for rectal cancer in a patient with situs inversus totalis. *Surg Laparosc Endosc Percutan Tech*. 2011;21:87-90.
20. Oms LM, Badia JM. Laparoscopic cholecystectomy in situs inversus totalis: the importance of being left handed. *Surg Endosc*. 2003;17:1859-61.