



## Original Article

# Assessment of fistulectomy combined with sphincteroplasty in the treatment of complicated anal fistula



Fakhrolsadat Anaraki<sup>a</sup>, Omid Etemad<sup>b</sup>, Elham Abdi<sup>c,\*</sup>, Gholamreza Bagherzadeh<sup>a</sup>, Roubik Behboo<sup>d</sup>

<sup>a</sup> Shahid Beheshti University of Medical Sciences, Taleghani Hospital, Department of Colorectal Surgery, Tehran, Iran

<sup>b</sup> Tehran University of Medical Sciences, Plastic and Reconstructive Surgery Ward, Tehran, Iran

<sup>c</sup> Shahid Beheshti University of Medical Sciences, Tehran, Iran

<sup>d</sup> Iran University of Medical Sciences, Rasoul Akram Hospital, Department of Colorectal Surgery, Tehran, Iran

### ARTICLE INFO

#### Article history:

Received 1 April 2017

Accepted 14 May 2017

Available online 5 July 2017

#### Keywords:

Fistulectomy

Sphincteroplasty

Anal fistula

### ABSTRACT

**Introduction:** The ideal method of treating the complex anal fistula is to eradicate the sepsis and preserve the anal sphincter; since there is no definite consensus on the surgical method of treating it. Recent studies show that fistulectomy and immediate sphincteroplasty are a safe and appropriate way to treat the fistula-in-ano. The aim of this study was to evaluate the long term outcomes of fistulectomy and sphincteroplasty in the treatment of complex perianal fistula.

**Methods:** In this prospective study, we have analyzed the data of 80 patients who underwent fistulectomy and sphincteroplasty from May 2013 to May 2016. Preoperative information included physical examination, preoperative fecal incontinence evaluation and taking a complete history about underlying diseases and past related surgeries were collected.

**Results:** Of all 80 patients with complex fistula, 57.5% (46 patients) were male. 70-Patients were presented with high transsphincteric fistula (87.5%) and anterior fistula was diagnosed in 10 of them (12.5%). 9 patients (11.3%) suffered from hypertension and 43 patients (53.75%) had recurrent fistula after previous surgeries. During the follow-up period, the overall success rate was 98.8% (98.8%) and fistulectomy and sphincteroplasty failed in only one patient (failure rate: 1.3%). preoperative and post-operative scoring showed mild fecal incontinence in 8 patients (10%). We have found no significant relation between the age, gender, hypertension, previous surgery and post-operative recurrence.

**Conclusion:** Fistulectomy and sphincteroplasty is a safe surgical procedure in the treatment of anterior anal fistula in females and high transsphincteric fistulas.

© 2017 Sociedade Brasileira de Coloproctologia. Published by Elsevier Editora Ltda. This is an open access article under the CC BY-NC-ND license (<http://creativecommons.org/licenses/by-nc-nd/4.0/>).

\* Corresponding author.

E-mail: [elhamabdi1993@gmail.com](mailto:elhamabdi1993@gmail.com) (E. Abdi).

<http://dx.doi.org/10.1016/j.jcol.2017.05.003>

2237-9363/© 2017 Sociedade Brasileira de Coloproctologia. Published by Elsevier Editora Ltda. This is an open access article under the CC BY-NC-ND license (<http://creativecommons.org/licenses/by-nc-nd/4.0/>).

## Avaliação de fistulectomia combinada com esfínteroplastia no tratamento de fístula anal complicada

### R E S U M O

#### Palavras-chave:

Fistulectomia  
Esfínteroplastia  
Fístula anal

**Introdução:** o método ideal para tratar a fístula anal complexa consiste em erradicar a sepse e preservar o esfíncter anal, uma vez que não existe consenso definitivo com relação ao método cirúrgico para tratamento desse problema. Estudos recentes demonstram que a fistulectomia, seguida imediatamente pela esfínteroplastia, é procedimento seguro e apropriado no tratamento da fístula perianal. O objetivo deste estudo foi avaliar os resultados em longo prazo da fistulectomia e da esfínteroplastia no tratamento da fístula perianal complexa.

**Métodos:** Neste estudo prospectivo analisamos os dados de 80 pacientes tratados por fistulectomia e esfínteroplastia no período de maio de 2013 até maio de 2016. Foram coletadas as seguintes informações pré-operatórias: exame físico, avaliação pré-operatória de incontinência fecal e história completa sobre doenças subjacentes e cirurgias prévias afins.

**Resultados:** De todos os 80 pacientes com fístula complexa, 57,5% (46 pacientes) pertenciam ao gênero masculino. Setenta pacientes se apresentaram com fístula trans-esfíncterica alta (87,5%); em 10 desses pacientes (12,5%), foi diagnosticada fístula anterior. Nove pacientes (11,3%) sofriam de hipertensão (HT), tendo sido observada recorrência de fístula após cirurgias prévias em 43 pacientes (53,75%). Durante o período de seguimento, o percentual de sucesso global foi de 98,8%, e em apenas um paciente os procedimentos de fistulectomia e esfínteroplastia não obtiveram sucesso (percentual de falha: 1,3%). Os escores pré-operatórios e pós-operatórios revelaram incontinência fecal leve em 8 pacientes (10%). Não observamos nenhuma relação significativa entre idade, gênero, HT, cirurgia prévia e recorrência pós-operatória.

**Conclusão:** Fistulectomia e esfínteroplastia constituem procedimento cirúrgico seguro no tratamento de fístulas anais anteriores em mulheres e de fístulas trans-esfínctericas altas.

© 2017 Sociedade Brasileira de Coloproctologia. Publicado por Elsevier Editora Ltda. Este é um artigo Open Access sob uma licença CC BY-NC-ND (<http://creativecommons.org/licenses/by-nc-nd/4.0/>).

## Introduction

Anal fistulas are mostly cryptogenic in which the main method of treatment is to eradicate the infection, and preserve the anal sphincter function.<sup>1</sup> The standard committee of American Society of Colorectal Surgeons (ASCRS) classified "Complex" fistulas as all intersphincteric, transsphincteric and suprasphincteric fistulas.<sup>2,3</sup>

There are many sphincter-saving methods for the treatment of complex anal fistula, but because of post-operative fecal incontinence (FI) or recurrence, there is no definite consensus about the surgical treatment of it.<sup>4,5</sup> Cutting seton placement has up to 67% incontinence rate<sup>6</sup>; since endorectal advancement flap has up to 35% risk of FI, and 30–60% failure rate.<sup>7,8</sup> Newer techniques such as ligation of intersphincteric fistula tract have the recurrence rate of 30–60% and anal fistula plug has the failure rate of 70–80%.<sup>9,10</sup>

20 years ago, fistulectomy and immediate sphincteroplasty was suggested to reduce the post-operative FI and then many surgeons employed this combined technique for treating complex anal fistula.<sup>11–14</sup> This technique is defined as a safe and appropriate way for treatment of fistula-in-ano and also has a high healing rate,<sup>15</sup> but there are some concerns and doubts about the results of this procedure.<sup>16</sup>

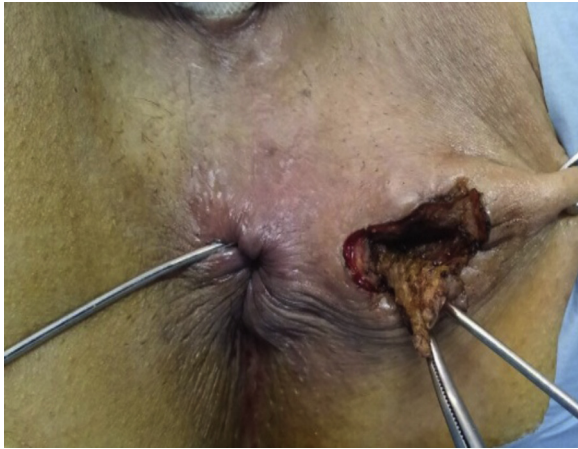The aim of this study is evaluation the long term results of fistulectomy with sphincteroplasty on treatment of Complex perianal fistula.

## Materials and methods

In our prospective study, we have analyzed and evaluated 80 patients who underwent fistulectomy and immediate sphincteroplasty from May 2013 to May 2016. All patients suffered from complex anal fistula (hightranssphincteric and anterior fistula in female). The patients with complex fistula secondary to radiation or IBD were excluded in this study.

All patients were physically examined by colorectal surgeon to identify the type of fistula and make sure that no abscess has occurred. We have assessed all patients in order to find out if they had past surgeries related to abscess drainage or healing the fistula or underlying disease such as Hypertension. Pre-operative assessments also included the examination of fecal incontinence by using Cleveland Clinic Florida fecal incontinence scoring (CCF-FIS) which is tabulated in Supplementary Material.

Bowel preparation was done by using suppository Bisacodil for all patients the day before surgery. Antibiotics (IV Cephtriaxon 1 g and Metronidazol 500 mg) were given on induction of



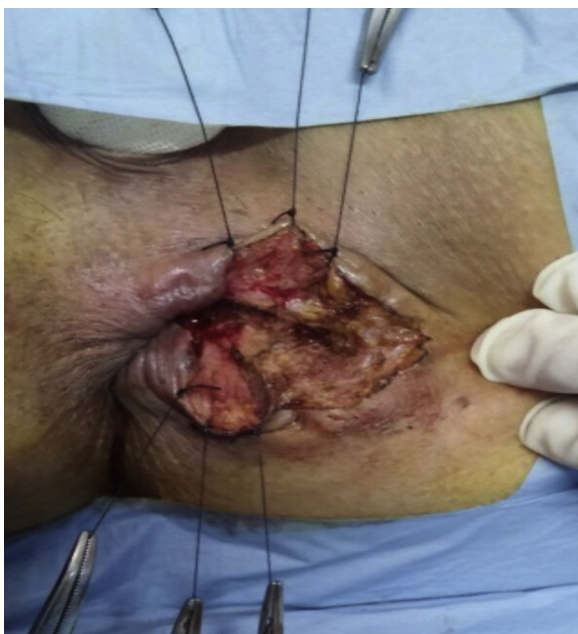**Fig. 1 – Excision of fistulous tract.**

regional anesthesia. All patients were positioned in the lithotomy position. Two distinct steps of the procedure were as follows:

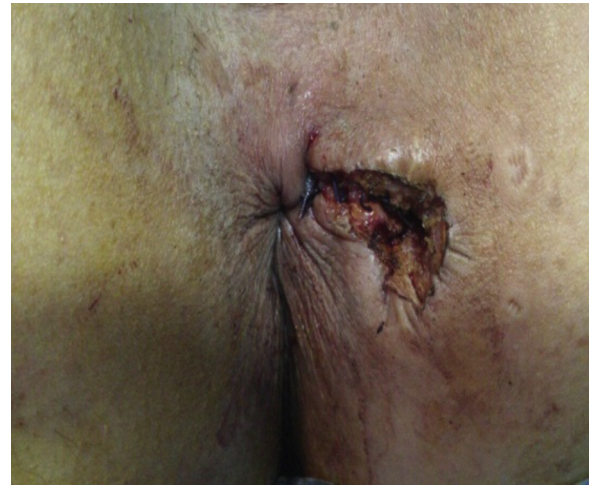First, we excised the fistulous tract in ischioanal fossa up to the lateral border of external sphincter and opened the transsphincteric portion of the tract and internal opening, as you can see in Fig. 1. After cutting the skin overlying the sphincter, we cut the sphincter over the tract, and then the granulation tissue of the tract was excised meticulously.

Then, after irrigation of the wound with saline solution, we approximated the two edges of external and internal sphincter using Vicryl 2/0 sutures (Fig. 2). The skin and anoderm overlying the wound was left open for drainage (Fig. 3).

First post-op day, we kept all patients NPO and prescribed them 2 doses of intravenous (i.v.) Ceftriaxone and Metronidazole.



**Fig. 2 – Approximation of two edges of external and internal sphincter using Vicryl 2/0 sutures.**



**Fig. 3 – The skin and anoderm overlying the wound was left open for drainage.**

On the second day after the surgery, only fluid diet was started for them and oral antibiotics included ciprofloxacin, 500 BID and Metronidazole, 250 mg TDS were prescribed for one week. On the end of second day, we taught the patients how to bath the wound, and discharged them. All the patients were visited 1 week after the surgery in colorectal clinic. They were also examined 1, 3, 6, 12, 24, 36 months after the surgery for evaluation of wound healing and continence status.

## Results

Statistical analysis was conducted by using SPSS software package Ver. 21. Baseline characteristic like mean  $\pm$  standard deviation or the median were calculated according to the statistical distribution for continues parameters, and the number of patients and associated percentages for categorical parameters. The variables analyzed were age, gender, weight, underlying disease, previous associated surgeries, Pre-op and Post-op FI, and recurrence. Follow-up was performed for all patients in 3, 6, 12, 24, 36 months after the surgery. Of 80 patients with complex fistula, 57.5% (46 patients) were male, and 42.5% (34 patients) were female (Fig. 4).

The median age was 40-years-old. The youngest patient was 17 years old, and the oldest was 70 years old. The median weight was 78 kg (mean = 77.6).

70 patients had high transsphincteric fistula (87.5%) and 10 of them who were female, had anterior fistula (12.5%) (Fig. 5).

The 9 patients (11.3%) suffered from hypertension (HTN) and 43 patients (53.75%) had recurrent fistula after previous surgeries. 25 patients (31.25%) had undergone previous operation once, 15 patients (18.75%) had experienced the previous surgery twice or three times, and 3 patients (3.75%) had the operations more than three times.

Most of the patients had no complaint of FI before this surgery ( $n=79$ , 98.8%) and only one person had fecal incontinence with the score of 8/20 according to CCF-FIS.

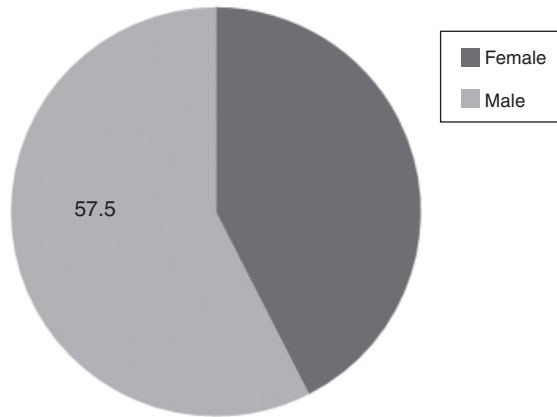


Fig. 4 – Gender distribution.

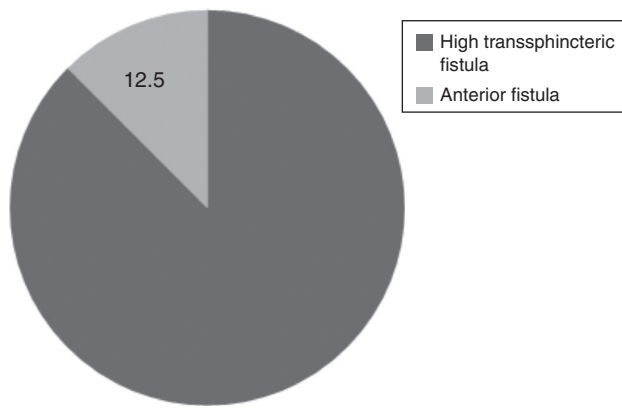


Fig. 5 – Type of fistula.

In follow up period, the overall success rate was 98.8%, and recurrence was seen in only one patient (failure rate: 1.2%) who had past anal fistula surgery (Fig. 6).

The preoperative and post-operative incontinence scoring showed mild fecal incontinence in 8 (10%) patients. The score of incontinence was 2/20 in two patients, 4/20 in two patients, 6/20 in one patient, 7/20 in one patient, 8/20 in one patient and there was fecal soilage in only one patient. Another patient with preoperative score of 8/20 improved to the postoperative score of 6/20.

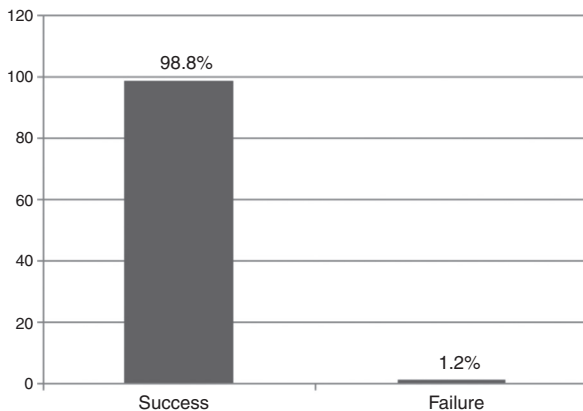


Fig. 6 – Success and failure rate.

The SPSS calculation detected no significant relation between the age, gender, HTN, previous surgery and post-operative recurrence or fecal incontinence.

## Discussion

Perianal fistulas have the mean incidence of 10 per 10, 1000 in the world. It is a frequent condition that needs colorectal intervention for treatment.<sup>17</sup> In spite of high incidence of perianal fistula and many advances in surgery and techniques, the treatment of perianal fistula is still a challenge because of high rate of recurrence and fecal incontinence after the surgery.<sup>4,18</sup> The disturbances of anal continence may vary from 0% to 25% for flatus control, 0% to 17% for stools, and up to 40% for passive incontinence which depend on the type of the procedure, the type and complexity of fistula, and associated risk factors for incontinence such as age, gender, previous surgery for perianal fistula and etc.<sup>6,19-21</sup>

For a long time, fistulotomy was the definite choice for management of anal fistula because of the best results of success healing rate which was between 74% and 100%, but in many literatures, the high risk of recurrence and fecal incontinence in the treatment of complex anal fistulas Visscher et al. was reported. In 2015, an evaluation on 141 patients with simple and complex perianal fistula who underwent fistulotomy was performed. The median follow-up was 7.8 years. 34% of the patients experienced fecal incontinence, which was worse in patients with complex fistula in comparison with simple fistula.<sup>4</sup> Both the American and European guidelines suggest using this procedure only for low, “simple” fistulas.<sup>3,16</sup>

In former years, fistulectomy has been performed to be the standard surgery for management of complex perianal fistula. However, the incontinence after surgery lead the proctologists to propose and evaluate some procedures with the mechanism of sphincter saving.<sup>5,22</sup> Insertion of cutting seton was evaluated in many studies, in which healing rate was reported between 80% and 100% and impaired continence rates after the surgery were between 0% and 92%.<sup>23-25</sup> Besides, endorectal advancement flap was evaluated with the healing rate between 33% and 100% and incontinence rate between 0% and 71%.<sup>26-31</sup> Recently, the newer techniques such as fibrin glue and collagen plug are offered. The studies showed that the healing rate of fibrin glue is ranged from 0% to 86%,<sup>32-35</sup> and anal collagen plug is between 14% and 100%.<sup>17,36-38</sup> Also recent literatures showed that the long-term results of anal collagen plug were poor, so performing this method seems to be doubtful.<sup>39,40</sup>

In 1985, Parkash et al. published their result of researches on primary closure and reconstruction of anal sphincter after fistulectomy. They introduced this procedure as a way for reducing the healing time and preventing anal deformity. After that, this procedure was performed for the treatment of complex anal fistula.<sup>11</sup>

In our series of 80 patients, healing rate was 98.8%, and FI rate was 10%. Among the patients with FI, one patient suffers from soilage or passive incontinence. Another patient with preoperative score of 8/20 has improved to the postoperative score of 6/20. Most of the previous studies had the same results as we had. One follow-up study by Hirschburger et al.

was done to evaluate the healing rate and FI in 50 patients with high transsphincteric fistula who underwent fistulectomy with primary sphincter reconstruction.<sup>15</sup> During their follow-up period, the healing rate was 88%, and the recurrence was 10%. Three patients had low grade fecal incontinence consequent the surgery and one patient with 2 score incontinence improved.

Roig et al., analyzed the data of 31 patients with high trans-sphincteric, low trans-sphincteric and suprasphincteric fistula who underwent fistulectomy with sphincteroplasty in the mean 24 months follow-up.<sup>41</sup> The recurrence was 9.7%, perianal soiling was 20%, and flatus incontinence was 4%. This study also showed that this procedure allows both rapid recovery and the preservation of anal sphincter.

We also assessed the factors such as age, gender, Hypertension, previous surgery, and type of fistula that may affect on the results of this procedure and found out that these factors had the meaningless effects on the outcome of the surgery.

In some studies, previous surgery was announced as a probable factor affecting the post-operative continence,<sup>6,42</sup> but we did not find a relation between previous surgeries and post-operative FI as what Abcarian had published in February, 2013.<sup>14</sup> That study showed that none of the investigated factors (age, gender, smoking, previous surgery) can predict the success of surgery.

In previous studies, fistulectomy with sphincteroplasty was mostly performed in the treatment of high transsphincteric fistula, but we employed this operation technique for the patients with high transsphincteric fistula, and the women with anterior fistula. The success rate of this procedure was high (100%) in patients with anterior fistula which lead us to say that fistulectomy with sphincter reconstruction is a safe and effective procedure for transsphincteric fistula and Anterior fistula in female patients, as well as recurrent fistulas.

## Conclusion

Fistulectomy and immediate sphincter reconstruction is a safe surgical procedure to treat the anterior anal fistula in women and high transsphincteric fistulas. The primary healing rate is high and the recurrence rate (failure rate) is very low.

## Conflicts of interest

The authors declare no conflicts of interest.

## Appendix A. Supplementary data

Supplementary data associated with this article can be found, in the online version, at [doi:10.1016/j.jcol.2017.05.003](https://doi.org/10.1016/j.jcol.2017.05.003).

## REFERENCES

- Whiteford MH, Kilkenny J 3rd, Hyman N, Buie WD, Cohen J, Orsay C, et al. Standards Practice Task Force; American Society of Colon and Rectal Surgeons. Practice parameters for the treatment of perianal abscess and fistula-in-ano. *Dis Colon Rectum*. 2005;48:1337–42.
- Parks AG, Gordon PH, Hardcastle JD. A classification of fistula-in-ano. *Br J Surg*. 1976;63:1–12.
- Steele SR, Kumar R, Feingold DL, Rafferty JL, Buie WD. Standards Practice Task Force of the American Society of Colon and Rectal Surgeons. Practice parameters for the management of perianal abscess and fistula-in-ano. *Dis Colon Rectum*. 2011;54:1465–74.
- Visscher AP, Schuur D, Roos R, Van der Mijnsbrugge GJ, Meijerink WJ, Felt-Bersma RJ. Long-term follow-up after surgery for simple and complex cryptoglandular fistulas: fecal incontinence and impact on quality of life. *Dis Colon Rectum*. 2015;58:533–9.
- Cirocchi R, Trastulli S, Morelli U, Desiderio J, Boselli C, Parisi A, et al. The treatment of anal fistulas with biologically derived products: is innovation better than conventional surgical treatment? An update. *Tech Coloproctol*. 2013;17:259–73.
- García-Aguilar J, Belmonte C, Wong DW, Goldberg SM, Madoff RD. Cutting seton versus two-stage seton fistulotomy in the surgical management of high anal fistula. *Br J Surg*. 1998;85:243–50.
- Schoutewr WR, Zimmerman DD, Briel JW. Transanal advancement flap repair of transsphincteric fistulas. *Dis Colon Rectum*. 1999;42:1419–22.
- Soltani A, Kaiser AM. Endorectal advancement flap for cryptoglandular or Crohn's fistula-in-ano. *Dis Colon Rectum*. 2010;53:486–95.
- Tan KK, Kaur G, Byrne CM, Young CJ, Wright C, Solomon MJ. Long-term outcome of the anal fistula plug for anal fistula of cryptoglandular origin. *Colorectal Dis*. 2013;15:1510–4.
- Wang JY, Garcia-Aguilar J, Sternberg JA, Abel ME, Varma MG. Treatment of transsphincteric anal fistulas: are fistula plugs an acceptable alternative? *Dis Colon Rectum*. 2009;52:692–7.
- Parkash S, Lakshmiratan V, Gajendran V. Fistula-in-ano: treatment by fistulectomy, primary closure and reconstitution. *Aust N Z J Surg*. 1985;55:23–7.
- Ratto C, Litta F, Parello A, Zaccone G, Donisi L, De Simone V. Fistulotomy with end-to-end primary sphincteroplasty for anal fistula: results from a prospective study. *Dis Colon Rectum*. 2013;56:226–33.
- Herold A. *Fistulectomy with primary sphincter reconstruction*; 2014.
- Abcarian H. *Anal fistula. Principles and management*. New York: Springer; 2014. p. 65–8.
- Hirschburger M, Schwandner T, Hecker A, Kierer W, Weinel R, Padberg W. Fistulectomy with primary sphincter reconstruction in the treatment of high transsphincteric anal fistulas. *Int J Colorectal Dis*. 2014;29:247–52.
- Williams JG, Farrands PA, Williams AB, Taylor BA, Lunniss PJ, Sagar PM, et al. The treatment of anal fistula: ACPGIBI position statement. *Colorectal Dis*. 2007;9 Suppl. 4:18–50.
- de la Portilla F, Rada R, Jiménez-Rodríguez R, Díaz-Pavón JM, Sánchez-Gil JM. Evaluation of a new synthetic plug in the treatment of anal fistulas: results of a pilot study. *Dis Colon Rectum*. 2011;54:1419–22.
- Mennigen R, Laukötter M, Senninger N, Rijcken E. The OTSC® proctology clip system for the closure of refractory anal fistulas. *Tech Coloproctol*. 2015;19:241–6.
- The Standards Practice Task Force. The American Society of Colon and Rectal Surgeons. Practice parameters for treatment of fistula-in-ano. *Dis Colon Rectum*. 1996;39:1361–72.
- Boyle DJ, Knowles CH, Murphy J, Bhan C, Williams NS, Scott SM, et al. The effects of age and childbirth on anal sphincter function and morphology in 999 symptomatic female patients with colorectal dysfunction. *Dis Colon Rectum*. 2012;55:286–93.

21. O'Connell PR. The effects of age and parity on anorectal function. *Dis Colon Rectum*. 2012;55:235-6.
22. Hull TL, El-Gazzaz G, Gurland B, Church J, Zutshi M. Surgeons should not hesitate to perform episiopectomy for rectovaginal fistula secondary to cryptoglandular or obstetrical origin. *Dis Colon Rectum*. 2011;54:54-9.
23. Mylonakis E, Katsios C, Godevenos D, Nousias B, Kappas AM. Quality of life of patients after surgical treatment of anal fistula the role of anal manometry. *Colorectal Dis*. 2001;3:417-21.
24. Dziki A, Bartos M. Seton treatment of anal fistula: experience with a new modification. *Eur J Surg*. 1998;164:543-8.
25. Zbar AP, Ramesh J, Beer-Gabel M, Salazar R, Pescatori M. Conventional cutting vs. internal anal sphincter-preserving seton for high trans-sphincteric fistula: a prospective randomized manometric and clinical trial. *Tech Coloproctol*. 2003;7:89-94.
26. Ortiz H, Marzo J, Ciga MA, Oteiza F, Armendáriz P, de Miguel M. Randomized clinical trial of anal fistula plug versus endorectal advancement flap for the treatment of high cryptoglandular fistula in ano. *Br J Surg*. 2009;96:608-12.
27. Amin SN, Tierney GM, Lund JN, Armitage NC. V-Y advancement flap for treatment of fistula-in-ano. *Dis Colon Rectum*. 2003;46:540-3.
28. Joy HA, Williams JG. The outcome of surgery for complex anal fistula. *Colorectal Dis*. 2002;4:254-61.
29. Gustafsson UM, Graf W. Randomized clinical trial of local gentamicin-collagen treatment in advancement flap repair for anal fistula. *Br J Surg*. 2006;93:1202-7.
30. Christoforidis D, Pieh MC, Madoff RD, Mellgren AF. Treatment of transsphincteric anal fistulas by endorectal advancement flap or collagen fistula plug: a comparative study. *Dis Colon Rectum*. 2009;52:18-22.
31. Chung W, Ko D, Sun C, Raval MJ, Brown CJ, Phang PT. Outcomes of anal fistula surgery in patients with inflammatory bowel disease. *Am J Surg*. 2010;199:609-13.
32. Hyman N, O'Brien S, Osler T. Outcomes after fistulotomy: results of a prospective, multicenter regional study. *Dis Colon Rectum*. 2009;52:2022-7.
33. Cintron JR, Park JJ, Orsay CP, Pearl RK, Nelson RL, Abcarian H. Repair of fistulas-in-ano using autologous fibrin tissue adhesive. *Dis Colon Rectum*. 1999;42:607-13.
34. Gisbertz SS, Sosef MN, Festen S, Gerhards MF. Treatment of fistulas in ano with fibrin glue. *Dig Surg*. 2005;22:91-4.
35. Thekkinkattil DK, Botterill I, Ambrose NS, Lundby L, Sagar PM, Buntzen S, et al. Efficacy of the anal fistula plug in complex anorectal fistulae. *Colorectal Dis*. 2009;11:584-7.
36. Safar B, Jobanputra S, Sands D, Weiss EG, Noguera JJ, Wexner SD. Anal fistula plug: initial experience and outcomes. *Dis Colon Rectum*. 2009;52:248-52.
37. Song WL, Wang ZJ, Zheng Y, Yang XQ, Peng YP. An anorectal fistula treatment with acellular extracellular matrix: a new technique. *World J Gastroenterol*. 2008;14:4791-4.
38. Zmora O, Neufeld D, Ziv Y, Tulchinsky H, Scott D, Khaikin M, et al. Prospective, multicenter evaluation of highly concentrated fibrin glue in the treatment of complex cryptogenic perianal fistulas. *Dis Colon Rectum*. 2005;48:2167-72.
39. Tinay OE, El-Bakry AA. Treatment of chronic fistula-in-ano using commercial fibrin glue. *Saudi Med J*. 2003;24:1116-7.
40. Buchanan GN, Bartram CI, Phillips RK, Gould SW, Halligan S, Rockall TA, et al. Efficacy of fibrin sealant in the management of complex anal fistula: a prospective trial. *Dis Colon Rectum*. 2003;46:1167-74.
41. Roig JV, Jordan J, Armengol J. Intermediate reconstruction of the anal sphincter alter in the management of complex fistula in an. *Colorectal Dis*. 1999;4:137-40.
42. Toyonaga T, Matsushima M, Kiri T, Sogawa N, Kanyama H, Matsumura N, et al. Factors affecting continence after fistulotomy for intersphincteric fistula-in-ano. *Int J Colorectal Dis*. 2007;22:1071-5.