



Original Article

A new defecographic parameter for assessing rectal emptying



Fábio Alves Soares^a, Juliana Portella Fontana^{b,*}, Erivaldo Fernandes de Lira^a,
Silvana Marques e Silva^a, Alexandre Gheller^a, Maurício Cotrim do Nascimento^a

^a Hospital de Base do Distrito Federal, Unidade de Coloproctologia, Brasília, DF, Brazil

^b Hospital das Forças Armadas, Unidade de Coloproctologia, Brasília, DF, Brazil

ARTICLE INFO

Article history:

Received 9 August 2018

Accepted 21 October 2018

Available online 2 November 2018

Keywords:

Barium

Constipation

Defecography

Rectum

ABSTRACT

Purpose: To validate a new defecographic parameter to assess rectal emptying correlating the percentage of weight reduction of barium paste and the variation in the percentage of area reduction of rectum compared before and after defecation during cindefecography.

Method: Thirty-two consecutive female patients with dyschezia who had clinical indication for cindefecography were selected. Their median age was 58 years old (18–78 years, mean = 55 years). During cindefecography, we calculated the cross-sectional sagittal area of the rectum before and after defecation and, thus, the percentage of area reduction of the rectum. The percentage of weight reduction of barium paste was calculated after weighing the contrast injected into the rectum and the amount of contrast evacuated, in grams, using a scale. Finally, both percentages were compared and checked for a correlation between them. Pearson's correlation (r) and Student's t test were used for statistical analysis.

Results: A correlation between evacuated barium paste and cross-sectional sagittal area of the rectum at the end of defecation was demonstrated ($r = 0.668$ and $p < 0.0001$).

Conclusion: It is possible to estimate how much barium paste is evacuated based on the variations in cross-sectional sagittal area of the rectum before and after defecation, in cindefecography.

© 2018 Published by Elsevier Editora Ltda. on behalf of Sociedade Brasileira de Coloproctologia. This is an open access article under the CC BY-NC-ND license (<http://creativecommons.org/licenses/by-nc-nd/4.0/>).

Um novo parâmetro defecográfico para avaliar o esvaziamento retal

RESUMO

Objetivo: Validar um novo parâmetro defecográfico para avaliar o esvaziamento retal correlacionando o percentual de redução de peso da pasta baritada e a variação da porcentagem da redução da área do reto antes e depois da evacuação durante o exame de cindefecografia.

Métodos: Foram selecionadas 32 pacientes consecutivas do sexo feminino, portadoras de disquezia, com indicação clínica de investigação por cindefecografia. A mediana de idade

Palavras-chave:

Bário

Constipação intestinal

Defecografia

Reto

* Corresponding author.

E-mail: jupfont@gmail.com (J.P. Fontana).

<https://doi.org/10.1016/j.jcol.2018.10.008>

2237-9363/© 2018 Published by Elsevier Editora Ltda. on behalf of Sociedade Brasileira de Coloproctologia. This is an open access article under the CC BY-NC-ND license (<http://creativecommons.org/licenses/by-nc-nd/4.0/>).

da amostra foi 58 anos (18-78 anos, média de 55 anos). Durante o exame de cinedefecografia, calcularam-se as áreas retais pela secção sagital antes e após a defecação e, assim, o percentual de redução da área retal. O percentual de redução do peso do contraste baritado foi calculado após medidas de peso do contraste injetado no reto e da quantidade de contraste evacuado, em gramas, utilizando uma balança. Por fim, os percentuais foram comparados e verificou-se se havia correlação entre eles. Para análise estatística, foram utilizados correlação de Pearson (r) e t de Student.

Resultados: Foi observada correlação entre o contraste baritado evacuado e a área retal pela secção sagital ao final da evacuação ($r=0.668$; $p<0.0001$).

Conclusões: É possível estimar o percentual de contraste baritado evacuado através da análise da variação da área retal pela secção sagital antes e após a evacuação, utilizando a cinedefecografia.

© 2018 Publicado por Elsevier Editora Ltda. em nome de Sociedade Brasileira de Coloproctologia. Este é um artigo Open Access sob uma licença CC BY-NC-ND (<http://creativecommons.org/licenses/by-nc-nd/4.0/>).

Introduction

Constipation affects up to 12.8%¹ of the U.S. adult population. This rate can vary a lot depending on eating habits, comorbidities, and physical activity. Dyschezia or intestinal constipation associated with dyschezia reported in up to 31% of the adult western population, which has at least four monthly episodes of intense straining while defecating.²

The technique of cinedefecography (CD) has become more popular after the standardization suggested by Mahieu et al.³ It consists of a radiological examination using contrast medium that is injected into the rectum (barium paste), anal canal, and vagina. It enables the dynamic evaluation of these structures and makes it possible to analyze their relationship with pelvic bone landmarks.

CD provides objective data for the differential diagnosis between several different causes of dyschezia, namely: rectocele, enterocele, sigmoidocele, Descending Perineum Syndrome (DPS), Rectal Mucosal Prolapse (RMP), Rectoanal Intussusception (RAI), Rectal Prolapse (RP), Paradoxical Puborectalis Contraction (PPC). CD also makes it possible to compare video stills of the anorectal angle, anorectal junction movement, and rectovaginal distance at rest, during contraction and straining. Post-toilet residual barium paste can be demonstrated.⁴

CD was first introduced by Burhenne, who initially described it as "Intestinal Evacuation Study".⁵ By this time, other authors used the term "defecography" to describe the technique of dynamic assessment of defecation using fluoroscopy in studies conducted in children and adults.^{6,7}

In 1984, Mahieu et al.³ described the currently used technique, which they called "defecography". This technique was different from the previous procedures because it was as similar as possible to the physiological simulation of defecation.

Since then, several variations and technical changes have been described, such as the use of contrast in the vagina, bladder, and rectum simultaneously,⁸ as well as contrast in the pouch of Douglas, with the emergence of terms like "colpocysto-defecography", "fluoroscopy" and "peritoneography".⁹ Technical variations, such as new alternative positioning and contrast media, have also been described.¹⁰

Nevertheless, despite the reproducibility and importance of CD for therapeutic decisions, there is considerable controversy about the correlation between certain objective or subjective findings and the diagnosis of the different causes of dyschezia.¹¹ Some of the reasons for this controversy are the different methods for measuring the size of a rectocele or even the importance of assessing the changes of the anorectal angle during defecation when compared to it at rest for the diagnosis of PPC.¹²⁻¹⁴ It is possible that new objective parameters may improve the clinical applicability of CD.

We propose a new parameter that is obtained by using free software to analyze still images obtained before and after evacuation. Even though calculating the amount of barium paste evacuated during CD is not an innovation, considering it demanded proprietary and unavailable technologies, this study addresses this issue to make it accessible in a clinical setting.

Methods

This is a prospective, non-randomized, single-center clinical trial. The study was conducted at the Coloproctology, specifically at the outpatient clinic of anorectal physiology and Radiology Units of a tertiary hospital with dyschezia and clinical indication for CD. Data collection was carried out in March 2016, and 32 female patients underwent CD. All procedures performed in studies involving human participants were in accordance with the ethical standards of the institutional research committee and with the 1964 Helsinki declaration and its later amendments or comparable ethical standards. Informed consent: Informed consent was obtained from all individual participants included in the study.

Female patients with dyschezia, complaining of symptoms such as digitation, straining, incomplete evacuation, vaginal bulge, vaginal weight after defecating, who agreed to participate in the study Patients with fecal incontinence and/or who refused to sign the consent form, patients without clinical indication for CD, pregnant women or those with suspected pregnancy, patients who could not undergo radiological tests, and patients who underwent previous surgery of the rectum were excluded from the study.

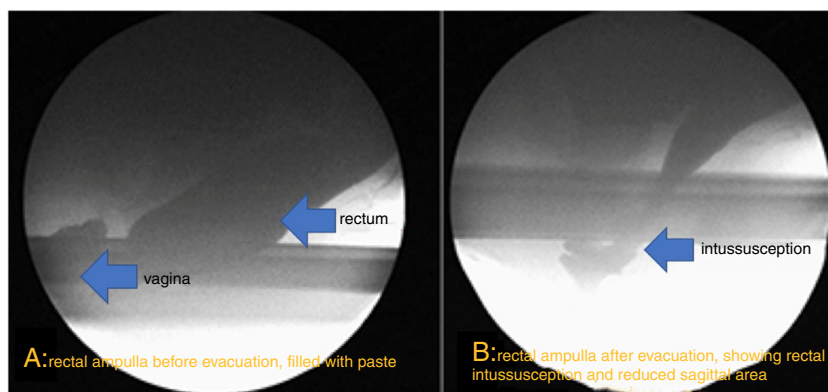


Fig. 1 – Video stills before and after defecation.

CD consisted of the following steps: a barium contrast agent was prepared on the day of the imaging study using 200 mL of warm water, 100 g of cornstarch powder, and 75 mL of barium sulfate, which resulted in a paste. This paste was slowly heated for 12 min to become thicker. The same tools and instruments were used to prepare the contrast to ensure homogeneous consistency in all samples of barium paste. After the paste cooled down, the amount of contrast needed to perform the imaging test was placed in a 350 mL tube.

In the morning of the day of the imaging study, a phosphate enema rectal cleansing was performed. Patients were also given oral barium contrast (Bariogel[®], Laboratório Cristalia, Nova Itapira, SP, Brazil) 1 h before the test so that there was contrast in the small bowel during the exam. Bladder, intraperitoneal, or double-sigmoid contrasts were not used. The patients were taken to a private room, where the procedures were explained and doubts were clarified.

Next, the patients laid on left lateral decubitus position for injection of barium paste. Vaginal and anal introitus were lubricated using lidocaine 2% gel (Lidogel[®], Brainfarma, Anápolis, GO, Brazil). Gauze soaked in iodinated contrast (Hypaque[®], Sanofi, Suzano, SP, Brazil) was placed in the patients' vagina. Barium paste was injected into the rectum until it elicited defecation sensation or until insertion of 350 mL; the applicator was gradually withdrawn, making sure that the anal canal was opacified. Contrast excess was removed using moist gauze dressings. These dressings were weighed and considered to calculate the weight of the contrast injected.

A wooden seat covered with a plastic toilet seat cover was used to simulate the usual residential toilet, featuring the same distance for feet support as the ones found in standard toilets. Patients were instructed to sit on the toilet. The X-Ray source was positioned on the left side of the bony pelvis and a fluoroscopic receiver was positioned to the right of the patient. A ruler featuring radiopaque markers was then positioned and secured so as to be displayed on the video signal to calculate the areas.

The dynamic assessment was performed during the contraction and defecation maneuvers. Video recording was

essential so that images could be reviewed and the exact times of the beginning and end of defecation could be selected. Video stills of these images were captured and stored as digital image files (Fig. 1). These files were evaluated and the following data were recorded to be included on the test report: (a) relaxation of the puborectalis muscle during defecation; (b) bulging in the anterior rectal wall (rectocele); (c) barium paste retention in the rectum and/or rectocele at the end of defecation; (d) changes in the mucosal projection or filling failure typical of mucosal prolapse or RAI; (e) enlargement of the rectovaginal distance at rest and during defecation and/or posterior extrinsic bulging of the anterior rectal wall (peritoneocele or sigmoidocele), and extension of a portion of the small bowel into the rectovaginal space (enterocele); (f) increased mobility of the anorectal junction during defecation (suggestive of DPS); (g) posterior rectal bulging (posterior perineal hernias).

The images were recorded using real-time digital fluoroscopy. A radiological device of remote controlled fluoroscopy (Plus[®] Pulsar, VMI, Lagoa Santa, MG, Brazil) and image recording equipment were used to store digital image files in a personal computer (Apple Computers[®], Cupertino, CA, USA).

Data collection consisted of comparing the weight of contrast before and after defecation using a Q510-3200C scale (Quimis[®], Diadema, SP, Brazil), considering the weight in grams (disregarding fractions). The percentage of evacuated contrast was calculated according to this formula: $B - b/L - l \times 100$, where "B" was the weight in grams of the contrast tube before injection into the rectum; "b" was the weight in grams of the contrast tube after injection into the rectum (including any discarded waste after contrast injection); "L" was the weight in grams of the collecting container after defecation; and "l" was the weight in grams of the collecting container before defecation. Then the percentage of evacuated contrast was measured based on the weight before and after defecation.

Next, two video stills were captured, one at the beginning of the defecation and another one at the end of the defecation. These images were digitally processed using an image analysis free software (Analyzing Digital Images[®] - Museum of Science, Boston, MA, USA); therefore, it was possible to calculate the rectal area of the sagittal section measured in cm². The percentage of evacuated contrast was calculated according to

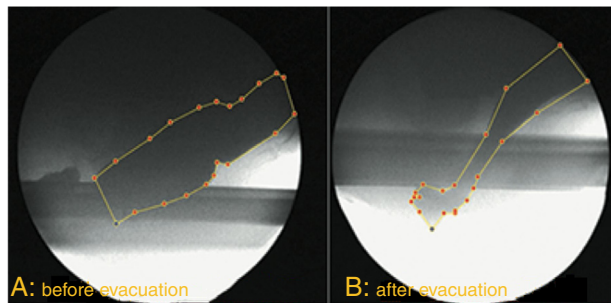


Fig. 2 – Marking of areas on video stills before and after defecation.

this formula: $H - h/H \times 100$, where “H” was the sectional area before defecation and “h” was the sectional area after defecation (Fig. 2). We called the amount of barium paste evacuated, in percentage, “Defecation Fraction”.

After calculating the percentage of evacuated barium paste according to the criteria of weight and analysis of area per image, their correlation was assessed using Student’s t test and Pearson’s correlation. *p*-values <0.05 were considered statistically significant. The previously calculated sample size was at least 30 patients. The statistical analyses were performed using the Statistical Package for the Social Sciences (SPSS) for Windows, version 22.0 (IBM Corp., Armonk, NY, USA).

Results

Our sample consisted of 32 female patients whose median age was 58 years old. First, we estimated the mean and standard deviations of the following variables: defecation area and evacuated weight. These results are shown in Table 1, whereas the dispersion of the results is shown in Fig. 3. Table 1 shows mean evacuated weight (X) and mean reduction of CSSRA (Y), as well as their respective standard deviations.

Fig. 3 shows the test results and the linear regression line obtained by adjusting data. As for the results of Pearson’s correlation, the variables had a positive correlation, where the *r* value was 0.668 and the *p*-value was <0.0001.

Discussion

Morphological examinations, such as rectosigmoidoscopy and barium enema, can detect anatomical abnormalities of the rectum, whereas functional assessment requires dynamic studies that demonstrate the physiological processes involved in defecation.¹⁵

CD makes it possible to capture images of the pelvic dynamics during defecation, thus providing the basis for the diagnosis of functional disorders, such as DPS, evaluating anatomical details, such as rectocele, RAI, and enterocele. In addition, defecation can be evaluated, which may help differentiate physiological anatomical findings from functional disorders. Defecographic anatomical findings, particularly mild rectocele or intussusception, are frequent in asymptomatic patients. The difficulty of distinguishing these abnormalities may easily lead to misdiagnosis and unnecessary treatments. Therefore, therapeutic decisions should not be based only on tests. It is important to consider the clinical context as well.¹⁵

Because there has been a better understanding of the physiology of anorectal dynamics in recent decades, CD has been considered a useful method for the assessment of defecation disorders in clinical practice.¹⁶ CD makes it possible to monitor the whole defecation dynamics and pelvic floor disorders. The images captured during the exam can also be recorded for later reassessment if necessary; therefore, CD is considered to be “gold standard” in the diagnosis of dyschezia.^{17–19} However, failure in viewing the anatomy of the structures involved in this mechanism may lead to false diagnoses depending on the expertise of the examiner and the quality of the images. Another disadvantage is the fact that CD exposes patients to ionizing radiation, thus, it should be avoided in suspected or known pregnancy.¹⁶

In addition, CD has some limitations considering the evaluation of RAI, because it may be difficult to distinguish between this condition and the folds of normal mucosa of the rectal wall during straining.²⁰ CD may also be limited to evaluate PPC because defecographic markers are not always present in patients whose Electromyography (EMG) suggests PPC and vice-versa.^{21,22}

Therefore, it would be desirable that new defecographic parameters could improve the accuracy of CD in the evaluation of the several different causes of dyschezia.

The present study suggests a technical change in the current CD protocols, and its purpose is to validate a new defecographic parameter using a free, user friendly, easy to assimilate and fast computerized application to assess the variation of the contrasted area of the rectum and showing its correlation to the percentage of evacuated barium contrast. Further studies should evaluate this parameter considering different pelvic floor disorders in order to determine its clinical relevance and usefulness in the study of dyschezia.

Assessing the clinical utility of this new parameter was not the aim of this study. The next step is to correlate it with different causes of dyschezia. Our group is currently working on it.

Table 1 – Mean and standard deviation of CD variables.

No. of patients	Mean of X	Mean of Y	Standard deviation of X	Standard deviation of Y
32	72.35	48.23	26.85	29.59

X, percentage of evacuated weight; Y, percentage of sagittal area reduction; CD, cinedefecography.

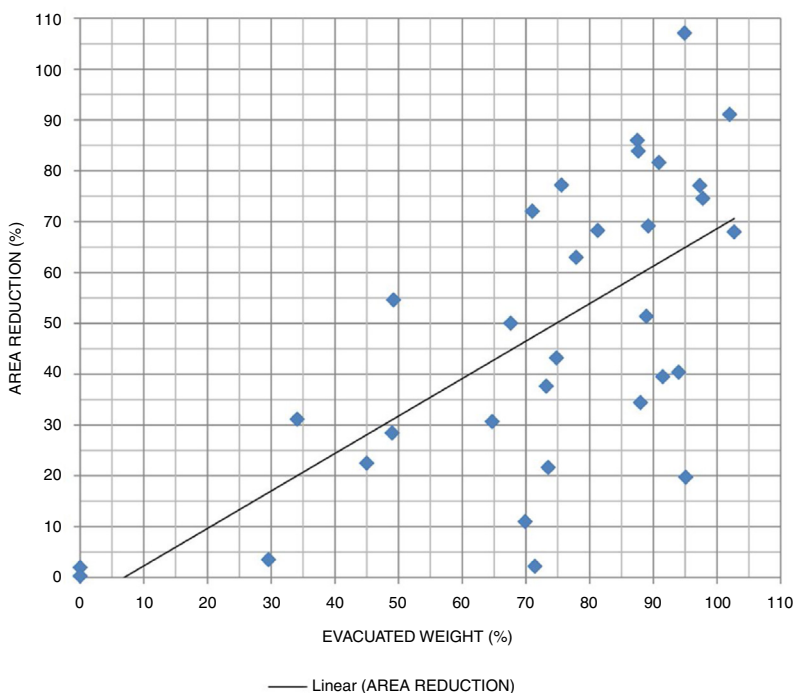


Fig. 3 – Dispersion of evacuated weight and mean reduction of cross-sectional sagittal rectum area and its regression line.

Conclusion

It is possible to estimate how much barium paste is evacuated based on the variations in cross-sectional sagittal area of the rectum before and after defecation, in CD. Further studies evaluating specific conditions that may lead to dyschezia are needed in order to address its clinical usefulness.

Conflicts of interest

The authors declare no conflicts of interest.

REFERENCES

- Sandler RS, Jordan MC, Shelton BJ. Demographic and dietary determinants of constipation in the US population. *Am J Public Health*. 1990;80:185–9.
- Dent OF, Goulston KJ, Zubrzycki J, Chapuis PH. Bowel symptoms in an apparently well population. *Dis Colon Rectum*. 1986;29:243–7.
- Mahieu P, Pringot J, Bodart P. Defecography: I. Description of a new procedure and results in normal patients. *Gastrointest Radiol*. 1984;9:247–51.
- Sobrado CW, Pires CEF, Amaro E, Cerri GG, Habr-Gama A, Kiss DR. Videodefecografia: aspectos técnicos atuais. *Radiol Bras*. 2004;37:283–5.
- Burhenne HJ. Intestinal evacuation study: a new roentgenologic technique. *Radiol Clin*. 1964;33:79–84.
- Brown BS. Defecography or anorectal studies in children including cinefluorographic observations. *J Can Assoc Radiol*. 1965;16:66–76.
- Broden B, Snellman B. Procidencia of the rectum studied with cineradiography. A contribution to the discussion of causative mechanism. *Dis Colon Rectum*. 1968;11:330–47.
- Hock D, Lombard R, Jehaes C, Markiewicz S, Penders L, Fontaine F, et al. Colpocystodefecography. *Dis Colon Rectum*. 1993;36:1015–21.
- Lopez A, Anzen B, Bremmer S, Kierkegaard J, Mellgren A, Zetterstrom J, et al. Cystodefecoperitoneography in patients with genital prolapse. *Int Urogynecol J Pelvic Floor Dysfunct*. 2002;13:22–9.
- Altringer WE, Saclarides TJ, Dominguez JM, Brubaker LT, Smith CS. Four-contrast defecography: pelvic “floor-oscopy”. *Dis Colon Rectum*. 1995;38:695–9.
- Mellgren A, Bremmer S, Johansson C, Dolk A, Uden R, Ahlback SO, et al. Defecography. Results of investigations in 2,816 patients. *Dis Colon Rectum*. 1994;37:1133–41.
- Shorvon PJ, McHugh S, Diamant NE, Somers S, Stevenson GW. Defecography in normal volunteers: results and implications. *Gut*. 1989;30:1737–49.
- Coremans GE. Surgical aspects of severe chronic non-Hirschsprung constipation. *Hepatogastroenterology*. 1990;37:588–95.
- Johansson C, Nilsson BY, Holmstrom B, Dolk A, Mellgren A. Association between rectocele and paradoxical sphincter response. *Dis Colon Rectum*. 1992;35:503–9.
- Jorge JM, Habr-Gama A, Wexner SD. Clinical applications and techniques of cinedefecography. *Am J Surg*. 2001;182:93–101.
- Faccioli N, Comai A, Mainardi P, Perandini S, Moore F, Pozzi-Mucelli R. Defecography: a practical approach. *Diagn Interv Radiol*. 2010;16:209–16.
- Karlbom U, Nilsson S, Pahlman L, Graf W. Defecographic study of rectal evacuation in constipated patients and control subjects. *Radiology*. 1999;210:103–8.
- Spazzafumo L, Piloni V. Rectal constipation and clinical decision-making: multiple correspondence analysis of defecographic findings. *Tech Coloproctol*. 1999;3:117–21.
- Chen HH, Iroatulam A, Alabaz O, Weiss EG, Noguera JJ, Wexner SD. Associations of defecography and physiologic

- findings in male patients with rectocele. *Tech Coloproctol*. 2001;5:157-61.
20. Ihre T, Seligson U. Intussusception of the rectum-internal proclentia: treatment and results in 90 patients. *Dis Colon Rectum*. 1975;18:391-6.
 21. Wexner SD, Marchetti F, Salanga VD, Corredor C, Jagelman DG. Neurophysiologic assessment of the anal sphincters. *Dis Colon Rectum*. 1991;34:606-12.
 22. Johansson C, Ihre T, Holmstrom B, Nordstrom E, Dolk A, Broden G. A combined electromyographic and cineradiologic investigation in patients with defecation disorders. *Dis Colon Rectum*. 1990;33:1009-13.