



Case Report

Multiple approaches to sexually transmitted infections: from diagnosis to treatment



José Antonio Dias da Cunha e Silva^{a,*}, Marcus Valadão^b, Antonio Carlos Iglesias^c

^a Titular Sociedade Brasileira de Coloproctologia, Rio de Janeiro, RJ, Brazil

^b Instituto Nacional de Câncer (INCA), Grupo Colorretal, Rio de Janeiro, RJ, Brazil

^c Universidade Federal do Estado do Rio de Janeiro (UNIRIO), Hospital Universitário Gaffrée e Guinle (HUGG), Rio de Janeiro, RJ, Brazil

ARTICLE INFO

Article history:

Received 23 July 2018

Accepted 6 November 2018

Available online 14 December 2018

Keywords:

Papillomaviridae

Infeção

Podophyllin

HIV

Palavras-chave:

Papillomaviridae

Infecção

Podofilina

HIV

ABSTRACT

Sexually transmitted infections are mainly caused by viruses and bacteria. They are transmitted through sexual intercourse, without a condom, with an infected individual. The anus, vagina, and mouth may become involved. This study aimed to present six clinical cases with the diagnosis of sexually transmitted infections, but in which different treatment approaches were required. This demonstrates the dynamic and unique character of the disease in each individual. That is, the behavior of sexually transmitted infections will vary not only according to its causative microorganism (virus or bacteria), but also according to the characteristics of the combination of etiologic agent and host.

© 2018 Sociedade Brasileira de Coloproctologia. Published by Elsevier Editora Ltda. This is an open access article under the CC BY-NC-ND license (<http://creativecommons.org/licenses/by-nc-nd/4.0/>).

Múltiplas formas de abordagem para as infecções sexualmente transmissíveis: do diagnóstico ao tratamento

RESUMO

As infecções sexualmente transmissíveis são causadas, principalmente, por vírus e bactérias. Por meio do contato sexual, sem preservativo, com um indivíduo que esteja infectado. O ânus, a vagina e a boca podem se tornar órgãos acometidos. O objetivo deste trabalho é apresentar 06 casos clínicos com o diagnóstico de infecções sexualmente transmissíveis, mas que para serem tratados foram necessárias diferentes abordagens. Isso demonstra o caráter dinâmico e singular da doença em cada indivíduo. Ou seja, o comportamento

* Corresponding author.

E-mail: joseantoniocunha@yahoo.com.br (J.A. Cunha e Silva).

<https://doi.org/10.1016/j.jcol.2018.11.002>

2237-9363/© 2018 Sociedade Brasileira de Coloproctologia. Published by Elsevier Editora Ltda. This is an open access article under the CC BY-NC-ND license (<http://creativecommons.org/licenses/by-nc-nd/4.0/>).

das infecções sexualmente transmissíveis vai variar não somente conforme o seu microrganismo causador (vírus × bactéria), mas também de acordo com o conjunto (agente etiológico + hospedeiro).

© 2018 Sociedade Brasileira de Coloproctologia. Publicado por Elsevier Editora Ltda. Este é um artigo Open Access sob uma licença CC BY-NC-ND (<http://creativecommons.org/licenses/by-nc-nd/4.0/>).

Introduction

Sexually transmitted infections (STIs) are mainly caused by viruses and bacteria. They are transmitted through sexual intercourse, without a condom, with an infected individual. The anus, vagina, and mouth may become involved.

The STI terminology used by the World Health Organization (WHO) has been adopted by the Brazilian Ministry of Health since November 2016, replacing the term sexually transmissible disease (STD), because it incorporates the possibility of a person having and transmit these infections despite the absence of signs and symptoms.¹

Treatment of STI patients interrupts the transmission chain of these pathogens; moreover, it also solves a problem that causes physical and psychological distress to patients.^{1,2}

This study aimed to present six clinical cases with the diagnosis of STI, but in which different treatment approaches were required. This demonstrates the dynamic and unique character of the disease in each individual. That is, the behavior of IST will vary not only according to its causative microorganism (virus or bacteria), but also according to the characteristics of the combination of etiologic agent and host.

Case 1

FBB, female, young, married, complaining of “non-healing wound” searched for several medical specialties, having undergone an unsuccessful prolonged treatment with antibiotics (doxycycline and ciprofloxacin) and antiviral (acyclovir ointment).

At physical examination, she presented an extensive secretive anal ulcer, with irregular borders and extremely painful, which prevented the proctologic examination and that substantially progressed in extension in the intervals between the consultations.

Immediate HIV serology was requested, as well as a biopsy under spinal anesthesia.

In addition to confirming the initial suspicion of HIV, severe immunodepression was observed, with anemia and leukopenia: 2.5 thousand/mm³; viral load: 95.579,00 copies/mL; TCD8 lymphocytes: 293 cells/μL; and TCD4 lymphocytes: 85 cells/μL.

She also presented positive IgG serology for herpes and cytomegalovirus (CMV).

After four weeks of antiretroviral therapy (ART; dolutegravir + tenofovir + desoproxil + lamivudine), an incisional biopsy was performed. The immunohistochemical study concluded this inflammatory process of viral nature (herpetic).

Treatment with ART was maintained, and a significant elevation of lymphocytes and abrupt reduction of viral

load were observed. Oral acyclovir 3200 mg/day + fluconazole 150 mg/week were added due to the frequent fungal infection associated in these cases. Since then, the patient has presented an excellent response to medications (Fig. 1).

Case 2

HSSG, male, 3 years old, was brought to the office by his mother, who observed the presence of warts during hygiene.

At examination, he presented multiple painless small velvety papules that ranged from rosy to dark brown.

The mother reported that, since she is divorced and needs to work, her son is under the care of a close uncle for a large part of the day, which raised in the family the suspicion of sexual abuse.

From the clinical diagnosis of bowenoid papulosis, treatment with podophyllin 25% was initiated in weekly applications, until full resolution of the condition was observed at six weeks. The family was referred to a support service with infectologist, pediatrician, and social worker (Fig. 2).

Case 3

DS, male, 20 years, reported the appearance of “warts”.

The examination, he presented multiple condylomatous lesions.

All requested serologies (HIV, syphilis, hepatitis B and C, herpes, cytomegalovirus, and chlamydia) were negative.

Treatment was then initiated with podophyllin 25% in weekly applications. After the fifth week, no macroscopic lesions were observed on examination. Then, 5% imiquimod cream, which is an immune response modulator, was initiated three times a week, for eight weeks, aiming to improve the local immune response and prevent relapses.

The patient has been under clinical follow-up for six months, without evidence of new lesions (Fig. 3).

Case 4

LC, male, 60 years old, who had anal intercourses, reported rectal “bleeding” associated with “weakness”.

At the examination, he presented skin-mucous pallor, emaciation, asthenia, and a weak general condition. Proctologic examination revealed an extensive perianal lesion, hardened, infiltrating, and friable. Complementary laboratory examination indicated important anemia with the need of transfusion of blood products in the preoperative period.

In surgical center, under spinal anesthesia, and in jack-knife position, the patient underwent an incisional biopsy that

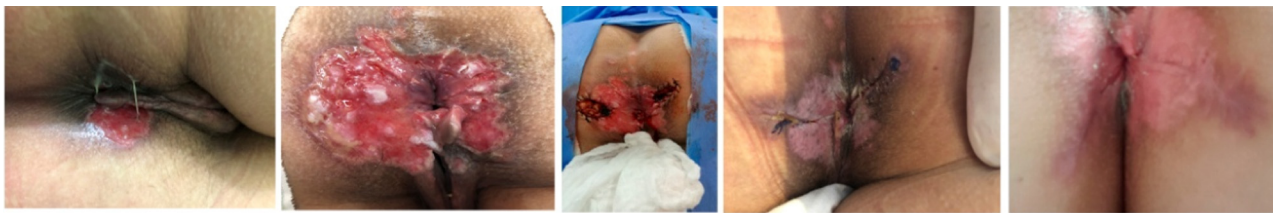

Fig. 1 – Progression of the lesion in a short interval of time; the operative act; and outpatient follow-up.

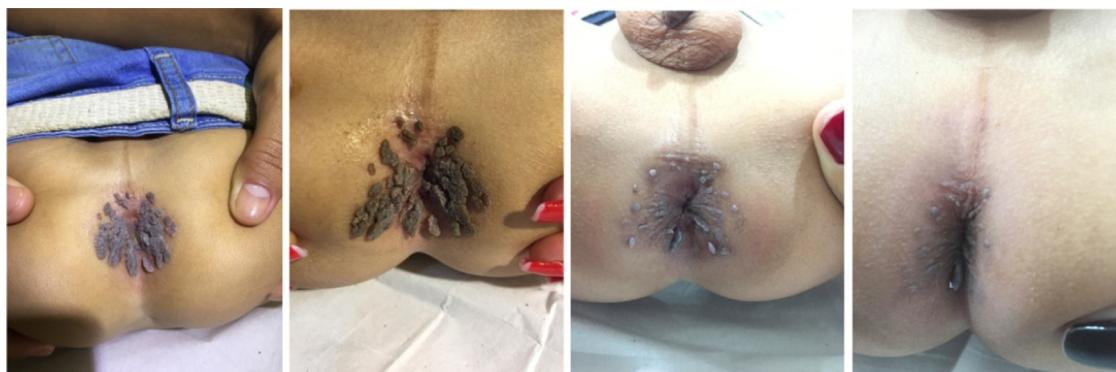

Fig. 2 – Good clinical evolution with the use of a topical chemical agent that is very well tolerated by children.

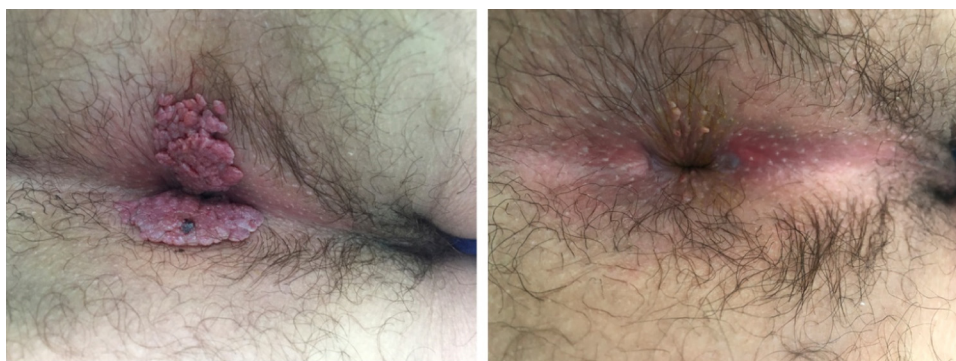


Fig. 3 – Image on the day of diagnosis and then after the fifth week.

concluded that the lesion was an epidermoid carcinoma of the anus.

The patient was then referred to a clinical oncology team, who initiated a radio- and chemotherapy protocol, with good clinical response. The lesion size decreased and the bleeding stopped. The patient is still under treatment (Fig. 4).

Case 5

SI, male, 30 years old, reported sexual abuse in adolescence, and noticed the presence of anal warts.

The proctologic examination presented multiple condylomatous lesions that covered the anus and perianal skin.

Clinical local treatment was initiated with podophyllin 25% (this is the authors first choice among the chemical agents for eradication of genital warts, except in pregnant women, in whom it is contraindicated); but that was unsuccessful.

The use of 90% trichloroacetic acid (TCA) was also unsuccessful. Thus, surgical excision was required to remove the lesions.

Given the great extent of the lesion and the risk of complications, such as anal stricture due to an excessively wide surgical resection, the authors opted for a two-step operation, associating resections with marsupialization of the wound edges and electrofulguration.

In the wound healing process, the authors periodically performed digital anal dilatation; after complete closure of the surgical wound, imiquimod was used for eight weeks (HIV negative serology) aiming to improve the local immune response and avoid relapses.

At the 18th month of follow-up, at physical examination, a small condylomatous lesion was observed in the anus, and was promptly cauterized with an electric scalpel under local anesthesia with 2% lidocaine. The patient is under a semi-annual outpatient follow-up (Fig. 5).

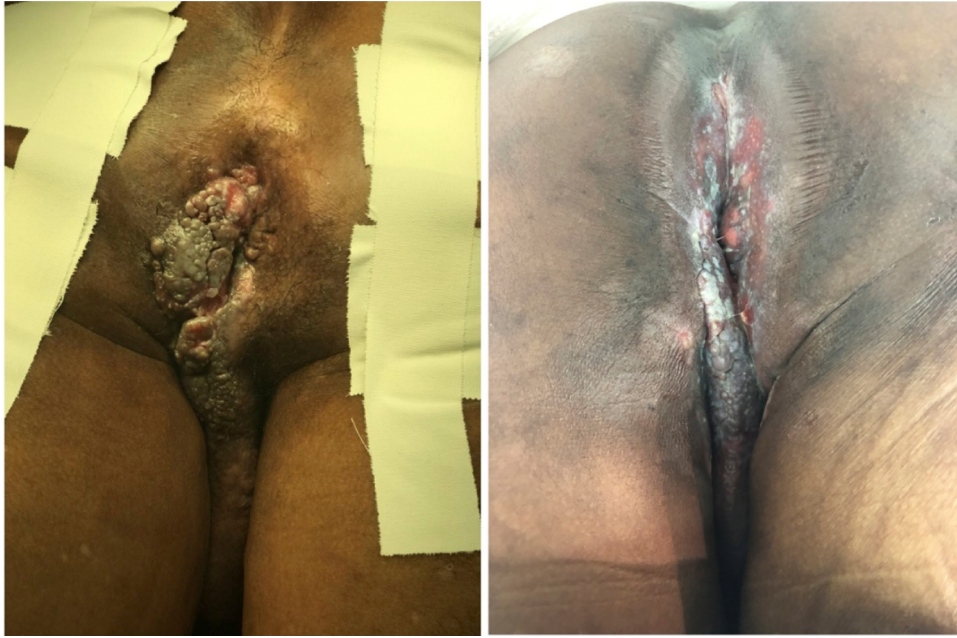

Fig. 4 – Squamous cell carcinoma of the anus at diagnosis and after radiotherapy and chemotherapy.

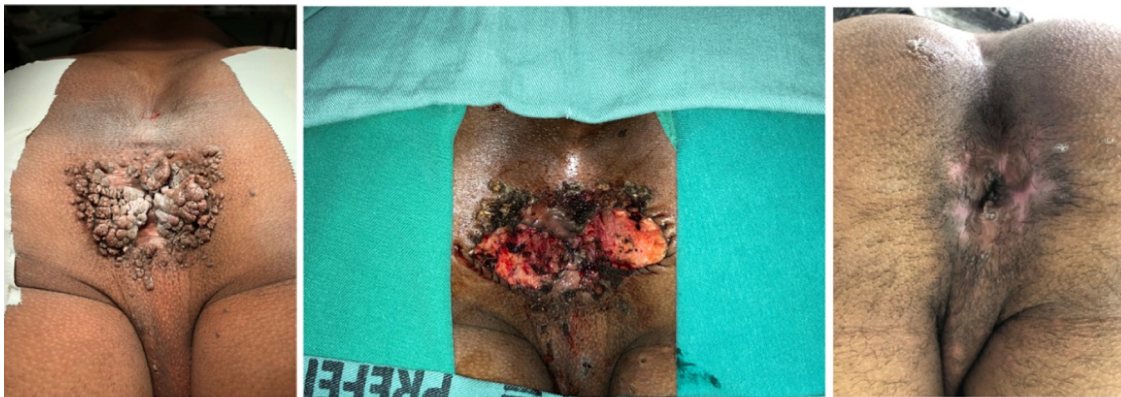

Fig. 5 – Extensive perianal lesion refractory to topical clinical treatment; second surgery; and current final aspect.

Case 6

WI, male, 35 years old, presented genital warts in his penis and testicular pouch.

This case is similar to the previous one, because it was also a case of condylomatous lesions in a young male patient that was also refractory to treatment with a topical chemical agent, requiring surgical excision. The divergence in the latter two cases was the affected site.

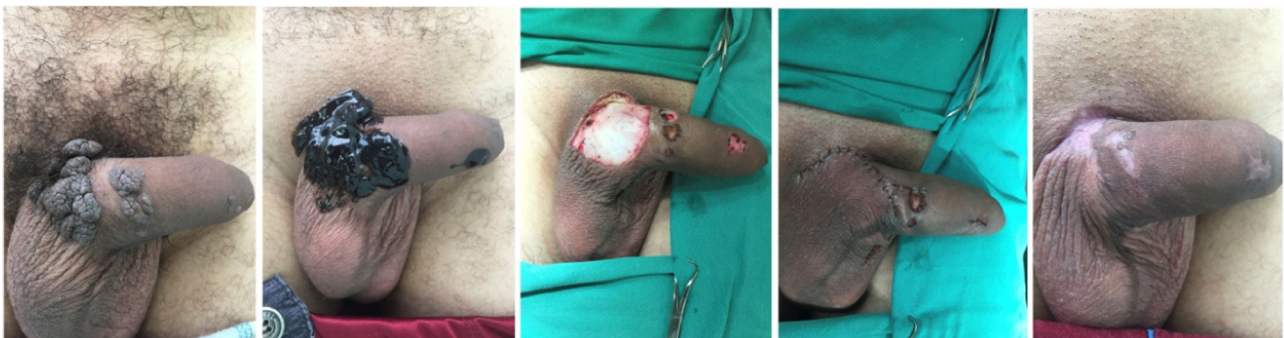

Fig. 6 – Condylomatous lesion on genitalia; application of podophyllin 25%; surgical excision; operative aspect; and current aspect.

After surgical resection, the patient is clinically well without new lesions, with approximately two years of follow-up (Fig. 6).

Discussion

With a series of clinical cases, this study aimed to illustrate the different clinical forms of STI manifestation and the influence of these different presentations on the treatment of choice.

At present, wide surgical resections, which expose patients who are already fragile and stigmatized by the disease to the possibility of other complications, are no longer the only alternative to treat STIs.

STI treatments range from the use of antibiotics, antivirals, chemical agents, physical destruction, immunological therapy (including vaccination), and surgical excision.²⁻⁴

The choice of the best method of treatment depends on several factors, not only the number, extent, and location of the lesions; it should be based on how the condition presents itself in each patient.

In this series of cases, it is important to highlight two agents that were used as part of the therapeutic arsenal, podophyllin and imiquimod, either as main drug or as an adjuvant.⁵

Podophyllin is an agent with antimitotic and caustic activity. It is mainly used in the topical treatment of anogenital warts and condyloma acuminatum, and applied in the form of solutions. It can be used in concentrations of 5% to 30%, within a period of up to six weeks. It is also used in the form of ointments, alone or in association with other keratolytics, for the elimination of warts. Due to its teratogenic action, it is not indicated in pregnant women. The risk of systemic toxicity increases after topical application at high concentrations in large areas with for prolonged periods; in the treatment of warts that rupture, bleed, or have undergone recent biopsy; and in applications to healthy skin or mucous membranes. Moreover, it is highly irritating to eyes and mucous membranes; these areas should always be protected when the drug is applied near them.⁵

In turn, imiquimod is a modulator of the immune response. Studies suggest that there is a membrane receptor for imiquimod in immune cells in which a response is observed.

This drug has no direct antiviral activity. In animal models, imiquimod is effective against viral infections and acts as an antitumor agent, mainly by inducing interferon alpha and other cytokines. This induction after imiquimod application in genital warts tissue has also been demonstrated in clinical studies. Increases in the systemic concentration of interferon alpha and other cytokines after topical application of imiquimod have been demonstrated in a pharmacokinetic study. *In vitro* studies have shown that imiquimod has no direct antiviral activity; however, the drug exhibits antiviral and antitumor effects *in vivo*. A study including 22 patients compared imiquimod with vehicle and showed that it induces cytokine-coding mRNA, including alpha interferon, at the treatment site. Moreover, the HPV L1 mRNA and HPV DNA counts are significantly lower after treatment.^{5,6}

This series reinforces the fact that treatment should be, above all, individualized.

Conflicts of interest

The authors declare no conflicts of interest.

REFERENCES

1. Nadal SR, Manzione CR. Identificação dos grupos de risco para as doenças sexualmente transmitidas. *Rev Bras Coloproctol.* 2003;23:128–9.
2. Nadal SR, Manzione CR. Manejo dos portadores das neoplasias intraepiteliais anais. *Rev Bras Coloproctol.* 2008;28:462–4.
3. Nadal SR, Formiga FB, Manzione CR. Papulose bowenóide – um aspecto clínico da infecção pelo HPV. *Rev Bras Coloproctol.* 2009;29:505–7.
4. Nadal SR, Manzione CR. Uso do colposcópico para avaliar a região perianal e o canal anal. Padronização técnica e indicações. *Rev Bras Coloproctol.* 2004;24:379.
5. Veneroso CDC, Silva CCF, Silva NMG, Mesquita VAC, Barbi RR, Coutinho JRH, et al. Tratamento de condilomas gigantes com medicação tópica: relato de casos. *J Coloproctol (Rio J).* 2017;37 Suppl. 1:73–176, <http://dx.doi.org/10.1016/j.jcol.2017.09.154>.
6. Taglietti PM, Batista RMSS, Junior SA, Lopes A, Bezerra TS, Filho PRS, et al. Tumor de Buschke-Lowenstein; 2017, <http://dx.doi.org/10.1016/j.jcol.2017.09.149>.