





Original Article

Standardization of endometriosis surgery – the
coloproctologist's vision

Barbara Pereira Lara^a, Karina Correa Ebrahim^a, Univaldo Etsuo Sagae^{a,b,c,d},
Gustavo Kurachi ^{a,b,c}, Francisco Sérgio Pinheiro Regadas^{e,f,g,h},
Sthela Maria Murad Regadas^e, Doryane Maria dos Reis Lima ^{a,b,c,*}

^a Fundação Hospitalar São Lucas, Cascavel, PR, Brazil

^b Gastroclínica Cascavel, Cascavel, PR, Brazil

^c Centro Universitário da Fundação Assis Gurgacz, Cascavel, PR, Brazil

^d Universidade do Oeste do Paraná, Cascavel, PR, Brazil

^e Universidade Federal do Ceará (UFC), Faculdade de Medicina, Fortaleza, CE, Brazil

^f Sociedade Brasileira de Coloproctologia, Rio de Janeiro, RJ, Brazil

^g Colégio Brasileiro de Cirurgia Digestiva (CBCD), Colégio Brasileiro de Cirurgiões (CBC), São Paulo, SP, Brazil

^h American Society of Colon and Rectal Surgeons, York Township, United States

ARTICLE INFO

Article history:

Received 28 August 2018

Accepted 10 February 2019

Available online 12 April 2019

Keywords:

Endometriosis

Ultrasonography

Laparoscopy

Colorectal surgery

ABSTRACT

Objective: To demonstrate the standardization of deep endometriosis surgery with intestinal involvement.

Methods: Prospective study evaluating 74 women undergoing standardized surgery for deep intestinal endometriosis. Divided into two groups, according to the findings of three-dimensional anorectal ultrasound, Group I with lesions affecting perirectal fat and Group II with lesions affecting at least the muscular layer of the rectum.

Results: There was no statistically significant difference between the groups in relation to the size of the focus and the distance of the lesion to the puborectalis muscle ($p > 0.05$). The type of surgery performed was laparoscopy without lesions in one patient (1.35%), disk resection in 13 patients (17.56%), shaving in 45 patients (60.81%), and rectosigmoidectomy in 15 patients (20.27%). The complications were bleeding from the drain with conservative treatment in three patients (4.05%), fistula in two patients submitted to the shaving method (2.70%), and three patients (4.05%) with lower anterior resection syndrome (LARS), with improvement from conservative treatment. Lesions in other organs were also observed during videolaparoscopy.

Conclusion: Surgical standardization is important to guide the general/colorectal surgeon in the effective approach of intestinal endometriosis.

© 2019 Published by Elsevier Editora Ltda. on behalf of Sociedade Brasileira de Coloproctologia. This is an open access article under the CC BY-NC-ND license (<http://creativecommons.org/licenses/by-nc-nd/4.0/>).

* Corresponding author.

E-mail: doryane@gmail.com (D.M. Lima).

<https://doi.org/10.1016/j.jcol.2019.02.003>

2237-9363/© 2019 Published by Elsevier Editora Ltda. on behalf of Sociedade Brasileira de Coloproctologia. This is an open access article under the CC BY-NC-ND license (<http://creativecommons.org/licenses/by-nc-nd/4.0/>).

Padronização da cirurgia da endometriose – visão do coloproctologista

R E S U M O

Palavras-chave:
Endometriose
Ultrassonografia
Laparoscopia
Cirurgia colorretal

Objetivo: Demonstrar a padronização da cirurgia de endometriose profunda com acometimento intestinal.

Métodos: Estudo prospectivo que avaliou 74 mulheres submetidas à cirurgia padronizada para endometriose profunda intestinal. Divididas em dois grupos, segundo os achados da ultrassonografia anorretal tridimensional, o Grupo I com lesões acometendo a gordura perirretal e o Grupo II com lesões acometendo, pelo menos, a camada muscular própria do reto.

Resultados: Não houve diferença estatisticamente significativa entre os grupos em relação ao tamanho do foco e à distância da lesão ao músculo puborretal ($p > 0,05$). O tipo de cirurgia realizada foi laparoscopia sem achados da lesão em um paciente (1,35%), ressecção em disco em 13 pacientes (17,56%), *Shaving* em 45 pacientes (60,81%) e retossigmoidectomia em 15 pacientes (20,27%). As complicações encontradas foram sangramento pelo dreno com tratamento conservador em 3 pacientes (4,05%), fistula em 2 pacientes submetidas ao método de *shaving* (2,70%), 3 pacientes (4,05%) com Síndrome da Ressecção Anterior do Reto (LARS), com melhora ao tratamento conservador. Lesões em outros órgãos também foram observadas durante a videolaparoscopia.

Conclusão: A padronização cirúrgica é importante para orientar o cirurgião geral/colorretal na abordagem eficaz na endometriose intestinal.

© 2019 Publicado por Elsevier Editora Ltda. em nome de Sociedade Brasileira de Coloproctologia. Este é um artigo Open Access sob uma licença CC BY-NC-ND (<http://creativecommons.org/licenses/by-nc-nd/4.0/>).

Introduction

Endometriosis is a benign gynecological condition characterized by the formation of ectopic endometrial tissue¹ with a consequent chronic inflammatory reaction; it affects 4%–17% of women of reproductive age. Studies report that between 15% and 30% of women with endometriosis present deep infiltrative disease,² whose management can often be difficult and challenging.

Deep endometriosis is defined as endometriotic implants that penetrate >5 mm beneath the peritoneal surface.³ These implants are commonly found in the uterosacral ligaments, rectovaginal septum, or intestinal wall; they are often responsible for the patient's symptoms, which include dyspareunia, dysmenorrhea, pain during defecation, or rectal bleeding during menstruation.⁴ Rectal or rectosigmoid junction involvement indicates a severe form of deep infiltrating endometriosis that affects 5.3%–12% of women with endometriosis.⁴

Surgery may be the only appropriate treatment.⁵ Complete resection of all symptomatic lesions has been shown to be a definitive treatment of deep endometriosis.^{6,7} Treatment aims to improve the quality of life of the patient and reduce the rates of recurrence of the disease, as well as improve fertility, a situation usually confused with the persistence of injuries after incomplete surgical procedures.^{8–10}

Objective

To present the standardization of the surgical procedure for deep endometriosis with intestinal involvement performed by a colorectal surgery team.

Patients and methods

This was a prospective, observational, cross-sectional study evaluating 180 female patients with pelvic endometriosis and suspected intestinal involvement who were referred from the gynecology outpatient clinic to the Department of Coloproctology from April 2010 to August 2012. Of these, 74 patients participated in all stages and were included in the study, as their medical records were complete and included surgery details, bleeding data, and complete description of the materials. The evaluation consisted of a thorough physical examination (rectal and vaginal examination). Initially, all patients underwent three-dimensional anorectal ultrasound (3D-US, performed by a single examiner [DMRL]) and colonoscopy to evaluate the intestinal mucosa and exclude concomitant diseases. In 3D-US, the images of the endometriotic foci are characterized as heterogeneous hypoechoic areas with a larger diameter outside the rectal wall, i.e., infiltrating the intestinal wall layers from the inside out: perirectal, serosa, muscularis, submucosa, and mucosa (Fig. 1). This is illustrated in Fig. 1, which depicts an endometriotic lesion affecting all rectal wall layers (axial section, two groups). Group I (GI) consisted of 38 women with a mean age of 33.85 years, ranging from 21 to 47 years, with lesions affecting the perirectal fat. Of these, 13 had undergone prior surgery for endometriosis. Group II (GII) consisted of 36 women, with a mean age of 34.67 years, ranging from 26 to 48 years, whose images suggested endometriotic foci affecting at least the muscularis layer of the rectum. Of these, 17 had undergone prior surgery for endometriosis.

After this initial stage, in which 3D-US was used to assess the localization of the endometriosis focus in relation to the

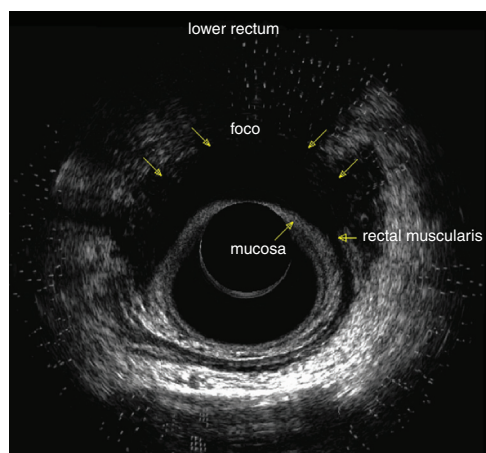


Fig. 1 – Endometriotic lesion affecting all rectal wall layers (axial section).

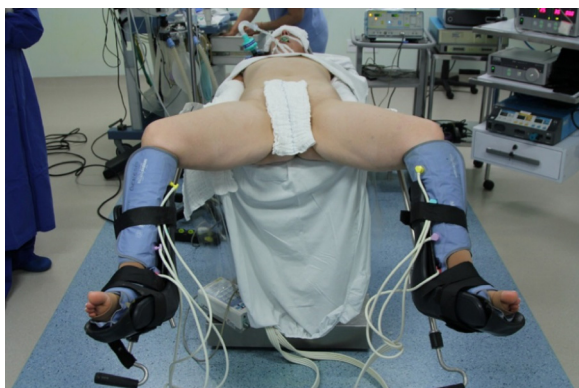

Fig. 2 – Patient positioned at the surgical table with the leg in abduction and Trendelenburg position.

stratum of the affected rectum, its distance from the puborectalis, and adjacent structures affected, patients were referred to a videolaparoscopic surgical procedure (VLP), which was performed by a multidisciplinary team. The first surgical stage was performed by two gynecologists (NC and DG) and the second surgical stage, by two colorectal surgeons (UES and GK). Intestinal preparation was performed in all women 24 h before the surgery with phospho-soda solution. All patients were operated under general anesthesia, with preoperative prophylactic antibiotic treatment and antithrombotic prophylaxis with low molecular weight heparin.

For all patients, the colorectal surgical strategy was based on the results presented by 3D-US and intraoperative surgical findings in accordance with the following protocol:

1. Correct positioning of the patient in the surgical procedure, with legs in abduction and in the Trendelenburg position (Fig. 2): the positioning of the patient during surgery is extremely important, since it allows improving the field for visualization of the structures at each surgical stage and decreases trauma to the abdominal organs.
2. Placement of the fourth trochar and complete surgical materials (Fig. 3): one 5.0 mm trochar positioned in the left iliac fossa and another one in the right

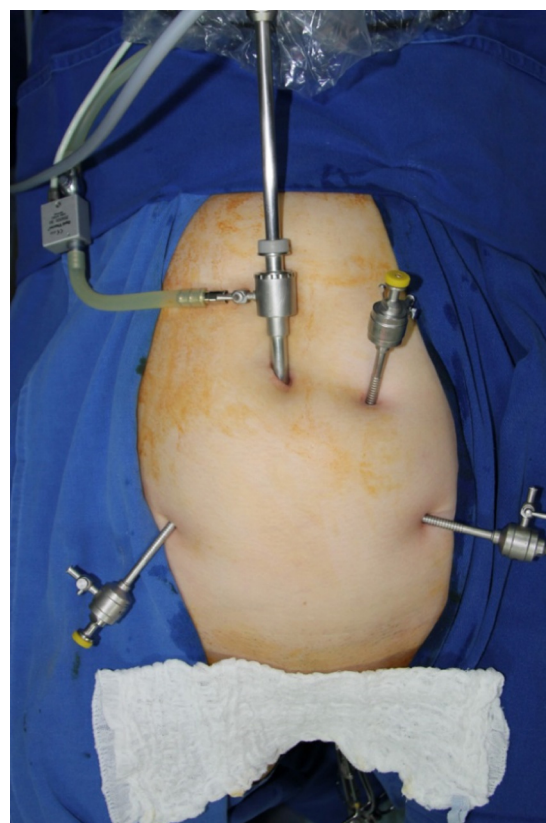


Fig. 3 – Trochar position.

3. Inventory of abdominal cavity through an assessment of the peritoneal organs in endometriosis¹¹; the small and large intestines were assessed, as well as the other intraperitoneal organs. Through this method, it is possible to evaluate all the organs, including the possibility of finding obstructive lesions not previously seen on imaging tests.
4. Routine use of the uterine and rectal manipulator: It acts as another trochar for presentation of the surgical field, mainly for visualizing the pelvic block. The rectal manipulator is used to guide the surgeon during release of the block, preventing rectal puncture or laceration, as well as decreasing the trauma in the organs involved during the procedure.
5. Isolation and ligation of the ureter: in cases of block in the ovarian fossa, it is important that it is completely released and resected using the ureter as a guide, thus preventing accidents.
6. Special care in the manipulation of gynecological organs, including presence of a gynecologist in the intraoperative period: these patients are women of childbearing age who often still have reproductive desire. The gynecological organs must be manipulated so as to avoid trauma and consequent infertility.

7. Preservation of the superior rectal artery: this is important, considering that the vast majority of the lesions are located in the middle rectum and, depending on the treatment chosen and the degree of infiltration, it is necessary to resect this segment.¹² Low anterior resection syndrome (LARS) was described in 2012 and consists of the following symptoms: fecal urgency, episodes of incontinence, increased evacuation frequency, bloating, and fecal fragmentation.¹³ This syndrome greatly harms the patients' quality of life, especially considering the young population affected. This technique aims to reduce the onset of this syndrome.
8. Proper handling of the stapler for resecting the various types of rectosigmoid infiltration: endometriosis lesions are usually anterior and there is no need to resect the total circumference of the rectum. Proper handling of the circular stapler allows simple or even double resection of the anterior wall of the rectum only.
9. Possibility of vaginal access for intraoperative palpation, manipulation, opening, and removal of surgical pieces (NOTES¹⁴): it decreases the number of abdominal incisions, for better patient recovery, and reduces surgical trauma.

Before surgery, all women gave their informed consent to a planned procedure, including bowel resection, colostomy, or ileostomy and possible laparotomy conversion, if necessary. The project was approved by the Medical Ethics Committee of Hospital Gênesis/CEDIMED under protocol No. 07 and all patients signed the informed consent term.

Statistical analyses were performed using GraphPad Prism 5.0. Data evaluations included descriptive statistical methods (mean and standard error). Student's *t*-test (non-paired) was applied to the numerical values assessed between the groups: age, size of the endometriotic focus, and distance from this focus to the puborectalis muscle. Differences were considered significant at $p < 0.05$.

Results

The mean age of the patients was 33.85 (21-48) years. All nodules were located in the anterior quadrant of the rectum. No statistically significant difference was observed between the groups regarding the size of the focus (Fig. 4) or in relation to the distance of the lesion to the puborectalis muscle (Fig. 5;




Fig. 4 – Foci size on GI and GII ($p > 0.05$).

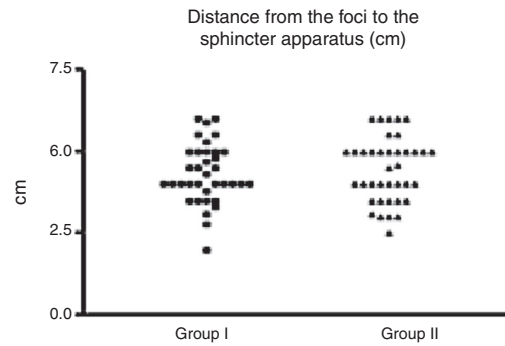


Fig. 5 – Distance from lesion to the puborectalis muscle in GI and GII ($p > 0.05$).

Student's *t*-test; $p > 0.05$). The mean time of surgery by the colorectal surgery team was 100 min.

In GI, the mean endometrial foci size was 1.97 cm, with a standard deviation of 0.70 and a standard error of 0.11. The mean distance of the lesion to the puborectalis muscle was 4.45 cm, with a standard deviation of 0.98 and a standard error of 0.15. The images from GII were characterized by the presence of heterogeneous irregular hypoechogenic masses with invasion of at least the muscular layer of the rectum. The mean GII foci size was 2.34 cm, with a standard deviation of 0.82 and a standard error of 0.13. The mean distance from the lesion to the puborectalis muscle was 4.31 cm, with a standard deviation of 0.82 and a standard error of 0.13.

The colorectal surgical procedures performed were shaving, disk resection, or rectosigmoidectomy. The surgeon made their decision based on the diameter and depth affected by the foci evidenced in 3D-US.

In addition to the gynecological organs involved and the rectum, during videolaparoscopy lesions were found in the appendix ($n = 15$), bladder ($n = 10$), sigmoid ($n = 4$), mesentery ($n = 4$), ileum ($n = 5$), cecum ($n = 3$), ureter ($n = 4$), and diaphragm ($n = 1$).

In three patients, due to ureter/bladder involvement, it was necessary to call a third surgical team (urological surgery). The colorectal surgical procedures were decided by the surgeon, based on videolaparoscopic findings and correlated with the 3D-US findings. Laparoscopy presented no lesion findings in one patient (1.35%); disk resection was performed in 13 patients (17.56%); shaving, in 45 patients (60.81%); and rectosigmoidectomy, in 15 patients (20.27%).

The use of a Penrose drain was chosen in 15% of the patients when considering both groups, with an average withdrawal time of five days. No cases required conversion to laparotomy or ostomy.

The following complications were observed: bleeding from the drain in three patients (4.05%; 3/74), treated conservatively; and fistula in two patients submitted to the shaving method (2.70%; 2/74), treated through videolaparoscopy with cavity lavage with simple raffia, drainage, and antibiotic therapy. Three patients (4.05%; 3/74) presented LARS syndrome, with improvement with clinical treatment and associated

biofeedback. The mean length of hospital stay was two days (1–5 days).

Discussion

Intestinal endometriosis is an increasingly frequent reality in clinical coloproctology practice. It predominantly affects young women, and has very peculiar characteristics, making its treatment challenging; it requires new knowledge for diagnosis and surgery, and is one of the few diseases that improves from a certain age onwards. The main goal of treatment is to maintain quality of life and reproductive desire.

Deep infiltrative endometriosis of the rectum is characterized by affecting at least the muscle layer of the rectal wall.¹⁵ It is a chronic disease that compromises the quality of life of women by causing progressive pelvic pain, dyspareunia, and digestive symptoms such as diarrhea, constipation, tenesmus, dyschezia, and painful defecation, among other symptoms.¹⁶ The rectum and the rectosigmoid junction are the preferred locations of all intestinal endometriosis sites, comprising 70%–93% of patients.¹⁷

Patients' digestive complaints can be explained by three main consequences of rectal endometriotic nodules: cyclic microhemorrhages with rectal wall inflammation, fixation of the rectum to the cervix, or rectal stenosis.¹⁸ However, most cases are asymptomatic from the gastrointestinal standpoint. Therefore, an intestinal assessment should be performed on all patients with deep pelvic disease.

Anorectal ultrasonography is a technique with good sensitivity and specificity for the visualization of rectal infiltration in patients with deep pelvic endometriosis. It should be used to define the best surgical approach.¹⁹

The treatment of intestinal endometriosis is not yet precisely established. Some groups of general surgeons/coloproctologists are on a learning curve regarding the best conduct in each case. For a long time, the management was similar to the surgical treatment of rectal cancer or even diverticular disease. Redwine et al.²⁰ reported the vaginal removal of a rectovaginal nodule and Abrão et al.²¹ reported a case of vaginal removal of the rectosigmoid segment, with stapled anastomosis. However, after many reports of immediate or late functional complications, the surgical approach to intestinal endometriosis is tending toward more economical resections. The objective of this new approach is to improve the quality of life of patients regarding pain, fertility, and decrease of LARS syndrome.^{12,13}

In cases of deep infiltrative endometriosis, surgery should be recommended, as it presents a significant improvement in all parameters of pelvic pain and quality of life.²² Laparoscopy was shown to be a viable approach in this type of procedure, and the complication rates are related to the surgeon's experience.²³

Several surgical approaches are generally adopted in the treatment of deep endometriosis of the rectum: nodule excision without opening the lumen of the rectum (shaving), removal of the nodule along with the surrounding rectal wall (disc excision), or colorectal resection of the affected segment (classic rectosigmoidectomy). However, there is no consensus in the literature about the indications for each procedure.²⁴

This study presented similar results in terms of surgical time and complications in the immediate trans- and post-operative period.^{25–29} The standardization of intestinal endometriosis surgery aims to guide and train general/colorectal surgeons on the main surgical stages.

Conclusion

The correct understanding of endometriosis affecting young women and their quality of life is critical for surgeons who aiming to treat this challenging condition. Surgical standardization is important to guide the general/colorectal surgeon in the effective approach in intestinal endometriosis, aiming to reduce risks and improve the quality of life of these patients.

Conflicts of interest

The authors declare no conflicts of interest.

REFERENCES

1. Clement MD. Diseases of the peritoneum (including endometriosis). In: Kurman RJ, editor. *Blaustein's pathology of the female genital tract*. Springer-Verlag; 2002. p. 729–89.
2. Roseau G, Dumontier I, Palazzo L, Chapron C, Dousset B, Chaussade S, et al. Rectosigmoid endometriosis: endoscopic ultrasound features and clinical implications. *Endoscopy*. 2000;32:525–30.
3. Darwish B, Roman H. Surgical treatment of deep infiltrating rectal endometriosis: in favor of less aggressive surgery. *Am J Obstet Gynecol*. 2016;215:195–200.
4. Darai E, Cohen J, Ballester M. Colorectal endometriosis and fertility. *Eur J Obstet Gynecol Reprod Biol*. 2017;209:86–94.
5. Roman H, Kouteich K, Gromez A, Hochain P, Resch B, Marpeau L. Endorectal ultrasound accuracy in the diagnosis of rectal endometriosis infiltration depth. *Fertil Steril*. 2008;90:1008–13.
6. Ford J, English J, Miles WA, Giannopoulos T. Pain, quality of life and complications following the radical resection of rectovaginal endometriosis. *BJOG*. 2004;111:353–6.
7. Chopin N, Vieira M, Borghese B, Foulot H, Dousset B, Coste J, et al. Operative management of deeply infiltrating endometriosis: results on pelvic pain symptoms according to a surgical classification. *J Minim Invasive Gynecol*. 2005;12:106–12.
8. Remorgida V, Ragni N, Ferrero S, Anserini P, Torelli P, Fulcheri E. How complete is full thickness resection of bowel endometriotic lesions? A prospective surgical and histological study. *Hum Reprod*. 2005;20:2317–20.
9. Vignali M, Bianchi S, Candiani M, Spadaccini G, Oggioni G, Busacca M. Surgical treatment of deep endometriosis and risk of recurrence. *J Minim Invasive Gynecol*. 2005;12:508–13.
10. Dubernard G, Piketty M, Rouzier R, Houry S, Bazot M, Darai E. Quality of life after laparoscopic colorectal resection for endometriosis. *Hum Reprod*. 2006;21:1243–7.
11. Sagae EU, Lopasso F, Abrão MS, Cavalli N, Rodrigues JGG. Endometriose do trato gastrointestinal – correlações clínicas e laparoscópicas. *Rev Bras Coloproctol*. 2007;27:423–31.
12. Lima DMR, Bortolli JP, Kurachi G, Sagae UE. Importance of superior rectal artery preservation in videolaparoscopic rectosigmoidectomy for benign disease. *Adv Res Gastroenterol Hepatol*. 2017;4.
13. Bryant CL, Lunniss PJ, Knowles CH, Thaha MA, Chan CL. Anterior resection syndrome. *Lancet Oncol*. 2012;13:e403–8.

14. Redwine DB, Koning M, Sharpe DR. Laparoscopic assisted transvaginal segmental resection of the rectosigmoid colon for endometriosis. *Fertil Steril*. 1996;65:193-7.
15. Chapron C, Fauconnier UMA, Vieira M, Barakat H, Dousset B, Pansini V, et al. Distribuição anatômica da endometriose profundamente infiltrante: implicações cirúrgicas e proposição para uma classificação. *Hum Reprod*. 2003;18:157-61.
16. Roman H, Vassilieff M, Gourcerol G, Savoye Anne G, Loïc ML, Michot MF, et al. Surgical management of deep infiltrating endometriosis of the rectum: pleading for a symptom-guided approach. *Hum Reprod*. 2011;26:274-81.
17. Bailey HR, Ott MT, Hartendorp P. Aggressive surgical management for advanced colorectal endometriosis. *Dis Colon Rectum*. 1994;37:747-53.
18. Roman H, Vassilieff M, Gourcerol G, Savoye G, Leroi AM, Marpeau L, et al. Surgical management of deep infiltrating endometriosis of the rectum: pleading for a symptom-guided approach. *Hum Reprod*. 2011;26:274-81.
19. Abbas B, de Parades V, Gadonneix P, Etienney I, Salet-Lizée D, Villet R, et al. Endorectal ultrasonography in predicting rectal wall infiltration in patients with deep pelvic endometriosis: a modern tool for an ancient disease. *Dis Colon Rectum*. 2006;49:869-75.
20. Redwine DB, Koning M, Sharpe DR. Laparoscopically assisted transvaginal segmental resection of the rectosigmoid colon for endometriosis. *Fertil Steril*. 1996;65:193-7.
21. Abrão MS, Sagae EU, Gonzales M, Podgaec S, Dias JÁ Jr. Treatment of rectosigmoidectomy endometrioses by laparoscopically assisted vaginal rectosigmoidectomy. *Int J Gynaecol Obstet*. 2005;91:27-31.
22. Riiskjær M, Kesmodel US, Lars AM, Ljungmann K, Seyer-Hansen M. Pelvic pain and quality of life before and after laparoscopic bowel resection for rectosigmoid endometriosis: a prospective, observational study. *Dis Colon Rectum*. 2018;61:221-9.
23. Tarjanne S, Heikinheimo O, Mentula M, Härkki P. Complications and long-term follow-up on colorectal resections in the treatment of deep infiltrating endometriosis extending to bowel wall. *Acta Obstet Gynecol Scand*. 2015;94:72-9.
24. Donnez O, Roman H. Choosing the right surgical technique for deep endometriosis: shaving, disc excision or bowel resection? *Fertil Steril*. 2017;108:0015-282.
25. Roman H, Milles M, Vassilieff M, Resch B, Tuech JJ, Huet E, et al. Long-term functional outcomes following colorectal resection versus shaving for rectal endometriosis. *Am J Obstet Gynecol*. 2016;215, 762.e1-9.
26. Roman H, Moatassim-Drissa S, Marty N, Milles M, Vallée A, Desnyder E, et al. Rectal shaving for deep endometriosis infiltrating the rectum: a 5year continuous retrospective series. *Fertil Steril*. 2016;106:1438-45.
27. Roman H, FRIENDS group (French Colorectal Infiltrating Endometriosis Study group). A national snapshot of the surgical management of deep infiltrating endometriosis of the rectum and colon in France in 2015: a multicenter series of 1135 cases. *J Gynecol Obstet Hum Reprod*. 2017;46:159-65.
28. Roman H, Darwish B, Bridoux V, Chati R, Kermiche S, Coget J, et al. Functional outcomes after disc excision in deep endometriosis of the rectum using transanal staplers: a series of 111 consecutive patients. *Fertil Steril*. 2017;107:977-86.
29. Thiels CA, Shenoy CC, Ubl DS, Habermann EB, Kelley SR, Mathis KL. Rates, trends, and short-term outcomes of colorectal resections for endometriosis: an ACS-NSQIP review. *Int J Surg*. 2016;31:5-9.