



Original Article

Postoperative results of 407 patients submitted to Doppler-guided transanal hemorrhoidal dearterialization[☆]



Carlos Mateus Rotta ^{a,*}, Laura Ruy Machado^b, Patrícia Mie Uwada^b,
Rafaela Delsin Mizael^b, Rachel de Oliveira Faxina^b, Gabriela Bittencourt^b,
Marjorie Cristina da Cruz Bernardino^c, Carlos Augusto Real Martinez^{d,e}

^a Universidade de Mogi das Cruzes (UMC), Faculdade de Medicina, Disciplina de Clínica Cirúrgica, Mogi das Cruzes, SP, Brazil

^b Universidade de Mogi das Cruzes (UMC), Faculdade de Medicina, Mogi das Cruzes, SP, Brazil

^c Universidade de Mogi das Cruzes (UMC), Políticas Públicas, Mogi das Cruzes, SP, Brazil

^d Universidade São Francisco (USF), Programa de Pós-Graduação em Ciências da Saúde, São Paulo, SP, Brazil

^e Universidade Estadual de Campinas (UNICAMP), Faculdade de Ciências Médicas, Departamento de Cirurgia, Campinas, SP, Brazil

ARTICLE INFO

Article history:

Received 4 February 2019

Accepted 21 April 2019

Available online 24 May 2019

Keywords:

Hemorrhoids

Hemorrhoids/surgery

Ligation

Doppler ultrasonography

Hemorrhoidal dearterialization

THD

ABSTRACT

Introduction: The treatment of hemorrhoidal disease by conventional technique is associated with significant morbidity, mainly represented by the postoperative pain and the late return to daily activities. A technique of hemorrhoidal dearterialization associated with rectal mucopexy is a minimal invasive surgical option that has been used to treat the hemorrhoidal disease and reduce its inconveniences.

Objective: To analyze the seven-year results of hemorrhoidal dearterialization associated with rectal mucopexy in the treatment of hemorrhoidal disease.

Methods: This study analyzed 407 patients with hemorrhoids grade II, III and IV, who underwent the technique of hemorrhoidal dearterialization in the Luzia de Pinho Melo Hospital, during the period between December 2010 and December 2017. Twenty-seven patients (6.6%) had hemorrhoidal disease of the grade II, 240 (59.0%) grade III, and 117 (28.8%) grade IV. In 23 patients (5.7%), the grade was not found. All patients were operated by the same surgeon under spinal anesthesia. The 407 patients underwent dearterialization, with a varying ligation of one to six arterial branches followed by rectal mucopexy by uninterrupted suture. Eighty-two (20.14%) required removal of concomitant perianal piles or external hemorrhoids and/or fibrosed. In the postoperative follow-up the following parameters were evaluated: pain, tenesmus, bleeding, prolapse, thrombosis, and recurrence.

Results: The tenesmus was postoperative complaint reported by 93.6% of patients. Forty-three (10.5%) presented intense tenesmus and 44 (22%), moderate to intense pain. Four (0.98%) patients presented more intense bleeding in postoperative follow up; none of the patients required blood transfusions. The prolapse occurred in 18 (4.42%) patients, thrombosis in 11 (2.7%), and there were 19 (4.67%) recurrences that were reoperated in this period.

[☆] Study conducted at the Department of Surgery of the Medical School of the Universidade de Mogi das Cruzes (UMC), at the Hospital Das Clinicas “Luzia De Pinho Melo”, Mogi das Cruzes, SP, Brazil.

* Corresponding author.

E-mail: mateusrotta@saluspraxis.com (C.M. Rotta).

<https://doi.org/10.1016/j.jcol.2019.04.001>

2237-9363/© 2019 Sociedade Brasileira de Coloproctologia. Published by Elsevier Editora Ltda. This is an open access article under the CC BY-NC-ND license (<http://creativecommons.org/licenses/by-nc-nd/4.0/>).

Conclusion: The hemorrhoidal dearterialization technique presents good results, with light and easy-to-resolve complications and little postoperative pain.

© 2019 Sociedade Brasileira de Coloproctologia. Published by Elsevier Editora Ltda. This is an open access article under the CC BY-NC-ND license (<http://creativecommons.org/licenses/by-nc-nd/4.0/>).

Resultados pós-operatórios de 407 doentes submetidos à desarterialização hemorroidária guiada pelo Doppler

R E S U M O

Palavras-chave:

Hemorróidas
Hemorróidas/cirurgia
Ligadura
Ultrassonografia Doppler
Desarterialização hemorroidária
THD

Introdução: O tratamento da doença hemorroidária pelas técnicas convencionais cursa com significativa redução da qualidade de vida do doente, principalmente relacionada à dor pós-operatória e ao considerável tempo de afastamento do trabalho. A técnica de desarterialização hemorroidária associada à mucopexia retal é uma opção cirúrgica pouco invasiva, a qual é utilizada com o objetivo de tratar a doença hemorroidária e reduzir seus inconvenientes.

Objetivo: Analisar os resultados encontrados após sete anos de seguimento em doentes submetidos à técnica da desarterialização hemorroidária associada à mucopexia para o tratamento da doença hemorroidária.

Método: Foram estudados 407 portadores de doença hemorroidária de graus II, III e IV, submetidos à técnica da desarterialização hemorroidária no Hospital das Clínicas Luzia de Pinho Melo de Mogi das Cruzes, durante o período de Dezembro de 2010 a Dezembro de 2017. Vinte e sete doentes (6,6%) apresentavam doença hemorroidária de grau II, 240 (59,0%) do grau III e 117 (28,8%) do grau IV. Em 23 doentes (5,7%) não foram encontradas a classificação nos prontuários. Todos os doentes foram operados pelo mesmo cirurgião e sob anestesia raquidiana. Os 407 doentes foram submetidos à desarterialização, variando de um até seis ramos arteriais seguidos de mucopexia por sutura contínua. Oitenta e dois (20,14%) necessitaram ressecções associadas por plicomas ou hemorroidas externas. No pós-operatório foram avaliados os seguintes parâmetros: dor, tenesmo, sangramento, prolapso, trombose e recidiva.

Resultados: O tenesmo foi a queixa pós-operatória referida por 93,36% dos doentes. Quarenta e três (10,5%) apresentaram tenesmo intenso e 44 (22%) de moderado a intenso. Quatro (0,98%) doentes apresentaram sangramento de maior intensidade no pós-operatório e em 1 (0,5%) houve necessidade de hemostasia cirúrgica, em nenhum deles houve necessidade de reposição sanguínea. O prolapso ocorreu em 18 (4,42%) doentes, trombose em 11 (2,7%) e houve 19 (4,67%) recidivas reoperados durante o período.

Conclusão: A desarterialização hemorroidária apresenta bons resultados, complicações leves e de fácil resolução e pouca dor pós-operatória.

© 2019 Sociedade Brasileira de Coloproctologia. Publicado por Elsevier Editora Ltda. Este é um artigo Open Access sob uma licença CC BY-NC-ND (<http://creativecommons.org/licenses/by-nc-nd/4.0/>).

Introduction

Hemorrhoidal disease (HD) is one of the most common diseases in outpatient coloproctology clinics. In developed countries, it is estimated that approximately 50% of individuals over the age of 50 will develop or have already developed some symptom related to HD.¹ Early-stage HD patients may benefit from conservative measures; however, when the disease is more advanced, surgical treatment is often required. The most common conventional surgical methods for the treatment of HD are Milligan-Morgan open hemorrhoidectomy or Ferguson closed hemorrhoidectomy, which have low postoperative complications, good resolution of HD, and acceptable recurrence rates. However, intense postoperative

pain and the prolonged leave of absence from work are major limitations of such procedures, due to the existence of a surgical wound in the anoderm, a region rich in sensitive nerve endings. Fear of postoperative pain causes many patients to avoid surgical treatment, preferring to cope with the symptoms of HD.

In order to reduce the drawbacks of conventional hemorrhoidectomy (CH), new methods have been proposed for the treatment of HD since the 1990s. Among them, mechanical rectopexy (MR), in which a circular mucosal and submucosal cuff is resected in the lower rectum, and the edges of the remaining rectal mucosa are reconstructed and fixated through a circular mechanical suture. As no incisions are made in the anal mucosa, patients develop with few postoperative painful symptoms. However, MR has postoperative

Table 1 – Sample characterization.

Characteristics	Number (n)	Percentage (%)
Sex		
Males	189	46.40
Females	218	53.50
Degree		
No definition of degree	23	5.70
Grade II	27	6.60
Grade III	240	59.0
Grade IV	117	28.8
Presence of associated resections		
Resections	82	20.15
Mean age (years)	47.82 (17-88)	–
Total patients	407	100

complications and higher rates of long-term relapse when compared with CH.² The presence of serious complications, such as severe postoperative hemorrhage and rectal wall perforation, have also been described. In MR, when the purse-string suture is too superficial, it may not include arterial branches present in the submucosa, increasing the chance of postoperative bleeding. Conversely, when the purse-string suture is performed more deeply, it may encompass the entire rectal wall and during stapling, it may lead to a low rectal anastomosis without the protection of a stoma, sometimes in a rectum without mechanical preparation.

In order to interrupt the blood flow directly on the branches of the hemorrhoidal arteries, preventing a deep penetration of the suture in the rectal wall, the hemorrhoidal dearterialization technique was proposed.³ With this method, it is possible to interrupt blood flow over the arterial branches, avoiding surgical incisions below the pectinate line, the main cause of postoperative pain in CH. When associated with rectal mucopexy, hemorrhoidal dearterialization also allows high fixation and, consequently, the correction of prolapsed internal hemorrhoidal piles.⁴⁻⁸

The present study aimed to analyze, after seven years of follow-up, the results of HD treatment with the use of the technique of hemorrhoidal dearterialization associated with rectal mucopexy in surgeries performed at the Hospital das Clínicas “Luzia de Pinho Melo” (HCLPM), a teaching hospital of the School of Medicine of the Universidade de Mogi das Cruzes (UMC).

Methods

This article was submitted to the Research Ethics Committee of the UMC under the number CAAE 96158318.8.0000.5497 and approved in opinion number 2,922,623.

Table 1 shows the characteristics of the patients studied. A total of 407 HD patients were analyzed: 218 women (53.5%) and 189 men (46.4%), with a mean age 47.82 years (17–88 years). Twenty-seven (6.6%) had grade II HD, refractory to conservative treatment, 240 (59.0%) had grade III, 117 (28.8%) had grade IV, and in 23 (5.7%), the grade was not defined. Associated resections were required in 82 patients (20.15%). Patients with other associated anorectal conditions were excluded, such as

those with neoplastic disease of any origin, or those who used anticoagulants.

All patients were operated on electively, and the procedure was always performed by the same surgeon (CMR) between December 2010 and December 2017 at the Hospital das Clínicas Luzia de Pinho Melo de Mogi das Cruzes. Prior to the procedure, patients underwent a complete proctologic examination consisting of static and dynamic inspection, rectal examination, and anoscopy. Patients aged 50 years underwent colonoscopy for screening for colon cancer. Anorectal manometry was not performed in any patients.

Equipment

The system used consisted of an anoscope, specially made for the procedure, composed of a fixed part and a sliding or rotating part for the mucopexy, which was performed using a Doppler flowmetry equipment connected to a transducer that captures sonic waves, a source of cold light, and a suture system. The anoscope has an extensible fenestra for the application of the sutures. The sliding transducer can be moved freely by the surgeon and is oriented toward the operative window of the anoscope. Thus, it is possible to identify the sound coming exclusively from arterial branches.

Technique

The anoscope was carefully inserted until it reached the lower portion of the rectum, approximately 7 cm above the anal border. The Doppler probe was then introduced and mobilized craniocaudally and laterolaterally until the best acoustic signal from the arterial branch, identified in the upper lateral wall of the rectum, was heard. After identification, a mounted needle holder was introduced until its end reached the fenestra. The needle holder had a 5/8-in. rounded, cylindrical needle, 2.65 cm long, already threaded with an absorbent, monofilament (2-0) suture supplied by the system. Dearterialization was always initiated at the point of sound emission, applying two X-shaped transfixing sutures, tied manually. After ligation, the mucosal prolapse was corrected by continuous suture performed under direct vision in the longitudinal direction of the rectum; rectal mucopexy was completed by tying the first suture to the last.

Results

All patients were submitted to dearterialization, rectopexy, and dearterialization of one to six arterial branches. In addition to the dearterialization and mucopexy, associated resection was required in 82 patients (20.15%). Resection, when necessary, was performed through an elliptical incision with electric scalpel.

Fig. 1 presents the main complaints. A total of 86 patients (43.0%) complained of anorectal pain; of these, 66 (16.21%) presented moderate to intense pain. Intense tenesmus was reported by 42 (10.31%) patients. Seven (1.72%) patients evolved with urinary retention in the immediate postoperative period. Four patients (0.98%) presented major bleeding in the postoperative period and one patient (0.24%) required

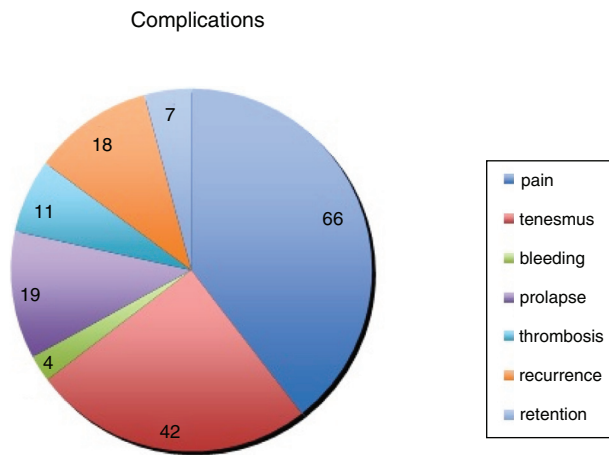


Fig. 1 – Post-operative complications.

surgical hemostasis. In the follow-up period, 18 patients (4.42%) presented recurrence and were reoperated by the same technique.

Discussion

The surgical option for the treatment of HD should have the following as its main goals: complete remission of symptoms, simple technical execution, affordable cost, good tolerance by patients, and low rates of postoperative complications and relapse.

Hemorrhoidal dearterialization aims to treat HD by interrupting blood flow to the hemorrhoidal plexus and reducing mucosal prolapse through rectopexy, restoring the normal anorectal anatomy. The procedure aims to achieve these goals by disrupting arterial blood flow to the hemorrhoidal venous plexus and fixating the excess prolapsed rectal mucosa within the rectum. HD presents with lower rates of severe complications when compared with MR. With HD, the risk of accidentally stapling the entire rectal wall, making an ultra-low rectal anastomosis, in a rectum without previous mechanical preparation and without the protection of a proximal stoma, is eliminated. This situation can lead to the development of severe abdominal-pelvic infections, which can sometimes be fatal.² In the present study, no severe or chronic complications were observed; all other complications were easily resolved.

The technique of hemorrhoidal dearterialization interrupts blood flow from the distal branches of the superior rectal artery (identified through Doppler) by applying transfixing sutures directly over them with posterior fixation of the prolapsed piles inside the rectum in a higher location.³ The use of a Doppler device associated with the light source and the procedure-specific anoscope allows precise localization of the arterial branches in the rectal wall,^{3,8} as well as the application of the transfixing suture directly into the wall. The acoustic echo transducer can capture sonic waves emitted even by small branches located on the surface of the rectal wall, increasing the precision of the ligature of these vessels. Knowing the exact location where each arterial branch

passes allows the suture and posterior rectal mucosa to be made exactly over the vessel along the longitudinal axis of the rectum, leaving a clear space between each pexy. This reduces the chance of complete blockage of the venous flow through the hemorrhoidal venous plexus, which is responsible for the postoperative cases of external hemorrhoidal thrombosis. The interval between suture and the longitudinal pexy also reduces the possibility of total obliteration of the rectal lumen, a complication described after MR. Another advantage of hemorrhoidal dearterialization in relation to MR is that the supplied anoscope and light allow the transfixing sutures to be applied under direct vision. As the mucosal cuff and rectal submucosa are not resected, the possibility of completely sectioning the rectal wall does not exist.

The possibility of identifying and individually dearterializing each arterial branch (one to six branches) may explain the differences in the number of ligatures when comparing the dearterialization technique with other methods of elastic ligature in HD, where it is not possible to identify exactly where the arterial branch passes.⁶⁻¹⁰ Due to the greater selectivity in the location of the arterial branches, the number of sutures applied (ligatures) varies among the studies, ranging from three to nine in most published articles.⁴ In this study, one to six arterial branches were sutured, identified at positions 1, 3, 5, 7, 9, and 11 h; the patient was always in the lithotomy position.

In the present study, hemorrhoidal dearterialization was indicated for HD patients grade II, III, and IV. Dearterialization was initially used only in grade II DH patients refractory to conservative treatment or for those in grade III.⁸ Subsequently, with the addition of pexy to surgical time, which allowed the reduction and fixation of prolapsed piles, it became possible to indicate the method for patients with grade IV HD.¹¹⁻¹³ In dearterialization, it is possible to define the places where pexy will be initiated and finished, as well as the amount of tissue involved, even in the grade IV patients. In this series of cases, the technique of hemorrhoidal dearterialization associated with rectal pexy was evaluated in 407 patients, aiming to reduce the need for CH and, consequently, postoperative pain intensity and other complications in HD patients from grades II to IV.

A multicentric study evaluating 507 patients with HD grade II (28.4%), grade III (63%), and grade IV (8.6%) patients who underwent dearterialization and were followed-up for one year found good results with the procedure in 69.2% of the patients and acceptable results in the remaining 4.8%.¹⁴ However, when patients were grouped according to the degree of HD, it was observed that 92.4% of patients with grade II and 84% of those with grade III disease were satisfied with the method, in contrast with only 41% of those with grade IV.¹⁴ In the present study, only 4.67% of patients required reoperation and 22% reported moderate to severe pain.

Bursics et al.¹⁵ (2004) compared dearterialization with CH after one year of follow-up. These authors demonstrated that patients undergoing dearterialization required less postoperative analgesia, for fewer days, and were able to return to work faster. These results were confirmed by other authors.^{10,16}

Avital et al. (2011)¹⁷ comparing MR with dearterialization in 63 patients, found that patients submitted to the latter had a lower pain score for bowel movements (2.1 ± 1.4 vs.

5.5 ± 1.9) and lower consumption of analgesics. The length of hospital stay, the interval until the first evacuation, and the complete functional recovery of evacuation were lower in those who underwent dearterialization.¹⁷ In the present study, all patients were admitted on the same day of surgery, were discharged on average 10 h after surgery, and maintained medication for three to five days.

Spiridakis et al. (2011)¹⁸ studied 90 patients who underwent dearterialization and found that recurrence, evaluated by bleeding or mucosal prolapse, was identified in 6.6% of patients, being more common in patients with grade IV hemorrhoids.

Bjelanovic et al. (2016)¹⁹ studied a total of 402 patients for five years. Of this total, 16 patients (4.0%) had grade II, 210 (52.2%) grade III, and 176 (43.8%) grade IV HD. Complications were observed in 67 patients: residual prolapse (4.7%); fissures (3.5%); bleeding (2.5%); hemorrhoidal thromboses (2.5%); perianal fistulas (1.2%); urinary retention (0.8%); severe anal pain (0.8%); and perianal abscesses (0.8%). HD was recurrent in 6.3% (1/16); 5.8% (12/210), and 9.7% (17/176) of patients with grades II, III, and IV, respectively. Twelve months after hemorrhoidal dearterialization, bleeding was controlled in 363 patients (90.5%), prolapse was reverted in 391 (97.3%), and pain improved markedly in 390 patients (97%).

Ratto et al. (2017)²⁰ studied 1000 patients using the transanal hemorrhoidal dearterialization (THD) technique and found that 14 (1.4%) presented acute postoperative hemorrhage; 31 (3.1%) reported tenesmus and 23 (2.3%) presented urinary retention. The recurrence rate was higher for patients with grade IV HD (18.1%) compared to that observed in patients with grade II and III (8.5% and 8.7%, respectively).

Trenti et al. (2017)²¹ evaluated 83 patients, of whom 49 underwent Doppler-guided dearterialization and 34, CH. It was observed that the 30-day postoperative surgical morbidity was 26.5% in the patients submitted to Doppler-guided dearterialization, vs. 8.82% in those who underwent CH.

Toledano et al. (2018)²² collected records of patients operated between November 2012 and June 2014, totaling 70 patients who underwent consecutive surgical procedures for hemorrhoid prolapse (52%), bleeding (29%), or both (17%). In 92.7% of the cases, no complications were observed. Treatment was not successful in six patients (9%), and ten patients (16.4%) had recurrence with symptoms of hemorrhoids. Only age greater than 51 years was statistically associated with more frequent recurrences. Of the present patients, 34 (8.35%) presented local complications; of these, 26 were aged over 41 years, and 13, over 51 years.

The results found in the present study demonstrate that, although all patients were discharged with an anti-inflammatory prescription, 43 (10.6%) complained of tenesmus in the postoperative period, which decreased after the first week, and 44 (10.8%) complained of anal pain. These discomforts are likely to be due to the suture and fixation of the prolapsed pile, to the inflammatory process at the site of the pexy, and to ischemia.⁷ The authors also believe that, in some patients, the pectinate line was reached during anopexy, causing pain. As described by other authors, most patients in the present study had more severe pain and tenesmus in the first week after the operation, which disappeared with

the passing of the days. Most authors describe the occurrence of minor bleeding associated with bowel movements in the first few days after surgery, similar to what is observed with other techniques. Data from the literature report that postoperative bleeding affects 1% to 20.9% of patients submitted to dearterialization.^{4,5,18} A randomized study comparing patients undergoing hemorrhoidal surgery reported that 12% of those who underwent MR presented more severe bleeding, requiring readmission for hemorrhage control, compared with only 4% of those who underwent dearterialization.²³ In the present study, four patients (0.98%) presented rectal bleeding of greater magnitude, but only one (0.25%) required surgical reoperation for hemostasis. A less frequent symptom was urinary retention, observed in seven patients (1.72%). Despite the fact that dearterialization preserved venous drainage between the pexy sutures, hemorrhoidal thrombosis occurred in 11 patients (2.7%), who recovered with clinical treatment. A review of the literature on THD in the treatment of HD indicates that Doppler-guided hemorrhoidal dearterialization is a safe and effective method for treating HD from grade II to IV. Anal physiology disorders are rare and transient. Therefore, hemorrhoidal dearterialization is an excellent option for all patients, especially those with previous anal surgeries and in patients with previous fecal continence alterations.²⁴

Dearterialization is a simple surgical procedure, which leads to symptom remission in most patients with grade II, III, and IV HD; it is well tolerated and presents acceptable recurrence rates.

Conclusion

The dearterialization technique for the treatment of grades II, III, and IV HD features the main benefits of evolving with less postoperative pain and with few relapses.

Conflicts of interest

The authors declare no conflicts of interest.

REFERENCES

1. Kaidar-Person O, Person B, Wexner SD. Hemorrhoidal disease: a comprehensive review. *J Am Coll Surg.* 2007;204:102-17.
2. Kornaros S, Dalamangas K, Zisi-Sermpetzoglou A. Fulminant intra-abdominal sepsis after stapled hemorrhoidectomy. *Surg Infect (Larchmt).* 2011;12:145-8.
3. Morinaga K, Hasuda K, Ikeda T. A novel therapy for internal hemorrhoids: ligation of the hemorrhoidal artery with a newly devised instrument (Moricorn) in conjunction with a Doppler flowmeter. *Am J Gastroenterol.* 1995;90:610-3.
4. Felice G, Privitera A, Ellul E, Klaumann M. Doppler-guided hemorrhoidal artery ligation: an alternative to hemorrhoidectomy. *Dis Colon Rectum.* 2005;48:2090-3.
5. Greenberg R, Karin E, Avital S, Skornick Y, Werbin N. First 100 cases with Doppler-guided hemorrhoidal artery ligation. *Dis Colon Rectum.* 2006;49:485-9.
6. Abdeldaim Y, Mabadeje O, Muhammad KM, Mc Avinchey D. Doppler-guided haemorrhoidal arteries ligation: preliminary clinical experience. *Ir Med J.* 2007;100:535-7.

7. Ratto C, Donisi L, Parello A, Litta F, Doglietto GB. Evaluation of transanal hemorrhoidal dearterialization as a minimally invasive therapeutic approach to hemorrhoids. *Dis Colon Rectum*. 2010;53:803–11.
8. Giordano P, Nastro P, Davies A, Gravante G. Prospective evaluation of stapled haemorrhoidopexy versus transanal haemorrhoidal dearterialisation for stage II and III haemorrhoids: three-year outcomes. *Tech Coloproctol*. 2011;15:67–73.
9. Pescatori M, Gagliardi G. Postoperative complications after procedure for prolapsed hemorrhoids (PPH) and stapled transanal rectal resection (STARR) procedures. *Tech Coloproctol*. 2008;12:7–19.
10. Aigner F, Bodner G, Conrad F, Mbaka G, Kreczy A, Fritsch H. The superior rectal artery and its branching pattern with regard to its clinical influence on ligation techniques for internal hemorrhoids. *Am J Surg*. 2004;187:102–8.
11. Infantino A, Bellomo R, Dal Monte PP, Salafia C, Tagariello C, Tonizzo CA, et al. Transanal haemorrhoidal artery echodoppler ligation and anopexy (THD) is effective for II and III degree haemorrhoids: a prospective multicentric study. *Colorectal Dis*. 2010;12:804–9.
12. Zagriadskii EA. Trans-anal disarterization of internal hemorrhoids under Doppler control with mucopexy and lifting in treatment of stage III–IV hemorrhoids. *Khirurgiia (Mosk)*. 2009;2:52–8.
13. Ratto C, Giordano P, Donisi L, Parello A, Litta F, Doglietto GB. Transanal haemorrhoidal dearterialization (THD) for selected fourth-degree haemorrhoids. *Tech Coloproctol*. 2011;15:191–7.
14. Shao WJ, Li GC, Zhang ZH, Yang BL, Sun GD, Chen YQ. Systematic review and meta-analysis of randomized controlled trials comparing stapled haemorrhoidopexy with conventional haemorrhoidectomy. *Br J Surg*. 2008;95:147–60.
15. Bursics A, Morvay K, Kupcsulik P, Flautner L. Comparison of early and 1-year follow-up results of conventional hemorrhoidectomy and hemorrhoid artery ligation: a randomized study. *Int J Colorectal Dis*. 2004;19:176–80.
16. Avital S, Itah R, Skornick Y, Greenberg R. Outcome of stapled hemorrhoidopexy versus doppler-guided hemorrhoidal artery ligation for grade III hemorrhoids. *Tech Coloproctol*. 2011;15:267–71.
17. Sajid MS, Parampalli U, Whitehouse P, Sains P, McFall MR, Baig MK. A systematic review comparing transanal haemorrhoidal de-arterialisation to stapled haemorrhoidopexy in the management of haemorrhoidal disease. *Tech Coloproctol*. 2012;16:1–8.
18. Cantero R, Balibrea JM, Ferrigni C, Sanz M, Pérez JC, Pérez R, et al. Doppler-guided transanal haemorrhoidal dearterialization: an alternative treatment for haemorrhoids. *Cir Esp*. 2008;83:252–5.
19. Bjelanovic Z, Draskovic M, Veljovic M, Lekovic I, Karanikolas M, Stamenkovic D. Transanal hemorrhoid dearterialization is a safe and effective outpatient procedure for the treatment of hemorrhoidal disease. *Cir Esp*. 2016;94:588–94.
20. Ratto C, Campenni P, Papeo F, Donisi L, Litta F, Parello A. Transanal hemorrhoidal dearterialization (THD) for hemorrhoidal disease: a single-center study on 1000 consecutive cases and a review of the literature. *Tech Coloproctol*. 2017;21:953–62.
21. Trenti L, Biondo S, Galvez A, Bravo A, Cabrera J, Kreisler E. Distal Doppler-guided transanal hemorrhoidal dearterialization with mucopexy versus conventional hemorrhoidectomy for grade III and IV hemorrhoids: postoperative morbidity and long-term outcomes. *Tech Coloproctol*. 2017;21:337–44.
22. Toledano AB, Blanchard P, Zaleski A, Benfred P, Fathallah N, Sultan S, et al. Lessons from the first 70 patients operated by doppler-guided haemorrhoidal artery ligation with mucopexy in a French team specialising in surgical proctology. *J Coloproctol*. 2018;38:111–6.
23. Pol RA, van der Zwet WC, Hooenenborg D, Makkinga B, Kaijser M, Eefitnck Schattenkerk M, et al. Results of 244 consecutive patients with hemorrhoids treated with Doppler-guided hemorrhoidal artery ligation. *Dig Surg*. 2010;27:279–84.
24. Figueiredo MN, Campos FG. Doppler-guided hemorrhoidal dearterialization/transanal hemorrhoidal dearterialization: technical evolution and outcomes after 20 years. *World J Gastrointest Surg*. 2016;8:232–7.