



Review Article

Internal hernia through mesocolon defect after left laparoscopic colectomy[☆]

Carlos Augusto Real Martinez ^{a,b,*}, Michel Gardere Camargo^a, Jaissy Jerubi Cervantes^c, Maria de Lourdes Setsuko Ayrizono^a, Natalia Sayuri Mukai^a, João Gabriel Romero Braga^a, Daniel Lahan Martins^a, Cláudio Saddy Rodrigues Coy^a

^a Universidade Estadual de Campinas (UNICAMP), Faculdade de Ciências Médicas, Divisão Colorretal, Campinas, SP, Brazil

^b Universidade São Francisco, Programa de Pós-Graduação em Ciências da Saúde, Bragança Paulista, SP, Brazil

^c Venezuela Central University, Faculty of Medicine, Caracas, Venezuela

ARTICLE INFO

Article history:

Received 3 February 2019

Accepted 17 June 2019

Available online 23 July 2019

Keywords:

Hernia/complications

Intestinal obstruction

Laparoscopy

Mesocolon

Colonic neoplasm

ABSTRACT

Introduction: The development of internal hernias due to the mesocolon defect after laparoscopic colectomy is a rare complication with only 39 cases described. There are controversies whether the closure of the defect of the mesocolon after resection of the colon could prevent the development of this complication.

Objective: To describe a case of intestinal obstruction due to internal hernia through the mesocolon defect after laparoscopic rectosigmoidectomy and to perform a literature review.

Case report: A 59-year-old woman was hospitalized for laparoscopic rectosigmoidectomy due to an adenocarcinoma located in the rectosigmoid junction. She underwent a rectosigmoidectomy by laparoscopy, with an extracorporeal mechanical anastomosis, without closure of the mesocolon defect. In the fifth postoperative day the patient presented an intestinal obstruction due to an internal hernia through the mesocolon defect confirmed by computerized tomography. During the exploratory laparotomy approximately 120 cm jejunum was identified through the mesocolon defect. The reduction of herniated small bowel was done without the need of intestinal resection. The mesocolon defect was corrected by continuous suture. After the reoperation, the patient presented a favorable recovery being discharged on the fifth day.

Conclusion: Intestinal obstruction due to internal hernia after laparoscopic rectosigmoidectomy is a rare postoperative complication that can be avoided by the adequate closure of the mesocolon defect.

© 2019 Sociedade Brasileira de Coloproctologia. Published by Elsevier Editora Ltda. This is an open access article under the CC BY-NC-ND license (<http://creativecommons.org/licenses/by-nc-nd/4.0/>).

[☆] From Colorectal Division of Faculdade de Ciências Médicas da Universidade Estadual de Campinas (UNICAMP).

* Corresponding author.

E-mail: caomartinez@uol.com.br (C.A. Martinez).

<https://doi.org/10.1016/j.jcol.2019.06.002>

2237-9363/© 2019 Sociedade Brasileira de Coloproctologia. Published by Elsevier Editora Ltda. This is an open access article under the CC BY-NC-ND license (<http://creativecommons.org/licenses/by-nc-nd/4.0/>).

Hérnia interna pelo defeito mesocólico após colectomia esquerda laparoscópica

R E S U M O

Palavras-chave:

Hérnia/complicações
Obstrução intestinal
Laparoscopia
Mesocolon
Neoplasias do colo

Introdução: O desenvolvimento de hérnias internas pelo defeito mesocólico após a realização de colectomia laparoscópica é uma complicação rara com apenas 39 casos descritos. Existem controvérsias se fechamento do defeito após a ressecção do cólon preveniria o desenvolvimento desta complicação.

Objetivo: Descrever um caso de obstrução intestinal por hérnia interna pelo defeito mesocólico, após retossigmoidectomia laparoscópica e revisar a literatura relacionada ao tema.

Relato do caso: Mulher, 59 anos foi internada para realizar ressecção cirúrgica de adenocarcinoma localizado na junção retossigmoideana. Foi submetida à retossigmoidectomia laparoscópica, com confecção de anastomose mecânica extracorpórea. O defeito mesocólico não foi corrigido no final do procedimento. No quinto dia de pós-operatório, a doente apresentou quadro de obstrução intestinal cuja tomografia computadorizada identificou presença de hérnia interna pelo defeito do mesocólon. Na laparotomia exploradora identificou-se que aproximadamente 120 cm de alças jejunais estavam herniadas através do defeito mesocólico. Realizou-se a redução do intestino delgado herniado sem necessidade de ressecção intestinal. O defeito foi corrigido por sutura contínua. Após a reoperação a doente apresentou evolução favorável recebendo alta no quinto dia.

Conclusão: Obstrução intestinal após retossigmoidectomia laparoscópica consequente à formação de hérnia interna é complicação pós-operatória rara, com alta mortalidade, que pode ser evitada pelo fechamento criterioso do defeito do mesocólico.

© 2019 Sociedade Brasileira de Coloproctologia. Publicado por Elsevier Editora Ltda. Este é um artigo Open Access sob uma licença CC BY-NC-ND (<http://creativecommons.org/licenses/by-nc-nd/4.0/>).

Introduction

Intestinal obstruction resulting from herniation of the small intestine through mesocolon defect after laparoscopic colectomies is an uncommon and rarely described complication.¹ Despite the low incidence, when undiagnosed and promptly corrected it can present a worse evolution. The development of Internal Hernias (IH) after laparoscopic colon resections seems to be greater when compared to conventional access.^{2–8} When performing colectomy by open access the surgeon usually corrects the mesocolon defect most of the time. However, because of the greater technical difficulty in performing laparoscopic sutures, most colorectal surgeons choose to leave the defect open, assuming that the simple positioning of the small intestine loops above the mesocolon would be sufficient to prevent the development of IH.¹ Despite this strategy, the majority of surgeons who experienced cases of intestinal obstruction due to the formation of an IH by the mesocolon corrected whenever possible.^{4,6} This proposition was based on the experience of bariatric surgeons showing that the routine correction of the mesenteric defect significantly reduced the cases of Petersen's hernias. From these evidences many colorectal surgeons advocate the closure of the mesocolon defect in order to avoid the development of IH.^{1,4,6} However, due to the lack of studies with a good level of evidence, there is still no consensus in the literature regarding the systematic correction of the mesocolon defect after colectomies. Thus, the subject still arouses warm discussions.

In order to contribute to the theme, the objective of the present study is to perform a literature review related to the subject, based on the experience of a case of intestinal obstruction caused by IH after performing a laparoscopic rectosigmoidectomy, where correction of the mesocolon defect was not performed.

Case report

After the patient had signed an informed consent term authorizing the publication, this article was submitted and approved by the Research Ethics Committee of the State University of Campinas (UNICAMP).

A 59-year-old woman, BMI of 28, was admitted for surgical treatment of adenocarcinoma located in the rectosigmoid transition. Six months ago, she complained of change in bowel habits, hematochezia, and weight loss. The colonoscopy identified an ulcer-vegetative lesion, sub-stenotic, measuring 6.0 × 5.0 cm, located at 18 cm from the anal margin, from which biopsies were collected and the local was tattooed with Chinese ink. The remaining colon was normal. The histopathological study confirmed the presence of moderately differentiated adenocarcinoma. In staging exams tomography of the thorax and abdomen was normal, as well the carcinoembryonic antigen levels (2.64 mg/mL).

The patient was submitted to anterior rectosigmoidectomy by laparoscopic access. The exam of the abdominal cavity showed the lesion was located 6 cm above the peritoneal

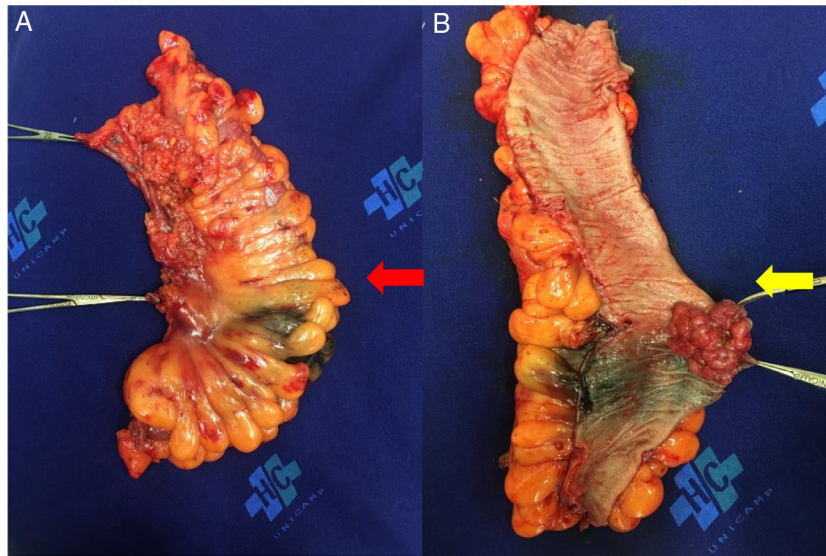


Fig. 1 – (A) External view of anterior rectosigmoidectomy product showing Chinese ink marking area of the tumor (red arrow). (B) Internal view of the specimen extirpated with vegetative lesion in the lumen of the colon (yellow arrow).

reflection. We chose to tie the superior rectal artery below the point where the inferior mesenteric artery originated the left colonic artery. Since the patient had a redundant sigmoid colon, it was decided not to release the splenic flexure of the colon. After complete liberation of the left colon, a 10 cm supra-pubic transverse incision was done for section of the descending colon and proximal rectal using a linear stapler (PROXIMATE Linear Cutter 75; Ethicon Endo-Surgery, Cincinnati, OH, USA). The surgical specimen was extracted with protection of the abdominal wall. The end-to-end anastomosis between the descending colon and the remaining rectum was made using circular stapler 29 (ECHELON Circular Stapler 29; Ethicon Endosurgery, Cincinnati, OH, USA). After anastomosis, the bubble test was performed to verify its integrity, as well the analysis of the colorectal tissue rings removed with the stapler. After closure of the suprapubic incision, the pneumoperitoneum was reestablished for revision of the abdominal cavity and careful placement of the small intestine loops above the mesocolon defect. The mesocolon opening region resulting from bowel resection was not closed by preference. The study of the surgical specimen (Fig. 1A and B) found 24 non-metastatic lymph nodes and classified the tumor as Stage I of TNM classification (7th ed.).

On the 1st postoperative, the patient walked without help and accepted oral liquid diet. On the 3rd postoperative after accepting mild diet and eliminate gases and received hospital discharge. On 5th postoperative day, she returned to the hospital emergency room, complaining about severe abdominal colic, accompanied by vomiting, stopping the gas and stool elimination. Physical examination showed no fever, but she was tachycardiac and dehydrated. The abdomen was painful to palpation, distended, but without signs of peritoneal irritation. With suspicion of intestinal obstruction, a radiographic series of the abdomen was performed, which showed suggestive signs of intestinal obstruction: dilated small intestine loops with visible convex valves, grouped mainly in the upper

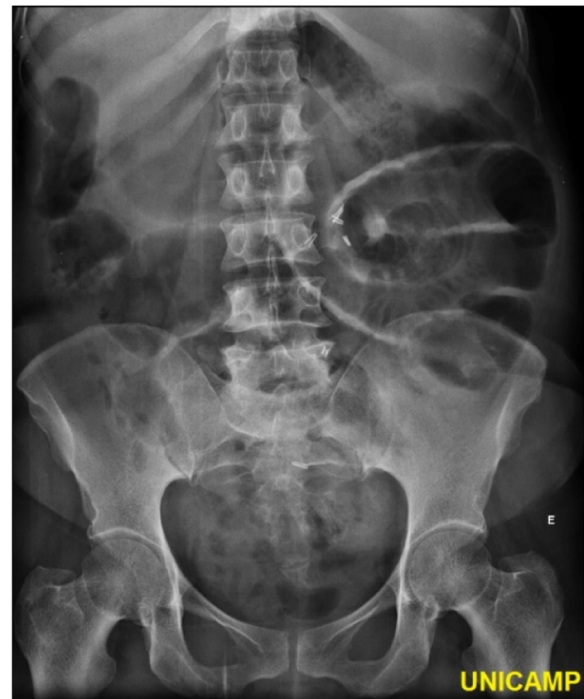

Fig. 2 – Simple abdominal radiograph showing dilated loops of the small intestine (jejunum) with visible convex valves, located mainly in the upper left quadrant.

left quadrant (Fig. 2). In order to identify the cause of intestinal obstruction, a Computerized Tomography (CT) scan of the abdomen was performed, showing in the coronal reformatted image, ascending vessels strongly grouped, indicating that the obstruction point was in the mesocolon defect, where they migrated multiple small bowel loops to the upper left quadrant. There was also segmental dilatation and liquid stasis

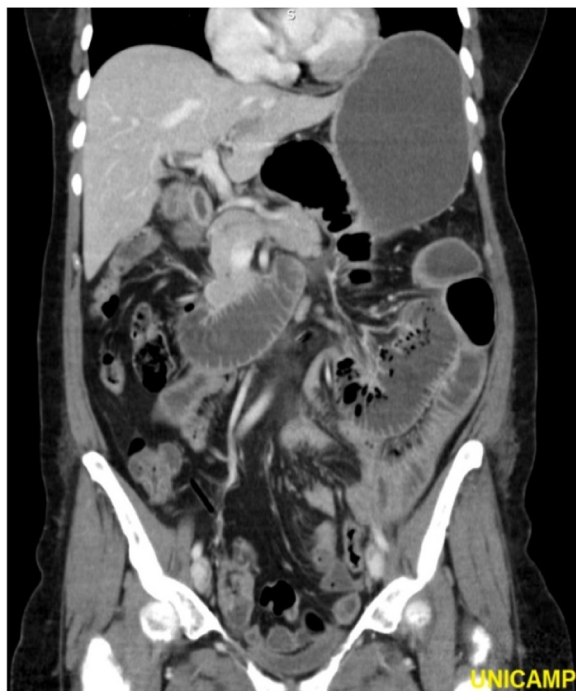

Fig. 3 – CT with reformatted image. Coronal section where ascending vessels are identified, strongly grouped, indicating mesocolon defect level, with multiple redundant loops of the small intestine in the upper left quadrant. It is also evidenced intestinal obstruction with segmental dilatation and liquid stasis proximal to the obstruction site.

proximal to the point of obstruction with marked gastric stasis obstruction (Fig. 3).

With diagnosis of intestinal obstruction by probable IH by the mesocolon defect the patient was indicated emergency surgery. The abdominal cavity was accessed by a median incision, identifying approximately 120 cm of herniated jejunal loops through the mesocolon defect. The jejunal loops passed through the defect and were imprisoned in the flank and left hypochondrium, laterally to the lowered colon (Fig. 4). The herniated intestinal segment was carefully reduced and showed no signs of ischemia or necrosis. The mesocolon defect was corrected from its caudal portion, near the sacral promontory, to the duodenal-jejunal flexure, through a continuous suture of absorbable cord. The colorectal anastomosis was intact. After the correction of the mesocolon defect, the abdominal wall was closed by planes. The patient presented favorable evolution, being discharged from hospital on the 5th day after the second intervention and is currently well without recurrence of symptoms six months after the second surgery.

Discussion

Laparoscopic colectomies performed by trained surgeons have similar postoperative complications, and even lower ones, than those found when using the conventional approach.¹⁻³ However, resections of the colon and rectum through laparoscopic access are not risk-free and may evolve with postoperative complications in a percentage ranging from

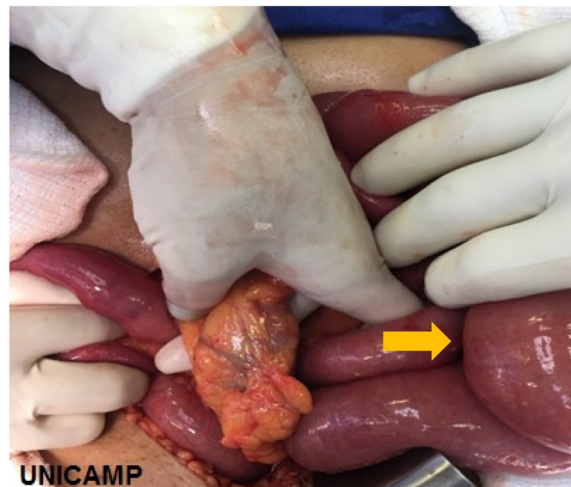


Fig. 4 – Intraoperative photograph where the descending colon is seen lowered with the hand of the surgeon circling the defect of the mesocolon. Jejunal loops passing through the defect toward left colic peritoneal reflection (arrow direction).

14% to 16% of cases.^{4,5} These complications include reoperations due to bowel obstructions caused by adhesions, volvulus, anastomoses, and, more rarely, IH.^{1,4,6-27} Studies have shown that the incidence of small bowel obstruction following laparoscopic colectomies ranges from 0.7% to 2.8%, which are lower when compared to those found with the use of conventional access.^{1,5-7,9} The most frequent cause of intestinal obstruction is Richter's hernia at the trocar site.²⁰ Intestinal adhesions also represents a common cause of intestinal obstruction after laparoscopic colectomies.³ The development of IH, herniation of the small bowel through the mesenteric defect, is not a common cause of intestinal obstruction.^{9,20} This complication seems to be more frequently described when the colon is removed by laparoscopic access due to difficulty to close the defect of the mesocolon. Most of the surgeons that use open approach close the mesocolon gap at the end of the operation. The suture of the mesocolon defect is considered as part of the technical systematization, precisely with the purpose of preventing the formation of IH.³ To further evaluate and help clarify the importance of the systematic closure of the mesocolon defect, Causey et al.²⁸ reviewed the follow-up of 133 patients submitted to different types of colonic resections performed by sixteen different surgeons. They showed that the presence of anastomoses dehiscence's and bowel obstruction was greater in patients where the defect of the mesocolon was systematically corrected.²⁸ They concluded that the closure of the mesocolon defect is associated with high rates of complication and does not show any benefit in patients submitted to colectomy. However, it is important to note in this study that 76% of patients had undergone colectomy by open access. The authors found only one case of anastomotic fistula in a patient undergoing to a right laparoscopic colectomy. At no point did the authors describe the presence of intestinal obstruction by IH in those patients submitted to colonic resections by laparoscopy.²⁸

Table 1 – Internal hernia after laparoscopic colorectal resections: case review.

References	n	Age	Sex	Onset d (day) y (years)	Resected colon	Closure of the mesocolic defect	Reoperative surgery	Intestinal resection	Postoperative course	Recommendation
Kok et al. (1996) ⁷	1	64	F	90 d	Left	–	–	No	Recovered	–
Elio et al. (1998) ¹⁵	1	46	F	60 d	Left	No	Seal	No	Recovered	Close
Lacy et al. (1997) ¹	1	–	–	30 d	Left	No	–	–	Recovered	Close
Kawamura et al. (1999) ⁶	1	47	F	20 d	Left	Partial	–	No	Recovered	Close
Blanc et al. (2003) ¹⁴	1	50	M	35 d	Left	–	Suture	No	Recovered	Close
Nagata et al. (2005) ²⁰	1	55	F	15 d	Transverse	No	Seal	No	Recovered	Close
Sabbagh et al. (2005) ¹³	1	47	M	60 d	Left	No	Suture	No	–	–
Hosono et al. (2007) ¹⁰	1	58	F	7 d	Transverse	No	Suture	Yes	Recovered	Selective close
Jimi et al. (2007) ⁹	1	69	F	59 d	Right	No	Suture	Yes	Recovered	Close
Díez Tabernilla et al. (2008) ⁴	1	62	F	7 y	Left	–	Suture	No	Recovered	Close
Sereno Trbaldo et al. (2009) ²⁴	5	69 (60–78)	M	1–5 d	Left	No (3) Yes (2)	Suture (3) Hartmann (1) Enterectomy (1)	Yes (2)	Recovered (2) Death (1) Recovered (3) Death (1)	Close
Cabot et al. (2010) ¹⁷	4	–	–	3 d 240 d	Right	No	No	Yes (2)	–	No
Saklani et al. (2012) ²³	2	70 85	F F	60 d 2 d	Left Left	No No	Enterectomy No	Yes No	– Recovered	–
Ansari et al. (2013) ¹¹	3	63 48 68	F M F	115 d 97 d 17 d	Left Left Left	– – –	No No No	No No No	Recovered Recovered Recovered	No
Erguner et al. (2013) ²¹	1	–	–	–	Right	–	–	Yes	–	–
Masubuchi et al. (2013) ²²	1	57	F	3.6 y	Transverse	No	Suture	No	Recovered	Selective close
Yoshida et al. (2014) ²⁵	1	61	M	6 d	Subtotal	No	Suture	No	Recovered	Close
Sugiyama et al. (2016) ²⁷	2	61 82	F F	21 d 13 d	Right Transverse	No No	By pass Suture	No No	– –	Close
Nair et al. (2015) ¹⁶	1	29	F	–	Subtotal	–	Suture	No	Recovered	Selective close
Daskalaki et al. (2015) ¹²	1	73	M	3 a	Left	–	No	No	Recovered	Close
Angelini et al. (2017) ⁸	1	77	M	3 d	Left	No	Fibrin glue	No	Recovered	Close
Sugita et al. (2017) ²⁶	1	74	F	90 d	Left	No	Suture	Yes	Recovered	Close
Svraka et al. (2017) ¹⁸	6	–	F	7 y	Left	No	Suture	Yes	Recovered (5)	Selective close
			F	5 a	Left		IR + suture	(2)		
			F	71 d	Left		IR + suture			
			M	5 d	Right		Suture		Death (1)	
			F	3 d	Right		Suture			
			M	6 d	Right		Suture			
Present case	1	59	F	5 d	Left	No	Suture	No	Recovered	Close

IR, intestinal resection.

The true incidence of IH by the mesocolon defect after laparoscopic colectomies remains unknown.⁸ Most of the publications describing the complication are retrospective studies or consist mainly of case reports or a series of cases.^{4,6–24} Systematic review of the literature evaluating 3813 patients undergoing laparoscopic colectomy found only 31 cases of IH indicating an incidence of only 0.65%.¹⁹ Five of these cases were identified in two prospective studies (5/648, 0.8%), 20 cases were found in seven retrospective studies (20/3165, 0.6%) and six in case reports (31/3819).¹⁹ Other authors, reviewed a total of 1093 patients undergoing laparoscopic colorectal resections. They found only six cases (6/1093) of IH, representing an incidence of 0.55%.¹⁸ The results of these two studies suggest that the development of IH by the mesocolon defect is an uncommon or, more likely, rarely described event. It is probable that the true incidence of IH may be underestimated, since many surgeons who experienced the complication did not publish their cases.¹⁸ When we performed the review of the literature for the preparation of this article, we identified other four cases, making a total of 39 cases besides the patient in the present report (Table 1).

IH, although uncommon, may occur after resection of the right colon, transverse colon, subtotal colectomies, proctocolectomies with ileal reservoir construction and, mainly, after resection of the left colon, as described in the patient of the present report.^{1,4,6–22} Most of the cases of IH due to the mesocolon defect described in the literature occurred after left colon resections (left colectomy, sigmoidectomy and rectal anterior resections) as occurred in the patient of the present report.^{7,8,23} Cabot et al.¹⁷ reviewing 530 patients undergoing laparoscopic right colon resection found 26 cases of intestinal obstruction (4.9%). Twelve patients (46%) improved from intestinal obstruction only with clinical measurements. Fourteen (54%) of these patients were treated surgically, and in only 4 (0.8%), the intestinal obstruction was related to problem with the mesocolon defect.¹⁷ However, two of these patients actually had anastomosis volvulus inside the mesocolon defect and the two remaining had an IH. The authors note that in 2/12 patients who showed improvement only with conservative treatment, the CT scans showed the presence of IH. Thus, they believe that the incidence of IH after right colectomy may be underestimated, since a percentage of patients improve only with expectant treatment.¹⁷

With respect to IH after left colectomy, the two largest published series identified eight cases suggesting an incidence between 0.55% and 1.14%.^{18,24} Similarly, another study evaluating 297 patients who underwent anterior resection of the rectum after a 6 year follow-up showed an incidence of 1.01%.¹¹ As occur with right colectomy, it is important to consider that probably the incidence of IH after resection of the left colon may also be underestimated by the small number of publications, as well as by the favorable evolution that a good part of the patients present only with conservative treatment.¹⁷ As an example, in a series of 167 laparoscopic colectomies, where only eight patients underwent resection of the left colon, the authors had to operate two of them due to intestinal obstruction caused by IH.²³

Most cases of intestinal obstruction related to the presence of IH by the mesocolon defect usually occur in the early postoperative period.¹⁸ A systematic review showed that

approximately 70% of cases of IH post-laparoscopic colectomies occurred within the first 10 days of the initial surgery, similar to the patient in this report.¹⁹ However, other authors have shown that intestinal obstruction can occur several years after the initial surgery.^{10,18} Svraka et al.¹⁸ identified six cases of IH after performing more than 1000 colorectal resections by laparoscopy. They showed that 3 (50%) of these patients had intestinal obstruction after 71 days, 5 years and 7 years of the initial surgery. In one of them there was a need for intestinal resection due to necrosis of the colon. Cabot et al.¹⁷ draw attention to the fact that one of their patients developed intestinal obstruction within the first 10 days after the initial operation. However, the second patient developed intestinal obstruction eight months after laparoscopic colectomy.¹⁷ They report that in both cases there was necessary resection of the previous colonic anastomosis. One of these patients improved and did not present any more episodes of intestinal obstruction. However, the second patient died on the 3rd day after reoperation.¹⁷ The possibility that late bowel obstruction due to IH may become relevant especially in those patients who develop recurrent abdominal cramps, or episodes of intestinal subocclusion, months or years after laparoscopic colectomy. These patients should be carefully investigated with imaging examinations, in order to avoid the possibility that abdominal cramps may result from chronic IH through the mesocolon opening.¹⁸ Delay in diagnosis, regardless of intestinal obstruction occurring in the early or late postoperative period, considerably increases morbidity and mortality rates.^{9,18}

Several etiopathogenic mechanisms were proposed to explain the development of IH after laparoscopic colectomies, particularly the through the left colon. Sereno Trabaldo et al.²⁴ propose that the pathophysiology of IH is multifactorial. They believe that the laparoscopic access route by decreasing the formation of intracavitary adhesions allows the free movement of the small bowel inside the abdominal cavity, thus increasing the possibility of migration of these intestinal loops through the mesocolon defect.²⁴ They remember that the laparoscopic access due is associated with less postoperative pain and allows the patient to move earlier, which could facilitate the migration of the intestinal loops through the mesocolon defect. The increase in mesenteric tension under the herniated bowel loops caused by early movement is also remembered as an additional factor that contributes to the incarceration of herniated loops.²⁴ They also call attention to two important anatomical considerations that may contribute to the development of IH after laparoscopic left colectomy. Recall that the duodenojejunal ligament (Treitz angle) represents the point of fixation for rotation of the small intestine. As the ligament is located at the root of the transverse mesocolon, it naturally holds the proximal jejunal loops near the posterior abdominal wall. When there is a formation of defect in the mesentery of the descending colon, it begins close to this site, allowing the jejunal loops to slide toward the colonic and left inguinal regions.²⁴ A second anatomical aspect that the authors still emphasize is related to the anatomical axis of the mesentery. Topographically, the mesentery of the small intestine is anchored in the posterior abdominal wall in a caudal, left-to-right and posterior-anterior direction. This anatomical arrangement creates, by gravity, a natural tendency for the

jejunal loops to move downward toward the left iliac fossa. As the left mesocolon is situated in the pathway between this point and the root of the mesentery of the small intestine it can be easily deduced that a defect in the site would be the perfect space for the herniation of the small intestine loops.²⁴ However, it should be remembered that these anatomical considerations are not capable of explaining IH that develop after laparoscopic resections of the right colon.

Another aspect that deserves reflection, concerns the release of the left flexure of the colon to make a colorectal anastomosis without tension. When the splenic flexure of the colon is not dissected and mobilized, the mesentery of the transverse colon is drawn down toward the pelvis. If the splenic flexure is not released, there is an area of greater tension between the lowered mesocolon and the retroperitoneum which could, at least theoretically, prevent the passage of the small intestine through the mesocolon defect. On the other hand, if the small intestine loops can pass under the defect there would be a greater possibility of incarceration. This peculiarity makes many surgeons prefer to keep the defect fully open, only by positioning the intestinal loops above the mesocolon gap, as we have done.²² However, it should be noted that, even taking this precaution, there are some cases of intestinal obstruction due to IH, similarly to occurred with the patient of the present report.^{25,26}

The precise diagnosis that an intestinal obstruction results from the development of an IH, begins with a careful clinical history. Importantly, the time to onset of symptoms between the initial surgery and the bowel obstruction may vary from hours to years. Thus, the surgeon should always consider the possibility that a late obstruction, in a patient previously submitted to laparoscopic left colectomy, may be related to IH. Regarding imaging methods, the occurrence of IH can be suspected in abdominal radiographic series. In the patient of the present study, the abdominal series showed tortuous dilated small intestinal (jejunum) loops with visible convex valves, grouped mainly in the upper left quadrant of the abdomen, suggestive findings of intestinal obstruction by IH. However, CT scan of the abdomen presents greater diagnostic acuity, since it adds complementary information such as: abnormalities in the pattern of distribution of the mesentery vessels of the herniated intestine segment, increase of the blood vessels that are twisted and elongated at the point of obstruction and a higher concentration of small intestine loops, particularly the initial portions of the jejunum, to the left of the lowered colon. In patients where the diagnosis was late, CT of the abdomen may show signs of vascular thrombosis, necrosis of the herniated gut, and pneumoperitoneum in cases where there is visceral perforation. However, it is important to highlight that if the CT images do not show signs of intestinal obstruction, the presence of IH cannot be completely excluded.¹⁸

The prevention of IH by correcting the mesocolon defect still raises hot debates in the scientific community. It should be noted that correction of IH is complex procedure most often performed with the patient under critical conditions, require intestinal resection in more than 50% of cases, and the mortality rate can reach 20%.²⁴ Thus, the best way to prevent this catastrophic complication is to prevent it from occurring. There is little evidence in the literature showing that routine closure of the mesocolon defect is capable of

reducing the incidence of IH.^{17,28} Surgeons who advocate the systematic closure of the mesocolon defect remember that in conventional colectomies, where defect correction is routinely performed, the incidence of IH is much lower.^{4,10,15} Those who believe that correction of the mesocolon defect also remember that there was a significant reduction in the number of IH cases after bariatric surgeries, once the mesenteric defect was systematically closed. Sugiyama et al.²⁷ with the aim to evaluating the importance of the correction of mesocolon defect, evaluated 58 patients consecutively submitted to proximal colectomy. In 30 patients the opening was closed, whereas in 28 the defect was not corrected. They found two cases of intestinal obstruction due to IH through the mesenteric defect.²⁷ In both patients, who required reoperations, the mesocolon defect had not been corrected in the first surgery. When comparing the duration of intervention and the blood loss, they found no differences, but with a significant lower rate of reoperations in patients where the defect was corrected. Based on these findings, they recommend the correction of the mesocolon defect systematically in laparoscopic proximal colectomies. Angelini et al.⁸ published an interesting study where they showed the experience of the group with 107 resections of the left colon or anterior rectal resections performed in a period of 10 years. In the first 298 procedures, they did not correct the mesocolon defect, having witnessed a case of intestinal obstruction due to IH (0.66%). After that in the following 781 cases they began to correct the defect using fibrin glue and did not identify any case of IH.⁸

Surgeons who prefer to leave the open mesenteric defect remember that the incidence of IH is very low, besides the fact that the correction of this defect by laparoscopy is not always possible to be performed safely, representing a great technical challenge.^{8,12,16–18,28} The closure of the mesocolon defect, increases the surgical time and, requires great technical training in laparoscopic suture. In poorly trained hands the attempt to suture the mesocolon gap can cause ureteral lesions or damage of the marginal vessels, allowing the development of ischemic complications of the anastomosed colon and consequently fistulas.^{11,17,22,28} Proponents of non-correction of the mesenteric defect also recall that incomplete closure may form a smaller orifice that increases the risk of intestinal obstruction.^{10,20,28} Causey et al.²⁸ found an odds ratio of post-operative complications 5.5 times greater when the defect of the mesocolon was systematically closed. It should be noted that the authors included in the study most patients undergoing open colectomy and found no case of IH and only one case of anastomosis leakage in patients undergoing laparoscopic colectomy.²⁸ Reviewing the published cases of IH after laparoscopic colorectal resections, the mesocolon defect was corrected in only 20% of cases of intestinal obstruction. In most patients presenting with IH (80%), the mesocolon defect had been left open in the initial intervention, as we have done in the patient of this report.

When it is considered that intestinal obstruction due to IH, although rare, is a serious complication, associated with high mortality rates, the routine closure of the mesocolon defect seems justified.⁴ Although there is no consensus regarding the closure or not of the mesocolon defect after laparoscopic left colectomy, several techniques have been proposed to correct

it, thus trying to prevent the development of IH.^{15,21,24} Among them, the closure through simple sutures, the application of clips, the use of sealers, the application of fibrin glue and the filling of the defect with flaps of the large omentum should be highlighted.^{15,22,24} Elio et al.¹⁵ proposed the correction of the mesocolon defect using continuous suture or clips. However, other authors have described cases of IH after the use of sealers and clips.²⁴ The use of a sealant is not able to keep the defect completely closed and the application of clips can damage the fragile mesocolon tissue, even in cases where the left colic flexure have been completely released.²⁴ Although defect correction through continuous suturing is the most commonly employed technique, this option does not completely prevent the damage to fat mesocolon tissue. Angelini et al.⁸ after routine use of fibrin glue to correct the mesocolon gap has not experienced more cases of IH. However, the use of fibrin glue, in addition to increasing the costs of the procedure, is not always available in most centers. Masubuchi et al.²² when cannot correct the defect through suture recommend the obliteration of the defect with the use of an omentum flap. Blanc et al.¹⁴ suggest carefully repositioned of the jejunal loops to the right and above the mesocolon defect and section of the Treitz ligament. They believe that the ligament section would position the jejunal loops in a more caudal direction, making it difficult to inherit the mesocolon defect.¹⁴ In the patient of the present report, although we did not have sectioned the Treitz ligament the jejunal loops we carefully repositioned above of the defect but, despite this care, IH occurred.

The recommendation for the systematic closure of the mesocolon defect after laparoscopic colectomy will continue to be the subject of intense and hot debates among laparoscopic colorectal surgeons. Multicenter, randomized trials involving a large number of patients, is the only way to answer this question. However, because of the low incidence of IH after laparoscopic colectomies, these studies are difficult to be performed. In our opinion, after reviewing all the cases published to date, we believe that due to the risk of complications related to the development of IH, with the need for complex reoperations, longer hospitalization and not negligible rates of morbidity and mortality, the closure of mesocolon defect should be entirely performed whenever possible. When we consider that intestinal obstruction by an IH may course with a fatal outcome, it may already be enough evidence to recommend the correction of the mesocolon defect.

Conflicts of interest

The authors declare no conflicts of interest.

REFERENCES

- Lacy AM, García-Valdecasas JC, Delgado S, Grande L, Fuster J, Tabet J, et al. Postoperative complications of laparoscopic-assisted colectomy. *Surg Endosc*. 1997;11:119–22.
- Sheetz KH, Norton EC, Birkmeyer JD, Dimick JB. Provider experience and the comparative safety of laparoscopic and open colectomy. *Health Serv Res*. 2017;52:56–73.
- Deijen CL, Vasmel JE, de Lange-de Klerk ESM, Cuesta MA, Coene PLO, Lange JF, et al., COLOR (Colon cancer Laparoscopic or Open Resection) study group. Ten-year outcomes of a randomized trial of laparoscopic versus open surgery for colon cancer. *Surg Endosc*. 2017;31:2607–15.
- Diez Tabernilla M, Die Trill J, López Hervás P, Fresneda Moreno V. Hernia Interna Tras sigmoidectomía laparoscópica. *Cir Esp*. 2008;83:45–7.
- Campos FG. Complications and conversion in laparoscopic colorectal surgery. Results of a multicenter Brazilian trial. *Surg Laparosc Endosc*. 2003;3:173–9.
- Kawamura YJ, Sunami E, Masaki T, Muto T. Transmesenteric hernia after laparoscopic-assisted sigmoid colectomy. *JSLs*. 1999;3:79–81.
- Kok KY, Ngoi SS, Kum CK, Tekant Y, Tasci I, Goh P. Laparoscopic-assisted large bowel resection. *Ann Acad Med Singap*. 1996;25:650–2.
- Angelini P, Sciuto A, Cuccurullo D, Pirozzi F, Reggio S, Corcione F. Prevention of internal hernias and pelvic adhesions following laparoscopic left sided colorectal resection: the role of fibrin sealant. *Surg Endosc*. 2017;31:3048–55.
- Jimi S, Hotokezaka M, Eto TA, Hidaka H, Maehara N, Matsumoto K, et al. Internal herniation through the mesenteric opening after laparoscopy-assisted right colectomy: report of a case. *Surg Laparosc Endosc Percutan Tech*. 2007;17:339–41.
- Hosono S, Ohtani H, Arimoto Y, Kanamiya Y. Internal hernia with strangulation through a mesenteric defect after laparoscopy-assisted transverse colectomy: report of a case. *Surg Today*. 2007;37:330–4.
- Ansari N, Keshava A, Rickard MJ, Richardson GL. Laparoscopic repair of internal hernia following laparoscopic anterior resection. *Int J Colorectal Dis*. 2013;28:1739–41.
- Daskalaki A, Kaimasidis G, Xenaki S, Athanasakis E, Chalkiadakis G. Internal-mesocolic hernia after laparoscopic left colectomy report of case with late manifestation. *Int J Surg Case Rep*. 2015;6C:88–91.
- Sabbagh C, Vibert E, Renou M, Yzet T, Regimbeau JM. A rare cause of intestinal obstruction after laparoscopic colectomy. *J Chir (Paris)*. 2005;142:44–5.
- Blanc P, Delacoste F, Atger J. A rare cause of intestinal obstruction after laparoscopic colectomy. *Ann Chir*. 2003;128:619–21.
- Elio A, Veronese E, Frigo F, Residori C, Salvato S, Orcalli F. Ileal volvulus on internal hernia following left laparoscopic-assisted hemicolectomy. *Surg Laparosc Endosc*. 1998;8:477–8.
- Nair HS, Watt KA, Anderson DN. Internal hernia and small bowel obstruction following open ileoanal pouch formation: a case report. *Int J Surg Case Rep*. 2015;11:68–70.
- Cabot JC, Lee SA, Yoo J, Nasar A, Whelan RL, Feingold DL. Long-term consequences of not closing the mesenteric defect after laparoscopic right colectomy. *Dis Colon Rectum*. 2010;53:289–92.
- Svraka M, Wilhelmisen M, Bulut O. Internal hernia following laparoscopic colorectal surgery: single center experience. *Pol Prz Chir*. 2017;89:19–22.
- Toh JW, Lim R, Keshava A, Rickard M. The risk of internal hernia or volvulus post laparoscopic colorectal surgery: systematic review. *Colorectal Dis*. 2016;18:1133–41.
- Nagata K, Tanaka J, Endo S, Tatsukawa K, Hidaka E, Kudo SE. Internal hernia through the mesenteric opening after laparoscopy-assisted transverse colectomy. *Surg Laparosc Endosc Percutan Tech*. 2005;15:177–9.
- Erguner I, Aytac E, Baca B, Hamzaoglu I, Karahasanoglu T. Total laparoscopic approach for the treatment of right colon cancer: a technical critique. *Asian J Surg*. 2013;36:58–63.
- Masubuchi S, Okuda J, Tanaka K, Kondo K, Asai K, Kayano H, et al. An internal hernia projecting through a mesenteric defect following laparoscopic-assisted partial resection of the

- transverse colon to the lesser omental cleft: report of case. *Surg Today*. 2013;43:814–7.
23. Saklani A, Naguib N, Tanner N, Moorhouse S, Davies CE, Masoud A. Internal herniation following laparoscopic left hemicolectomy: an underreported event. *J Laparoendosc Adv Surg Tech A*. 2012;22:496–500.
 24. Sereno Trbaldo S, Anvari M, Leroy J, Marescaux J. Prevalence of internal hernias after laparoscopic colonic surgery. *J Gastrointest Surg*. 2009;13:1107–10.
 25. Yoshida T, Kinugasa T, Oka Y, Mizobe T, Ishikawa H, Mori N, et al. Bowel obstruction caused by an internal hernia that developed after laparoscopic subtotal colectomy: a case report. *J Med Case Rep*. 2014;8:470.
 26. Sugita H, Akiyama T, Daitoku N, Tashima R, Tanaka H, Honda S. Internal hernia after laparoscopic right hemicolectomy, report of a case. *J Surg Case Rep*. 2017;2017, rjw217.
 27. Sugiyama M, Sakaguchi Y, Oki E, Kusumoto E, Kimura Y, Tsutsumi N, et al. Clinical significance of closure of mesenteric defects in laparoscopic colectomy: single-institutional cohort study. *Surg Laparosc Endosc Percutan Tech*. 2016;26:82–5.
 28. Causey MW, Oguntoye M, Steele SR. Incidence of complications following colectomy with mesenteric closure versus no mesenteric closure: does it really matter? *J Surg Res*. 2011;171:571–5.