

Intraneural ganglion cysts of the lower limb

Intraneurale Ganglionzysten der unteren Extremität

Authors

Tobias Fricke¹, Anne Dorothee Schmitt², Olav Jansen¹

Affiliations

- 1 Department of Radiology and Neuroradiology, Universitätsklinikum Schleswig-Holstein, Campus Kiel, Germany
- 2 Department of Neurosurgery, Universitätsklinikum Schleswig-Holstein, Campus Kiel, Germany

Key words

nervous-peripheral, muscular, intraneural ganglion cyst, neuropathy, MR imaging

received 28.06.2018

accepted 16.10.2018

Bibliography

DOI <https://doi.org/10.1055/a-0777-2525>

Published online: 19.11.2018

Fortschr Röntgenstr 2019; 191: 732–738

© Georg Thieme Verlag KG, Stuttgart · New York

ISSN 1438-9029

Correspondence

Dr. Tobias Fricke

Radiologie und Neuroradiologie, Universitätsklinikum Schleswig-Holstein Campus Kiel, Arnold-Heller-Straße 3, 24105 Kiel, Germany

Tel.: ++ 49/4 31/50 01 65 00

tobiasfricke2@hotmail.de

ABSTRACT

Background Intraneural ganglion cysts are rare. They affect the peripheral nerves. According to the most widely accepted theory (articular/synovial theory), the cysts are formed from a capsular defect of an adjacent joint, so that synovial fluid spreads along the epineurium of a nerve branch. This leads to diverse neurological symptoms. We will illustrate this disease based on three of our own cases.

Methods Patients were examined between 2011 and 2018 using lower limb MRI. MRI scans were also performed for the follow-up examinations.

Case studies and Discussion The patients had many symptoms. We were able to accurately detect the intraneural ganglion cysts on MRI and provide the treating surgeons with the basis for the operation to be performed. The success of surgical therapy depends on the resection of the nerve endings supplying the joint as the only way to treat the origin of the disease and prevent recurrence. Based on our case studies,

we can support the commonly favored articular/synovial theory.

Key Points:

- Intraneural ganglion cysts can cause diverse neurological symptoms depending on their location.
- The pathogenesis is reasonably explained by the articular/synovial theory, which states that cysts are the result of a capsular defect of a joint.
- MRI is the method of choice for diagnosing intraneural ganglion cysts. However, ultrasound is also important.
- Surgery is the only curative treatment with treatment success being dependent on ligation of the nerve endings supplying the articular branch.

Citation Format

- Fricke T, Schmitt AD, Jansen O. Intraneural ganglion cysts of the lower limb. Fortschr Röntgenstr 2019; 191: 732–738

ZUSAMMENFASSUNG

Hintergrund Bei intraneuralen Ganglionzysten handelt es sich um eine seltene Pathologie, welche die peripheren Nerven betrifft. Die Zysten entstehen gemäß der anerkanntesten Theorie (Gelenk-/Synovial-Theorie) aus einem Kapseldefekt eines benachbarten Gelenks, sodass sich Gelenkflüssigkeit entlang des Epineuriums eines Nervenastes ausbreitet. Dadurch kommt es zu den entsprechenden neurologischen Symptomen. Anhand von 3 eigenen Kasuistiken soll dieses Krankheitsbild dargestellt werden.

Methoden Die Patienten wurden zwischen 2011 und 2018 mittels MRT der unteren Extremitäten untersucht. Auch für die Nachuntersuchungen wurden MRTs durchgeführt.

Kasuistiken und Diskussion Die von uns beschriebenen Patienten zeigten vielfältige Symptome. Durch die MRT konnten wir die intraneuralen Ganglionzysten exakt detektieren und so den behandelnden Kollegen die Basis für die durchzuführenden Operationen liefern. Die operative Therapie bei intraneuralem Ganglion besteht in der Dekompression der Nerven/der Ganglionzysten und Ligation des versorgenden Gelenkastes; letzteres ist für die Prognose entscheidend, da nur so der Ursprung der Erkrankung behandelt wird und Rezidive verhindert werden. Durch unsere Fallbeispiele können wir die allgemein favorisierte Gelenk-/Synovial-Theorie unterstützen.

Background

Damage to the peripheral nerves can cause various symptoms depending on the affected nerves and the severity of the injury. Such damage can have a variety of causes, such as penetrating injuries, indirect trauma, or metabolic diseases like diabetes [1]. While injury to the peripheral nerves, e. g. the tibial nerve, is common, intraneural ganglion cysts in the peripheral nerves are much rarer. They usually occur in adults. Intraneural ganglia are non-neoplastic cysts caused by the collection of mucinous fluid in the dense, fibrous capsules of the epineurium. These cysts can cause compression of the adjacent nerve fascicles, resulting in corresponding symptoms like pain, paresthesia, weakness, muscle denervation, and muscle atrophy [2].

The etiology of intraneural ganglion cysts is controversial. However, in recent years, the articular/synovial theory has become the most widely accepted theory. According to this theory, cysts are formed from a capsular defect of an adjacent joint so that synovial fluid spreads along the epineurium of a nerve branch (► **Fig. 1**) [3]. Therefore, intraneural ganglion cysts occur at sites at which there is a nerve branch that supplies the joint and provides sensory information from the joint, in particular nociception and proprioception, to the central nervous system [4]. Intraneural ganglion cysts can be virtually invisible on MRI scans but still result in neuropathy in patients because the size and morphology of these cysts can vary [5]. However, the MRI method also has a decisive effect on the ability to visualize intraneural cysts. High structural resolution can be achieved with MR neurography so that individual nerve fascicles can be visualized and intraneural cysts can be detected already in the initial stage [8, 9]. Some cysts extend, for example, from the peroneal nerve to the sciatic nerve and then to the tibial nerve [6]. The fluid from the joint capsule follows the path of least resistance. The pressure exerted by the knee joint on the ganglion cysts explains the dynamic features of the formation of some ganglion cysts with ascent within the epineurium, crossing of nerve branches, and descent [7].

Intraneural ganglion cysts can be associated with any joint but most commonly affect the peroneal nerve in connection with the proximal tibiofibular joint [10]. In contrast, intraneural ganglion cysts of the tibial nerve tend to be rare [2, 11].

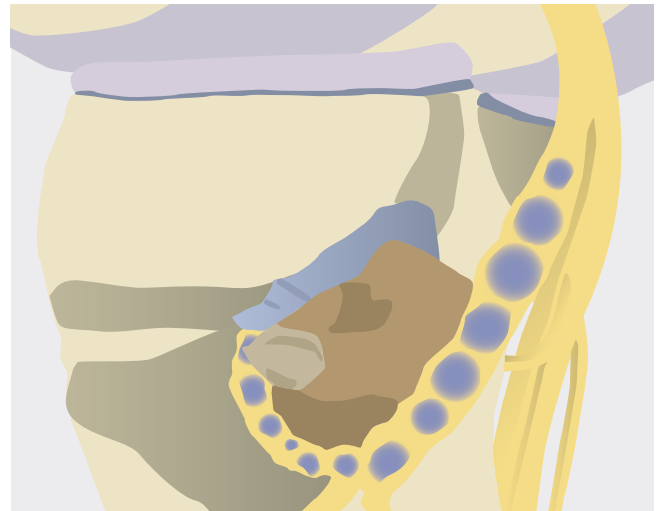
MRI is the method of choice for diagnosing intraneural ganglion cysts. It provides detailed characterization of the lesions and shows the subsequent muscle denervation [12, 13].

The following describes three of our own case studies to show the clinical and morphological diversity of this disease on MRI.

Methods

All MRI examinations were performed between 2011 and 2018. The MRI units and sequences were as follows:

Patient 1, male, 66 years old, initial examination of the left leg (Philips Achieva 3.0-T, Philips Medical Systems, Best, The Netherlands): The following native sequences were selected: Coronal T1-weighted turbo spin echo sequence; transverse T2-weighted turbo spin echo sequence; coronal, fat-saturated SPAIR sequence; coronal, T1-weighted SPIR sequence. The following contrast-



► **Fig. 1** Formation of intraneural ganglion cysts along the peroneal nerve from the proximal tibiofibular joint.

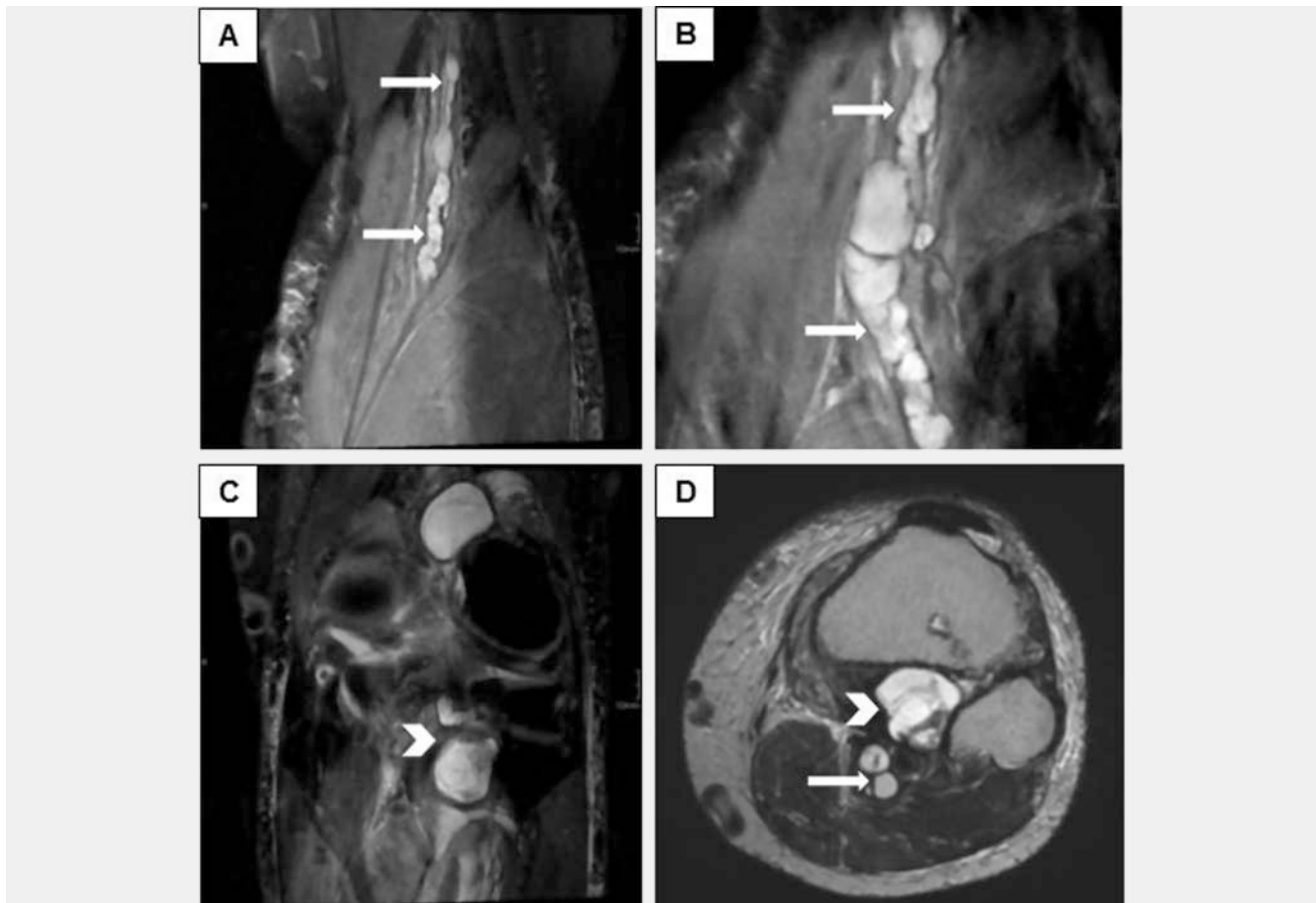
enhanced sequences were performed: Transverse, T1-weighted, 3D-compatible sequence; transverse, fat-saturated, T1-weighted sequence; sagittal, fat-saturated T1-weighted sequence; transverse, T1-weighted SPIR sequence.

Patient 2, male, 15 years old, initial examination of the right leg (Philips Achieva 1.5-T, Philips Medical Systems, Best, The Netherlands): The following native sequences were performed: Coronal STIR sequence; sagittal T1-weighted SPIR sequence; coronal STIR sequence; transverse, T1-weighted turbo spin echo sequence. The following contrast-enhanced sequence was performed: Transverse, fat-saturated, T1-weighted turbo spin echo sequence.

Follow-up examination of the right leg performed at a different facility (Philips Gyroscan NT 1.5-T, Philips Medical Systems, Best, The Netherlands): The following native sequences were performed: Coronal and transverse STIR sequence; sagittal, T2-weighted turbo spin echo sequence; coronal, T1-weighted turbo spin echo sequence. The following contrast-enhanced sequences were performed: Transverse and sagittal T1-weighted STIR sequence.

Patient 3, female, 64 years old, initial examination of the left leg performed at a different facility (Philips Ingenia 1.5-T, Philips Medical Systems, Best, The Netherlands): The following native sequences were performed: 3D-reconstructed, T1-weighted sequence; 3D-reconstructed, fat-saturated, T1-weighted sequence; sagittal, T1-weighted turbo spin echo sequence; sagittal, coronal, and transverse SPAIR sequence; 3D mFFE WATS.

Follow-up examination of the left knee joint (Siemens Aera 1.5-T, Siemens Healthcare, Erlangen, Germany): The following native sequences were performed: Coronal and transverse, PD- and T2-weighted turbo spin echo sequence; transverse, T1-weighted TIRM sequence; diffusion-weighted sequences; sagittal PD-weighted SPACE sequence.



► **Fig. 2** MRI examination of patient 1. **a, b** Intraneural ganglion cysts along the tibial nerve (arrows) in the course of the popliteal fossa. **c, d** Connection of the cysts in the tibial nerve (arrow) with the dorsal knee joint capsule over a large ganglion cyst (arrowheads), corresponding to the course of the nerve branches supplying the joint.

Case studies

Patient 1, male, 66 years old:

The patient presented with severe stabbing pain in the lower leg and the left foot sole as well as toe flexor weakness on the left side that he had been experiencing for approximately one year. His clinical symptoms included areflexia and paresthesia. The patient also exhibited dorsal flexor and plantar flexor paresis (severity IV/V).

6 years ago the patient was diagnosed with Churg-Strauss syndrome with apparent involvement of the vasa nervorum. In addition, the patient had a history of neuropathy of the right foot with electrophysiological verification of polyneuropathy classified as a consequence of the underlying disease. After onset of the acute symptoms, deep vein thrombosis of the left lower leg with intermittent significant edema of the lower leg was detected. In addition, an ultrasound examination showed dilatation of the tibial nerve. MRI was performed for a more detailed diagnostic workup.

MRI showed isointense cystic lesions resembling a string of pearls along the tibial nerve from the diaphyseal junction of the distal upper leg to the level of the proximal tibiofibular joint. There were no compact increases in soft tissue along the tibial nerve and no suspicious contrast enhancement was seen. In

addition, large isointense cystic lesions arising from the tibial nerve were seen along the nerve branches supplying the femoro-tibial joint. Moreover, a knee effusion with synovitis, gonarthrosis, and retropatellar arthrosis was seen. Denervation edema was seen in the posterior tibial muscle (► **Fig. 2**).

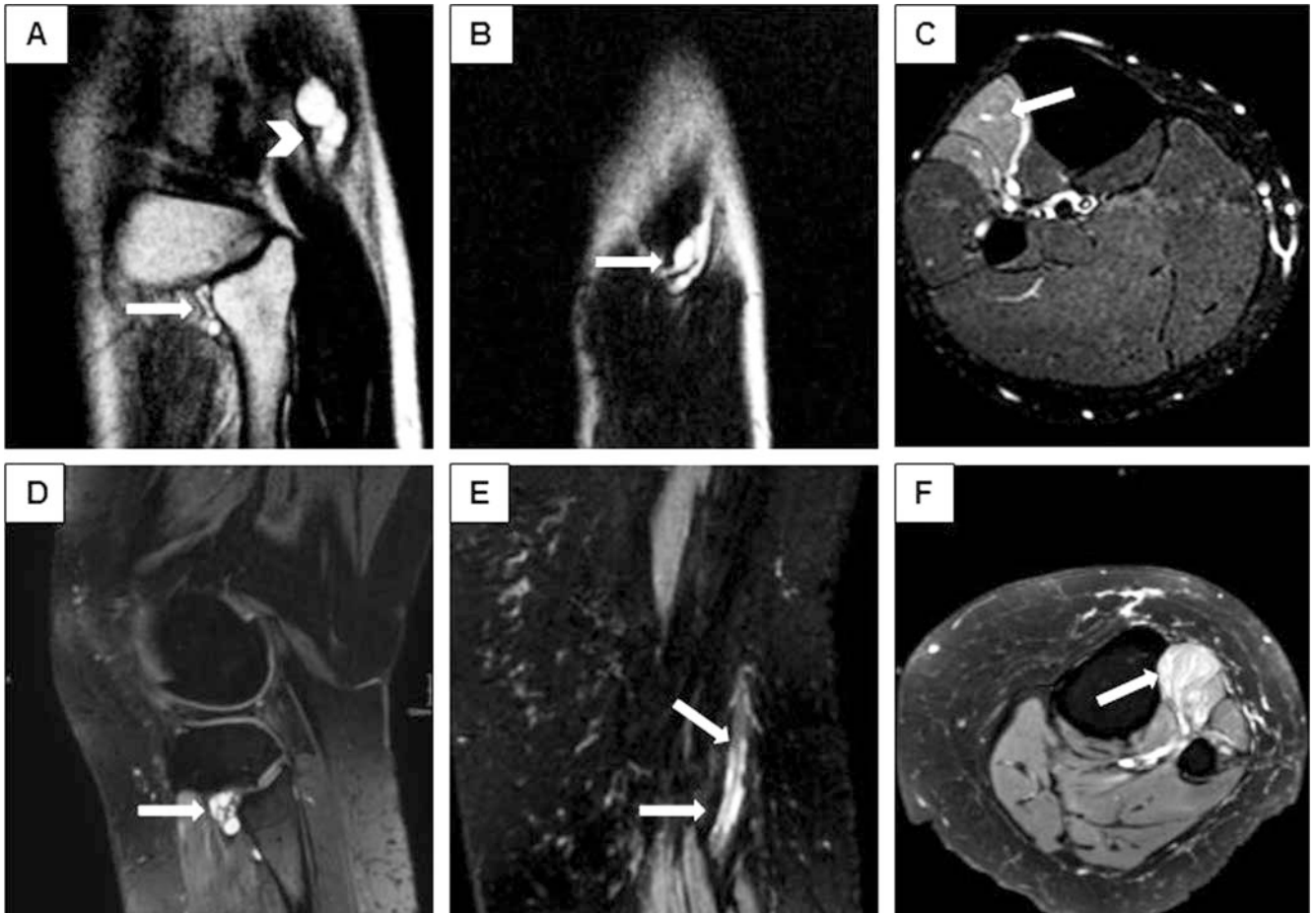
The indication for surgical therapy was determined on a neuro-surgical basis.

The focus of the operation was to identify the nerve branches supplying the joint. These were able to be visualized at the tibio-fibular joint and on the dorsal side of the knee joint and ligated. The cysts surrounding the nerve like a pearl necklace were incised only at prominent locations to allow gelatinous epineurial fluid to drain. Draining along the nerve was not performed.

The patient's symptoms improved significantly after surgery. The paresis had diminished at the time of discharge (severity IV +/V). The patient reported that he was doing generally well after the surgery. He was no longer experiencing shooting pains.

Patient 2, male, 15 years old

The patient described pain in the right shin that he had been experiencing for a year particularly when playing sports. In addition, he had been experiencing paralysis of the dorsal flexor and



► **Fig. 3** MRI scans of patients 1 (a–c) and 3 (d–f, images with kind permission of O. Lehmeberg/ Förde-Radiologicum Kiel). **a, d** Origin of intraneural ganglion cysts from the proximal tibiofibular joint (arrows) and in **a** Continuation to the common peroneal nerve (arrowheads). **b** Further course along the deep peroneal nerve (arrow) to the common peroneal nerve with descent into the superficial peroneal nerve. **c, f** Denervation edema in the extensor compartment (arrows). **e**: Onset of spread of the cystic lesions to the common peroneal nerve (arrows).

numbness in the region of the right shin from the knee down for approximately two months. The clinical neurological examination confirmed the paralysis of the dorsal flexor on the right side and dysesthesia of the right lateral shin and in interdigital space I/II. Otherwise, there was no sensomotoric deficit. Electrophysiological examination showed a complete conduction block in the right peroneal nerve.

MRI showed isointense cystic lesions resembling a pearl necklace and originating from the nerve branch supplying the tibiofibular joint. The lesions extended over the deep peroneal nerve into the distal common peroneal nerve and descended into the superficial peroneal nerve. Edema in the anterior tibial muscle and in the extensor hallucis longus muscle was seen in the extensor compartment (► **Fig. 3a–b**).

Surgery was indicated also in this case. The pressure in the intraneural ganglion cysts was relieved in that the lesions resembling a pearl necklace along the nerve were opened at prominent sites and the gelatinous epineural fluid was drained. A nerve branch supplying the joint could not be visualized and ligated.

The patient continued to experience paralysis of the dorsal flexor and a feeling of numbness post-surgery. He received a right

peroneal splint and crutches and underwent physical therapy. The follow-up MRI showed that the surgically treated intraneural ganglion cysts were virtually unchanged. Therefore, a new surgery was discussed. However, the patient was reluctant to undergo a second intervention given the lack of change in his clinical symptoms. Consequently, a 2-year follow-up MRI examination was scheduled.

Patient 3, female, 64 years old

The patient complained of significant pain in the left lateral malleolus and the left lower leg that she had been experiencing for one week. The pain increased under strain and with longer movement. Pain medication initially caused an improvement. When the pain returned, the woman went to her family physician. Deep vein thrombosis was ruled out.

The patient later complained of new tingling sensations in the outside of the foot and the outside of the left lower leg, dorsal flexor paresis, and hypesthesia of the left foot.

Clinical examination showed weakness in the left dorsal flexor (severity 3/5), and she was not able to stand on her heels. She also

had hypesthesia of the left foot. A subacute peroneal lesion on the left side was suspected.

The MRI examination performed at a different facility showed cystic lesions resembling a pearl necklace in the deep peroneal nerve with further onset in the distal common peroneal nerve starting from a nerve branch supplying the tibiofibular joint and extending directly to the joint. In addition, denervation edema in the extensor compartment was seen (► Fig. 3d–f).

The patient decided to undergo surgical therapy. The intraneural ganglion cysts in the region of the common peroneal nerve were surgically incised. The nerve branch supplying the tibiofibular joint was identified and ligated. The results of the neurological examination performed immediately after surgery were the same as the preoperative results. The patient's paresis was still present but had diminished at the 3-month follow-up examination. Otherwise, the patient was free of clinical symptoms. The MRI follow-up examination showed residual cysts along the common peroneal nerve and decreased but still present denervation edema in the extensor compartment.

Discussion

The fibrous epineurium surrounds the nerve fibers of the peripheral nerves which bundle to form fascicles. Every fascicle is in its own membrane, i. e., the perineurium. Delicate connective tissue, the endoneurium, is located between the nerve fibers in the fascicle. The connective tissue membranes serve among other things to mechanically protect the nerve fibers [14].

A peripheral nerve can have various compositions of motor and sensory fibers. The sensory manifestations of neuropathy include hypesthesia, hypoalgesia, paresthesia, and hyperalgesia. In the case of neuropathy caused by compression, the sensory fibers are usually affected first as in our cases. Symptoms of motor neuropathy normally include paresis, muscle cramps, clonus, and fasciculations [15].

In all described cases the patients initially experienced pain in the corresponding supply regions of the nerves. Moreover, the patients complained of dysesthesia, hypesthesia, and tingling sensations. Parallel to the sensory dysfunction or a short time later, paralysis occurred in the form of toe flexor weakness and dorsal flexor/plantar flexor paresis in our cases. A further commonality among all cases was denervation edema of the corresponding musculature.

Intraneural ganglion cysts usually occur in adults [2]. However, one of our cases showed that the disease can also occur in children and adolescents as also described in other cases [16, 17].

Pathological lesions of peripheral nerves can result from direct trauma (crush injury or severance), traction, compression, or permanent friction [18]. Intraneural ganglion cysts are comparably rare pathologies. In particular, intraneural ganglion cysts of the tibial nerve are a rarity. The peroneal nerve and its branches are affected more frequently. Other intraneural ganglion cysts of the radial nerve, ulnar nerve, median nerve, sciatic nerve, and posterior interosseous nerve have been described. A case of a cyst of the tibial nerve was first described in 1967. Since then, only a few cases have been reported in the literature [2, 10, 11].

There are multiple theories regarding the formation of intraneural ganglion cysts with the articular/synovial theory being most widely accepted. According to this theory, cysts are formed from a capsular defect of an adjacent joint so that synovial fluid spreads along the epineurium of a nerve branch [19]. It is possible for cysts to arise from the proximal tibiofibular joint, to extend over the peroneal nerve to the sciatic nerve, and then to descend into the tibial nerve [7].

In the case of our first patient with ganglion cysts of the tibial nerve, the cysts extended to the proximal tibiofibular joint but were also in close contact with the femorotibial joint which showed significant degeneration and was affected by synovitis. The fact that smaller branches extend from the tibial nerve to the femorotibial joint and innervate the joint [20] is assumed to be the origin of the disease. Based on the precise preoperative diagnosis, the nerve clusters supplying the tibiofibular joint and the femorotibial joint were ligated. Intraneural ganglion cysts arising from the tibiofibular joint have also been described in the literature. However, this combination is very rare. To date, only 5 such cases have been described in the literature [21, 22].

Initial case reports on intraneural ganglion cysts postulated that the cysts were the result of a localized degenerative process of the connective tissue or the perineural sheath caused by chronic irritation. According to other theories, the cysts were the result of traumatic intraneural bleeding. However, this theory does not seem as plausible since no hemosiderin deposits were found in the ganglion cysts. Trauma has also been discussed as a possible general cause since multiple patients from previous case reports have a knee injury in their history [2]. However, the patients in our case reports did not have a history of trauma.

There is one case report in the literature of intraneural ganglion cysts with no communication with the joint [8]. However, the case of our young patient (patient 2) shows that surgically drained cysts refill postoperatively when the nerve branches supplying the joint are not identified and ligated. Therefore, it can be assumed that ganglion cysts in the nerve branches supplying the joint cannot always be identified intraoperatively even though they exist. Both MRI and ultrasound are suitable for diagnosing intraneural ganglion cysts and can visualize the full extent of the lesions [8]. They are also very important for the diagnosis of intraneural ganglion cysts, particularly for the visualization of intrafascicular structures in the case of nerve lesions. However, ultrasound is highly examiner-dependent. Particularly smaller lesions can be easily missed with this technique in primary diagnosis.

MRI examination has various advantages compared to ultrasound: Multiplanar 3D images can be generated, vascular signals can be suppressed, and the complete extent of lesions can always be precisely determined. Nerve fascicles can be shown in greater detail so that changes in signal intensity can be better evaluated. In addition, the consequences of muscle denervation can be effectively visualized [23, 24].

On MRI, cysts typically present as homogeneous multilocular soft tissue formations with fluid signals. Intravenous administration of gadolinium helps to assess malignancy [25]. Purely clinical differentiation between intraneural ganglion cysts and malignant lesions is impossible, particularly when the patient presents with isolated sensory or motor symptoms. Cross-sectional imaging is

essential for differentiating between traumatic nerve entrapment, tumors, and other causes. MRI imaging is suitable particularly for the diagnosis or exclusion of benign tumors, e. g. schwannomas or neurofibromas, as well as for ruling out malignant peripheral nerve sheath tumors. In our cases, the cysts did not have any solid parts or malignancy criteria, e. g. inhomogeneities within the cysts or structures with contrast enhancement [26].

The treatment of choice for a symptomatic ganglion cyst is surgical decompression of the nerves, draining of the cysts, and ligation of the articular branch. Follow-up can be considered in cases of relapse without neurological impact.

Clinical recovery depends on the preoperative extent of the damage, the time to surgery, and the time to follow-up examination so that it is not unusual to initially see no improvement in plegia. All 3 patients who presented at our hospital decided to undergo surgery. In 2 patients (case examples 1 and 3), the symptoms improved after draining of the cysts and ligation of the articular branch. In the other patient (case example 2), surgery did not provide any significant improvement. In this case the cysts were drained but the articular joint was not ligated.

Ligation of the articular branch prevents recurrence. Based on the presumed etiology of intraneural ganglion cysts, the nerve connection to the joint must be severed.

Neurological symptoms, such as paralysis of the dorsal flexor, often do not improve immediately after surgical therapy so that follow-up should only be performed after sufficient time has passed.

Surgical treatment can be complicated since the lesions usually run between nerve fascicles and differentiation between cystic lesions and nerve is difficult. Excessive excision can result in nerve damage. Clipping or excision of intraarticular nerve ends can only be performed at specialized centers [19].

In summary, intraneural ganglion cysts are rare but should be considered as a differential diagnosis when patients develop pain, unclear paresis, or sensory dysfunction in the extremities. Although the etiology has not yet been able to be definitively clarified, the articular/synovial theory which states that cysts are formed as a result of synovial fluid spreading along the epineurium of a nerve branch is widely accepted. The cases described here support this theory. MRI, in particular MR neurography, is the diagnostic method of choice for optimal surgery planning to provide the surgeon with detailed information for surgical treatment by means of the high-resolution visualization of the nerve-joint connection.

Conflict of Interest

The authors declare that they have no conflict of interest.

References

- [1] Kim DH, Ryu S et al. Surgical management and results of 135 tibial nerve lesions at the Louisiana State University Health Sciences Center. *Neurosurgery* 2003; 53: 1114–1124
- [2] Patel P, Schucany WG. A rare case of intraneural ganglion cyst involving the tibial nerve. *Proc (Bayl Univ Med Cent)* 2012; 25: 132–135
- [3] Desy NM, Wang H et al. Intraneural ganglion cysts: a systematic review and reinterpretation of the world's literature. *J Neurosurg* 2016; 125: 615–630
- [4] Kontinen YT, Tiainen VM et al. Innervation of the joint and role of neuropeptides. *Ann N Y Acad Sci* 2006; 1069: 149–154
- [5] Wilson TJ, Hebert-Blouin MN et al. The nearly invisible intraneural cyst: a new and emerging part of the spectrum. *Neurosurg Focus* 2017; 42: E10
- [6] Spinner RJ, Hebert-Blouin MN et al. Extreme intraneural ganglion cysts. *J Neurosurg* 2011; 114: 217–224
- [7] Spinner RJ, Amrami KK et al. Dynamic phases of peroneal and tibial intraneural ganglia formation: a new dimension added to the unifying articular theory. *J Neurosurg* 2007; 107: 296–307
- [8] Silveira CRS, Vieira CGM et al. Cystic degeneration of the tibial nerve: magnetic resonance neurography and sonography appearances of an intraneural ganglion cyst. *Skeletal Radiol* 2017; 46: 1763–1767
- [9] Robbins NM, Shah V et al. Magnetic resonance neurography in the diagnosis of neuropathies of the lumbosacral plexus: a pictorial review. *Clin Imaging* 2016; 40: 1118–1130
- [10] Scherman BM, Bilbao JM et al. Intraneural ganglion: a case report with electron microscopic observations. *Neurosurgery* 1981; 8: 487–490
- [11] Adn M, Hamlat A et al. Intraneural ganglion cyst of the tibial nerve. *Acta Neurochir (Wien)* 2006; 148: 885–889; discussion 889–890
- [12] Koltzenburg M, Bendszus M. Imaging of peripheral nerve lesions. *Curr Opin Neurol* 2004; 17 (5): 621–626
- [13] Bendszus M, Koltzenburg M et al. Sequential MR imaging of denervated muscle: experimental study. *AJNR Am J Neuroradiol* 2002; 23: 1427–1431
- [14] Lüllmann-Rauch R. *Taschenlehrbuch Histologie*. Stuttgart: Thieme. 2009
- [15] Krachete DC, Sakata RK. Painful peripheral neuropathies. *Rev Bras Anestesiol* 2011; 61: 641–648
- [16] Akcakaya MO, Shapira Y et al. Peroneal and tibial intraneural ganglion cysts in children. *Pediatr Neurosurg* 2013; 49: 347–352
- [17] Keser N, Akpınar P et al. Irreversible Foot Drop as a Consequence of Neglected Knee Pain in an Adolescent with a Peroneal Intraneural Ganglion Cyst. *World Neurosurg* 2018; 111: 307–310
- [18] Hochman MG, Zilberfarb JL. Nerves in a pinch: imaging of nerve compression syndromes. *Radiol Clin North Am* 2004; 42: 221–245
- [19] Desy NM, Lipinski LJ et al. Recurrent intraneural ganglion cysts: Pathoanatomic patterns and treatment implications. *Clin Anat* 2015; 28: 1058–1069
- [20] Moore KL, Agur AMR et al. *Essential clinical anatomy*. Baltimore, MD: Lippincott Williams & Wilkins. 2011
- [21] Roger J, Chauvin F et al. Synovial cyst of the knee: A rare case of acute sciatic neuropathy. *Ann Phys Rehabil Med* 2017; 60: 274–276
- [22] Wilson TJ, Amrami KK et al. Intraneural ganglion cysts: A predictable method to their madness. *Ann Phys Rehabil Med* 2017; 60: 414–415
- [23] Petchprapa CN, Rosenberg ZS et al. MR imaging of entrapment neuropathies of the lower extremity. Part 1. The pelvis and hip. *Radiographics* 2010; 30: 983–1000
- [24] Chhabra A, Flammang A et al. Magnetic resonance neurography: technical considerations. *Neuroimaging Clin N Am* 2014; 24: 67–78
- [25] Ahlawat S, Chhabra A et al. Magnetic resonance neurography of peripheral nerve tumors and tumorlike conditions. *Neuroimaging Clin N Am* 2014; 24: 171–192
- [26] Chung WJ, Chung HW et al. MRI to differentiate benign from malignant soft-tissue tumours of the extremities: a simplified systematic imaging approach using depth, size and heterogeneity of signal intensity. *Br J Radiol* 2012; 85: e831–e836