

# Inadequate steroid injection after esophageal ESD might cause mural necrosis



## Authors

Satoshi Yamashita<sup>1</sup>, Motohiko Kato<sup>1</sup>, Ai Fujimoto<sup>1</sup>, Tadateru Maehata<sup>1</sup>, Motoki Sasaki<sup>1</sup>, Naoko Inoshita<sup>2</sup>, Hiroki Sato<sup>3</sup>, Kenji Suzuki<sup>3</sup>, Naohisa Yahagi<sup>1</sup>

## Institutions

- 1 Division of Research and Development for Minimally Invasive Treatment, Cancer Center, Keio University School of Medicine, Tokyo, Japan
- 2 Department of Pathology, Toranomon Hospital, Tokyo, Japan
- 3 Division of Gastroenterology and Hepatology, Graduate School of Medical and Dental Sciences, Niigata University, Niigata, Japan

submitted 26.6.2018

accepted after revision 24.9.2018

## Bibliography

DOI <https://doi.org/10.1055/a-0781-2333> |  
Endoscopy International Open 2019; 07: E115–E121  
© Georg Thieme Verlag KG Stuttgart · New York  
ISSN 2364-3722

## Corresponding author

Naohisa Yahagi, MD PhD, Division of Research and Development for Minimally Invasive Treatment, Cancer Center, Keio University School of Medicine, 35 Shinanomachi, Shinjuku-ku, Tokyo 160-8582, Japan  
Fax: +81-3-53633895  
[yahagi.keio@gmail.com](mailto:yahagi.keio@gmail.com)

## ABSTRACT

**Background and study aims** Locoregional triamcinolone acetonide (TAC) injection is increasingly used for prevention of stricture after extensive endoscopic submucosal dissection (ESD) for superficial esophageal neoplasia. However, the safety of intramural TAC injection has not been elucidated. The aim of this study was to assess the clinical courses and histopathological changes after TAC injection into the muscle layer in a porcine model.

**Methods** Three pigs were subjected to ESD under general anesthesia. Two artificial 30-mm lesions were created at the oral and anal ends of the esophagus in each pig. TAC was injected into the muscle layer of the artificial oral ulcers (TAC group) and saline was injected into the muscle layer of the artificial anal ulcers (control group). Endoscopic, macroscopic, and histopathological evaluations were performed.

**Results** The artificial ulcers remained open at sacrifice on day 28 post-ESD in the three ulcers injected with TAC. Esophageal wall perforation and abscess spreading to the mediastinum were observed in two of the three ulcers in the TAC group. The abscesses involved the lungs, bronchi, and aortic adventitia. Severe inflammatory cell infiltration in the muscularis propria layer and significant muscularis propria degradation were observed in all three ulcers in the TAC group.

**Conclusions** This study suggests that TAC may cause deep mural damage when it is injected into the muscularis propria. Care should be taken not to inject TAC into the muscle layer when it is used to prevent post-ESD stricture formation.

## Introduction

Endoscopic submucosal dissection (ESD) has been widely accepted as a minimally invasive alternative treatment for superficial esophageal neoplasia without obvious lymph node or distant metastases because it allows successful en bloc removal, even for superficially spreading esophageal carcinoma [1]. Recently, some studies have shown that long-term ESD outcomes

are good and are comparable to those of radical esophagectomy [2, 3].

Despite its high curability, stricture formation after extensive resection remains an issue. Stricture formation causes patients to suffer from severe symptoms, such as dysphagia, vomiting, and weight loss. The occurrence of post-ESD stricture has been associated with mucosal defects to more than three-quarters of the total circumferential area [4–6], and its incidence has been reported to be greater than 70% [5, 7–9].

Endoscopic balloon dilatation (EBD) is commonly used to treat strictures; however, EBD sometimes causes complications, such as perforation, and repeated EBD procedures worsen the patient's quality of life [10].

Triamcinolone acetonide (TAC) is a type of corticosteroid that is used for locoregional injection as a slurry. Some studies have revealed the significant superiority of locoregional TAC injection to historical control in preventing post-ESD esophageal stricture formation [8, 11, 12]. Based on these results, TAC is now widely used in clinical practice. However, corticosteroids are known to cause tissue vulnerability, and the sustained anti-inflammatory effects of TAC could sometimes be harmful.

We hypothesized that TAC may be particularly harmful when it is injected into the muscularis propria; in fact, TAC could cause vulnerability by inhibiting the deposition and enhancing the breakdown of collagen to reduce scar-tissue formation [13]. Therefore, the purpose of the present study was to assess the clinical and histopathological changes after TAC injection into the muscle layer in a porcine model.

## Materials and methods

### Study design

This was an experimental animal study using live pigs. Before TAC injection into the muscularis propria (MP) model, we performed TAC injection into the submucosal layer of three pigs as a pilot study. Subsequently, a further three female pigs weighing approximately 15 to 20 kg were used for the main experiment. After 24 hours of fasting, the pigs were subjected to ESD under general anesthesia induced by the intramuscular administration of midazolam (0.2 mg/kg), medetomidine (0.1 mg/kg), and atropine sulfate (0.02 mg/kg), and maintained by isoflurane inhalation. After ESD, the pigs received either TAC (TAC group) or saline injection (control group) into the muscle layer of the post-ESD artificial ulcers. Oral intake was started immediately after the procedure. In addition, the postoperative clinical course (weight and food intake) was monitored. Esophagoscopy was performed 7, 14, and 28 days after ESD. The pigs were sacrificed 28 days after the procedure using an intravenous injection of potassium chloride. The esophageal tissues were subjected to pathological analyses. The protocol was reviewed and approved in advance by the Ethics Review Board of our animal experimental laboratory (No. 14074).

### Creation of the ESD model

Two artificial 30-mm lesions were created 32 and 38 cm from the incisor of the esophagus in each pig (six lesions in total). ESD was performed as previously reported [14]. A single channel endoscope equipped with a waterjet function (GIF-Q260; Olympus Medical Systems, Tokyo, Japan), DualKnife J (KD-655 Q; Olympus Medical Systems), and high frequency generator (ESG-100; Olympus Medical Systems) was used. Glycerol (10% glycerol and 5% fructose; Chugai Pharmaceutical, Tokyo, Japan) with a small amount of indigo carmine and 0.1% epinephrine was injected submucosally around the marking to lift it off the muscle layer. After the mucosal incisions, the submucosal layer

was dissected to obtain the perfect specimen, and complete en bloc resection was achieved.

### TAC or saline injection into the muscle layer of the post-ESD ulcer

Immediately after ESD, single injections of endoscopic steroid or saline were performed in each ESD region. TAC was injected into the oral ESD site (32 cm incision; TAC group), because we could not observe the ESD wound on the anal side in case of severe stricture. In the present study, a TAC slurry (Kenacort; Bristol-Myers Squibb, New York, USA) was diluted with saline to make a 5 mg/mL solution. After puncturing the appropriate muscle layer with a 25-gauge, 4-mm needle (TOP Corporation, Tokyo, Japan), TAC was injected in aliquots of 0.2 mL (1 mg). A 1-mL syringe was used to inject triamcinolone manually; this method facilitated injections with constant pressure. The total amount of triamcinolone injection was 5 mL (25 mg), which was distributed approximately equally over 25 punctures. The endoscopic judgment for muscle injection was made by the swelling and local white turbidity change by TAC in the muscularis propria layer without these changes in the submucosal layer. For the ulcers on the anal ESD site, an equal volume of normal saline was injected in the same manner as a control (control group). All endoscopic procedures, including TAC injection, were performed by a single expert endoscopist.

### Histological assessment

After the pigs were sacrificed, the esophagi were resected with the surrounding organs and opened longitudinally. The specimens were fixed in 5% buffered formalin for 48 hours and dissected axially at 4-mm intervals. Each piece was embedded in a paraffin block, cut into 4- $\mu$ m-thick slices, and examined after hematoxylin and eosin (HE) and Masson's trichrome staining.

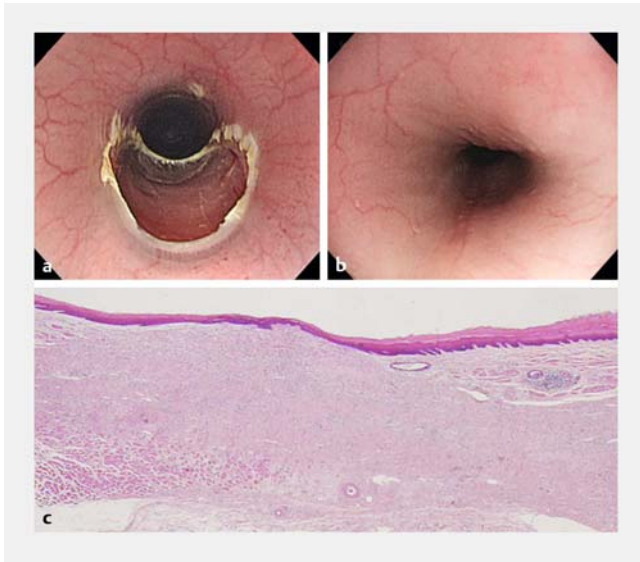
## Results

### Submucosal TAC injection model

Typical endoscopic images and histological findings for the TAC injection site are shown in ► **Fig. 1**. There were no perforations in all three ulcers where TAC was injected into the submucosal layer. At 28 days after ESD, all artificial ulcers had completely closed and no stricture was observed. Histological findings revealed mild degeneration of the muscularis propria layer.

### Procedure-related outcomes

All procedures were performed successfully in all study animals. All of the pigs survived the 4 weeks until sacrifice without any adverse events; additionally, perforation during the ESD procedure, postoperative bleeding, dysphagia, and weight loss were not observed.



► **Fig. 1** Endoscopic images and histological findings for TAC injection site in the pilot study. **a** Endoscopic image of post-ESD ulcer (day 0). **b** Endoscopic image of post-ESD ulcer (day 28). **c** Typical appearance of TAC injection site (HE staining). The post-ESD ulcer had healed completely and mild degeneration of the muscularis propria layer was found.

### Endoscopic findings

Typical images obtained for each group are shown in ► **Fig. 2**. The artificial ulcers remained open at sacrifice on day 28 post-ESD in the three ulcers injected with TAC, whereas the ulcers were closed completely in two of the three ulcers in the control group. In ulcers in the TAC group, the ulcers were apparently

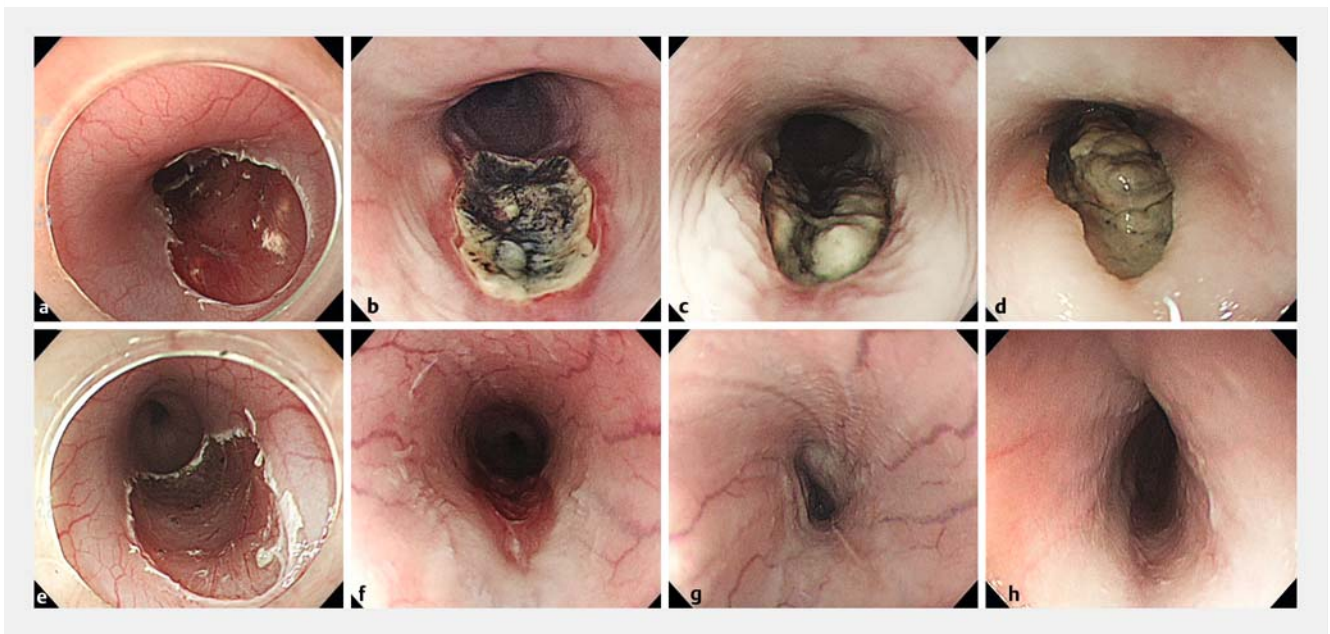
deeper than when they were created, and necrotic changes were observed in the ulcer bed.

### Macroscopic findings

Open ulcers were observed in all ulcers in the steroid group as mentioned above. In two of the three ulcers in the TAC group, esophageal wall perforation and abscess spread to the mediastinum were observed. Strong tissue adhesion was observed between the esophagus and the bronchi, lungs, and aorta (► **Fig. 3**).

### Histopathological findings

A summary of the histopathological assessment is shown in ► **Table 1**. In all three ulcers injected with TAC, the depth of ulcers reached the muscularis propria, whereas the depth was limited to the submucosa in all ulcers in the control group. In two ulcers in the TAC group, the ulcers penetrated to the mediastinum, and abscesses were formed. The abscesses involved the lungs, bronchi, and aortic adventitia (► **Fig. 3**). In the control group, the inflammatory cell infiltration was weak compared with the TAC group apart from one ulcer where the inflammatory cell infiltration in the submucosal layer and muscularis propria spread beneath the normal mucosa from the steroid injection site to the saline injection site. The length of the disrupted muscularis mucosa was longer in the TAC group than in the control group. Masson's trichrome staining revealed significant muscularis propria degradation in the TAC group (► **Fig. 4**). There were no apparent differences in thickness of the muscularis propria layer between the oral and anal ESD site on histology.

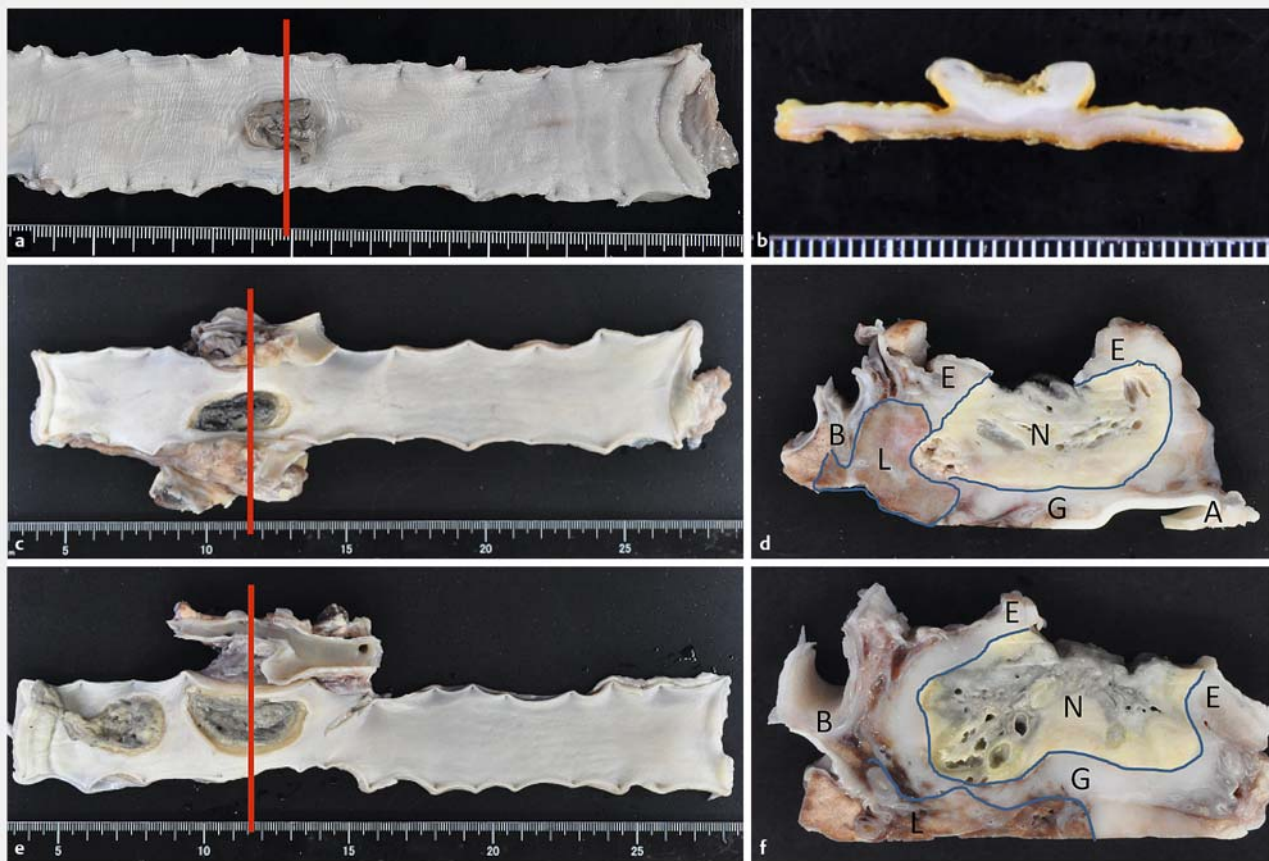


► **Fig. 2** Endoscopic images of post-ESD ulcer on day 0, 7, 14, and 28 after ESD. **a** TAC group (day 0). **b** TAC group (day 7). **c** TAC group (day 14). **d** TAC group (day 28). **e** Control group (day 0). **f** Control group (day 7). **g** Control group (day 14). **h** Control group (day 28).

► **Table 1** Pathological findings for resected esophagus.

Case	Treatment	Depth of ulcer	Penetration	Abscess formation	Pus on ulcer	Disrupted length of MM
1	TAC	MP	N	N	Y	11 mm
2	TAC	Ad	Y	Y	Y	15 mm
3	TAC	Ad	Y	Y	Y	19 mm
4	Control	SM	N	N	N	0.7 mm
5	Control	SM	N	N	N	4 mm
6	Control	SM	N	N	Y	17 mm

MP, muscularis propria; MM, muscularis mucosae; TAC, triamcinolone acetonide; Ad, adventitia; SM, submucosa.



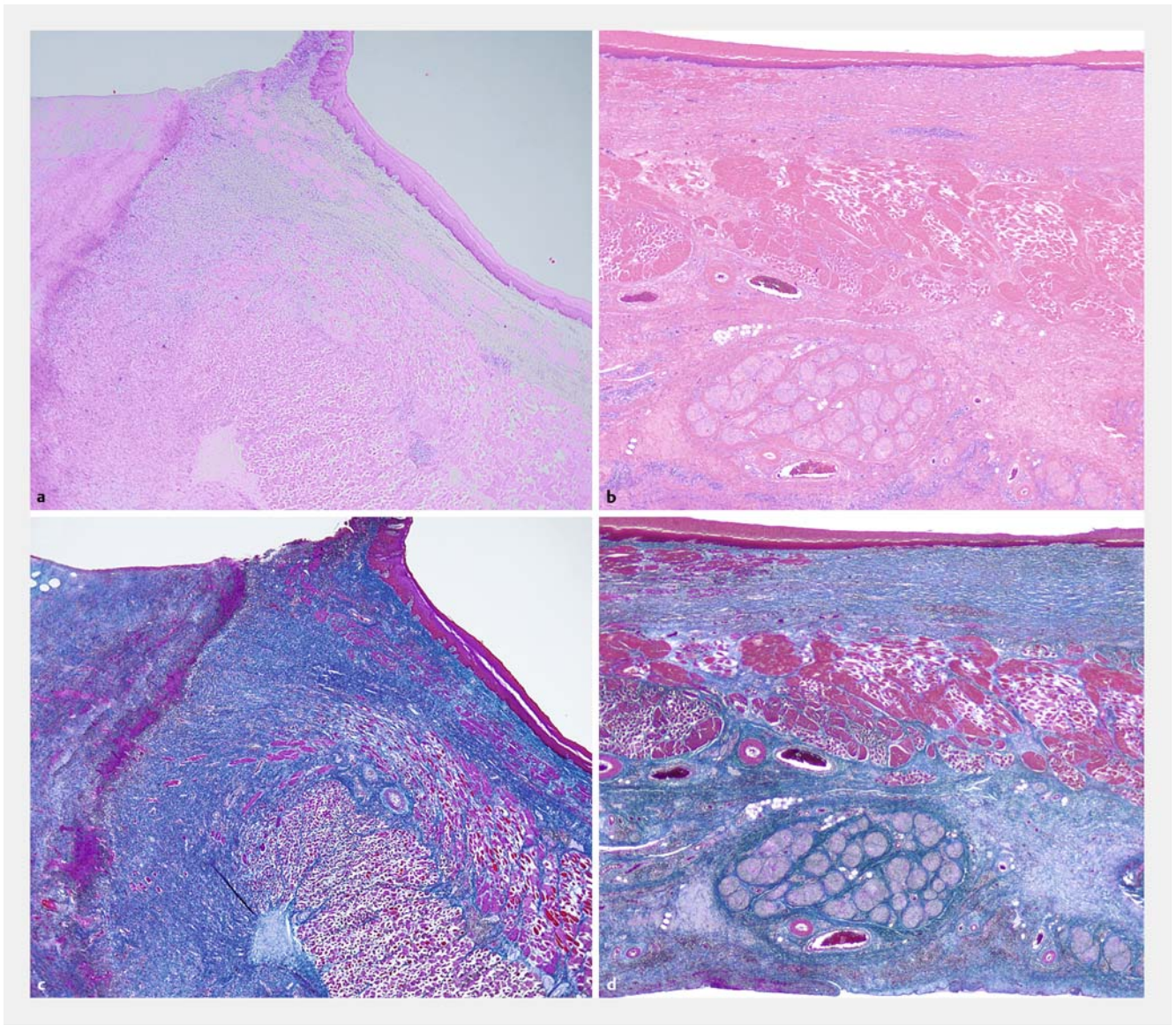
► **Fig. 3** Macroscopic findings for resected specimens and representative sections of TAC injection. **a** Formalin fixed specimen from pig 1. **b** Formalin fixed section with TAC injection in pig 1. **c** Formalin fixed specimen from pig 2. **d** Formalin fixed section with TAC injection in pig 2. **e** Formalin fixed specimen from pig 3. **f** Formalin fixed section with TAC injection in pig 3. E represents esophagus, N represents necrotic tissue, G represents granulation tissue, L represents lung, B represents bronchus, and A represents aorta.

## Discussion

As the use of ESD for superficial esophageal cancer has increased, post-ESD stricture has become a major issue. Locoregional steroid injection reportedly reduces post-ESD stricture. The occurrence of post-ESD stricture is less than 20% in patients receiving this treatment and significantly less than the 66–75% of patients not receiving this treatment [8, 11].

As a result of these data and the benefits of avoiding systemic steroid administration, locoregional steroid injection is becoming widely used in clinical practice.

On the other hand, tissue TAC concentration seems to be higher in locoregional injection than in systemic administration and some adverse events related to locoregional steroid treatment have recently been reported. McAlindon et al. reported that intra-articular TAC injection in patients with osteoarthritis



► **Fig. 4** Histological findings for resected specimens from a TAC injected ulcer and control ulcer. **a** Specimen of ulcer edge of ulcer injected with TAC (HE staining). **b** Specimen of ulcer edge of control ulcer (HE staining). **c** Specimen of ulcer edge of ulcer injected with TAC (Masson's trichrome staining). **d** Specimen of ulcer edge of control ulcer (Masson's trichrome staining).

significantly reduced the knee cartilage volume [15]. Moreover, there is a case report of delayed perforation after intralesional TAC injection for esophageal stricture following endoscopic submucosal dissection [16]. There have been few studies on the adverse effects of the strong and long-acting anti-inflammatory activity of locoregional TAC injection.

Surprisingly, two of the three ulcers in which TAC was injected developed full-thickness necrosis of the esophagus, whereas no perforation was observed in the control group and in ulcers where TAC was injected into the submucosal layer in the pilot study. The depth of all three ulcers in the TAC group reached the muscularis propria layer, whereas the ulcers in the control group remained within the submucosa. Moreover, all three of the ulcers injected with TAC had not healed at all on day 28, whereas two of the three ulcers in the control group

had completely closed. These findings indicate that TAC not only disturbs ulcer healing but also causes mural injury and necrosis when it is injected into the muscular layer. In clinical practice, we tried to inject TAC into the submucosal layer, not into the muscular layer. However, this objective is sometimes difficult because there is only a small amount of the submucosal layer left after ESD.

Another concern of TAC injection is that the muscularis propria would be degraded. Tsujii and colleagues reported that the risk of perforation with endoscopic balloon dilation increased after TAC injection [17]. The effectiveness of locoregional TAC injection might not only be because it prevents fibrosis, but also because it degrades the muscle layer, which leads to incomplete contraction. In the present study, we found significant muscularis propria degradation, as shown by Masson's tri-

chrome staining. Therefore, in the case of stricture after TAC injection, the risk of perforation is increased due to tissue vulnerability.

The detailed mechanism of why TAC injection into the muscular layer causes mural necrosis is unknown; however, it might be explained by the catabolic action of glucocorticoids. It is known that glucocorticoids induce myopathy [18]. Glucocorticoids cause skeletal muscle atrophy by promoting protein catabolism and inhibiting protein anabolism. They exert their effects by binding to the nuclear glucocorticoid receptor (GR). GR inhibits the activity of mammalian target of rapamycin complex 1 (mTORC1), which is a known promoter of protein anabolism [19]. Moreover, GR enhances the expression of FoxO, a transcription factor that induces the atrophy-related ubiquitin ligase atrogin-1 and causes skeletal muscle atrophy [20].

As shown above, locoregional TAC injection might cause mural necrosis, despite its clinical effectiveness in preventing post-ESD stricture formation. Recently, novel treatment options have been proposed for preventing post-ESD stricture; these treatments include fabricated autologous epidermal cell sheets [21,22], absorbent polyglycolic acid sheets [23,24], and siRNAs with anti-fibrotic functions [25]. These novel treatments are expected to replace TAC if they are effective and less toxic.

This study has several limitations. Steroid injection into the muscularis propria was attempted; however, the steroid may have been accidentally injected into the remnant submucosa. In this study, only six lesions in three pigs were assessed. TAC was injected only in the oral ESD site and the difference in location might influence the outcomes, though there was no difference in histological features (e.g. thickness of the wall) between oral and anal esophagus. Mucosal defects were relatively small and the amount of TAC and puncture time might have been more than clinical practice even though the difference was not significant. There may be a species difference between humans and pigs. Due to these limitations, further studies are needed.

In conclusion, this study suggests that TAC may cause deep mural damage when it is injected into the muscularis propria. We should be careful not to inject TAC into the muscle layer when it is used to prevent post-ESD stricture formation.

## Competing interests

None

## References

- [1] Fujishiro M, Yahagi N, Kakushima N et al. Endoscopic submucosal dissection of esophageal squamous cell neoplasms. *Clin Gastroenterol Hepatol* 2006; 4: 688–694
- [2] Tsujii Y, Nishida T, Nishiyama O et al. Clinical outcomes of endoscopic submucosal dissection for superficial esophageal neoplasms: a multicenter retrospective cohort study. *Endoscopy* 2015; 47: 775–783
- [3] Shimizu Y, Tsukagoshi H, Fujita M et al. Long-term outcome after endoscopic mucosal resection in patients with esophageal squamous cell carcinoma invading the muscularis mucosae or deeper. *Gastrointest Endosc* 2002; 56: 387–390
- [4] Ono S, Fujishiro M, Niimi K et al. Predictors of postoperative stricture after esophageal endoscopic submucosal dissection for superficial squamous cell neoplasms. *Endoscopy* 2009; 41: 661–665
- [5] Katada C, Muto M, Manabe T et al. Esophageal stenosis after endoscopic mucosal resection of superficial esophageal lesions. *Gastrointest Endosc* 2003; 57: 165–169
- [6] Mizuta H, Nishimori I, Kuratani Y et al. Predictive factors for esophageal stenosis after endoscopic submucosal dissection for superficial esophageal cancer. *Dis Esophagus* 2009; 22: 626–631
- [7] Sato H, Inoue H, Kobayashi Y et al. Control of severe strictures after circumferential endoscopic submucosal dissection for esophageal carcinoma: oral steroid therapy with balloon dilation or balloon dilation alone. *Gastrointest Endosc* 2013; 78: 250–257
- [8] Hashimoto S, Kobayashi M, Takeuchi M et al. The efficacy of endoscopic triamcinolone injection for the prevention of esophageal stricture after endoscopic submucosal dissection. *Gastrointest Endosc* 2011; 74: 1389–1393
- [9] Ezo Y, Muto M, Horimatsu T et al. Efficacy of preventive endoscopic balloon dilation for esophageal stricture after endoscopic resection. *J Clin Gastroenterol* 2011; 45: 222–227
- [10] Sato H, Inoue H, Ikeda H et al. Clinical experience of esophageal perforation occurring with endoscopic submucosal dissection. *Dis Esophagus* 2014; 27: 617–622
- [11] Hanaoka N, Ishihara R, Takeuchi Y et al. Intralesional steroid injection to prevent stricture after endoscopic submucosal dissection for esophageal cancer: a controlled prospective study. *Endoscopy* 2012; 44: 1007–1011
- [12] Nagami Y, Shiba M, Tominaga K et al. Locoregional steroid injection prevents stricture formation after endoscopic submucosal dissection for esophageal cancer: a propensity score matching analysis. *Surg Endosc* 2016; 30: 1441–1449
- [13] Werner S, Grose R. Regulation of wound healing by growth factors and cytokines. *Physiol Rev* 2003; 83: 835–870
- [14] Ono S, Fujishiro M, Koike K. Endoscopic submucosal dissection for superficial esophageal neoplasms. *World J Gastrointest Endosc* 2012; 4: 162–166
- [15] McAlindon TE, LaValley MP, Harvey WF et al. Effect of intra-articular triamcinolone vs saline on knee cartilage volume and pain in patients with knee osteoarthritis: a randomized clinical trial. *JAMA* 2017; 317: 1967–1975
- [16] Yamashina T, Uedo N, Fujii M et al. Delayed perforation after intralesional triamcinolone injection for esophageal stricture following endoscopic submucosal dissection. *Endoscopy* 2013; 45: (Suppl. 02): E92
- [17] Tsujii Y, Hayashi Y, Kawai N et al. Risk of perforation in balloon dilation associated with steroid injection for preventing esophageal stricture after endoscopic submucosal dissection. *Endosc Int Open* 2017; 5: E573–E579
- [18] Schakman O, Gilson H, Thissen J-P. Mechanisms of glucocorticoid-induced myopathy. *J Endocrinol* 2008; 197: 1–10
- [19] Shimizu N, Yoshikawa N, Ito N et al. Crosstalk between glucocorticoid receptor and nutritional sensor mTOR in skeletal muscle. *Cell Metab* 2011; 13: 170–182
- [20] Sandri M, Sandri C, Gilbert A et al. Foxo transcription factors induce the atrophy-related ubiquitin ligase atrogin-1 and cause skeletal muscle atrophy. *Cell* 2004; 117: 399–412
- [21] Ohki T, Yamato M, Murakami D et al. Treatment of oesophageal ulcerations using endoscopic transplantation of tissue-engineered autologous oral mucosal epithelial cell sheets in a canine model. *Gut* 2006; 55: 1704–1710

- [22] Ohki T, Yamato M, Ota M et al. Prevention of esophageal stricture after endoscopic submucosal dissection using tissue-engineered cell sheets. *Gastroenterology* 2012; 143: 582–588 e581-582
- [23] Sakaguchi Y, Tsuji Y, Ono S et al. Polyglycolic acid sheets with fibrin glue can prevent esophageal stricture after endoscopic submucosal dissection. *Endoscopy* 2015; 47: 336–340
- [24] Iizuka T, Kikuchi D, Yamada A et al. Polyglycolic acid sheet application to prevent esophageal stricture after endoscopic submucosal dissection for esophageal squamous cell carcinoma. *Endoscopy* 2015; 47: 341–344
- [25] Sato H, Sagara S, Nakajima N et al. Prevention of esophageal stricture after endoscopic submucosal dissection using RNA-based silencing of carbohydrate sulfotransferase 15 in a porcine model. *Endoscopy* 2017; 49: 491–497