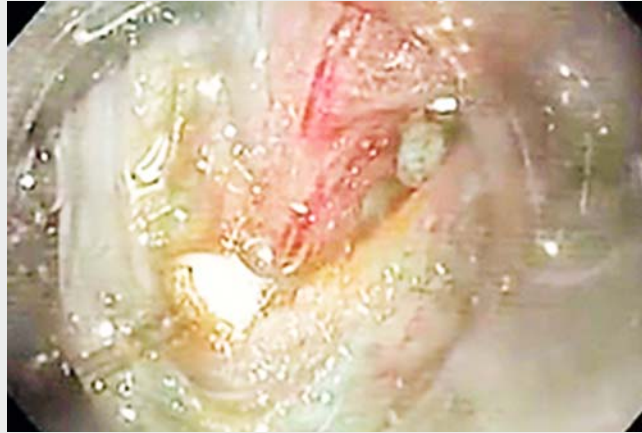

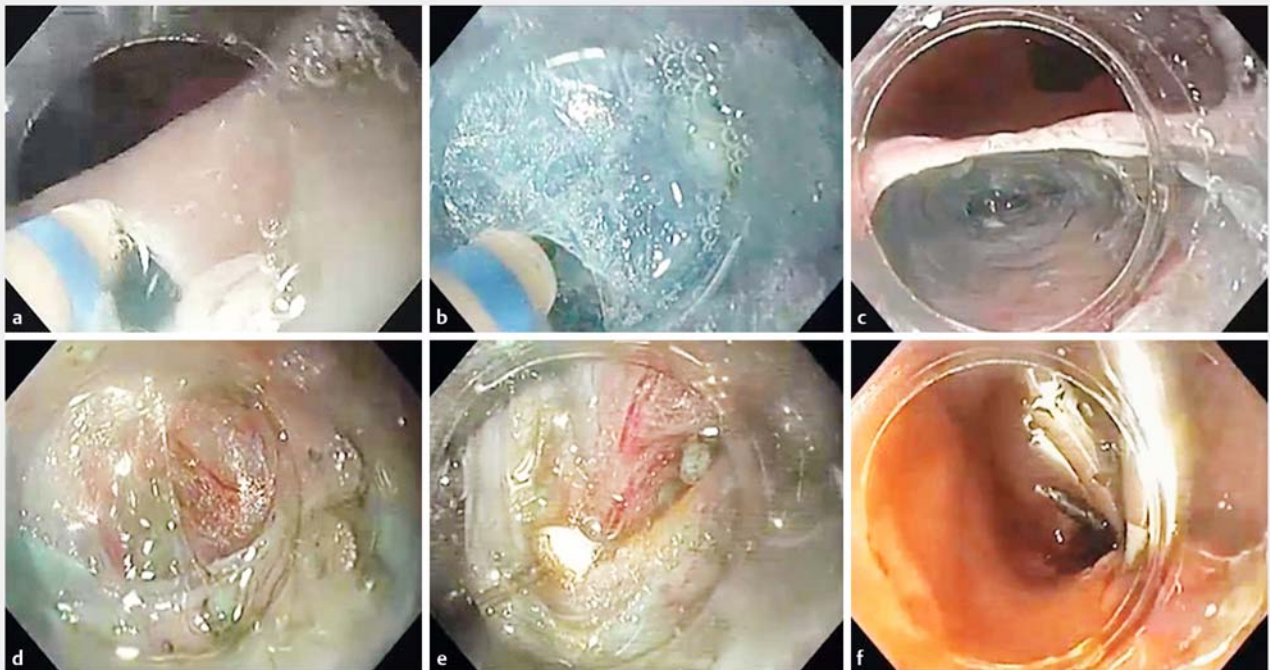
Gastric peroral endoscopic myotomy for transthyretin amyloidosis gastroparesis

Hereditary transthyretin amyloidosis is associated with gastrointestinal symptoms which can have a negative impact on quality of life [1], with gastroparesis being a frequent complication of familial amyloidotic polyneuropathy (FAP) [2]. Interventions that target symptoms while liver transplantation is awaited can be of the utmost importance for improvement of nutritional status and optimization of surgical outcomes. Gastric peroral endoscopic myotomy (G-POEM) has been described as safe with high technical and clinical success rates, mainly for post-operative, diabetic, and idiopathic gastroparesis [3].

A 38-year-old man with a genetic diagnosis of FAP and a 10-year history of neuropathic manifestations who was receiving treatment with tafamidis presented with nausea, vomiting, post-prandial epigastric pain, and weight loss, with severe



▶ Video 1 A gastric peroral endoscopic myotomy (G-POEM) procedure is performed for amyloidotic gastroparesis, with the following steps: mucosotomy, submucosal dissection, submucosal tunneling, coagulation of the submucosal (Sm) vessels, identification of the pyloric arch, IT knife anchoring at the pyloric arch, creation of the pyloromyotomy, and closure of the mucosal defect with endoclips.



▶ Fig. 1 Endoscopic images showing: **a** the mucosotomy performed on the greater curvature of the antrum; **b** submucosal dissection being performed; **c** creation of a submucosal tunnel; **d** identification of the pyloric arch; **e** creation of a 2-cm pyloromyotomy; **f** the mucosal defect after closure with endoclips.

gastroparesis on gastric emptying scintigraphy (GES; T_{50} of 50% at 120 minutes). He was started on combined prokinetic and antiemetic therapy, which was further optimized to maximum tolerated doses. Because of his continuing symptoms, with a Gastroparesis Cardinal Symptom Index (GCSI) of 26 points, and malnutrition risk, with a net weight loss of 20 kg over 2 years, G-POEM was proposed to the patient.

The procedure (► **Video 1**) followed the overall steps previously described [4]. A submucosal injection was performed on the greater curvature of the antrum, proximal to the pylorus, with a subsequent mucosotomy (► **Fig. 1 a**) and submucosal tunneling dissection using a DualKnifeJ (Olympus, Japan) (► **Fig. 1 b, c**). After identification of the pyloric arch (► **Fig. 1 d**), a pyloromyotomy (2 cm in length) was created with an ITknife2 (Olympus) (► **Fig. 1 e**). The mucosal defect was then closed using endoclips (► **Fig. 1 f**). After 24 hours, an esophago-gastroduodenography showed normal emptying of contrast into the duodenum, after which oral intake was resumed with no complications.

The patient continues to wait for a liver transplant but, 6 months later, he denies nausea and vomiting, tolerates normal-sized meals without using prokinetics, and scores 6 points on GCSI, with a T_{50} of 44% at 120 minutes on GES.

G-POEM seems feasible, beneficial, and safe in this particular subset of patients with gastroparesis.

Endoscopy_UCTN_Code_TTT_1AO_2A]

Competing interests

None

The authors

Tiago P. Guedes, Ricardo Küttner-Magalhães, Luis Maia, João Sousa, Mónica Garrido, Isabel Pedroto

Gastroenterology Department, Porto Hospital Centre, Porto, Portugal

Corresponding author

Tiago P. Guedes, MD

Gastroenterology Department, Porto Hospital Centre, Porto, Portugal
tiagoapguedes@gmail.com

References

- [1] Mundayat R, Karayal ON, Anan I et al. THAOS: Gastrointestinal manifestations of transthyretin amyloidosis-common complications of a rare disease. *Orphanet J Rare Dis* 2014; 9: 61
- [2] Suhr OB, Anan I, Åhlström KR et al. Gastric emptying before and after liver transplantation for familial amyloidotic polyneuropathy, Portuguese type [Val30Met]. *Amyloid* 2003; 10: 121–126
- [3] Khoury T, Mizrahi M, Mahamid M et al. A state of the art review with literature summary on gastric per-oral endoscopic pyloromyotomy for gastroparesis. *J Gastroenterol Hepatol* 2018; 33: 1829–1833
- [4] Gonzalez J-M, Vanbiervliet G, Vitton V et al. First European human gastric peroral endoscopic myotomy, for treatment of refractory gastroparesis. *Endoscopy* 2015; 47 (Suppl. 01): E135–E136

Bibliography

DOI <https://doi.org/10.1055/a-0826-9166>

Published online: 21.2.2019

Endoscopy 2019; 51: E101–E102

© Georg Thieme Verlag KG

Stuttgart · New York

ISSN 0013-726X

ENDOSCOPY E-VIDEOS

<https://eref.thieme.de/e-videos>



Endoscopy E-Videos is a free access online section, reporting on interesting cases and new

techniques in gastroenterological endoscopy. All papers include a high quality video and all contributions are freely accessible online.

This section has its own submission website at

<https://mc.manuscriptcentral.com/e-videos>