

Extensive Embolization of Splanchnic Artery Aneurysms due to Segmental Arterial Mediolytic

Extensive Embolisation von Aneurysmata der Viszeral-Arterien bei segmentaler arterieller Mediolyse

Authors

Arash Najafi, Gabriel Tobias Sheikh, Christoph Binkert

Affiliation

Institut für Radiologie und Nuklearmedizin, Kantonsspital Winterthur, Switzerland

Key words

embolization, segmental arterial mediolysis, visceral artery aneurysm

received 27.07.2018

accepted 25.01.2019

Bibliography

DOI <https://doi.org/10.1055/a-0855-4198>

Published online: 4.4.2019

Fortschr Röntgenstr 2019; 191: 1010–1014

© Georg Thieme Verlag KG, Stuttgart · New York

ISSN 1438-9029

Correspondence

Dr. Arash Najafi

Institut für Radiologie und Nuklearmedizin, Kantonsspital Winterthur, Brauerstrasse 15, 8401 Winterthur, Switzerland

Tel.: ++41/52/2 66 41 17

arash.najafi@ksw.ch

ABSTRACT

Aim Segmental arterial mediolysis (SAM) is a rare non-atherosclerotic, non-inflammatory, non-infectious arteriopathy in middle-aged patients that tends to affect medium-sized splanchnic arteries typically leading to dissecting aneurysms which in case of rupture have a high mortality. Treatment options include watchful waiting and endovascular or surgical intervention. There are no official treatment guidelines and to the best of our knowledge, there has not been any report of extensive exclusion of multiple splanchnic vessel regions in affected patients to date.

Materials and Methods We retrospectively examined the outcome of extensive splanchnic embolization in four patients suffering from SAM between 2011 and 2016 with follow-up periods of up to 7 years.

Results One patient presented with abdominal pain due to rupture of aneurysms of the pancreaticoduodenal arcade, one with abdominal pain due to dissection, and two were clinically asymptomatic but displayed rapidly progressing dis-

ease over the course of 12 months. All patients were treated with complete exclusion of the diseased vessel segments by coiling all branches to and from the diseased segment. In three cases the main hepatic artery was excluded completely. In one case, the complete vascular bed of the celiac axis was excluded by coiling the distal vessel branches and placing a stent graft over the orifice of the celiac trunk. During a follow-up period of a minimum of 2 and a maximum of 7 years after intervention, there were no immediate or long-term complications except for a temporary arterio-portal fistula. Interestingly, no new diseased areas of SAM were detected afterwards.

Conclusion Extensive endovascular exclusion of the entire diseased arterial segment with coils seems to be a safe and effective treatment option in patients with SAM presenting with ruptured or rapidly growing aneurysms. Provided that patients have normal liver function and proper portal venous flow, risk of hepatobiliary complications seems to be low even after extensive embolization.

Key points:

- An asymptomatic SAM can be followed up.
- In case of disease progression or suspicion of aneurysm rupture, an endovascular approach is indicated where the whole pathological vessel bed should be excluded with coils.
- It seems that exclusion of even extensive vessel areas is tolerated.

Citation Format

- Najafi A, Sheikh GT, Binkert C. Extensive Embolization of Splanchnic Artery Aneurysms due to Segmental Arterial Mediolytic. Fortschr Röntgenstr 2019; 191: 1010–1014

ZUSAMMENFASSUNG

Ziel Die segmentale arterielle Mediolyse (SAM) ist eine seltene, nicht-atherosklerotische, nicht-inflammatorische und nicht-infektiöse Arteriopathie des mittleren Lebensalters, die vorwiegend mittelgroße Viszeralarterien betrifft und typischerweise zu dissezierten Aneurysmata führt, welche im Falle einer Ruptur mit einer hohen Mortalität einhergehen. Als Therapieoptionen kommen in Frage das „watchful waiting“, eine endovaskuläre oder eine chirurgische Intervention. Zurzeit existieren keine offiziellen Richtlinien. Unseres Wissens nach

existieren keine Untersuchungen über ausgedehnte Embolisierungen mehrerer Viszeralgefäße in dieser Patientengruppe.

Material und Methoden Wir haben retrospektiv das Resultat extensiver viszeraler Embolisierungen bei vier Patienten zwischen 2011 und 2016 untersucht mit Langzeit Follow-Up von bis zu 7 Jahren.

Ergebnisse Ein Patient präsentierte sich mit Ruptur von Aneurysmen der pancreatico-duodenalen Arkade, ein Patient mit dem Bild eines akuten Abdomens infolge einer Dissektion und zwei Patienten waren asymptomatisch. Die drei Letztgenannten zeigten unter engmaschiger Verlaufskontrolle (bis 12 Monate) einen Progress. Alle Patienten wurden endovaskulär behandelt, wobei jeweils das gesamte erkrankte Versorgungsgebiet, sowohl zuführende als auch abführende Gefäße, mittels Coils ausgeschaltet wurde. In drei von vier Fällen wur-

den alle hepatischen Arterien gecoilt. Bei einem Patienten wurde das gesamte Stromgebiet des Truncus coeliacus ausgeschaltet mittels Coiling der distalen Gefäße und Stentgraft des Truncusabgangs. Post-interventionell zeigten sich nach einem Follow-Up-Intervall von 2 bis 7 Jahren bis auf eine temporäre arterio-portale Fistel keine weiteren Kurzzeit- oder Langzeitkomplikationen. Interessanterweise entwickelten sich zudem nach dem akuten Krankheitsschub keine neuen Aneurysmata.

Schlussfolgerung Das endovaskuläre Ausschalten auch größerer viszeraler Versorgungsgebiete scheint eine sichere und effektive Behandlungsoption bei Patienten mit rupturierter oder progredienter SAM zu sein. Unter der Voraussetzung einer normalen Leberfunktion mit regelrechtem portalvenösem Fluss dürfte die hepatobiliäre Komplikationsrate, auch nach extensiver Embolisation, gering sein.

Introduction

Segmental arterial mediolysis (SAM) was described for the first time in 1976 [1]. It is a non-atherosclerotic, non-inflammatory, non-infectious arteriopathy primarily of the medium-sized splanchnic arteries characterized by vacuolar degeneration of the smooth muscle cells of the media. Over the course of the disease, the confluence of the vacuoles results in a disruption of the media with intramural hematoma and fibrin deposits. This results in segmental arterial mediolysis with a patchy appearance (“arterial gaps”) that ultimately becomes symptomatic in the form of dissections, aneurysms, stenoses and/or occlusions [2–5]. The etiology of the disease is currently not known but endothelial lesions resulting from repetitive vasospasms in hypoxia, hypotension, or sepsis have been postulated [6]. Primarily middle-age and older patients (40–80 years) are affected [7]. Splanchnic vessel regions are involved in approximately three-quarters of cases, with the splenic artery being affected most frequently [8].

A characteristic feature of SAM is dissected aneurysms that can potentially rupture causing life-threatening intraperitoneal and/or retroperitoneal bleeding. Alternatively, reparative mechanisms are triggered, resulting in the formation of granulation tissue with subsequent vessel wall fibrosis. Almost 50% of patients have multiple aneurysms. The mortality rate in the case of rupture is approx. 20% [7, 8].

SAM symptoms and imaging are non-specific. It is a diagnosis of exclusion. Other non-inflammatory vascular diseases, e. g. atherosclerosis, Marfan syndrome, Ehlers-Danlos syndrome, and fibromuscular dysplasia, as well as inflammatory vascular diseases like vasculitis and mycotic aneurysms must first be ruled out because the treatment of these entities is fundamentally different.

SAM can affect vast splanchnic areas and represents a therapeutic challenge. The treatment options include regular CT follow-ups, so-called watchful waiting, and an invasive (i. e., endo-

vascular or surgical) treatment approach. Official guidelines have not yet been published.

Spontaneous regression of SAM can occur [9]. After exclusion of an imminent rupture (imbibition in periarterial adipose tissue, wall calcification disruptions, penetrating ulcers) or end organ ischemia, conservative treatment with close monitoring and adjustment of the blood pressure can be successful in approximately 2/3 of cases [7]. If an intervention is necessary, endovascular therapy is probably preferable to surgical therapy based on the lower complication rates with similar success rates [7]. Aneurysms are excluded with coil embolization of the afferent and efferent vessels or stent grafting. Surgical options include resection of the aneurysm, vasoligation, and arterio-arterial bypass.

To our knowledge, extensive exclusion of entire splanchnic vessel regions has not yet been examined.

Materials and Methods

The postinterventional results of four patients of our institute who were diagnosed with SAM and treated with extensive embolization of the splanchnic arteries between 2011 and 2016 were studied retrospectively. With less than five patients studied on a retrospective basis, it was not necessary to obtain approval from the ethics committee. To rule out another pathology, a full diagnostic workup was performed. This included an extensive patient interview (e. g. infection, trauma, accompanying symptoms), family history, clinical examination, urinalysis, and determination of multiple laboratory parameters (including inflammatory parameters, BSR, various autoantibodies that are positive in vasculitis) The CT follow-up intervals were 1, 3, 6, 12, and 24 months for conservative treatment or following intervention. The last imaging after diagnosis or embolization was specified as the maximum follow-up time.

► **Table 1** Patients no. 1 and 2 had incidental findings on ultrasound and chest CT, respectively, while patients no. 3 and 4 were symptomatic.

patient	age, sex	pathological vessels (diameter)	primary therapy	course	follow-up
1	80, m	aneurysm of the common/proper hepatic artery (2.2 cm)	coil embolization of the common, right, media, left hepatic artery and gastroduodenal artery	aneurysm thrombosis	7 years
		aneurysm of the superior mesenteric artery (1.3 cm)	conservative	stationary size	7 years
2	49, m	dissected aneurysm of the celiac trunk (1.5 cm)	conservative	stationary size	3 years
		aneurysm of the proper hepatic artery (2.4 cm)	coil embolization of the common, right and left hepatic artery	thrombosis and shrinkage of the aneurysm	2 years ¹
3	51, m	dissection of the celiac trunk (1.1 cm)	initially conservative; in light of progression of multiple aneurysms after 6 months, a decision was made to perform coil embolization of the splenic artery, left gastric artery, right and left hepatic arteries, gastroduodenal artery, stent graft over the orifice of the celiac trunk	post-interventional iatrogenic temporary arterioportal fistula for 12 months	4 years
		dissection of the splenic artery with stenosis (8 mm)		spontaneous occlusion of the splenic artery with splenic infarction; embolization performed to prevent retrograde perfusion	
		dissected, partially thrombosed aneurysm of the common hepatic artery (1.7 cm)		post-interventional shrinkage ²	
		intramural hematoma of the gastroduodenal arterial with stenosis (0.6 cm)		post-interventional shrinkage	
		dissected, partially thrombosed aneurysm of the right hepatic artery (1.3 cm)		post-interventional shrinkage	
		dissected, partially thrombosed aneurysm of the left hepatic artery (1.1 cm)		post-interventional shrinkage	
		dissection of the left renal artery with stenosis (0.8 cm)		stationary size	
4	76, m	aneurysms of the anterior (0.6 cm) and posterior (2 × 0.4 cm) pancreaticoduodenal arcade	coil embolization of the entire anterior and posterior pancreaticoduodenal arcade	aneurysms no longer visible over time	5 years

¹ Calculated from the time of embolization.

² Evaluation slightly limited by artifacts caused by coils.

Results

The four patients were men 49 to 80 years old. Two patients had acute symptoms while the other two were asymptomatic and were diagnosed with SAM as an incidental finding (► **Table 1**).

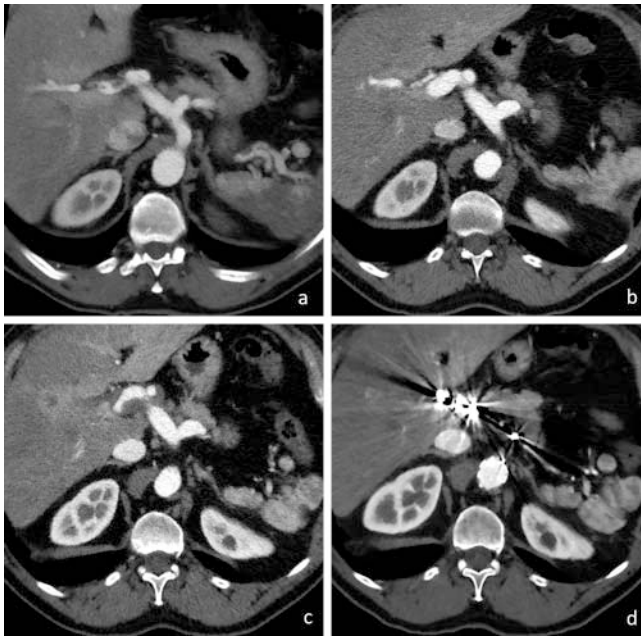One of the symptomatic patients complained of sudden severe abdominal pain radiating to the back. CT angiography showed three aneurysms of the pancreaticoduodenal arcade with a large hematoma at the head of the pancreas. The aneurysms were excluded via coil embolization.

The other symptomatic patient also reported sudden severe abdominal pain. CT angiography showed dissections and/or aneurysms of almost all branches of the celiac trunk (except the left gastric artery) and dissection of the left renal artery. A conservative approach with blood pressure regulation, thrombocyte aggregation inhibitors, and short-term follow-up was initially

decided upon in the interdisciplinary vascular board. Despite regressive symptoms, there was disease progression with a diameter of the right hepatic artery of up to 2.1 cm resulting in visible compression of the portal vein and perfusion inhomogeneity of the liver (► **Fig. 1**).

Aneurysms of the celiac trunk and the common/proper hepatic artery were seen in the two asymptomatic patients as incidental findings on abdominal ultrasound or chest CT. The interdisciplinary angio-board selected an active approach with coil embolization for patient #1 due to the highly irregular shape of the aneurysm of the common/proper hepatic artery. Patient #2 developed a 2.4-cm aneurysm of the proper hepatic artery between the 6 and 12-month follow-ups that was treated with coils due to the strong dynamics.

The entire diseased vessel segment was excluded via coil embolization in one session in all patients. The complete hepatic ar-



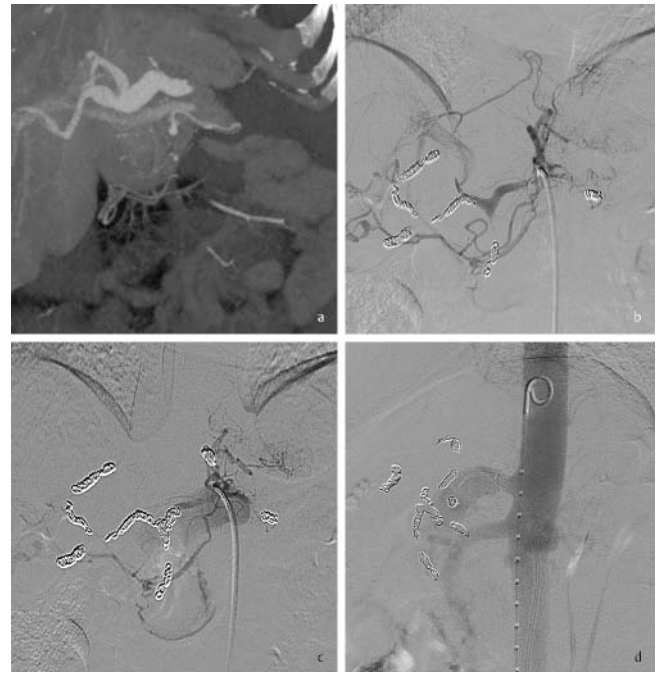
► **Fig. 1** **a** Initial CT showing aneurysm of the common right and left, with wall-adherent thrombi. Also visible is a large dissection of the splenic artery with splenic infarction. **b** CT follow-up after 3 months shows progressive enlargement of the hepatic arteries with thrombus dissolution. The proximal splenic artery is occluded. The spleen is already atrophied. **c** 6 months after the initial CT examination, progressive enlargement of the aneurysm with extensive wall thrombosis and impaired perfusion in liver segments II/III are seen. **d** 3 years after coil embolization and stent graft of the celiac trunk, the entire trunk vessel segment is occluded and the size of the hepatic aneurysms has decreased. The liver continues to be well perfused by tributaries.

tery was excluded in three cases. Normal liver function and an open portal vein were required for embolization. In one of these cases, the entire vascular bed of the celiac trunk was excluded by placing a stent graft over the orifice of the celiac trunk in addition to performing coil embolization due to a dissected aneurysm of the trunk (► **Fig. 2**). Due to arterioportal fistulas that occurred during the intervention, retrograde portal-venous perfusion of the trunk was seen for up to 1 year post-intervention and thrombosis only occurred subsequently.

All patients were hospitalized for one night for observation. Other than temporary arterioportal fistulas, no short-term or long-term complications, particularly bleeding, liver insufficiency, liver abscesses, or bile duct necrosis, were seen post-intervention. Complete regression of the aneurysms was seen over time. New irregularities or aneurysms were not seen.

Conclusion and discussion

The true prevalence of SAM is probably underestimated in the literature since its course can be asymptomatic or subclinical and not every patient with abdominal symptoms undergoes workup with angio-CT. Due to the underlying mediolysis and probable fragility of the vessels with a tendency toward dissection and



► **Fig. 2** **a** Coronal maximum intensity projection (MIP) of CT 6 months after initial diagnosis with significant enlargement and irregularity of the common hepatic artery and the right and left hepatic arteries. The wall-adherent thrombi (Fig. 1) are not readily visible in this projection. **b** Angiography of the celiac trunk after coil embolization of the splenic artery, the hepatic arteries, and the gastroduodenal artery: The common hepatic artery is noticeably smooth with no more tortuosity. The liver is partially supplied by the branches of the left gastric artery. A fistula between the left hepatic artery and the portal artery is already seen here. **c** and **d** Anteroposterior and lateral angiography of the celiac trunk after further embolization of the common hepatic artery and the left gastric artery. There is a further large fistula directly between the trunk and the portal vein.

rupture, a primary conservative approach entailing watchful waiting is to be preferred over catheter-based or surgical manipulation in patients with SAM whenever clinically appropriate. The fragility was highlighted in our study by the iatrogenic arterioportal fistula. In the case of a watchful waiting treatment strategy, it should be taken into consideration that a conservative approach was only successful in 64% of cases (9 of 14 cases) in the literature, while endovascular or surgical treatment was successful in 96% of cases (68 of 71 cases) [7]. On the one hand this could be due to an underdiagnosis for the above-mentioned reasons with spontaneous healing. On the other hand, there is probably a publication bias because significantly fewer conservatively treated cases have been published. Extensive endovascular exclusion of the entire diseased arterial segment with coils and possibly a stent graft could be a safe and effective treatment option in patients with ruptured or rapidly growing aneurysms. Provided that patients have normal liver function and proper portal venous flow, risk of hepatobiliary complications seems to be low even after extensive embolization.

Limitations of our study are the lower number of treated cases (n = 4), the retrospective analysis, and the lack of randomization and controls.

CLINICAL RELEVANCE OF THE STUDY

From a scientific standpoint, a randomized controlled study regarding the outcome of various treatment modalities in SAM would be desirable. However, since the disease is a rare diagnosis of exclusion, such studies are hardly feasible and observational studies with long-term follow-up represent a more realistic approach. This study provides further evidence that endovascular exclusion even of large splanchnic vessel regions is a possible treatment option without major complications. In addition, the study showed that new diseased areas typically do not manifest after the “acute episode”, which coincides with the literature published to date.

Conflict of Interest

The authors declare that they have no conflict of interest.

References

- [1] Slavin RE, Gonzalez-Vitale JC. Segmental mediolytic arteritis: a clinical pathologic study. *Lab Invest* 1976; 35: 23–29
- [2] Slavin RE, Cafferty L, Cartwright J Jr. Segmental mediolytic arteritis. A clinicopathologic and ultrastructural study of two cases. *Am J Surg Pathol* 1989; 13: 558–568
- [3] Ito MR, Ohtani H, Nakamura Y et al. An autopsy case of segmental mediolytic arteritis (SMA) accompanied with microscopic polyarteritis nodosa. *Ryumachi* 1995; 35: 693–698
- [4] Armas OA, Donovan DC. Segmental mediolytic arteritis involving hepatic arteries. *Arch Pathol Lab Med* 1992; 116: 531–534
- [5] Heritz DM, Butany J, Johnston KW et al. Intraabdominal hemorrhage as a result of segmental mediolytic arteritis of an omental artery: case report. *J Vasc Surg* 1990; 12: 561–565
- [6] Slavin RE, Saeki K, Bhagavan B et al. Segmental arterial mediolysis: a precursor to fibromuscular dysplasia? *Mod Pathol* 1995; 8: 287–294
- [7] Kim HS, Min SI, Han A et al. Longitudinal evaluation of segmental arterial mediolysis in splanchnic arteries: case series and systematic review. *PLoS One* 2016; 11: e0161182
- [8] Tameo MN, Dougherty MJ, Calligaro KD. Spontaneous dissection with rupture of the superior mesenteric artery from segmental arterial mediolysis. *J Vasc Surg* 2011; 53: 1107–1112
- [9] Michael M, Widmer U, Wildermuth S et al. Segmental arterial mediolysis: CTA findings at presentation and follow-up. *Am J Roentgenol* 2006; 187: 1463–1469