

A huge inflammatory fibroid polyp: an unexpected finding after positive fecal immunochemical test

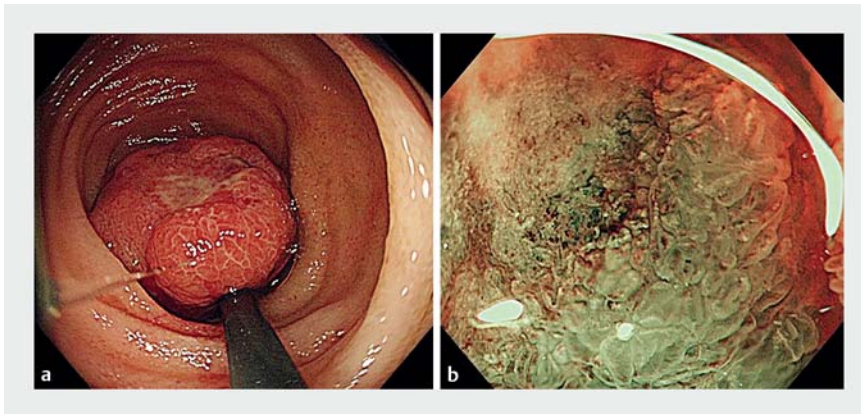
A 45-year-old man was referred to our surgery department for treatment of an ileal polyp detected in a previous colonoscopy, after a positive fecal immunochemical test. The colonoscopy showed a 40-mm pedunculated polyp, with ulcers, in the distal ileum (► **Fig. 1 a**). A magnifying endoscopy with narrow-band imaging showed no capillary vessels, which suggested that a non-neoplastic epithelium covered a subepithelial

lesion (► **Fig. 1 b**). The pathological examination of biopsies showed only inflammatory etiology and we could not reach a definitive diagnosis.

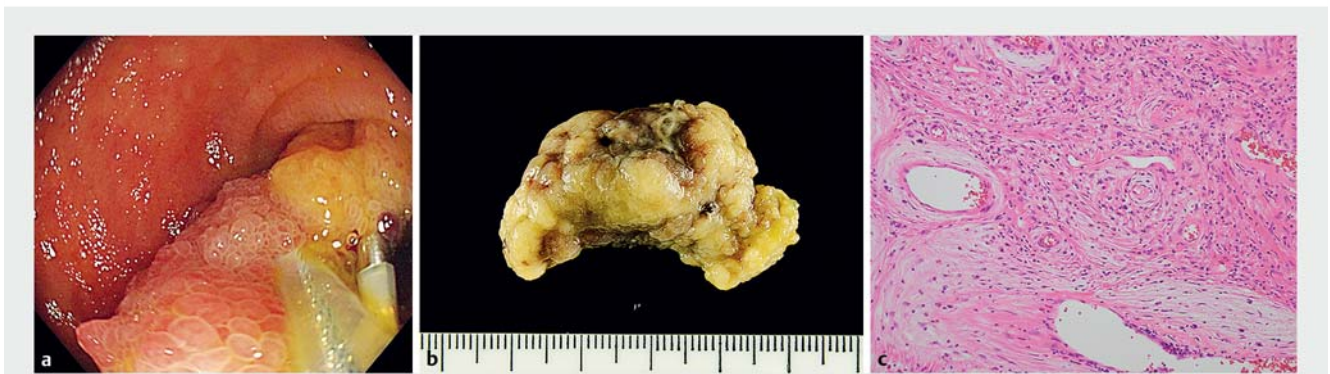An endoscopic resection was initiated for histological evaluation. We performed a clip-assisted snare polypectomy and achieved en bloc removal, with no adverse events (► **Fig. 2 a**, ► **Video 1**). Gross examination showed a 40-mm polyp with ulceration (► **Fig. 2 b**). Pathological ex-

amination showed fibroblast proliferation and vessels infiltrated with inflammatory cells, including eosinophils (► **Fig. 2 c**). The diagnosis was inflammatory fibroid polyp (IFP).

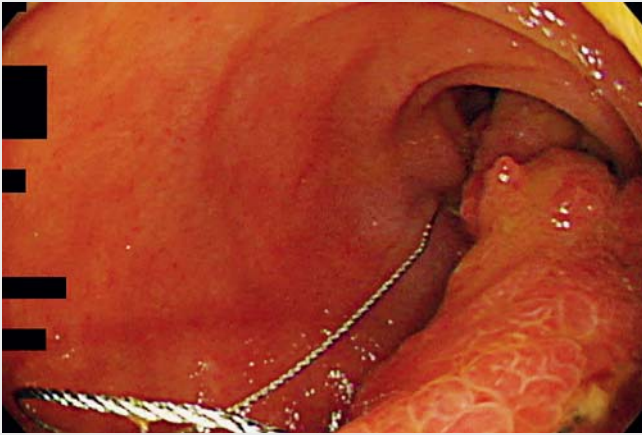
IFPs are benign submucosal lesions. The endoscopic features of small-bowel IFPs are not well recognized, because most reported cases undergo surgery with no endoscopic attempts owing to the presence of urgent symptoms, such as intussusception, obstruction, or bleeding [1]. In the current case, the ileal polyp was asymptomatic and was detected by colonoscopy. In addition, we could observe pedunculated morphology, patchy ulceration, and a non-neoplastic epithelium covering (subepithelial polyp). Our case is, to the best of our knowledge, the largest small-bowel IFP treated by endoscopy based on preoperative diagnosis; previously reported cases measured 20–30 mm in diameter [1–4]. By clipping the stalk of the polyp to prevent postpolypectomy bleeding [5], we could remove the huge polyp with no complications. In such asymptomatic cases, endoscopic removal for apparently benign ileal subepithelial polyps could not only provide histological clues for treatment but also avoid surgery.



► **Fig. 1** Endoscopic images. **a** Colonoscopy showed a 40-mm pedunculated polyp, with ulcers, in the distal ileum. **b** Magnifying endoscopy with narrow-band imaging showed no capillary vessels, which suggested that a non-neoplastic epithelium covered a subepithelial lesion.



► **Fig. 2** Endoscopic treatment and pathological diagnosis. **a** A clip-assisted snare polypectomy was performed, with no complications. **b** Gross examination showed a 40-mm polyp with ulceration. **c** Pathological examination showed fibroblast proliferation and vessels infiltrated with inflammatory cells, including eosinophils.



Video 1 The colonoscopy showed a 40-mm pedunculated polyp, with ulcers, in the distal ileum. The huge polyp was removed by clip-assisted snare polypectomy, with no complications.

Bibliography

DOI <https://doi.org/10.1055/a-0862-0133>

Published online: 25.3.2019

Endoscopy 2019; 51: E147–E148

© Georg Thieme Verlag KG

Stuttgart · New York

ISSN 0013-726X

ENDOSCOPY E-VIDEOS

<https://eref.thieme.de/e-videos>



Endoscopy E-Videos is a free access online section, reporting on interesting cases and new techniques in gastroenterological endoscopy. All papers include a high quality video and all contributions are freely accessible online.

This section has its own submission website at

<https://mc.manuscriptcentral.com/e-videos>

Endoscopy_UCTN_Code_CCL_1AC_2AC

Competing interests

None

The authors

Hidegori Kimura, Kenichiro Imai, Kinichi Hotta, Sayo Ito, Yoshihiro Kishida, Hiroyuki Ono

Division of Endoscopy, Shizuoka Cancer Center, Shizuoka, Japan

Corresponding author

Kenichiro Imai, MD

Division of Endoscopy, Shizuoka Cancer Center, 1007, Shimonagakubo, Nagaizumi-cho, Suntogun, Shizuoka 411-8777, Japan
Fax: +81-55-9895783
k.imai1977@gmail.com

References

- [1] Yoon DW, Lee BJ, Lee JH et al. A case of giant inflammatory ileal polyp removed by double-balloon enteroscopy. *Clin Endosc* 2012; 45: 198–201
- [2] Wolff JH, Twaddell WS, Darwin PE et al. Endoscopic resection of an ileal inflammatory fibroid polyp using retrograde single-balloon enteroscopy. *Clin Gastroenterol Hepatol* 2009; 7: e66–e67
- [3] Laskaratos FM, Vlachou E, Loung TV et al. Endoscopic resection of a giant ileal inflammatory fibroid polyp by retrograde double-balloon enteroscopy. *Endoscopy* 2016; 48: e14–e15
- [4] Takeshita K, Kashiwagi K, Ishibashi Y et al. An ileal inflammatory fibroid polyp treated by endoscopic resection. *Intern Med* 2016; 55: 2901–2902
- [5] Jeong-Seon Ji, Seung-Woo Lee, Tae HoKim et al. Comparison of prophylactic clip and endoloop application for the prevention of postpolypectomy bleeding in pedunculated colonic polyps: a prospective, randomized, multicenter study. *Endoscopy* 2014; 46: 598–604