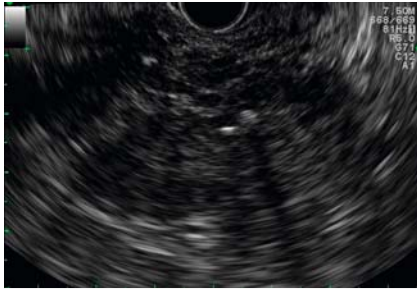


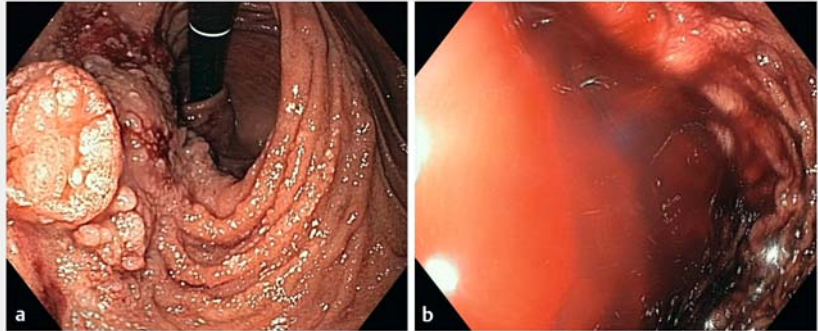
Endoscopic ultrasound-guided injection of N-butyl-2-cyanoacrylate into portal venous collateral vessels that were feeding bleeding duodenal varices



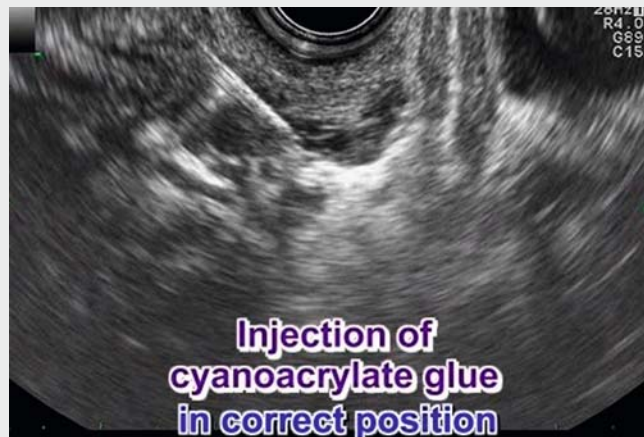
► **Fig. 1** Endosonographic view of calcifying pancreatitis.

Endoscopic injection of sclerosants (N-butyl-2-cyanoacrylate, fibrin glue) is a well-established treatment for bleeding gastroesophageal and ectopic varices, with injection into the varices usually performed under direct endoscopic view [1]. Alternatively, injection can be performed under endoscopic ultrasound (EUS) guidance [2–4]. We describe a case of duodenal varices with recurrent bleeding that were not accessible to direct endoscopic injection because of postoperatively altered anatomy (► **Fig. 1** and ► **Fig. 2**).

A 25-year-old woman with a congenital malformation complex (VACTERL association) underwent resection of the pancreatic tail with duodenojejunostomy and splenectomy at the age of 10 years because of obstructive jaundice due to severe chronic calcifying pancreatitis. After that and due to cardiopathy with stasis (corrected Fallot tetralogy), the patient developed portal venous collateral vessels and duodenal varices. Because direct sclerosant injection was not possible, we examined the duodenum and stomach using EUS. Even gentle compression of the duodenal wall by the EUS device, which is necessary for a proper examination, made it impossible to perform EUS-guided injection therapy of the submucosal duodenal varices; however, we found portal venous collaterals feeding the duodenal varices. We



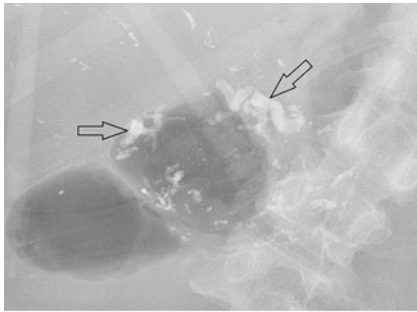
► **Fig. 2** Endoscopic views showing: **a** the major papilla and duodenojejunostomy with hyperplastic tissue; **b** the region of the major duodenal papilla and duodenojejunostomy with variceal bleeding.



► **Video 1** Demonstration of endoscopic ultrasound-guided injection of cyanoacrylate glue into portal venous collaterals that were feeding duodenal varices.

therefore successfully treated the duodenal varices by EUS-guided injection of N-butyl-2-cyanoacrylate into the feeding portal venous collaterals (► **Fig. 3**). In two sessions, with the patient under general anesthesia, we applied a total of four portions of the mixture, which consisted of 0.5 mL N-butyl-2-cyanoacrylate and 0.7 mL Lipiodol. In doing this, it is vital to ensure that the injection is strictly intravascular. Before puncturing each

collateral, we used a 22 G needle to inject distilled water first into the vessel. Once we were sure of the intravascular position, we injected N-butyl-2-cyanoacrylate (► **Video 1**). It was even possible to puncture and treat vessels with a diameter of 3 mm. No complications occurred in our patient and, to date, no new bleeding has been observed. We conclude that EUS-guided obliteration of portal venous collaterals that are



► **Fig. 3** Fluoroscopic view of the region showing portal venous collaterals treated by cyanoacrylate glue (arrows) and calcifying pancreatitis.

feeding varices is an effective treatment for recurrent bleeding from varices that are not suitable for direct endoscopic treatment.

Endoscopy_UCTN_Code_TTT_1AS_2AB

Competing interests

None

The authors

Ingo Wallstabe¹, Marlen Zurek², Christian Geyer³

- 1 Department of Gastroenterology and Hepatology, Klinikum St. Georg, Leipzig, Germany
- 2 Department of Paediatrics and Adolescent Medicine, Klinikum St. Georg, Leipzig, Germany
- 3 Department of Pediatric Surgery, Klinikum St. Georg, Leipzig, Germany

Corresponding author

Ingo Wallstabe, MD

Department of Gastroenterology and Hepatology, Klinikum St. Georg GmbH, Delitzscher Str. 141, 04129 Leipzig, Germany
 Fax: +49-341-9092673
 ingo.wallstabe@endoskopieren.de

References

- [1] Ibrahim M, Mustafa I, Deviere J. New developments in managing variceal bleeding. *Gastroenterology* 2018; 154: 1964–1969
- [2] Gonzalez JM, Giacino C, Pioche M et al. Endoscopic ultrasound-guided vascular therapy: is it safe and effective? *Endoscopy* 2012; 44: 539–542
- [3] Kimura G, Hashimoto Y, Ikeda M. Successful obliteration of bleeding duodenal varices by EUS-guided injection of N-butyl-2-cyanoacrylate. *VideoGIE* 2017; 2: 317–319
- [4] Dedania B, Kukreja K, Davee T et al. Endoscopic ultrasound-guided sclerosant injection and coil embolization of bleeding gastric varices. *Endoscopy* 2018; 50: 283–285

Bibliography

DOI <https://doi.org/10.1055/a-0915-1424>

Published online: 23.5.2019

Endoscopy 2019; 51: E293–E294

© Georg Thieme Verlag KG

Stuttgart · New York

ISSN 0013-726X

ENDOSCOPY E-VIDEOS

<https://eref.thieme.de/e-videos>



Endoscopy E-Videos is a free access online section, reporting on interesting cases and new

techniques in gastroenterological endoscopy. All papers include a high quality video and all contributions are freely accessible online.

This section has its own submission website at <https://mc.manuscriptcentral.com/e-videos>