

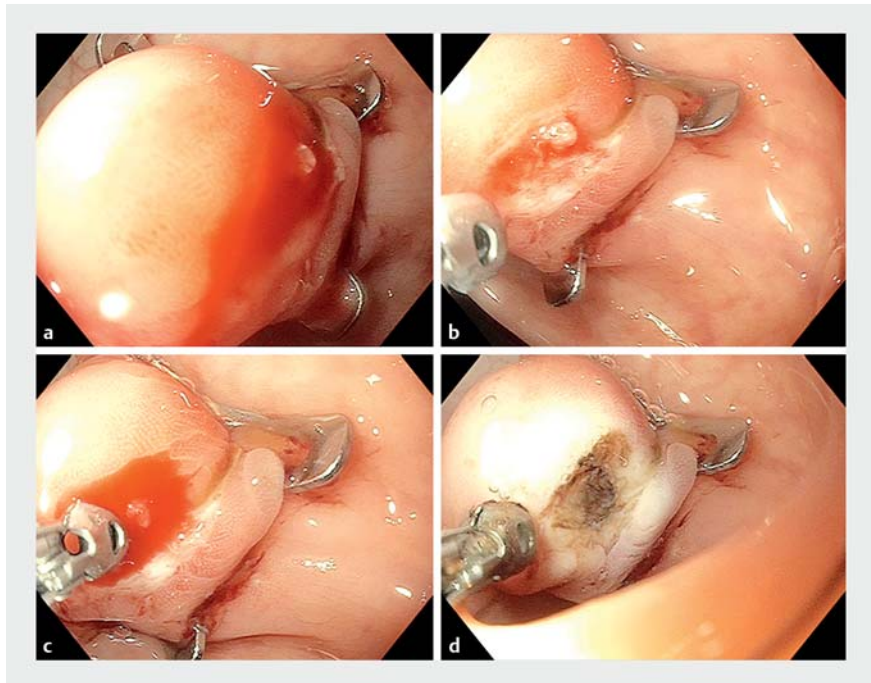
## An over-the-scope clip placed for large colonic perforation can be complicated by delayed bleeding despite its known hemostatic mechanical effect

The efficacy and safety of the over-the-scope clip (OTSC) to manage acute gastrointestinal defects have been demonstrated for several years [1]. Data have shown a technical success rate of almost 100% [2], with very good safety [3]. The most common complication after the use of an OTSC for acute gastrointestinal defects is peritonitis, which occurs when leaks remain [4]. We present a case of delayed bleeding after the closure of an iatrogenic colonic perforation with an OTSC (► **Video 1**).

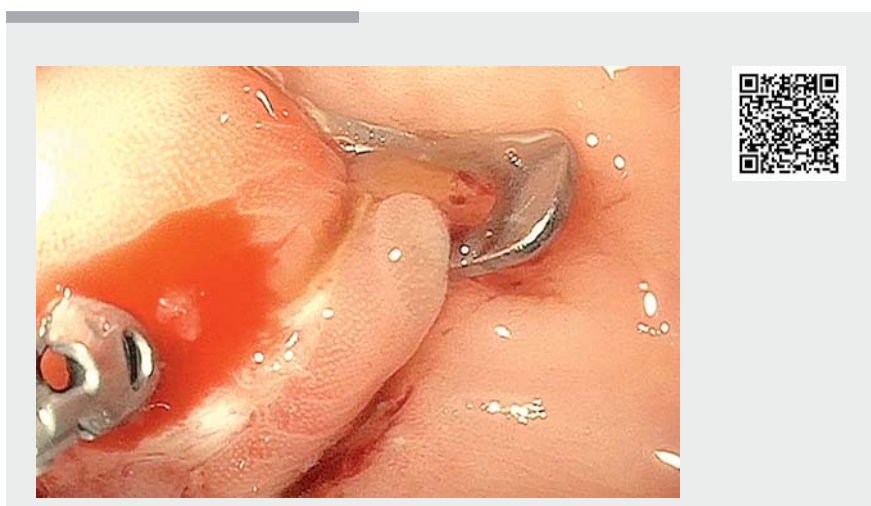A 48-year-old woman underwent a colonoscopy to rule out a colorectal tumor in the context of paraneoplastic polymyositis with severe malnutrition and ongoing corticosteroid therapy over several days. The colonoscopy was complicated by a sigmoid perforation caused by the scope (> 1 cm). This iatrogenic perforation was managed as per procedure by placement of an OTSC, with technical success. No surgery was necessary in the aftermath. However, 6 days after the successful closure, the patient developed hematochezia and a fall in her hemoglobin was noted. At the time, she was receiving ongoing anticoagulation for a mechanical mitral valve. A second endoscopy confirmed that there was bleeding at the site of the OTSC (► **Fig. 1 a**). In fact, an enlarged pulsating vessel with active non-pulsating bleeding could be seen in the middle of the clip teeth (► **Fig. 1 b, c**). Hemostasis was achieved with hot biopsy forceps coagulation (► **Fig. 1 d**).

This case highlights an unusual outcome of an OTSC that has not been well described in safety studies [4]. Furthermore, it is important to be aware of this surprising cause of bleeding, even though OTSCs are well known for their use in controlling bleeding.

In conclusion, bleeding can be a complication of an OTSC and it can present in a delayed manner. Despite the hemostatic



► **Fig. 1** Endoscopic images of delayed bleeding complicating the placement of an over-the-scope clip (OTSC) for colonic perforation showing: **a** bleeding from the center of the mucosa that had been trapped into the OTSC; **b** a vessel drawn into the OTSC teeth; **c** active bleeding after contact with the forceps; **d** the appearance after hot biopsy forceps coagulation.



► **Video 1** An over-the-scope clip (OTSC) placed for a large colonic perforation was complicated by delayed bleeding despite its known hemostatic mechanical effect.

features of OTSCs, it is important to do a second-look endoscopy to re-examine the OTSC site in patients who present with delayed bleeding.

Endoscopy\_UCTN\_Code\_CPL\_1AJ\_2AZ

## Competing interests

None

## The authors

**Armelle Schoch<sup>1</sup>, Gaspard Bertrand<sup>1</sup>, Jérôme Rivory<sup>1</sup>, Myrtille Fouche<sup>2</sup>, Hugo Tête<sup>2</sup>, Julie Perinel<sup>3</sup>, Mathieu Pioche<sup>1</sup>**

- 1 Department of Endoscopy and Gastroenterology, Pavillon L, Edouard Herriot Hospital, Lyon, France
- 2 Anesthesiology department, Pavillon L, Edouard Herriot Hospital, Lyon, France
- 3 Department of Visceral Surgery, Pavillon D, Edouard Herriot Hospital, Lyon, France

## Corresponding author

**Mathieu Pioche, MD**

Endoscopy unit – Digestive Disease department, Pavillon L – Edouard Herriot Hospital, 69437 Lyon, France  
mathieu.pioche@chu-lyon.fr

## References

- [1] Nishiyama N, Mori H, Kobara H et al. Efficacy and safety of over-the-scope clip: including complications after endoscopic submucosal dissection. *World J Gastroenterol* 2013; 19: 2752–2760
- [2] Goenka MK, Rai VK, Goenka U et al. Endoscopic management of gastrointestinal leaks and bleeding with the over-the-scope clip: a prospective study. *Clin Endosc* 2017; 50: 58–63
- [3] Raithel M, Albrecht H, Scheppach W et al. Outcome, comorbidity, hospitalization and 30-day mortality after closure of acute perforations and postoperative anastomotic leaks by the over-the-scope clip (OTSC) in an unselected cohort of patients. *Surg Endosc* 2017; 31: 2411–2425

- [4] Manta R, Mangiafico S, Zullo A et al. First-line endoscopic treatment with over-the-scope clips in patients with either upper or lower gastrointestinal bleeding: a multicenter study. *Endosc Int Open* 2018; 6: E1317–E1321

## Bibliography

DOI <https://doi.org/10.1055/a-1022-4187>  
Published online: 25.10.2019  
*Endoscopy* 2020; 52: E118–E119  
© Georg Thieme Verlag KG  
Stuttgart · New York  
ISSN 0013-726X

**ENDOSCOPY E-VIDEOS**  
<https://eref.thieme.de/e-videos>



*Endoscopy E-Videos* is a free access online section, reporting on interesting cases and new techniques in gastroenterological endoscopy. All papers include a high quality video and all contributions are freely accessible online.

This section has its own submission website at  
<https://mc.manuscriptcentral.com/e-videos>