

Diagnosis and management of iatrogenic endoscopic perforations: European Society of Gastrointestinal Endoscopy (ESGE) Position Statement – Update 2020



Authors

Gregorios A. Paspatis¹, Marianna Arvanitakis², Jean-Marc Dumonceau³, Marc Barthet⁴, Brian Saunders⁵, Stine Ydegaard Turino⁶, Angad Dhillon⁵, Maria Fragaki¹, Jean-Michel Gonzalez⁴, Alessandro Repici⁷, Roy L.J. van Wanrooij⁸, Jeanin E. van Hooft⁹

Institutions

- 1 Gastroenterology Department, Venizelion General Hospital, Heraklion, Crete-Greece
- 2 Gastroenterology, Hepatopancreatology, and Digestive Oncology, Erasme Hospital, Universite Libre de Bruxelles, Brussels, Belgium
- 3 Gastroenterology Service, Centre Hospitalier Universitaire de Charleroi, Charleroi, Belgium
- 4 APHM, Hôpital Nord, Marseille, France
- 5 St Mark's Hospital, Wolfson Unit for Endoscopy, North West London Hospitals University Trust, Harrow, London, UK
- 6 Department of Surgery, Zealand University Hospital, Denmark
- 7 Department of Gastroenterology, Digestive Endoscopy Unit, IRCCS Istituto Clinico Humanitas, Milan, Italy
- 8 Department of Gastroenterology and Hepatology, AG&M Research Institute, Vrije Universiteit Amsterdam, Amsterdam UMC, Amsterdam, The Netherlands
- 9 Department of Gastroenterology and Hepatology, Leiden University Medical Center, The Netherlands

Bibliography

DOI <https://doi.org/10.1055/a-1222-3191>

Published online: 11.8.2020 | Endoscopy 2020; 52: 792–810

© Georg Thieme Verlag KG Stuttgart · New York

ISSN 0013-726X

Corresponding author

Gregorios A. Paspatis, MD PhD, Gastroenterology Department, Venizelion General Hospital, Heraklion, L. Knosou 71409, Crete-Greece
gpaspatis@gmail.com

 Supplementary material

Online content viewable at:

<https://doi.org/10.1055/a-1222-3191>

SUMMARY OF RECOMMENDATIONS

- 1 ESGE recommends that each center implements a written policy regarding the management of iatrogenic perforations, including the definition of procedures that carry a higher risk of this complication. This policy should be shared with the radiologists and surgeons at each center.
- 2 ESGE recommends that in the case of an endoscopically identified perforation, the endoscopist reports its size and location, with an image, and statement of the endoscopic treatment that has been applied.
- 3 ESGE recommends that symptoms or signs suggestive of iatrogenic perforation after an endoscopic procedure should be rapidly and carefully evaluated and documented with a computed tomography (CT) scan.
- 4 ESGE recommends that endoscopic closure should be considered depending on the type of the iatrogenic perforation, its size, and the endoscopist expertise available at the center. Switch to carbon dioxide (CO₂) endoscopic insufflation, diversion of digestive luminal content, and decompression of tension pneumoperitoneum or pneumothorax should also be performed.
- 5 ESGE recommends that after endoscopic closure of an iatrogenic perforation, further management should be based on the estimated success of the endoscopic closure and on the general clinical condition of the patient. In the case of no or failed endoscopic closure of an iatrogenic perforation, and in patients whose clinical condition is deteriorating, hospitalization and surgical consultation are recommended.

SOURCE AND SCOPE

This position paper is an official statement from the European Society of Gastrointestinal Endoscopy (ESGE). It updates the 2014 ESGE recommendations on inadvertent iatrogenic perforations occurring during gastrointestinal endoscopy.

ABBREVIATIONS

ASGE	American Society of Gastrointestinal Endoscopy
BSG	British Society of Gastroenterology
CO₂	carbon dioxide
CT	computed tomography
DBE	double-balloon enteroscopy
DMI	deep mural injury
EMR	endoscopic mucosal resection
ERCP	endoscopic retrograde cholangiopancreatography
ESD	endoscopic submucosal dissection
EUS	endoscopic ultrasound
EVT	endoscopic vacuum therapy
ESGE	European Society of Gastrointestinal Endoscopy
FCSEMS	fully covered self-expandable metal stent
GI	gastrointestinal
OTS	over-the-scope
PCSEMS	partially covered self-expandable metal stent
PICO	population, interventions, comparators, outcomes
POEM	peroral endoscopic myotomy
PPI	proton pump inhibitor
RCT	randomized controlled trial
SEMS	self-expandable metal stent
SEPS	self-expandable plastic stent
TTS	through-the-scope

Introduction

This Position Statement updates recommendations issued by ESGE in 2014 regarding iatrogenic perforations occurring during gastrointestinal (GI) endoscopy, not including purposely performed perforations. As in 2014 [1], these recommendations are defined as a position statement rather than a guideline because of the scarcity of high quality studies, mainly due to the rarity of iatrogenic perforation.

Iatrogenic perforations are rare but severe adverse events, therefore adequate diagnosis and management are of paramount importance.

Methods

ESGE commissioned this Position Statement. The development process included meetings and online discussions among members of the project committee during February 2019 and December 2019. Subgroups were formed, each in charge of a

series of key questions that were clearly defined using PICO (population, interventions, comparators, outcomes) methodology [2]. The project committee chairs (G.P., J.v.H.) worked with the subgroup leaders (A.R., M.B., J.M.D., S.Y.T., B.S.) to identify pertinent search terms that included: iatrogenic perforation, endoscopy, clips, surgery, as well as terms pertinent to specific key questions.

Searches were performed on Medline (via Pubmed) and the Cochrane Central Register of Controlled Trials up to October 2019. This time-point should be the starting point in the search for new evidence for future updates to this Position Statement. Articles were first selected by title; their relevance was then assessed by reviewing full-text articles, and publications with content that was considered irrelevant were excluded. Because of the lack of well-designed studies, quality of evidence and strength of recommendations were not formally graded [3].

Each subgroup developed draft proposals that were presented to the entire group for general discussion during a meeting held on October 2019 (in Barcelona, Spain). Further details on the methodology of ESGE guidelines have been reported elsewhere [3].

In February 2020, a draft prepared by G.P. was sent to all group members for review. The draft was reviewed by two external reviewers and then sent for further comments to the ESGE national societies and individual members. After agreement on a final version, the manuscript was submitted to the journal *Endoscopy* for publication. All authors agreed on the final revised version. This Guideline was issued in 2020 and will be considered for update in 2025. Any interim updates will be noted on the ESGE website: <http://www.esge.com/esgeguidelines.html>.

Recommendations and statements

A summary of the recommendations and statements is presented at the beginning of this document.

General policy

RECOMMENDATION

ESGE recommends that each center implements a written policy regarding the management of iatrogenic perforation, including the definition of procedures that carry a higher risk of this complication. This policy should be shared with the radiologists and surgeons at each center.

Iatrogenic perforation is associated with a high risk of morbidity and mortality [4, 5]. It is best managed by a multidisciplinary approach, including the competences of endoscopists, radiologists, and surgeons that need to be promptly available. The implementation in each center of a written policy/protocol regarding the management of iatrogenic perforation may prevent serious complications. For instance failure to use computed tomography (CT) scan instead of plain films to detect subtle perforations may result in a diagnostic delay. Moreover, the

simple awareness that a particular procedure carries a higher risk of esophageal perforation should indicate not to perform the procedure unless a surgeon with adequate thoracic competence is available. As mentioned in the previous Position Statement, the availability of dedicated protocols and the adoption of the ESGE performance measures for complications in GI endoscopy may also represent structural quality indicators for the health system [6, 7].

The stratification of procedures between low and high risk for iatrogenic perforation is of importance for patients' informed consent, evaluation of post-endoscopic symptoms, and as a quality performance measure. In advanced endoscopic procedures that are high risk and invasive, such as endoscopic submucosal dissection (ESD), large endoscopic mucosal resection (EMR), peroral endoscopic myotomy (POEM), and large balloon dilation in the papilla, perforation is an accepted and anticipated event that is treated conservatively in most cases [8–11]. All perforations should be reported, and measures should be taken if they occur more frequently than defined thresholds [7].

Reporting

RECOMMENDATION

ESGE recommends that in the case of an endoscopically identified iatrogenic perforation, the endoscopist reports its size and location with an image and statement of the endoscopic treatment that has been applied.

Acute iatrogenic perforation related to GI endoscopy is defined as the recognition of gas or luminal fluids outside the GI tract [12] or any endoscopically identified definite visible sign of perforation during or in time related to endoscopy. The timing of diagnosis is decisive in influencing the management and the patient outcome [13–15]. Endoscopy is considered to be a valuable tool in the early diagnosis of iatrogenic perforation [16]. In the case of an endoscopically recognized iatrogenic perforation, a comprehensive and clear written report has a substantial part in deciding further management. Thus, incomplete reporting—that may be dictated by the fear of future medicolegal litigation—may expose patients to pointless diagnostic or therapeutic delays and generate a suboptimal outcome. A clear report, stating that the endoscopic therapy applied to the iatrogenic perforation was effective or not, might decisively influence the strategy of treating the patient conservatively or surgically. Photographic or video documentation of the perforated area might be useful for the decision making, and also for legal considerations.

RECOMMENDATION

ESGE recommends that symptoms or signs suggestive of iatrogenic perforation after an endoscopic procedure should be rapidly and carefully evaluated and documented with a CT scan.

Iatrogenic perforation is not always recognized at endoscopy [17, 18], therefore a high level of suspicion for such perforation is required when evaluating specific post-endoscopy symptoms, especially following procedures carrying increased risk for perforation. Early search for iatrogenic perforation should be prompted by unusual abdominal pain with distension, chest pain, subcutaneous emphysema, or shortness of breath, while iatrogenic perforation at a later stage is associated with more severe symptoms or signs, such as systemic inflammatory response, hypotension, and mental confusion. An early diagnosis has been shown to substantially impact the post-perforation outcome, mainly because it allows endoscopic treatment or potential surgical intervention in an uncontaminated setting [5, 16, 17, 19–21].

Imaging modalities such as abdominal plain film radiography or CT scan are commonly performed in the case of clinically suspected or diagnosed perforation, to verify the presence of gas or fluid collections [22]. Cross-sectional imaging has an improved sensitivity and specificity over conventional radiography in detecting small amounts of free gas, liquids, and small pneumothorax [16, 23, 24]. Moreover, CT scan can assess whether a previously performed endoscopic closure was successful. For suspected upper GI perforations, the ingestion of water-soluble contrast medium prior to CT scan adds accuracy because it may display the site of extravasation or it may confirm the effective closure of the defect [25]. After endoscopic resection, small bubbles of gas may be seen without true iatrogenic perforation [14, 26]. Thus, radiologic findings should always be evaluated in combination with the endoscopic and clinical findings.

The 2010 American Society for Gastrointestinal Endoscopy (ASGE) lexicon for endoscopic adverse events may be used to stratify the severity of iatrogenic perforation [12]. It includes four grades of severity based mainly on the need for hospitalization.

Treatment: general considerations

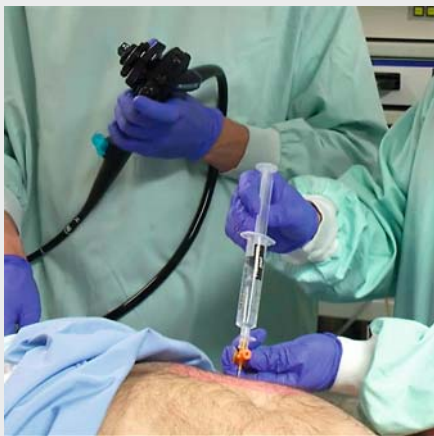
RECOMMENDATION

ESGE recommends that endoscopic closure should be considered depending on the type of the iatrogenic perforation, its size, and the endoscopist expertise available at the center. Switch to carbon dioxide (CO₂) endoscopic insufflation, diversion of digestive luminal content, and decompression of tension pneumoperitoneum or pneumothorax should also be performed.

The therapy recommended for iatrogenic perforation depends on the timing of diagnosis (intra- or post-procedural), the presence of luminal contents and their character ("clean" or not), the characteristics of the perforation (size, location), the patient's general status, the experience of the endoscopist, and the availability of closure devices. The therapeutic options can be immediate endoscopic closure of the perforation, conservative, or a surgical approach. In the cases where the iatrogenic perforation is recognized during the endoscopy, the

completion of the interventional procedure is advised, if at all possible and reasonable.

Immediate, if possible, endoscopic closure results in the prevention of peritonitis or mediastinitis and reduces the need for a surgical intervention [27–29]. A variety of endoscopic clips have been applied according to the size of iatrogenic perforation. Through-the-scope (TTS) clips are useful for closing a small iatrogenic perforation, provided that the tissue surrounding the edges is compliant and nonfibrotic. TTS clips vary in terms of their diameter, rotation capacity, and deployment capability after multiple openings [30,31]. Generally, they may only be used to treat small defects (<10 mm) because of their limited wingspan [32]. Larger perforations (>10 mm but <20–25 mm) may be treated with over-the-scope (OTS) clips [30]. Defects larger than 30 mm are rather difficult to close endoscopically. However, the wide use of OTS clips or, less often, suturing systems in everyday practice has enhanced the efficacy of endoscopic closure, even in larger perforations [33–38]. Nasogastric or nasoduodenal tube insertion may be beneficial for decompression and diversion of GI fluids. In the case of hemodynamic instability or respiratory failure due to gas under tension, decompression should be emergently performed [39]. Tension pneumoperitoneum should properly be treated aiming to avoid development of the compartment syndrome. A large-diameter venous catheter is used and is advanced over the needle in order to minimize the risk of injury to the abdominal organs (▶ **Video 1**). The use of CO₂ in GI endoscopy has become a standard practice for most procedures, but this is even more important in the setting of procedures with increased risk of iatrogenic perforation (e.g. ESD) or in the case of suspected or confirmed iatrogenic perforation [40–43].



▶ **Video 1** Drainage of a pneumoperitoneum performed by Professors H. Inoue and P. Fockens.
Online content viewable at:
<https://doi.org/10.1055/a-1222-3191>

RECOMMENDATION

ESGE recommends that after endoscopic closure of an iatrogenic perforation, further management should be based on the estimated success of the endoscopic closure and on the general clinical condition of the patient. In the case of no or failed endoscopic closure of an iatrogenic perforation, and in patients whose clinical condition is deteriorating, hospitalization and surgical consultation are recommended.

Because of the complexity of management of iatrogenic perforation, a multidisciplinary approach that includes the endoscopist, radiologist, and surgeon should be available. The follow-up of an iatrogenic perforation depends on both its type and site and the patient's clinical condition.

Hospitalization after an iatrogenic perforation is almost mandatory. Same-day discharge in an asymptomatic perforation successfully treated endoscopically may be considered in selected patients, although close follow-up should be adopted [44].

The conservative approach consists of intravenous antibiotics, nothing by mouth, hemodynamic monitoring, and close multidisciplinary follow-up [45]. Parenteral nutrition is recommended in undernourished patients or in well-nourished individuals who will not be able to be fed for ≥7 days [46]. If the conservative approach is failing and the patient's condition deteriorates (e.g. presenting with septic or peritonitis signs), surgery is strongly considered [47–49]. Moreover, in the case of unsuccessful endoscopic closure of the perforation, surgical management is strongly recommended [41]. Early surgery is generally to be preferred in patients with large perforations, generalized peritonitis, ongoing sepsis, or deteriorating clinical condition, or after failure of percutaneous drainage, or in the presence of an active leak or a significant amount of free fluid as seen at CT scan that cannot be drained percutaneously.

The type of surgical management of iatrogenic perforation (laparoscopy vs. open procedure) depends mainly on the location of the perforation and the surgeon's decision. Minimally invasive laparoscopic treatment of perforations has become the preferred surgical option for colonic iatrogenic perforation as it provides better outcomes than open surgery [4,50].

Esophageal perforations

RECOMMENDATION

ESGE suggests that endoscopic dilations, mucosal resection/submucosal dissection, septotomy for Zenker's diverticulum, and foreign body removal should be considered to carry increased risk of esophageal iatrogenic perforation.

A systematic review (52 studies, 2830 patients with esophageal perforations) concluded that iatrogenic causes were responsible for 46.5% of esophageal perforations [16]. Most esophageal iatrogenic perforations are associated with therapeutic endoscopic maneuvers and are localized in the thoracic part of the esophagus [51, 52]. Endoscopic procedures responsible for this adverse event include balloon dilation for esophageal stricture or achalasia, septotomy for Zenker's diverticulum, endoscopic resection (EMR or ESD), and removal of foreign bodies [52].

Iatrogenic perforation is the most frequently reported major complication of esophageal dilation [52]. The risk is low (0.09%–2.2%) for simple ring, peptic, or anastomotic strictures, and higher for complex (angulated, multiple, or long), caustic, radiation-induced, or malignant strictures: in a national database (591 187 hospitalizations for esophageal strictures, including 4.2% of malignant strictures), iatrogenic perforation was more common in malignant versus benign strictures (0.9% vs. 0.5%, $P=0.007$) [53]. Over-the-wire balloon and bougie dilations seem to be safer than blind dilation [54]. A systematic review (5 randomized controlled trials [RCTs], 461 patients with benign stricture) found no difference between balloon and bougie dilation in the incidence of iatrogenic perforation [55]. Finally, nonadherence to the “rule of three” did not appear to increase dilation-related iatrogenic perforation in two retrospective studies including a total of 461 patients [56]. In achalasia, the rate of perforation for pneumatic dilation has been reported to broadly range between 0.4% and 14%, and it seems lower if a 30-mm balloon is used first with an interval, stepwise approach [52, 57]. In a recent RCT, comparing balloon dilation ($n=66$) to POEM ($n=64$), only one patient in the balloon dilation group had an iatrogenic perforation [58].

For septotomy of Zenker's diverticulum, a meta-analysis (23 studies and 997 patients) showed an overall iatrogenic perforation rate of 5.3% [59]. For endoscopic resection, in the setting of early Barrett's and esophagogastric neoplasia, a meta-analysis including 16 studies with EMR and ESD (all ESD studies were performed in Japan) showed a similar perforation rate (1.2% for EMR vs. 1.5% for ESD) [60]. Regarding complete mucosal resection for Barrett's, another meta-analysis (8 studies) revealed a perforation rate of 2.3% [61]. A more recent RCT comparison of EMR and ESD reported a higher perforation risk with ESD (0% for EMR vs. 10% for ESD) [62]. Similar iatrogenic perforation rates (1.4%–2.4%) have been reported for ESD of squamous cell cancer, by Japanese authors [63, 64]. A retrospective cohort ($n=147$) identified mucosal deficiency larger than 75% of the circumference of the esophagus as an independent risk factor for intraoperative iatrogenic perforation during ESD (odds ratio [OR] 7.37, 95%CI 1.45–37.4, $P=0.016$) [65]. Finally, a systematic review concerning submucosal tunnelling endoscopic resection including 28 studies ($n=1041$), reported a pooled prevalence of iatrogenic perforation of 5.6% (95%CI 3.7%–8.2%) [66].

A meta-analysis including 1122 patients from 22 studies reported on adverse effects of POEM [67]. Capno-/pneumoperitoneum (30.6%), capno-/pneumothorax (11.0%) and subcuta-

neous emphysema (36.1%) were frequent; nevertheless, major adverse events such as mediastinal leakage requiring endoscopic or surgical treatment were rare (0.3%) [67]. A subsequent retrospective cohort that was focused exclusively on POEM-related adverse effects confirmed these results [68].

Finally, large, irregular, sharp foreign bodies, or foreign bodies impacted in the esophagus for a very long duration as well as a history of repeated intentional foreign body ingestion are all risk factors for esophageal perforation [69]. A retrospective study of 194 patients with foreign body impaction in the upper GI tract and removal showed an iatrogenic perforation rate of 1.5% [70].

RECOMMENDATION

ESGE suggests to diagnose delayed esophageal iatrogenic perforation based on patient history, physical examination, blood tests, and imaging using CT scan with orally administered water-soluble contrast. Delayed diagnosis and treatment, beyond 24 hours, may be related to increased morbidity and mortality.

Although an iatrogenic perforation is readily evident in most cases of endoscopy-related perforation, a high index of suspicion for iatrogenic perforation should be considered in patients who present shortly after a higher-risk GI endoscopy procedure. The early clinical presentation of esophageal iatrogenic perforation may be different according to the perforation site. If the perforation involves the cervical esophagus, clinical presentation is characterized by dysphagia, subcutaneous emphysema, odynophagia, or dysphonia; in the thoracic esophagus prevalent symptoms are chest pain, dyspnea, tachypnea, and subcutaneous emphysema; in the distal esophagus there may be retrosternal/epigastric pain, nausea, and vomiting, with signs of acute peritonitis. Conversely, symptoms of the late stage can be nonspecific (e.g. signs of systemic inflammation and sepsis), and often confused with other diseases. Delay of treatment may be associated with significant increase of morbidity and mortality [16].

Patient history, physical evaluation, blood tests, and imaging should be the first diagnostic approach for patients with a suspected esophageal perforation. If the patient is presenting with consistent and suspicious symptoms and signs of perforation, a CT scan with orally administered water-soluble contrast should immediately be considered; it is very specific and sensitive in diagnosing perforation, defining the anatomical site, and detecting subsequent collections of fluid and air in extra-esophageal organs and spaces [71].

Of note, after endoscopic procedures, especially esophageal ESD, limited gas bubbling out of the esophageal lumen may be detected in the absence of iatrogenic perforation, even though the routine use of CO₂ has reduced the risk of extraluminal gas detection [72, 73].

Endoscopy has a limited indication as a purely diagnostic test. Diagnostic endoscopy should be performed only in selected cases and with caution because it may increase the size of

the wall defect or spread contaminated fluids out from the esophagus. In general endoscopy is indicated when, according to the clinical situation, endoscopic therapy can be provided during the same procedure or before surgery after discussion with the surgeon [74].

Treatment: esophagus

RECOMMENDATION

ESGE recommends first-step endoscopic treatment for endoscopy-related esophageal iatrogenic perforation. TTS clips can be used for perforations <10 mm, and OTS clips are recommended for perforations >10 mm. Stents can be used for larger defects (>20 mm).

Conservative therapies include intravenous broad spectrum antibiotics, nil per mouth, nasogastric suction, pain control, and gastric acid suppression, as well as hemodynamic monitoring and support [45]. If collections are present, percutaneous drainage is suggested, and a sample of the fluid should be sent for bacteriological analysis [45]. A perforation located in the cervical esophagus has more likelihood for successful conservative management because of anatomical factors reducing the risk of contamination of the mediastinum [25, 75].

The main endoscopic management options for esophageal iatrogenic perforation include closure with clips, diversion of enteral contents with stents, or endoscopic vacuum therapy [30, 45].

A systematic review including all types of leaks (38 studies, 127 patients) identified 31/32 patients with esophageal iatrogenic perforation who underwent successful closure with TTS clips [32]. In a multicenter European cohort study, enrolling 36 consecutive cases of iatrogenic perforation, all of 5 esophageal perforations were successfully closed endoscopically, using a combination of OTS and TTS clips ($n=3$) or only OTS clips ($n=2$) to close the defect [38]. A similar multicenter cohort study ($n=188$) included 10 patients with esophageal iatrogenic perforation, all treated successfully with OTS clipping [33]. A large systematic review of patients all treated with OTS clipping ($n=1517$ cases; total GI perforations, $n=351$) concluded that the mean success rate when using OTS clips for treatment of perforation was 84.6% (297/351 cases) [37]. These results included perforations throughout the GI tract; nevertheless, iatrogenic perforation in the esophagus may be difficult to close because of the tubular esophageal anatomy [37, 76]. Hagel et al. concluded that defects located in the proximal and mid esophagus, greater than 20 mm in size, with ischemic or congested margins, or present for longer than 72 hours, were least amenable to OTS clip closure [76].

Temporary treatment with self-expandable metal stents (SEMSs) has also been proposed for the treatment of mid and lower esophageal iatrogenic perforation. Stents are deemed particularly useful for treatment of large defects and in cases of malignancy-associated perforation, where they also contribute to relieving dysphagia [77]. A large retrospective US cohort

study (2007–2014), using a commercial claims database of 659 patients with esophageal iatrogenic perforation or anastomotic leaks, observed a fourfold rise in the use of SEMSs over the 8-year period [78]. A systematic review (25 studies and 267 patients), including 66 patients (25%) with esophageal iatrogenic perforation, showed high technical (99%) and overall clinical (85%) success rates, without showing any differences between the fully covered SEMS (FCSEMS), partially covered SEMS (PCSEMS) and self-expandable plastic stent (SEPS) [79]. An additional meta-analysis (27 studies, 340 patients), including 88 patients with esophageal iatrogenic perforation confirmed these results [80]. Subsequent studies, including patients with iatrogenic perforation, anastomotic leaks, and fistulas, confirmed the role of stents in the management of these conditions, with clinical success rates ranging from 67.8% to 85% [77, 81–88]. Stent-related adverse effects include stent migration (with FCSEMS) and tissue ingrowth (with PCSEMS), requiring a stent-in-stent technique for definitive SEMS retrieval [81]. A retrospective cohort with calculation of a predictor rule identified patients with iatrogenic perforation as having a higher probability of obtaining successful treatment with SEMS, compared to those with fistulas [87]. Recently OTS clips have been used for esophageal stent fixation [89]. Caution is advised against the placement of a SEMS after insertion of an OTS clip as this may erode major vessels [90].

Endoscopic vacuum therapy (EVT) uses negative pressure to absorb secretions and promote wound healing by secondary intention [30]. A systematic review including 11 studies and 180 patients with esophageal leaks (28 with iatrogenic perforation) reported a healing rate of 91%, with mean healing times ranging from 11 to 29 days [91]. Furthermore, a recent meta-analysis, including 4 retrospective comparative studies in mostly patients with postoperative anastomotic leaks, revealed significantly higher healing rates with EVT compared to SEMS (pooled OR 5.51, 95%CI 2.11–14.88; $P<0.001$) [92]. Additionally, EVT had shorter treatment duration (pooled mean difference -9.0 days, 95%CI -16.6 to -1.4 ; $P=0.021$), and lower rates of major complication ($P=0.011$), and in-hospital mortality ($P=0.002$) compared to SEMS [92]. In fact, the estimate of whether an iatrogenic perforation has completely healed after stent placement is rather difficult to confirm and the exact period required for healing is still unknown. However, the time period of 4–6 weeks until removal of esophageal stents placed for treatment of iatrogenic perforation has been proposed, in order to achieve both adequate sealing of the defect and reduction of the complications associated with stent placement [81, 85, 93].

In a systematic review that compared SEMS insertion (371 patients) versus surgery (368 patients) for esophageal leaks, success/mortality rates were 88%/7.5% and 83%/17%, respectively [94]. These data should be interpreted with caution as no study was randomized or even comparative, implying a high risk of bias. In another systematic review including 2830 patients with esophageal leaks (1933 with iatrogenic perforation), nonsurgical and surgical management were performed in approximately one half of patients each, with an overall mortality rate of 13.3% [16]. Additional individual published cohorts disclose varying 30-day mortality rates, reflecting the

heterogeneity in the patient populations and therapeutic management [51, 95–100]. Nonsurgical management seemed to be related to a lower rate of morbidity [51,95]. A 12-year English multicenter retrospective study including 2564 patients with esophageal perforation (152 cases with iatrogenic perforation) revealed that high hospital case volume was associated with significant reductions in 30-day mortality (OR 0.68, $P=0.001$) and 90-day mortality (OR 0.69, $P=0.001$) [101].

Gastric perforations

RECOMMENDATION

ESGE suggests that endoscopic dilations and mucosal resection/submucosal dissection should be considered to carry increased risk for gastric iatrogenic perforation.

Iatrogenic gastric perforations are most often related to therapeutic procedures, including: gastroenteric anastomosis dilation (2%) [102]; overdistension during argon plasma coagulation or cryotherapy (<0.5%); standard snare polypectomy; EMR (0.5%); and, more frequently, ESD [103]. Additional risk factors during EMR and ESD are the presence of an ulcer or unhealthy (e.g. irradiated) tissues [104], age >80 years, large tumor size, location of the lesion in the thinner upper region, and long duration of the resection [103, 105, 106].

RECOMMENDATION

ESGE recommends endoscopic treatment for gastric iatrogenic perforation, using TTS clips for perforations ≤ 10 mm, and OTS clips or omental patching or the combined technique using endoloop and TTS clips for perforations >10 mm.

At the outset of endoscopic management, only TTS clips were available but their use seemed to be hazardous in the case of large perforations [107–112]. In such cases omental patching added to TTS clip closure seemed to be more effective and also extended the possibility of endoscopic closure for larger perforations [113, 114]. The OTS clip has become the most popular endoscopic tool for closing gastric perforations, giving the possibility of closing 30-mm diameter defects [36,38, 115–117]. Band ligation has been performed only in a very small series [118]. The nonsurgical treatment of gastric perforations may include removable FCSEMS or self-expanding plastic stents (SEPSs) only if the perforation occurred on the site of a stricture. These stents are indicated for perforations caused by dilation of a gastroenteric anastomosis, or of an anal stricture, or after cystogastrostomy [119].

When iatrogenic perforation is diagnosed during or within 24 hours of endoscopy, endoscopic closure has been associated with good patient outcome. If the perforation is recognized later than 24 hours the outcome of endoscopic management

could be worsened and surgery may be required, as shown in a large series after ESD [120].

A series including 38 patients with perforations initially treated nonsurgically showed that the majority of patients did not present with clinical signs of peritonitis nor require interventions beyond conservative management, whereas only 7 (18%) required surgery [121]. The only factors associated with failure of nonsurgical treatment were free fluid or contrast extravasation on CT scan (75% vs. 23%, $P<0.005$; and 33% vs. 0%, $P=0.047$; respectively). The morbidity in patients requiring surgery after initial nonsurgical management was equivalent to that observed in patients who underwent direct surgical management (63% vs. 61%, not significant). However, mortality appeared to be greater in those who underwent surgery after failed endoscopic treatment than in those who underwent initial surgical management (43% vs. 21%, $P=0.09$). Late recognition of gastric iatrogenic perforation with septic symptoms is generally associated with peritonitis due to leakage of intra-abdominal fluid. These patients generally require surgical management.

Endoscopic treatment for small gastric defects (≤ 10 mm)

In the case of iatrogenic perforations smaller than 10 mm (the opening width of TTS clips) with a linear shape, endoscopic clipping is an acceptable method and should be attempted [113]. Sometimes, clip placement may be difficult because of the location of the perforation. In such cases, the recently described band ligation technique could be an interesting alternative [118]. In the literature there are only a few publications on acute endoscopic iatrogenic perforation of the stomach, reporting a total of 145 patients treated with TTS clips [122]. In detail, 8 studies have been reported on acute iatrogenic perforations after EMR or ESD procedures and all were treated using TTS clips. Pooling these studies, the overall success rate of TTS clips was >99% (Table 1 s, available online-only in Supplementary Material). The limitation of 10 mm in the size of the defect could be reconsidered with both the improvement of TTS clips (jaw distance reaching 16 mm) and better knowledge of the closure of mucosal defects after POEM and EMR/ESD.

Endoscopic treatment for large gastric defects (> 10 mm)

In the case of defects measuring 10–30 mm, the OTS clipping system has been the most evaluated technique and has already demonstrated its efficacy in clinical studies for the management of postoperative leaks or fistulas [123–126]. Regarding acute gastric iatrogenic perforation, many relevant publications have highlighted the efficacy of OTS clips (Table 2 s) [36, 37, 115–117, 123–128] with an overall success rate of 88%. All these experimental and clinical studies recommend OTS clips for the management of gastric defects between 10 and 30 mm in diameter, with or without the use of grasping devices. In a single-center study assessing the role of OTS clips in 233 patients during routine endoscopic practice, the efficacy for closure of acute perforations was 90.3% (65/72 cases), with 24%

of them being gastric perforations [127]. An abovementioned review including 280 cases concluded that the overall efficacy of OTS clipping for iatrogenic perforation was 81% [36]. When the omentum is visible through the defect, the omental patch technique may be recommended [113, 114], especially if the defect is very large (**Table 3s**). In the case of OTS clipping unavailability, the combined technique using TTS clips plus endo-loop can be recommended [128, 129]. A recent review assessing the results for OTS clipping over 9 years in 1517 cases, found clinical success of 84.7% in 351 cases of iatrogenic perforation [37]. The efficacy for gastric perforation was restricted to defects of size <40mm, and OTS clip deployment was contraindicated in cases of stenosis. In some cases, the OTS clipping system was efficient in delayed-onset perforation [37]. The use of the new suturing devices must be restricted to expert centers and/or the setting of clinical trials.

Endoscopic management should be avoided in cases of diagnosis delayed >24 hours or of clinical features suggestive of infection. In cases of late recognition (nonintraoperatively), a CT scan should first be performed to search for peritoneal effusion. In cases of peritoneal effusion, surgical management is strongly recommended. If no peritoneal effusion could be demonstrated and if the patient does not present signs of infection, an attempt at endoscopic closure could be performed with a close follow-up.

Periampullary and biliopancreatic ductal perforation

RECOMMENDATION

ESGE suggests that endoscopic retrograde cholangiopancreatography (ERCP) in the setting of a papillary lesion, a dilated common bile duct, or sphincter of Oddi dysfunction, or when the ERCP involves sphincterotomy, precut sphincterotomy, or biliary stricture dilation, should be considered to carry increased risk for iatrogenic perforation.

ERCP may cause perforation in different locations, as recognized in the Stapfer classification which includes four categories of decreasing severity (**Table 4s**) [130]. A systematic survey of 21 prospective studies (16 855 patients) reported ERCP-related duodenal or biliary perforations in 0.60% of patients (95%CI 0.48%–0.72%) and a perforation-related mortality rate of 9.90% (95%CI 3.96%–15.84%) [131]. An identical perforation rate of 0.6% has been reported in a more recent systematic review (12 retrospective studies, 42 374 patients) [132].

Excluding Stapfer type I perforations, which are included in the next section (Duodenal and small-bowel perforation), the following risk factors for ERCP-related perforation have been identified in a retrospective study (33 perforations): sphincterotomy (OR 9.0, 95%CI 3.2–28.1), biliary stricture dilation (OR 7.2, 95%CI 1.84–28.11), dilated common bile duct (OR 4.07, 95%CI 1.63–10.18), sphincter of Oddi dysfunction (OR

3.8, 95%CI 1.4–11.0), and long procedure duration (OR 1.021, 95%CI 1.006–1.036) [133]. The presence of a papillary lesion necessitating endoscopic papillectomy (OR 18.0, $P<0.01$) and the performance of a precut (OR 3.0, $P=0.04$) were independent risk factors in another study (37 perforations) [134].

RECOMMENDATION

ESGE suggests nonsurgical management in the majority of ERCP-related periampullary or biliopancreatic ductal iatrogenic perforations. The indications for surgery include a major contrast medium leak, severe sepsis despite nonsurgical management, severe peritonitis, and fluid collections or unsolved problems (e.g., retained hardware) that cannot be solved by nonsurgical means.

A majority of patients with ERCP-related perforations can be managed nonsurgically but they need to be carefully selected, therefore a therapeutic algorithm is proposed according to the Stapfer type of the perforation (**Fig. 1s**).

Stapfer type II perforations communicate with the retroperitoneal space which is more contained than the intra-abdominal space. When a Stapfer type II perforation is identified during ERCP, the endoscopist should attempt to cover the perforation and to direct away the bile flow from the perforation site by providing endoscopic biliary drainage [135]. The two relatively large studies that have compared nasobiliary drainage versus FCSEMS insertion have reported better results with FCSEMS in terms of pain ($P=0.005$), length of hospital stay ($P=0.053$) and absence of retroperitoneal abscess formation ($P=0.018$) [135, 136] (**Table 5s**). Emergency surgery is indicated only in rare cases where a major contrast leakage is insufficiently sealed. Patients with a delay in the detection of a Stapfer type II perforation who were clinically stable have successfully undergone repeat ERCP to insert a biliary stent [137–140]. Persisting retroperitoneal fluid collections that might occur in these patients can be treated with percutaneous drains [21, 141]. In addition, endoscopic ultrasound (EUS)-guided drainage of bilomas might be an attractive alternative that enables internal drainage [142]. **Table 6s** shows that 5% of patients undergo primary surgery, and that 11% of the patients initially managed nonsurgically eventually need surgery. Patients who require salvage surgery present a worse prognosis with a mortality rate of 38% [143].

Stapfer type III perforations should initially be managed conservatively as nonsurgical management is successful in 95% of patients (**Table 7s**). These perforations can be difficult to detect but if a substantial extravasation of contrast medium from the biliary or pancreatic duct is detected during ERCP, decompression of the perforated duct using an FCSEMS or a plastic stent should be considered [130, 144, 145]. Stapfer type III perforations have a good prognosis [143].

Treatment measures

Local treatment aims to close the perforation (Stapfer types I and II) and/or to divert bile from the perforation (Stapfer types II and III), awaiting spontaneous wound healing.

- TTS clips may be used for Stapfer types I and II perforations; limitations relate to the size of the defect, its location that may require a tangential approach, and the duodenoscope elevator that may hinder the deployment of TTS clips. To help resolve these issues, multiple TTS clips may be used, possibly delivered using a cap-fitted endoscope with an axial view [146]; duodenoscope-friendly TTS clips are another option currently under evaluation [147]. Another option for large defects is to combine TTS clips with endoloops according to different techniques, using a single-channel [148] or double-channel endoscope [149].
- Temporary biliary drainage has been used to divert bile from the perforation (Stapfer types II and III perforations), by means of plastic stents, FCSEMS, and nasobiliary drains. For type II perforation, this can be used alone or combined with perforation closure.

Regional treatment consists in draining collections. This can be performed through percutaneous access or during surgery, which also allows evacuation of debris. More recently EUS-guided drainage has also been proposed [150].

General measures include hospital admission and administration of broad spectrum antibiotics. The majority of patients reported in the literature were treated with a nil-per-mouth strategy that was regularly combined with a nasogastric or nasoduodenal tube (with suction) and proton pump inhibitors (PPIs), aiming to minimize the fluid load upon the perforation site. No available studies have addressed the benefit of gastric/duodenal tube suction and PPIs as compared to a nil-per-mouth strategy, so that such a treatment regimen is advised on the basis of theoretical considerations. If the perforation has been successfully closed by means of endoscopy or surgery, oral intake can be reinitiated. Parenteral nutrition has been advised for patients expected to be without enteral intake for long periods or who are severely malnourished [46].

If endoscopic treatment of the iatrogenic perforation is likely to have been successful, it may be important to complete the intended procedure [151]. Patients in whom the primary procedure is not completed may have a worse clinical course and increased mortality mainly due to uncontrolled cholangitis [152].

When primary endoscopic closure has been successful, regardless of the type of perforation, approximately 90% of patients recover without the need for surgery (Tables 5s–7s). However, publication biases towards positive outcomes probably contribute to an unduly favorable estimate.

General indications that warrant surgery include major contrast medium leak, unsolved problems (e. g. perforation during endoscopic treatment of an ampullary tumor) [134], severe peritonitis, severe sepsis despite nonsurgical management, or retroperitoneal fluid collections not amenable to percutaneous

or EUS-guided drainage [1, 48, 153–156]. Clinical signs such as fever, tachycardia, guarding, or leukocytosis are suggestive that conservative measures are failing and emergency surgery is indicated [47–49]. Nevertheless, the clinical condition of the patient might deteriorate only when full-blown peritonitis has already developed. This means that relying on clinical condition may lead to delayed surgery, which has been associated with increased morbidity and mortality [157, 158].

Surgical options include primary repair of the defect, abdominal washout, drain placement, and duodenal diversion [132]. No prospective comparative studies between surgical approaches are available, and the most suitable technique depends on the size and location of the defect and the time from perforation to surgery, as well as the underlying condition and current clinical condition of the patient; this implies that a case-by-case strategy to determine operative modality should be adopted.

Duodenal and small-bowel iatrogenic perforation

RECOMMENDATION

ESGE suggests that risk factors for nonperiampullary duodenal iatrogenic perforation include ERCP in patients with Billroth II reconstruction, EMR, and particularly ESD. Risk factors for jejunoileal iatrogenic perforation related to enteroscopy include stricture dilation or patients having altered anatomy or having inflammatory bowel disease being treated with steroids.

Duodenal perforations

At ERCP, duodenal perforations caused by the duodenoscope are classified as type I according to Stapfer et al. [130]). A recent systematic review of ERCP-related iatrogenic perforations found that type I was the second most frequent type (overall incidence of 0.12%, with 54 perforations in a total of 305 perforations among 42 374 procedures [0.7%]) [132]. Billroth II resection and a procedure described as “difficult” are the main risk factors for duodenal perforation during ERCP [134, 159–161]. In a retrospective series of 165 patients with a Billroth II gastrectomy, 1.8% of patients experienced the adverse event of perforation [162]. A more recent retrospective study showed that, in patients with Billroth II reconstruction, loop-shaped insertion of the endoscope is a risk factor for perforation ($P=0.01$) [163].

Duodenal EMR and ESD may cause duodenal perforation. In a meta-analysis (7 studies, 203 patients), duodenal ESD was associated with intraoperative and delayed perforation in 15% and 2% of the patients, respectively [164]. This is remarkably higher than for ESD performed in the stomach or the colon [165]. Duodenal ESD carries a higher risk of perforation than duodenal EMR (16.2% vs. 2.3% in a recent series of 150 patients, $P=0.001$) [166], but ESD is performed only for specific

indications, and novel techniques are being developed to decrease this risk [167]. The relatively high risk of delayed perforation is probably due to the thinness of the duodenal wall, coupled with proteolysis or chemical irritation by pancreatic enzymes and bile juice. Overall, EMR seems to be safer than ESD in the duodenum [168, 169].

Jejunal and ileal perforations

In obese patients with a Roux-en-Y gastric bypass, the dilation of gastrojejunal anastomotic strictures has been reported to be associated with perforation in 1.6%–10% of patients [170–174].

Small-bowel perforation during enteroscopy has been reported for all techniques. With respect to double-balloon enteroscopy (DBE), a perforation incidence of 0.1%–0.4% has been reported in three studies with a total of >33 000 procedures; factors associated with perforation included polypectomy, altered surgical anatomy, and patients' having inflammatory bowel disease (IBD) that was being treated with steroids [175–177]. Fewer data are available for single-balloon enteroscopy, but perforation has been reported that was associated with dilation of a radiation stricture [178] and with altered surgical anatomy [179]. With respect to spiral enteroscopy, perforation has been reported in 0.34% of 1750 patients in a prospective study [180]; it has been associated with low operator experience [180] and surgically altered anatomy [181, 182]. Finally, there have been case reports on capsule endoscopy in patients with obstructive small-bowel cancer or Crohn's disease leading to retention and perforation [183–186].

Mortality rates for duodenal and jejunal/ileal iatrogenic perforations

Iatrogenic duodenal perforation has been a feared complication with a high mortality rate compared to jejunal/ileal iatrogenic perforation. Avgerinos et al. [157] found in a retrospective review of 15 cases of duodenal iatrogenic perforation that mortality dramatically increases with late (>24 hours) surgical management. The overall mortality rate was 20% and similar high mortality rates have been reported in several cohorts (**Table 8s**). However, there is a clear tendency for a shorter hospital stay in the cohorts treated endoscopically [146, 187–190]. The difference between mortality rates after iatrogenic perforation in the duodenum and in the jejunum/ileum is probably explained by differences in surgical procedures combined with a greater systemic response to leak of duodenal contents.

Treatment: small bowel

RECOMMENDATION

ESGE recommends endoscopic treatment of duodenal iatrogenic perforation if this is recognized immediately or early (<12 hours) after the procedure. In the case of failed endoscopic treatment, the patient requires immediate surgery. If the duodenal iatrogenic perforation is diagnosed late (>12 hours), management should be surgical in the case of contrast medium extravasation at CT scan and/or deterioration of the patient's condition. If the patient is clinically well, without contrast medium extravasation, the patient may be treated conservatively.

RECOMMENDATION

ESGE suggests that jejunal and ileal iatrogenic perforation should be treated endoscopically when recognized immediately, and surgically in the case of failed endoscopic closure or postprocedural recognition of perforation with intraperitoneal leak of air and fluids.

Nonperiampullary duodenal perforations: treatment

Stapfer type I perforations are detected during the procedure in the majority of cases (**Table 8s**). Recently, successful endoscopic closure techniques in an increasing proportion of cases have decreased the need for emergency surgery. If the defect cannot be sealed or if the patient deteriorates with a standing endoscopic closure, then emergency surgical repair is indicated. If the iatrogenic perforation is diagnosed several hours after the endoscopy and the patient shows symptoms of generalized peritonitis and/or sepsis, the only option is surgery [132]. Percutaneous drainage of collections with no major contrast leak or solid debris is a reasonable alternative for patients in whom endoscopic closure was not possible and who are considered unfit for surgery [21, 191].

The surgical approach depends on the intraoperative findings. However, the morbidity and mortality of surgical repair is high (**Table 8s**) and therefore immediate endoscopic closure should be the first choice for treatment.

Techniques for endoscopic closure

Clips have been used to close Stapfer type I perforations in the majority of cases (**Table 8s**). For large perforations, a combination of an endoloop and TTS clips can enable successful closure [149, 190], although TTS clips alone may be sufficient [189, 192]. Recently, OTS clips have been used for perforations of up to 20 mm in diameter, using two clips in some cases [193–199]. In a retrospective series, the introduction of the use of OTS clipping at one center was followed by a reduction in surgery for gastrointestinal iatrogenic perforation from 62.5% to 12.5% [200]. The use of covered and semi-covered SEMs is currently evolving as a treatment option in upper GI perfora-

tions [201] and could be a possible tool in the future management of iatrogenic perforation. The increased feasibility of endoscopic closure of Stapfer type I perforations accounts for some of the changes in management algorithms recommended for ERCP-related perforations [144]. However, the real-world success of endoscopic closure is difficult to estimate because of publication bias.

Jejunal and ileal perforations: treatment

In the jejunum and ileum, endoscopic closure is only an option if the perforation is recognized immediately [192, 198], as endoscopic reintervention can entail renewed risk and it may be difficult to locate the site of perforation. If endoscopic closure fails, ink-marking the site of perforation should be considered in order to facilitate the subsequent surgical procedure. Surgical treatment of iatrogenic perforation in the jejunum and ileum requires primary suture of the perforation or a small resection and primary anastomosis.

Colorectal iatrogenic perforations

RECOMMENDATION

ESGE suggests that complex EMR, ESD and balloon dilation procedures should be considered to carry increased risk of colorectal iatrogenic perforation. Older age, comorbidity, inflammatory colonic disease, and endoscopist inexperience are other significant risk factors for iatrogenic perforation at colonoscopy.

Risk factors include female gender (presumably related to pelvic adhesions), major comorbidities, and older age (associated with weakened colonic wall tissues) [202–206]. Risk may also be increased in patients with IBD. In one case–control study, the rate of perforation was 18.91 per 10 000 and 2.50 per 10 000 procedures for IBD and non-IBD endoscopy, respectively [207]. Patients with IBD taking systemic corticosteroids were at a higher risk of perforation-associated complications [207]. Colonoscopic surveillance however, for long-standing extensive ulcerative colitis has proved to be safe with no significant complications when biopsies are obtained with caution [208]. The risk of iatrogenic perforation appears to be operator-dependent; non-gastroenterologist endoscopists and endoscopists performing at volumes in the lowest quintile (<141 procedures annually, median 63) being associated with an increased risk [204, 209]. The use of anesthesia assistance to achieve deep sedation with propofol during colonoscopy has previously been associated with increased risk of iatrogenic perforation, with one study reporting the risk to be 26% higher among those undergoing polypectomy with no such association in nonpolypectomy cases [210]. In a more recent large population-based cohort study, use of propofol was not associated with a significantly increased risk of perforation [211].

The sigmoid colon and the rectosigmoid junction are the most common sites of iatrogenic perforation during a diagnostic procedure, because of direct mechanical injury via shearing forces applied by the shaft or tip of the colonoscope during insertion [19, 212, 213]. Pericolonic adhesions (from previous gynecological surgery or abdominal inflammation) and severe diverticular disease may increase the risk of perforation, particularly when large-caliber instruments and excessive force are used [214, 215]. Traumatic antimesenteric tears of the colonic wall are less common elsewhere but can occur at the flexures because of excessive tip force or in the rectum during retroflexion [216]. Cecal perforation can also occur because of barotrauma, particularly if gas is introduced above an area of stenosis [217]; barotrauma is probably less likely when CO₂ is used compared to air, as the former is absorbed more quickly [40].

Iatrogenic perforation has been reported in 0.03%–0.8% of diagnostic colonoscopies and flexible sigmoidoscopies, in both the symptomatic and screening settings [215, 218–220]. Therapeutic colonoscopy, carries a small but significant risk of iatrogenic perforation, particularly following advanced polypectomy. However, high risk procedures such as endoscopic balloon dilation, applied to treat Crohn's strictures, may be associated with iatrogenic perforation rates up to 3% [221, 222]. Iatrogenic perforation is related to colonic stent placement [223]. The perforation risk in colorectal stenting has been reported as 7.4% in one meta-analysis [224]. Most perforations occurred in the first week after stent placement. Stent design, benign etiology, and concomitant bevacizumab therapy were identified as risk factors [224]. The British Society of Gastroenterology (BSG) audit of colonoscopy demonstrated that the risk of perforation at diagnostic examinations was 1:923 compared with 1:460 following polypectomy [225]. The largest prospective study, the Munich Polypectomy Study, reported a risk of 1.1% for colorectal perforation from 3976 snare polypectomies. Major complications were more common where polyps were over 20 mm in size or located in the right colon. Most perforation events were delayed [226].

There is substantial heterogeneity among studies reporting iatrogenic perforation rate after EMR, because of differences in perforation definition, polyp size, polyp morphology, and center experience. Two recent meta-analyses report pooled rates of 0.9% and 1.1% [227, 228]. The perforation rate for colorectal ESD is higher, ranging from 4% to 10%, with lower complication rates reported from high volume centers [165, 227, 228]. Predictive risk factors include endoscopist experience (<50 ESDs), tumor size, and presence of submucosal fibrosis [229, 230]. Abdominal CT is the most sensitive examination for detecting gas or liquid leaks [24]; water-soluble contrast enema per rectum is seldom used to detect concealed perforation.

Treatment: colorectum

RECOMMENDATION

ESGE recommends the use of TTS clips for iatrogenic perforation <10 mm and consideration of the use of the OTS clip for defects >10 mm. Adequate colon preparation is an important factor when contemplating endoscopic treatment of iatrogenic perforation. All patients treated conservatively should be watched closely by a multidisciplinary team in the post-procedure period. Larger iatrogenic perforations or patients with failed closure or deteriorating clinical condition may require immediate surgical repair.

Air or gas entry into the peritoneal cavity is a hallmark of iatrogenic perforation but does not necessarily cause infective peritonitis unless leakage of luminal contents occurs. Urgent endoscopic intervention with clip placement and the use of CO₂ may limit the volume of extraluminal insufflation and subsequently the need for surgery [231, 232].

When there is no evidence of intraperitoneal contamination by fecal contents, free air may either resolve spontaneously within a week or progress to compartment syndrome [233]. In the latter case, a tension pneumoperitoneum develops that requires an immediate release of trapped intraperitoneal air. On the other hand, if fecal contents are present then the optimal management is surgery.

The decision to attempt endoscopic closure of an iatrogenic perforation depends on multiple factors including the size and the cause of the perforation, the endoscopist's experience, and the accessories available at the time. With immediate endoscopic closure of the defect, superficial apposition of the mucosa and submucosal layers seems sufficient to obtain adequate wound healing at the perforation site and to achieve a good nonsurgical outcome [234]. In the largest retrospective observational case series in Europe describing post-perforation outcomes, endoclips were successfully used to close perforations in 83.3% of cases where the perforation was visualized by the endoscopist [215].

The recognition of colorectal wall tears may be immediate at the time of the procedure or can be delayed for up to 3 days [17, 18]. After all endoscopic resections, careful inspection of the mucosal defect should be performed. The Sydney deep mural injury (DMI) classification, derived from outcomes of 911 lesions ≥ 20 mm treated by EMR, describes the full breadth of bowel wall injury, ranging from muscularis propria exposure to full-thickness transection and observed contamination (**Table 9s**) [235].

The risk of perforation following a type 1 DMI is thought to be low and prophylactic treatment with clips is generally not required. Clip placement in cases of type 2 injury is recommended to reduce the risk of delayed perforation. The "target sign" is an easily recognized endoscopic sign of partial- or full-thickness muscularis propria resection (DMI types 3, 4, and 5)

during the post-polypectomy examination of the resected polyp specimen. This is characterized by a white to grey circle of resected muscularis propria on the transected undersurface of the specimen surrounded by blue-stained submucosa from the injection solution [236]. In one study of 445 patients with polyps >20 mm, all ten patients with histologically confirmed muscularis propria resection were identified intraprocedurally by a target sign and were satisfactorily treated with TTS clips with no requirement for subsequent surgery [44]. Type 4 and 5 DMIs correspond to complete transection of the muscle layer and should be closed to avoid extension of the injury or extraluminal fecal contamination.

In some circumstances, it may be appropriate to complete polyp resection adjacent to the perforation prior to clip application, particularly if the defect is small and bowel preparation good. Clearance of polyp close to the perforation may assist apposition of the muscle layer. During TTS clip closure, luminal gas insufflation should be minimized to reduce wall tension and the defect should be orientated to the antigravity position to reduce the risk of peritoneal contamination whilst maintaining adequate visualization. It may be helpful to place a tattoo at a safe distance from the perforation, whether closed or not, to aid location of the site should subsequent surgery be required.

Early endoscopic closure of an iatrogenic perforation smaller than 20 mm using either TTS or OTS clips is likely to be effective, with overall technical and clinical success rates, respectively, of 93% and 89% [38, 237, 238]. Electrocautery injury may induce colorectal perforations which are amenable to both TTS and OTS clipping, in particular during ESD where there is a high risk of microperforation [125, 239]. It has been reported that TTS clipping is more effective for closure of therapeutic perforations that are less than 10 mm than for diagnostic perforations, where defects have an irregular edge and may be larger in size [240, 241].

Recent systematic reviews based mainly on case series, report that the OTS clipping system is also a safe, easy to handle, and efficacious method to treat both diagnostic and therapeutic colorectal perforations [242–244]. Band ligation has been reported as a salvage therapy after failed clipping [245]. In one small study, a novel purse-string suture technique was successfully used to close perforations developed during diagnostic colonoscopy, using a dual-channel endoscope with an end-loop and clips, without complications or subsequent surgery [246]. Endoscopic closure of perforations using suturing devices may also be effective, with promising results in a small retrospective study, but requires endoscope exchange and reinsertion, thereby risking extraluminal contamination [247].

Occasionally, a perforation is diagnosed post-procedurally and if preparation is still adequate (within 4 hours after the procedure) endoscopic therapy may also be considered (**Fig. 2s**). Concomitant administration of intravenous fluids, broad spectrum antibiotics, and close monitoring of vital signs are always recommended in each suspected or diagnosed colorectal perforation, to prevent and monitor possible clinical deterioration.

A clear indication for surgery is a complicated or failed endoscopic closure with an ongoing leak that causes feculent peritonitis [248]. Minimally invasive laparoscopic treatment of

perforations has become the preferred surgical option and is now widely accepted and practiced [50]. Preliminary data demonstrated that the laparoscopic approach resulted in decreased morbidity and length of hospital stay as well as reduced abdominal wall scarring [249].

Disclaimer

ESGE position statements represent a consensus of best practice based on the available evidence at the time of preparation. They may not apply to all situations and should be interpreted in the setting of specific clinical situations and resource availability. They are intended to be an educational tool to provide information that may support endoscopists in providing care to patients. They are not rules and should not be utilized to establish a legal standard of care.

Acknowledgments

The authors are grateful to Professor Lars Aabakken, GI Endoscopy Unit, OUS, Rikshospitalet University Hospital, Oslo, Norway, and Dr. Cesare Hassan, Digestive Endoscopy Unit, Nuovo Regina Margherita Hospital, Rome, Italy, for their critical review of the Position Statement.

They are also grateful for the comments from Professor Stanislas Chaussade, Société Française d'Endoscopie Digestive; Professor Fredrik Swahn, Scandinavian Association of Gastrointestinal Endoscopy; and Dr. Gertjan Rasschaert, UMC Sint-Pieter, Brussels, Belgium.

Competing interests

M. Barthet's department has received a research grant from Boston Scientific. G. Paspatis has received consultancy fees from Boston Scientific (2019). A. Repici has received consultancy fees from Boston Scientific (2019–2020); his department has received a research grant from Boston Scientific (2018–2020). B. Saunders' department has received a research grant and loan of equipment from Olympus (2019 to present). J.E. van Hooft has received lecture fees from Medtronic (2014–2015, 2019) and Cook Medical (2019), and consultancy fees from Boston Scientific (2014–2017); her department has received research grants from Cook Medical (2014–2018) and Abbott (2014–2017). M. Arvanitakis, A. Dhillon, J.M. Dumonceau, M. Fragaki, J.M. Gonzalez, S.Y. Turino, and R.L.J. van Wanrooij have no competing interests.

References

- [1] Paspatis GA, Dumonceau JM, Barthet M et al. Diagnosis and management of iatrogenic endoscopic perforations: European Society of Gastrointestinal Endoscopy (ESGE) Position Statement. *Endoscopy* 2014; 46: 693–711
- [2] Akobeng AK. Principles of evidence based medicine. *Arch Dis Child* 2005; 90: 837–840
- [3] Dumonceau JM, Hassan C, Riphaus A et al. European Society of Gastrointestinal Endoscopy (ESGE) Guideline Development Policy. *Endoscopy* 2012; 44: 626–629
- [4] Martinez-Perez A, de'Angelis N, Brunetti F et al. Laparoscopic vs. open surgery for the treatment of iatrogenic colonoscopic perforations: a systematic review and meta-analysis. *World J Emerg Surg* 2017; 12: 8
- [5] Polydorou A, Vezakis A, Fragulidis G et al. A tailored approach to the management of perforations following endoscopic retrograde cholangiopancreatography and sphincterotomy. *J Gastrointest Surg* 2011; 15: 2211–2217
- [6] Kaminski MF, Thomas-Gibson S, Bugajski M et al. Performance measures for lower gastrointestinal endoscopy: a European Society of Gastrointestinal Endoscopy (ESGE) Quality Improvement Initiative. *United European Gastroenterol J* 2017; 5: 309–334
- [7] Bisschops R, Areia M, Coron E et al. Performance measures for upper gastrointestinal endoscopy: A European Society of Gastrointestinal Endoscopy Quality Improvement Initiative. *United European Gastroenterol J* 2016; 4: 629–656
- [8] Toyonaga T, Man-i M, East JE et al. 1,635 Endoscopic submucosal dissection cases in the esophagus, stomach, and colorectum: complication rates and long-term outcomes. *Surg Endosc* 2013; 27: 1000–1008
- [9] Paspatis GA, Konstantinidis K, Tribonias G et al. Sixty- versus thirty-seconds papillary balloon dilation after sphincterotomy for the treatment of large bile duct stones: a randomized controlled trial. *Dig Liver Dis* 2013; 45: 301–304
- [10] Mangiavillano B, Caruso A, Manta R et al. Over-the-scope clips in the treatment of gastrointestinal tract iatrogenic perforation: A multicenter retrospective study and a classification of gastrointestinal tract perforations. *World J Gastrointest Surg* 2016; 8: 315–320
- [11] Jayanna M, Burgess NG, Singh R et al. Cost analysis of endoscopic mucosal resection vs surgery for large laterally spreading colorectal lesions. *Clin Gastroenterol Hepatol* 2016; 14: 271–278. e271-272
- [12] Cotton PB, Eisen GM, Aabakken L et al. A lexicon for endoscopic adverse events: report of an ASGE workshop. *Gastrointest Endosc* 2010; 71: 446–454
- [13] Raju GS, Saito Y, Matsuda T et al. Endoscopic management of colonoscopic perforations (with videos). *Gastrointest Endosc* 2011; 74: 1380–1388
- [14] Baron TH, Wong Kee Song LM et al. A comprehensive approach to the management of acute endoscopic perforations (with videos). *Gastrointest Endosc* 2012; 76: 838–859
- [15] Jin YJ, Jeong S, Kim JH et al. Clinical course and proposed treatment strategy for ERCP-related duodenal perforation: a multicenter analysis. *Endoscopy* 2013; 45: 806–812
- [16] Sdralis EIK, Petousis S, Rashid F et al. Epidemiology, diagnosis, and management of esophageal perforations: systematic review. *Dis Esophagus* 2017; 30: 1–6
- [17] Iqbal CW, Cullinane DC, Schiller HJ et al. Surgical management and outcomes of 165 colonoscopic perforations from a single institution. *Arch Surg* 2008; 143: 701–706; discussion 706-707
- [18] Ignjatovic A, Saunders BP. A clinical case of delayed caecal perforation. *Gut* 2009; 58: 1170–; author reply 1170-1171
- [19] Paspatis GA, Vardas E, Theodoropoulou A et al. Complications of colonoscopy in a large public county hospital in Greece. A 10-year study. *Dig Liver Dis* 2008; 40: 951–957
- [20] Carr-Locke DL. The changing management of colonoscopy-associated perforations. *Digestion* 2008; 78: 216–217
- [21] McCarthy CJ, Butros SR, Dawson SL et al. Image-guided percutaneous management of duodenal perforation following endoscopic retrograde cholangiopancreatography (ERCP): assessment of efficacy and safety. *Clin Radiol* 2018; 73: 319 e319–319 e315
- [22] Kim DH, Pickhardt PJ, Taylor AJ et al. Imaging evaluation of complications at optical colonoscopy. *Curr Probl Diagn Radiol* 2008; 37: 165–177

- [23] Furukawa A, Sakoda M, Yamasaki M et al. Gastrointestinal tract perforation: CT diagnosis of presence, site, and cause. *Abdom Imaging* 2005; 30: 524–534
- [24] Zissin R, Hertz M, Osadchy A et al. Abdominal CT findings in nontraumatic colorectal perforation. *Eur J Radiol* 2008; 65: 125–132
- [25] Carrott PW Jr, Low DE. Advances in the management of esophageal perforation. *Thorac Surg Clin* 2011; 21: 541–555
- [26] Tamiya Y, Nakahara K, Kominato K et al. Pneumomediastinum is a frequent but minor complication during esophageal endoscopic submucosal dissection. *Endoscopy* 2010; 42: 8–14
- [27] Raju GS, Fritscher-Ravens A, Rothstein RI et al. Endoscopic closure of colon perforation compared to surgery in a porcine model: a randomized controlled trial (with videos). *Gastrointest Endosc* 2008; 68: 324–332
- [28] Fritscher-Ravens A, Hampe J, Grange P et al. Clip closure versus endoscopic suturing versus thoracoscopic repair of an iatrogenic esophageal perforation: a randomized, comparative, long-term survival study in a porcine model (with videos). *Gastrointest Endosc* 2010; 72: 1020–1026
- [29] Schmidt A, Fuchs KH, Caca K et al. The endoscopic treatment of iatrogenic gastrointestinal perforation. *Dtsch Arztebl Int* 2016; 113: 121–128
- [30] Stavropoulos SN, Modayil R, Friedel D. Closing perforations and post-perforation management in endoscopy: esophagus and stomach. *Gastrointest Endosc Clin N Am* 2015; 25: 29–45
- [31] Daram SR, Tang SJ, Wu R et al. Benchtop testing and comparisons among three types of through-the-scope endoscopic clipping devices. *Surg Endosc* 2013; 27: 1521–1529
- [32] Lazar G, Paszt A, Man E. Role of endoscopic clipping in the treatment of oesophageal perforations. *World J Gastrointest Endosc* 2016; 8: 13–22
- [33] Haito-Chavez Y, Law JK, Kratt T et al. International multicenter experience with an over-the-scope clipping device for endoscopic management of GI defects (with video). *Gastrointest Endosc* 2014; 80: 610–622
- [34] Belfiori V, Antonini F, Deminicus S et al. Successful closure of anastomotic dehiscence after colon–rectal cancer resection using the Apollo overstitch suturing system. *Endoscopy* 2017; 49: 823–824
- [35] Modayil R, Friedel D, Stavropoulos SN. Endoscopic suture repair of a large mucosal perforation during peroral endoscopic myotomy for treatment of achalasia. *Gastrointest Endosc* 2014; 80: 1169–1170
- [36] Iabichino G, Eusebi LH, Palamara MA et al. Performance of the over-the-scope clip system in the endoscopic closure of iatrogenic gastrointestinal perforations and post-surgical leaks and fistulas. *Minerva Gastroenterol Dietol* 2018; 64: 75–83
- [37] Kobara H, Mori H, Nishiyama N et al. Over-the-scope clip system: A review of 1517 cases over 9 years. *J Gastroenterol Hepatol* 2019; 34: 22–30
- [38] Voermans RP, Le Moine O, von Renteln D et al. Efficacy of endoscopic closure of acute perforations of the gastrointestinal tract. *Clin Gastroenterol Hepatol* 2012; 10: 603–608
- [39] Lin BW, Thanassi W. Tension pneumoperitoneum. *J Emerg Med* 2010; 38: 57–59
- [40] Lo SK, Fujii-Lau LL, Enestvedt BK et al. The use of carbon dioxide in gastrointestinal endoscopy. *Gastrointest Endosc* 2016; 83: 857–865
- [41] Kim SY, Chung JW, Kim JH et al. Carbon dioxide insufflation during endoscopic resection of large colorectal polyps can reduce post-procedure abdominal pain: A prospective, double-blind, randomized controlled trial. *United European Gastroenterol J* 2018; 6: 1089–1098
- [42] Baniya R, Upadhaya S, Khan J et al. Carbon dioxide versus air insufflation in gastric endoscopic submucosal dissection: a systematic review and meta-analysis of randomized controlled trials. *Clin Endosc* 2017; 50: 464–472
- [43] Li X, Dong H, Zhang Y et al. CO₂ insufflation versus air insufflation for endoscopic submucosal dissection: A meta-analysis of randomized controlled trials. *PLoS One* 2017; 12: e0177909 doi:10.1371/journal.pone.0177909
- [44] Swan MP, Bourke MJ, Moss A et al. The target sign: an endoscopic marker for the resection of the muscularis propria and potential perforation during colonic endoscopic mucosal resection. *Gastrointest Endosc* 2011; 73: 79–85
- [45] Di Leo M, Maselli R, Ferrara EC et al. Endoscopic management of benign esophageal ruptures and leaks. *Curr Treat Options Gastroenterol* 2017; 15: 268–284
- [46] Weimann A, Braga M, Carli F et al. ESPEN guideline: Clinical nutrition in surgery. *Clin Nutr* 2017; 36: 623–650
- [47] Knudson K, Raeburn CD, McIntyre RC Jr. et al. Management of duodenal and pancreaticobiliary perforations associated with periampullary endoscopic procedures. *Am J Surg* 2008; 196: 975–981; discussion 981–972
- [48] Alfieri S, Rosa F, Cina C et al. Management of duodeno-pancreatobiliary perforations after ERCP: outcomes from an Italian tertiary referral center. *Surg Endosc* 2013; 27: 2005–2012
- [49] Enns R, Branch MS. Management of esophageal perforation after therapeutic upper gastrointestinal endoscopy. *Gastrointest Endosc* 1998; 47: 318–320
- [50] Pilgrim CH, Nottle PD. Laparoscopic repair of iatrogenic colonic perforation. *Surg Laparosc Endosc Percutan Tech* 2007; 17: 215–217
- [51] Soreide JA, Konradsson A, Sandvik OM et al. Esophageal perforation: clinical patterns and outcomes from a patient cohort of Western Norway. *Dig Surg* 2012; 29: 494–502
- [52] Ben-Menachem T, Decker GA, Early DS et al. Adverse events of upper GI endoscopy. *Gastrointest Endosc* 2012; 76: 707–718
- [53] Goyal A, Chatterjee K, Yadlapati S et al. Health-care utilization and complications of endoscopic esophageal dilation in a national population. *Clin Endosc* 2017; 50: 366–371
- [54] Hernandez LV, Jacobson JW, Harris MS. Comparison among the perforation rates of Maloney, balloon, and Savary dilation of esophageal strictures. *Gastrointest Endosc* 2000; 51: 460–462
- [55] Josino IR, Madruga-Neto AC, Ribeiro IB et al. Endoscopic dilation with bougies versus balloon dilation in esophageal benign strictures: systematic review and meta-analysis. *Gastroenterol Res Pract* 2018; 2018: 5874870
- [56] Grooteman KV, Wong Kee Song LM et al. Non-adherence to the rule of 3 does not increase the risk of adverse events in esophageal dilation. *Gastrointest Endosc* 2017; 85: 332–337. e331
- [57] Campos GM, Vittinghoff E, Rabl C et al. Endoscopic and surgical treatments for achalasia: a systematic review and meta-analysis. *Ann Surg* 2009; 249: 45–57
- [58] Ponds FA, Fockens P, Lei A et al. Effect of peroral endoscopic myotomy vs pneumatic dilation on symptom severity and treatment outcomes among treatment-naïve patients with achalasia: a randomized clinical trial. *JAMA* 2019; 322: 134–144
- [59] Jain D, Sharma A, Shah M et al. Efficacy and safety of flexible endoscopic management of Zenker's diverticulum. *J Clin Gastroenterol* 2018; 52: 369–385
- [60] Komeda Y, Bruno M, Koch A. EMR is not inferior to ESD for early Barrett's and EGJ neoplasia: An extensive review on outcome, recurrence and complication rates. *Endosc Int Open* 2014; 2: E58–64
- [61] Tomizawa Y, Konda VJA, Coronel E et al. Efficacy, durability, and safety of complete endoscopic mucosal resection of Barrett esophagus: a systematic review and meta-analysis. *J Clin Gastroenterol* 2018; 52: 210–216
- [62] Terheggen G, Horn EM, Vieth M et al. A randomised trial of endoscopic submucosal dissection versus endoscopic mucosal resection for early Barrett's neoplasia. *Gut* 2017; 66: 783–793

- [63] Shimizu Y, Takahashi M, Yoshida T et al. Endoscopic resection (endoscopic mucosal resection/ endoscopic submucosal dissection) for superficial esophageal squamous cell carcinoma: current status of various techniques. *Dig Endosc* 2013; 25: (Suppl. 01): 13–19
- [64] Sato H, Inoue H, Ikeda H et al. Clinical experience of esophageal perforation occurring with endoscopic submucosal dissection. *Dis Esophagus* 2014; 27: 617–622
- [65] Noguchi M, Yano T, Kato T et al. Risk factors for intraoperative perforation during endoscopic submucosal dissection of superficial esophageal squamous cell carcinoma. *World J Gastroenterol* 2017; 23: 478–485
- [66] Lv XH, Wang CH, Xie Y. Efficacy and safety of submucosal tunneling endoscopic resection for upper gastrointestinal submucosal tumors: a systematic review and meta-analysis. *Surg Endosc* 2017; 31: 49–63
- [67] Patel K, Abbassi-Ghadi N, Markar S et al. Peroral endoscopic myotomy for the treatment of esophageal achalasia: systematic review and pooled analysis. *Dis Esophagus* 2016; 29: 807–819
- [68] Werner YB, von Renteln D, Noder T et al. et al. Early adverse events of per-oral endoscopic myotomy. *Gastrointest Endosc* 2017; 85: 708–718 .e702
- [69] Birk M, Bauerfeind P, Deprez PH et al. Removal of foreign bodies in the upper gastrointestinal tract in adults: European Society of Gastrointestinal Endoscopy (ESGE) Clinical Guideline. *Endoscopy* 2016; 48: 489–496
- [70] Hong KH, Kim YJ, Kim JH et al. Risk factors for complications associated with upper gastrointestinal foreign bodies. *World J Gastroenterol* 2015; 21: 8125–8131
- [71] Kowalczyk L, Forsmark CE, Ben-David K et al. Algorithm for the management of endoscopic perforations: a quality improvement project. *Am J Gastroenterol* 2011; 106: 1022–1027
- [72] Maeda Y, Hirasawa D, Fujita N et al. Mediastinal emphysema after esophageal endoscopic submucosal dissection: its prevalence and clinical significance. *Dig Endosc* 2011; 23: 221–226
- [73] Maeda Y, Hirasawa D, Fujita N et al. Carbon dioxide insufflation in esophageal endoscopic submucosal dissection reduces mediastinal emphysema: A randomized, double-blind, controlled trial. *World J Gastroenterol* 2016; 22: 7373–7382
- [74] Sancheti MS, Fernandez FG. Surgical management of esophageal perforation. *Oper Tech Thoracic Cardiovasc Surg* 2015; 20: 234–250
- [75] Kuppusamy MK, Hubka M, Felisky CD et al. Evolving management strategies in esophageal perforation: surgeons using nonoperative techniques to improve outcomes. *J Am Coll Surg* 2011; 213: 164–171
- [76] Hagel AF, Naegel A, Lindner AS et al. Over-the-scope clip application yields a high rate of closure in gastrointestinal perforations and may reduce emergency surgery. *J Gastrointest Surg* 2012; 16: 2132–2138
- [77] Seven G, Irani S, Ross AS et al. Partially versus fully covered self-expanding metal stents for benign and malignant esophageal conditions: a single center experience. *Surg Endosc* 2013; 27: 2185–2192
- [78] Thornblade LW, Cheng AM, Wood DE et al. A nationwide rise in the use of stents for benign esophageal perforation. *Ann Thorac Surg* 2017; 104: 227–233
- [79] van Boeckel PG, Sijbrink A, Vlegelaar FP et al. Systematic review: temporary stent placement for benign rupture or anastomotic leak of the oesophagus. *Aliment Pharmacol Ther* 2011; 33: 1292–1301
- [80] Dasari BV, Neely D, Kennedy A et al. The role of esophageal stents in the management of esophageal anastomotic leaks and benign esophageal perforations. *Ann Surg* 2014; 259: 852–860
- [81] El HII, Imperiale TF, Rex DK et al. Treatment of esophageal leaks, fistulae, and perforations with temporary stents: evaluation of efficacy, adverse events, and factors associated with successful outcomes. *Gastrointest Endosc* 2014; 79: 589–598
- [82] Gubler C, Bauerfeind P. Self-expandable stents for benign esophageal leakages and perforations: long-term single-center experience. *Scand J Gastroenterol* 2014; 49: 23–29
- [83] Persson S, Elbe P, Rouvelas I et al. Predictors for failure of stent treatment for benign esophageal perforations – a single center 10-year experience. *World J Gastroenterol* 2014; 20: 10613–10619
- [84] van den Berg MW, Kerbert AC, van Soest EJ et al. Safety and efficacy of a fully covered large-diameter self-expanding metal stent for the treatment of upper gastrointestinal perforations, anastomotic leaks, and fistula. *Dis Esophagus* 2016; 29: 572–579
- [85] Freeman RK, Ascoti AJ, Dake M et al. An assessment of the optimal time for removal of esophageal stents used in the treatment of an esophageal anastomotic leak or perforation. *Ann Thorac Surg* 2015; 100: 422–428
- [86] Navaneethan U, Lourdasamy V, Duvuru S et al. Timing of esophageal stent placement and outcomes in patients with esophageal perforation: a single-center experience. *Surg Endosc* 2015; 29: 700–707
- [87] van Halsema EE, Kappelle WFW, Weusten B et al. Stent placement for benign esophageal leaks, perforations, and fistulae: a clinical prediction rule for successful leakage control. *Endoscopy* 2018; 50: 98–108
- [88] Huh CW, Kim JS, Choi HH et al. Treatment of benign perforations and leaks of the esophagus: factors associated with success after stent placement. *Surg Endosc* 2018; 32: 3646–3651
- [89] Monkemuller K, Martinez-Alcala A, Schmidt AR et al. The use of the over the scope clips beyond its standard use: a pictorial description. *Gastrointest Endosc Clin N Am* 2020; 30: 41–74
- [90] Lindenmann J, Maier A, Fink-Neuboeck N et al. Fatal aortic hemorrhage after over-the-scope clipping and subsequent esophageal stenting for sealing of iatrogenic esophageal perforation. *Endoscopy* 2015; 47: (Suppl. 01): E280–E281
- [91] Newton NJ, Sharrock A, Rickard R et al. Systematic review of the use of endo-luminal topical negative pressure in oesophageal leaks and perforations. *Dis Esophagus* 2017; 30: 1–5
- [92] Rausa E, Asti E, Aiolfi A et al. Comparison of endoscopic vacuum therapy versus endoscopic stenting for esophageal leaks: systematic review and meta-analysis. *Dis Esophagus* 2018; 31: doi:10.1093/dote/doy060
- [93] Leers JM, Vivaldi C, Schafer H et al. Endoscopic therapy for esophageal perforation or anastomotic leak with a self-expandable metallic stent. *Surg Endosc* 2009; 23: 2258–2262
- [94] Persson S, Rouvelas I, Irino T et al. Outcomes following the main treatment options in patients with a leaking esophagus: a systematic literature review. *Dis Esophagus* 2017; 30: 1–10
- [95] Zimmermann M, Hoffmann M, Jungbluth T et al. Predictors of morbidity and mortality in esophageal perforation: retrospective study of 80 patients. *Scand J Surg* 2017; 106: 126–132
- [96] Schweigert M, Sousa HS, Solymosi N et al. Spotlight on esophageal perforation: A multinational study using the Pittsburgh esophageal perforation severity scoring system. *J Thorac Cardiovasc Surg* 2016; 151: 1002–1009
- [97] Ben-David K, Behrns K, Hochwald S et al. Esophageal perforation management using a multidisciplinary minimally invasive treatment algorithm. *J Am Coll Surg* 2014; 218: 768–774
- [98] Biancari F, Saarnio J, Mennander A et al. Outcome of patients with esophageal perforations: a multicenter study. *World J Surg* 2014; 38: 902–909
- [99] Biancari F, Gudbjartsson T, Mennander A et al. Treatment of esophageal perforation in octogenarians: a multicenter study. *Dis Esophagus* 2014; 27: 715–718

- [100] Kuppusamy MK, Felisky C, Kozarek RA et al. Impact of endoscopic assessment and treatment on operative and non-operative management of acute oesophageal perforation. *Br J Surg* 2011; 98: 818–824
- [101] Markar SR, Mackenzie H, Wiggins T et al. Management and outcomes of esophageal perforation: a national study of 2,564 patients in England. *Am J Gastroenterol* 2015; 110: 1559–1566
- [102] Ukleja A, Afonso BB, Pimentel R et al. Outcome of endoscopic balloon dilation of strictures after laparoscopic gastric bypass. *Surg Endosc* 2008; 22: 1746–1750
- [103] Yoo JH, Shin SJ, Lee KM et al. Risk factors for perforations associated with endoscopic submucosal dissection in gastric lesions: emphasis on perforation type. *Surg Endosc* 2012; 26: 2456–2464
- [104] Imagawa A, Okada H, Kawahara Y et al. Endoscopic submucosal dissection for early gastric cancer: results and degrees of technical difficulty as well as success. *Endoscopy* 2006; 38: 987–990
- [105] Chung IK, Lee JH, Lee SH et al. Therapeutic outcomes in 1000 cases of endoscopic submucosal dissection for early gastric neoplasms: Korean ESD Study Group multicenter study. *Gastrointest Endosc* 2009; 69: 1228–1235
- [106] Toyokawa T, Inaba T, Omote S et al. Risk factors for perforation and delayed bleeding associated with endoscopic submucosal dissection for early gastric neoplasms: analysis of 1123 lesions. *J Gastroenterol Hepatol* 2012; 27: 907–912
- [107] Fujishiro M, Yahagi N, Kakushima N et al. Successful nonsurgical management of perforation complicating endoscopic submucosal dissection of gastrointestinal epithelial neoplasms. *Endoscopy* 2006; 38: 1001–1006
- [108] Binmoeller KF, Grimm H, Soehendra N. Endoscopic closure of a perforation using metallic clips after snare excision of a gastric leiomyoma. *Gastrointest Endosc* 1993; 39: 172–174
- [109] Albuquerque W, Arantes V. Large gastric perforation after endoscopic mucosal resection treated by application of metallic clips (video). *Endoscopy* 2004; 36: 752–753
- [110] Katsinelos P, Beltsis A, Paroutoglou G et al. Endoclipping for gastric perforation after endoscopic polypectomy: an alternative treatment to avoid surgery. *Surg Laparosc Endosc Percutan Tech* 2004; 14: 279–281
- [111] De Caro G, Pagano N, Malesci A et al. Endoclipping for gastric perforation secondary to second session of EMRC in locally residual early gastric cancer: a case report. *Dig Liver Dis* 2009; 41: e32–e34
- [112] Kim HS, Lee DK, Jeong YS et al. Successful endoscopic management of a perforated gastric dysplastic lesion after endoscopic mucosal resection. *Gastrointest Endosc* 2000; 51: 613–615
- [113] Minami S, Gotoda T, Ono H et al. Complete endoscopic closure of gastric perforation induced by endoscopic resection of early gastric cancer using endoclips can prevent surgery (with video). *Gastrointest Endosc* 2006; 63: 596–601
- [114] Tsunada S, Ogata S, Ohyama T et al. Endoscopic closure of perforations caused by EMR in the stomach by application of metallic clips. *Gastrointest Endosc* 2003; 57: 948–951
- [115] Kirschniak A, Subotova N, Zieker D et al. The over-the-scope clip (OTSC) for the treatment of gastrointestinal bleeding, perforations, and fistulas. *Surg Endosc* 2011; 25: 2901–2905
- [116] Baron TH, Song LM, Ross A et al. Use of an over-the-scope clipping device: multicenter retrospective results of the first U.S. experience (with videos). *Gastrointest Endosc* 2012; 76: 202–208
- [117] Nishiyama N, Mori H, Kobara H et al. Efficacy and safety of over-the-scope clip: including complications after endoscopic submucosal dissection. *World J Gastroenterol* 2013; 19: 2752–2760
- [118] Han JH, Lee TH, Jung Y et al. Rescue endoscopic band ligation of iatrogenic gastric perforations following failed endoclip closure. *World J Gastroenterol* 2013; 19: 955–959
- [119] Iwashita T, Lee JG, Nakai Y et al. Successful management of perforation during cystogastrostomy with an esophageal fully covered metallic stent placement. *Gastrointest Endosc* 2012; 76: 214–215
- [120] Kim GJ, Park SM, Kim JS et al. Risk factors for additional surgery after iatrogenic perforations due to endoscopic submucosal dissection. *Gastroenterol Res Pract* 2017; 2017: 6353456
- [121] Merchea A, Cullinane DC, Sawyer MD et al. Esophagogastroduodenoscopy-associated gastrointestinal perforations: a single-center experience. *Surgery* 2010; 148: 876–880; discussion 881–872
- [122] Mangiavillano B, Viaggi P, Masci E. Endoscopic closure of acute iatrogenic perforations during diagnostic and therapeutic endoscopy in the gastrointestinal tract using metallic clips: a literature review. *J Dig Dis* 2010; 11: 12–18
- [123] Surace M, Mercky P, Demarquay JF et al. Endoscopic management of GI fistulae with the over-the-scope clip system (with video). *Gastrointest Endosc* 2011; 74: 1416–1419
- [124] von Renteln D, Denzer UW, Schachschal G et al. Endoscopic closure of GI fistulae by using an over-the-scope clip (with videos). *Gastrointest Endosc* 2010; 72: 1289–1296
- [125] Parodi A, Repici A, Pedroni A et al. Endoscopic management of GI perforations with a new over-the-scope clip device (with videos). *Gastrointest Endosc* 2010; 72: 881–886
- [126] Manta R, Manno M, Bertani H et al. Endoscopic treatment of gastrointestinal fistulas using an over-the-scope clip (OTSC) device: case series from a tertiary referral center. *Endoscopy* 2011; 43: 545–548
- [127] Honegger C, Valli PV, Wiegand N et al. Establishment of over-the-scope-clips (OTSC(R)) in daily endoscopic routine. *United European Gastroenterol J* 2017; 5: 247–254
- [128] Martinek J, Ryska O, Tuckova I et al. Comparing over-the-scope clip versus endoloop and clips (KING closure) for access site closure: a randomized experimental study. *Surg Endosc* 2013; 27: 1203–1210
- [129] Shi Q, Chen T, Zhong YS et al. Complete closure of large gastric defects after endoscopic full-thickness resection, using endoloop and metallic clip interrupted suture. *Endoscopy* 2013; 45: 329–334
- [130] Stapfer M, Selby RR, Stain SC et al. Management of duodenal perforation after endoscopic retrograde cholangiopancreatography and sphincterotomy. *Ann Surg* 2000; 232: 191–198
- [131] Andriulli A, Loperfido S, Napolitano G et al. Incidence rates of post-ERCP complications: a systematic survey of prospective studies. *Am J Gastroenterol* 2007; 102: 1781–1788
- [132] Cirocchi R, Kelly MD, Griffiths EA et al. A systematic review of the management and outcome of ERCP related duodenal perforations using a standardized classification system. *Surgeon* 2017; 15: 379–387
- [133] Enns R, Eloubeidi MA, Mergener K et al. ERCP-related perforations: risk factors and management. *Endoscopy* 2002; 34: 293–298
- [134] Weiser R, Pencovich N, Mlynarsky L et al. Management of endoscopic retrograde cholangiopancreatography-related perforations: Experience of a tertiary center. *Surgery* 2017; 161: 920–929
- [135] Shi D, Yang JF, Liu YP. Endoscopic treatment of endoscopic retrograde cholangiopancreatography-related duodenal perforations. *J Laparoendosc Adv Surg Tech A* 2019; 29: 385–391
- [136] Odemis B, Oztas E, Kuzu UB et al. Can a fully covered self-expandable metallic stent be used temporarily for the management of duodenal retroperitoneal perforation during ercp as a part of conservative therapy? *Surg Laparosc Endosc Percutan Tech* 2016; 26: e9–e17
- [137] Jeon HJ, Han JH, Park S et al. Endoscopic sphincterotomy-related perforation in the common bile duct successfully treated by placement of a covered metal stent. *Endoscopy* 2011; 43: (Suppl. 02): E295–E296
- [138] Lee SM, Cho KB. Value of temporary stents for the management of perivaterian perforation during endoscopic retrograde cholangiopancreatography. *World J Clin Cases* 2014; 2: 689–697

- [139] Park WY, Cho KB, Kim ES et al. A case of ampullary perforation treated with a temporally covered metal stent. *Clin Endosc* 2012; 45: 177–180
- [140] Vezakis A, Fragulidis G, Nastos C et al. Closure of a persistent sphincterotomy-related duodenal perforation by placement of a covered self-expandable metallic biliary stent. *World J Gastroenterol* 2011; 17: 4539–4541
- [141] Theopistos V, Theocharis G, Konstantakis C et al. Non-operative management of type 2 ERCP-related retroperitoneal duodenal perforations: a 9-year experience from a single center. *Gastroenterology Res* 2018; 11: 207–212
- [142] Shami VM, Talreja JP, Mahajan A et al. EUS-guided drainage of bilomas: a new alternative? *Gastrointest Endosc* 2008; 67: 136–140
- [143] Vezakis A, Fragulidis G, Polydorou A. Endoscopic retrograde cholangiopancreatography-related perforations: Diagnosis and management. *World J Gastrointest Endosc* 2015; 7: 1135–1141
- [144] Wu HM, Dixon E, May GR et al. Management of perforation after endoscopic retrograde cholangiopancreatography (ERCP): a population-based review. *HPB (Oxford)* 2006; 8: 393–399
- [145] Fatima J, Baron TH, Topazian MD et al. Pancreaticobiliary and duodenal perforations after perampullary endoscopic procedures: diagnosis and management. *Arch Surg* 2007; 142: 448–454; discussion 454–455
- [146] Lee TH, Bang BW, Jeong JI et al. Primary endoscopic approximation suture under cap-assisted endoscopy of an ERCP-induced duodenal perforation. *World J Gastroenterol* 2010; 16: 2305–2310
- [147] Aranez JL, Miller J, Hughes M et al. A novel, duodenoscope-friendly endoscopic clip for treating massive upper-GI bleeding secondary to a Dieulafoy lesion. *VideoGIE* 2018; 3: 205–206
- [148] Samarasena JB, Nakai Y, Park DH et al. Endoscopic closure of an iatrogenic duodenal perforation: a novel technique using endoclips, endoloop, and fibrin glue. *Endoscopy* 2012; 44: (Suppl. 02): E424–E425
- [149] Nakagawa Y, Nagai T, Soma W et al. Endoscopic closure of a large ERCP-related lateral duodenal perforation by using endoloops and endoclips. *Gastrointest Endosc* 2010; 72: 216–217
- [150] Arvanitakis M, Dumonceau JM, Albert J et al. Endoscopic management of acute necrotizing pancreatitis: European Society of Gastrointestinal Endoscopy (ESGE) evidence-based multidisciplinary guidelines. *Endoscopy* 2018; 50: 524–546
- [151] Kayhan B, Akdogan M, Sahin B. ERCP subsequent to retroperitoneal perforation caused by endoscopic sphincterotomy. *Gastrointest Endosc* 2004; 60: 833–835
- [152] Srivastava S, Sharma BC, Puri AS et al. Impact of completion of primary biliary procedure on outcome of endoscopic retrograde cholangiopancreatographic related perforation. *Endosc Int Open* 2017; 5: E706–E709
- [153] Ercan M, Bostanci EB, Dalgic T et al. Surgical outcome of patients with perforation after endoscopic retrograde cholangiopancreatography. *J Laparoendosc Adv Surg Tech A* 2012; 22: 371–377
- [154] Machado NO. Management of duodenal perforation post-endoscopic retrograde cholangiopancreatography. When and whom to operate and what factors determine the outcome? A review article. *JOP* 2012; 13: 18–25
- [155] Preetha M, Chung YF, Chan WH et al. Surgical management of endoscopic retrograde cholangiopancreatography-related perforations. *ANZ J Surg* 2003; 73: 1011–1014
- [156] Sarli L, Porrini C, Costi R et al. Operative treatment of perampullary retroperitoneal perforation complicating endoscopic sphincterotomy. *Surgery* 2007; 142: 26–32
- [157] Avgerinos DV, Llaguna OH, Lo AY et al. Management of endoscopic retrograde cholangiopancreatography: related duodenal perforations. *Surg Endosc* 2009; 23: 833–838
- [158] Kim BS, Kim IG, Ryu BY et al. Management of endoscopic retrograde cholangiopancreatography-related perforations. *J Korean Surg Soc* 2011; 81: 195–204
- [159] Miller R, Zbar A, Klein Y et al. Perforations following endoscopic retrograde cholangiopancreatography: a single institution experience and surgical recommendations. *Am J Surg* 2013; 206: 180–186
- [160] Kim J, Lee SH, Paik WH et al. Clinical outcomes of patients who experienced perforation associated with endoscopic retrograde cholangiopancreatography. *Surg Endosc* 2012; 26: 3293–3300
- [161] Cotton PB, Garrow DA, Gallagher J et al. Risk factors for complications after ERCP: a multivariate analysis of 11,497 procedures over 12 years. *Gastrointest Endosc* 2009; 70: 80–88
- [162] Park TY, Kang JS, Song TJ et al. Outcomes of ERCP in Billroth II gastrectomy patients. *Gastrointest Endosc* 2016; 83: 1193–1201
- [163] Takano S, Fukasawa M, Shindo H et al. Risk factors for perforation during endoscopic retrograde cholangiopancreatography in post-reconstruction intestinal tract. *World J Clin Cases* 2019; 7: 10–18
- [164] Watanabe D, Hayashi H, Kataoka Y et al. Efficacy and safety of endoscopic submucosal dissection for non-ampullary duodenal polyps: A systematic review and meta-analysis. *Dig Liver Dis* 2019; 51: 774–781
- [165] Pimentel-Nunes P, Dinis-Ribeiro M, Ponchon T et al. Endoscopic submucosal dissection: European Society of Gastrointestinal Endoscopy (ESGE) Guideline. *Endoscopy* 2015; 47: 829–854
- [166] Perez-Cuadrado-Robles E, Queneherve L, Margos W et al. Comparative analysis of ESD versus EMR in a large European series of non-ampullary superficial duodenal tumors. *Endosc Int Open* 2018; 6: E1008–E1014
- [167] Esaki M, Suzuki S, Ikehara H et al. Endoscopic diagnosis and treatment of superficial non-ampullary duodenal tumors. *World J Gastrointest Endosc* 2018; 10: 156–164
- [168] Conio M, De Ceglie A, Filiberti R et al. Cap-assisted EMR of large, sporadic, nonampullary duodenal polyps. *Gastrointest Endosc* 2012; 76: 1160–1169
- [169] Kakushima N, Ono H, Takao T et al. Method and timing of resection of superficial non-ampullary duodenal epithelial tumors. *Dig Endosc* 2014; 26: (Suppl. 02): 35–40
- [170] de Moura EGH, Orso IRB, Aurelio EF et al. Factors associated with complications or failure of endoscopic balloon dilation of anastomotic stricture secondary to Roux-en-Y gastric bypass surgery. *Surg Obes Relat Dis* 2016; 12: 582–586
- [171] Almby K, Edholm D. Anastomotic strictures after Roux-en-Y gastric bypass: a cohort study from the Scandinavian Obesity Surgery Registry. *Obes Surg* 2019; 29: 172–177
- [172] Goitein D, Papasavas PK, Gagne D et al. Gastrojejunal strictures following laparoscopic Roux-en-Y gastric bypass for morbid obesity. *Surg Endosc* 2005; 19: 628–632
- [173] Mathew A, Veluona MA, DePalma FJ et al. Gastrojejunal stricture after gastric bypass and efficacy of endoscopic intervention. *Dig Dis Sci* 2009; 54: 1971–1978
- [174] Carrodeguas L, Szomstein S, Zundel N et al. Gastrojejunal anastomotic strictures following laparoscopic Roux-en-Y gastric bypass surgery: analysis of 1291 patients. *Surg Obes Relat Dis* 2006; 2: 92–97
- [175] Moschler O, May A, Muller MK et al. Complications in and performance of double-balloon enteroscopy (DBE): results from a large prospective DBE database in Germany. *Endoscopy* 2011; 43: 484–489
- [176] Gerson LB, Tokar J, Chiorean M et al. Complications associated with double balloon enteroscopy at nine US centers. *Clin Gastroenterol Hepatol* 2009; 7: 1177–1182, 1182.e1171–1173
- [177] Odagiri H, Matsui H, Fushimi K et al. Factors associated with perforation related to diagnostic balloon-assisted enteroscopy: analysis

- of a national inpatient database in Japan. *Endoscopy* 2015; 47: 143–146
- [178] Aktas H, de Ridder L, Haringsma J et al. Complications of single-balloon enteroscopy: a prospective evaluation of 166 procedures. *Endoscopy* 2010; 42: 365–368
- [179] Tominaga K, Iida T, Nakamura Y et al. Small intestinal perforation of endoscopically unrecognized lesions during peroral single-balloon enteroscopy. *Endoscopy* 2008; 40: (Suppl. 02): E213–214
- [180] Akerman PA, Cantero D. Severe complications of spiral enteroscopy in the first 1750 patients. *Gastrointest Endosc* 2009; 69: AB127. doi:10.1016/j.gie.2009.03.152
- [181] Welch AR, Moyer MT, Dye CE et al. A single-center experience with spiral enteroscopy: a note of caution. *Gastrointest Endosc* 2012; 75: 1125–1126
- [182] Li XB, Gu LY, Song Y et al. Small-bowel perforation in a patient with Roux-en-Y anatomy for Peutz–Jeghers polyps after spiral enteroscopic investigation. *Endoscopy* 2011; 43: (Suppl. 02): E85
- [183] Palmer JS, Marenah K, El MF et al. Small bowel perforation following capsule endoscopy: a case report. *Ann R Coll Surg Engl* 2011; 93: e69–e70
- [184] Um S, Poblete H, Zavotsky J. Small bowel perforation caused by an impacted endocapsule. *Endoscopy* 2008; 40: (Suppl. 02): E122–E123
- [185] Yitzhak A, Bayme M, Perry ZH et al. Small bowel perforation after capsule endoscopy in a patient with occult gastrointestinal bleeding and undiagnosed Crohn's disease. *Am Surg* 2012; 78: E159–E161
- [186] De Palma GD, Masone S, Persico M et al. Capsule impaction presenting as acute small bowel perforation: a case series. *J Med Case Rep* 2012; 6: 121
- [187] Jung JH, Choi KD, Ahn JY et al. Endoscopic submucosal dissection for sessile, nonampullary duodenal adenomas. *Endoscopy* 2013; 45: 133–135
- [188] Inoue T, Uedo N, Yamashina T et al. Delayed perforation: a hazardous complication of endoscopic resection for non-ampullary duodenal neoplasm. *Dig Endosc* 2014; 26: 220–227
- [189] Parlak E, Koksali A, Disibeyaz S et al. Endoscopic closure of ERCP-related duodenal perforations by using endoclips: a case series. *Surg Laparosc Endosc Percutan Tech* 2013; 23: e225–228
- [190] Ye LP, Mao XL, Zheng HH et al. Safety of endoscopic resection for duodenal subepithelial lesions with wound closure using clips and an endoloop: an analysis of 68 cases. *Surg Endosc* 2017; 31: 1070–1077
- [191] Krishna RP, Singh RK, Behari A et al. Post-endoscopic retrograde cholangiopancreatography perforation managed by surgery or percutaneous drainage. *Surg Today* 2011; 41: 660–666
- [192] Cordova J, Waxman I, Hart J et al. Double-balloon endoscopic management of iatrogenic perforation in the small bowel. *VideoGIE* 2016; 1: 14–15
- [193] Furukawa K, Miyahara R, Funasaka K et al. Endoscopic closure of duodenal perforation with the over-the-scope-clipping system. *Intern Med* 2016; 55: 3131–3135
- [194] Kirtane T, Singhal S. Endoscopic closure of iatrogenic duodenal perforation using dual over-the-scope clips. *Gastrointest Endosc* 2016; 83: 467–468
- [195] Dogan UB, Keskin MB, Soker G et al. Endoscopic closure of an endoscopy-related duodenal perforation using the over-the-scope clip. *Turk J Gastroenterol* 2013; 24: 436–440
- [196] Salord S, Gornals JB, Maisterra S et al. Endoscopic closure of duodenal perforation with an over-the-scope clip during endoscopic ultrasound-guided cholangiopancreatography. *Rev Esp Enferm Dig* 2012; 104: 489–490
- [197] Tyberg A, Zerbo S, Sharaiha RZ et al. Endoscopic management of a GI perforation. *Gastrointest Endosc* 2015; 82: 955
- [198] Balmadrid B, Ross A. Severe laceration in a percutaneous endoscopic jejunostomy placement resolved with over-the-scope clips. *Gastrointest Endosc* 2013; 78: 783–784; discussion 784–785
- [199] Donatelli G, Dumont JL, Vergeau BM et al. Colic and gastric over-the-scope clip (Ovesco) for the treatment of a large duodenal perforation during endoscopic retrograde cholangiopancreatography. *Therap Adv Gastroenterol* 2014; 7: 282–284
- [200] Khater S, Rahmi G, Perrod G et al. Over-the-scope clip (OTSC) reduces surgery rate in the management of iatrogenic gastrointestinal perforations. *Endosc Int Open* 2017; 5: E389–E394 doi:10.1055/s-0043-104862
- [201] Bergström M, Arroyo Vázquez JA, Park PO. Self-expandable metal stents as a new treatment option for perforated duodenal ulcer. *Endoscopy* 2013; 45: 222–225
- [202] Korman LY, Overholt BF, Box T et al. Perforation during colonoscopy in endoscopic ambulatory surgical centers. *Gastrointest Endosc* 2003; 58: 554–557
- [203] Anderson ML, Pasha TM, Leighton JA. Endoscopic perforation of the colon: lessons from a 10-year study. *Am J Gastroenterol* 2000; 95: 3418–3422
- [204] Rabeneck L, Paszat LF, Hilsden RJ et al. Bleeding and perforation after outpatient colonoscopy and their risk factors in usual clinical practice. *Gastroenterology* 2008; 135: 1899–1906, 1906.e1891
- [205] Saunders BP, Fukumoto M, Halligan S et al. Why is colonoscopy more difficult in women? *Gastrointest Endosc* 1996; 43: 124–126
- [206] Olaiya B, Adler DG. Adverse events after inpatient colonoscopy in octogenarians: results from the national inpatient sample (1998–2013). *J Clin Gastroenterol* 2019; doi:10.1097/mcg.0000000000001288
- [207] Mukewar S, Costedio M, Wu X et al. Severe adverse outcomes of endoscopic perforations in patients with and without IBD. *Inflamm Bowel Dis* 2014; 20: 2056–2066
- [208] Rutter MD, Saunders BP, Wilkinson KH et al. Thirty-year analysis of a colonoscopic surveillance program for neoplasia in ulcerative colitis. *Gastroenterology* 2006; 130: 1030–1038
- [209] Bielawska B, Day AG, Lieberman DA et al. Risk factors for early colonoscopic perforation include non-gastroenterologist endoscopists: a multivariable analysis. *Clin Gastroenterol Hepatol* 2014; 12: 85–92
- [210] Wernli KJ, Brenner AT, Rutter CM et al. Risks associated with anesthesia services during colonoscopy. *Gastroenterology* 2016; 150: 888–894; quiz e818
- [211] Bielawska B, Hookey LC, Sutradhar R et al. Anesthesia assistance in outpatient colonoscopy and risk of aspiration pneumonia, bowel perforation, and splenic injury. *Gastroenterology* 2018; 154: 77–85. e73
- [212] Luning TH, Keemers-Gels ME, Barendregt WB et al. Colonoscopic perforations: a review of 30,366 patients. *Surg Endosc* 2007; 21: 994–997
- [213] Hawkins AT, Sharp KW, Ford MM et al. Management of colonoscopic perforations: A systematic review. *Am J Surg* 2018; 215: 712–718
- [214] Putcha RV, Burdick JS. Management of iatrogenic perforation. *Gastroenterol Clin North Am* 2003; 32: 1289–1309
- [215] Derbyshire E, Hungin P, Nickerson C et al. Colonoscopic perforations in the English national health service bowel cancer screening programme. *Endoscopy* 2018; 50: 861–870
- [216] Tribonias G, Konstantinidis K, Theodoropoulou A et al. Rectal perforation caused by colonoscopic retroflexion. *Gastrointest Endosc* 2010; 71: 662
- [217] Loffeld RJ, Engel A, Dekkers PE. Incidence and causes of colonoscopic perforations: a single-center case series. *Endoscopy* 2011; 43: 240–242

- [218] Stock C, Ihle P, Sieg A et al. Adverse events requiring hospitalization within 30 days after outpatient screening and non-screening colonoscopies. *Gastrointest Endosc* 2013; 77: 419–429
- [219] Lee TJ, Rutter MD, Blanks RG et al. Colonoscopy quality measures: experience from the NHS Bowel Cancer Screening Programme. *Gut* 2012; 61: 1050–1057
- [220] Rabeneck L, Saskin R, Paszat LF. Onset and clinical course of bleeding and perforation after outpatient colonoscopy: a population-based study. *Gastrointest Endosc* 2011; 73: 520–523
- [221] Morar PS, Faiz O, Warusavitarne J et al. Systematic review with meta-analysis: endoscopic balloon dilatation for Crohn's disease strictures. *Aliment Pharmacol Ther* 2015; 42: 1137–1148
- [222] Bettenworth D, Gustavsson A, Atreja A et al. A pooled analysis of efficacy, safety, and long-term outcome of endoscopic balloon dilatation therapy for patients with stricturing Crohn's disease. *Inflamm Bowel Dis* 2017; 23: 133–142
- [223] van Hooft JE, van Halsema EE, Vanbiervliet G et al. Self-expandable metal stents for obstructing colonic and extracolonic cancer: European Society of Gastrointestinal Endoscopy (ESGE) Clinical Guideline. *Gastrointest Endosc* 2014; 80: 747–761.e1-75
- [224] van Halsema EE, van Hooft JE, Small A] et al. Perforation in colorectal stenting: a meta-analysis and a search for risk factors. *Gastrointest Endosc* 2014; 79: 970–982.e977; quiz 983.e972, 983.e975
- [225] Bowles CJ, Leicester R, Romaya C et al. A prospective study of colonoscopy practice in the UK today: are we adequately prepared for national colorectal cancer screening tomorrow? *Gut* 2004; 53: 277–283
- [226] Heldwein W, Dollhopf M, Rosch T et al. The Munich Polypectomy Study (MUPS): prospective analysis of complications and risk factors in 4000 colonic snare polypectomies. *Endoscopy* 2005; 37: 1116–1122
- [227] Arezzo A, Passera R, Marchese N et al. Systematic review and meta-analysis of endoscopic submucosal dissection vs endoscopic mucosal resection for colorectal lesions. *United European Gastroenterol J* 2016; 4: 18–29
- [228] Kothari ST, Huang RJ, Shaukat A et al. ASGE review of adverse events in colonoscopy. *Gastrointest Endosc* 2019; 90: 863–876.e33
- [229] Fujiya M, Tanaka K, Dokoshi T et al. Efficacy and adverse events of EMR and endoscopic submucosal dissection for the treatment of colon neoplasms: a meta-analysis of studies comparing EMR and endoscopic submucosal dissection. *Gastrointest Endosc* 2015; 81: 583–595
- [230] Hong SN, Byeon JS, Lee BI et al. Prediction model and risk score for perforation in patients undergoing colorectal endoscopic submucosal dissection. *Gastrointest Endosc* 2016; 84: 98–108
- [231] La Torre M, Velluti F, Giuliani G et al. Promptness of diagnosis is the main prognostic factor after colonoscopic perforation. *Colorectal Dis* 2012; 14: e23–26
- [232] Bassan MS, Holt B, Moss A et al. Carbon dioxide insufflation reduces number of postprocedure admissions after endoscopic resection of large colonic lesions: a prospective cohort study. *Gastrointest Endosc* 2013; 77: 90–95
- [233] Gayer G, Hertz M, Zissin R. Postoperative pneumoperitoneum: prevalence, duration, and possible significance. *Semin Ultrasound CT MR* 2004; 25: 286–289
- [234] Raju GS, Ahmed I, Xiao SY et al. Controlled trial of immediate endoluminal closure of colon perforations in a porcine model by use of a novel clip device (with videos). *Gastrointest Endosc* 2006; 64: 989–997
- [235] Burgess NG, Bassan MS, McLeod D et al. Deep mural injury and perforation after colonic endoscopic mucosal resection: a new classification and analysis of risk factors. *Gut* 2017; 66: 1779–1789
- [236] Ma MX, Bourke MJ. Complications of endoscopic polypectomy, endoscopic mucosal resection and endoscopic submucosal dissection in the colon. *Best Pract Res Clin Gastroenterol* 2016; 30: 749–767
- [237] Magdeburg R, Collet P, Post S et al. Endoclipping of iatrogenic colonic perforation to avoid surgery. *Surg Endosc* 2008; 22: 1500–1504
- [238] Byeon JS. Colonic perforation: can we manage it endoscopically? *Clin Endosc* 2013; 46: 495–499
- [239] Kim ES, Cho KB, Park KS et al. Factors predictive of perforation during endoscopic submucosal dissection for the treatment of colorectal tumors. *Endoscopy* 2011; 43: 573–578
- [240] Magdeburg R, Sold M, Post S et al. Differences in the endoscopic closure of colonic perforation due to diagnostic or therapeutic colonoscopy. *Scand J Gastroenterol* 2013; 48: 862–867
- [241] Jovanovic I, Zimmermann L, Fry LC et al. Feasibility of endoscopic closure of an iatrogenic colon perforation occurring during colonoscopy. *Gastrointest Endosc* 2011; 73: 550–555
- [242] Singhal S, Changela K, Papafragkakis H et al. Over the scope clip: technique and expanding clinical applications. *J Clin Gastroenterol* 2013; 47: 749–756
- [243] Weiland T, Fehlker M, Gottwald T et al. Performance of the OTSC system in the endoscopic closure of iatrogenic gastrointestinal perforations: a systematic review. *Surg Endosc* 2013; 27: 2258–2274
- [244] Alsowaina KN, Ahmed MA, Alkhamisi NA et al. Management of colonoscopic perforation: a systematic review and treatment algorithm. *Surg Endosc* 2019; 33: 3889–3898
- [245] Han JH, Park S, Youn S. Endoscopic closure of colon perforation with band ligation; salvage technique after endoclip failure. *Clin Gastroenterol Hepatol* 2011; 9: e54–55
- [246] Ryu JY, Park BK, Kim WS et al. Endoscopic closure of iatrogenic colon perforation using dual-channel endoscope with an endoloop and clips: methods and feasibility data (with videos). *Surg Endosc* 2019; 33: 1342–1348
- [247] Kantsevov SV, Bitner M, Hajiyeva G et al. Endoscopic management of colonic perforations: clips versus suturing closure (with videos). *Gastrointest Endosc* 2016; 84: 487–493
- [248] Cho SB, Lee WS, Joo YE et al. Therapeutic options for iatrogenic colon perforation: feasibility of endoscopic clip closure and predictors of the need for early surgery. *Surg Endosc* 2012; 26: 473–479
- [249] Bleier JI, Moon V, Feingold D et al. Initial repair of iatrogenic colon perforation using laparoscopic methods. *Surg Endosc* 2008; 22: 646–649