

Status of Sentinel Lymph Node Biopsy in Endometrial Cancer

Stellenwert der Sentinellymphonodektomie beim Endometriumkarzinom



Authors

Florin Andrei Taran, Lisa Jung, Julia Waldschmidt, Sarah Isabelle Huwer, Ingolf Juhasz-Böss

Affiliation

Klinik für Frauenheilkunde, Universitätsklinikum Freiburg, Freiburg, Germany

Key words

endometrial cancer, sentinel lymph node, sentinel mapping, ultrastaging

Schlüsselwörter

Endometriumkarzinom, Sentinellymphknoten, Sentinel-Mapping, Ultrastaging

received

27. 7. 2020

accepted after revision

1. 3. 2021

Bibliography

Geburtsh Frauenheilk 2021; 81: 562–573

DOI 10.1055/a-1228-6189

ISSN 0016-5751

© 2021. The Author(s).

This is an open access article published by Thieme under the terms of the Creative Commons Attribution-NonDerivative-NonCommercial-License, permitting copying and reproduction so long as the original work is given appropriate credit. Contents may not be used for commercial purposes, or adapted, remixed, transformed or built upon. (<https://creativecommons.org/licenses/by-nc-nd/4.0/>)

Georg Thieme Verlag KG, Rüdigerstraße 14, 70469 Stuttgart, Germany

Correspondence

Prof. Dr. I. Juhasz-Böss

Klinik für Frauenheilkunde, Universitätsklinikum Freiburg
Hugstetterstraße 55, 79106 Freiburg, Germany
ingolf.juhasz-boess@uniklinik-freiburg.de



Deutsche Version unter:

<https://doi.org/10.1055/a-1228-6189>

ABSTRACT

The role of lymphadenectomy in surgical staging remains one of the biggest controversies in the management of endometrial cancer. The concept of sentinel lymph node biopsy in endometrial cancer has been evaluated for a number of years, with promising sensitivity rates and negative predictive values. The possibility of adequate staging while avoiding systematic lymphadenectomy leads to a significant reduction in the rate of peri- and postoperative morbidity. Nevertheless, the status of sentinel lymph node biopsy in endometrial cancer has not yet been fully elucidated and is variously assessed internationally. According to current European guidelines and recommendations, sentinel lymph node biopsy in endometrial cancer should be performed only in the context of clinical studies. In this review article, the developments of the past decade are explored concisely. In addition, current data regarding the technical aspects, accuracy and prognostic relevance of sentinel lymph node biopsy are explained and evaluated critically.

ZUSAMMENFASSUNG

Eine der größten Kontroversen im Management des Endometriumkarzinoms bleibt die Rolle der Lymphonodektomie im Rahmen des operativen Stagings. Das Konzept des Sentinellymphknoten-Verfahrens beim Endometriumkarzinom wird bereits seit mehreren Jahren evaluiert – mit vielversprechenden Sensitivitätsraten und negativen Vorhersagewerten. Die Möglichkeit des adäquaten Stagings unter Verzicht auf eine systematische Lymphonodektomie führt zu einer wesentlichen Reduktion der peri- und postoperativen Morbiditätsrate. Dennoch ist der Stellenwert der Sentinellymphonodektomie beim Endometriumkarzinom bislang noch nicht gänzlich geklärt und wird international unterschiedlich bewertet. Gemäß den geltenden europäischen Leitlinien und Empfehlungen sollte die Sentinellymphonodektomie beim Endometriumkarzinom nur im Rahmen von klinischen Studien durchgeführt werden. Im Rahmen dieser Übersichtsarbeit werden die Entwicklungen der letzten Dekade prägnant erläutert. Des Weiteren wird die aktuelle Datenlage hinsichtlich technischer Aspekte, Genauigkeit und prognostischer Relevanz der Sentinellymphonodektomie erläutert und kritisch bewertet.

Introduction

Endometrial cancer is the fifth most frequent cancer in women and the commonest cancer of the female reproductive organs in developed countries; an incidence of 11 200 cases of endometrial cancer was predicted for 2020 in Germany [1]. About 70% of the cancers are diagnosed at FIGO (Fédération Internationale de Gynécologie et d'Obstétrique) stage I; lymphatic metastasis defines advanced disease and can also occur at an early local stage (e.g., pT1a) [1, 2]. In 1988, the FIGO introduced the concept of surgical staging of endometrial cancer to provide reliable information about the pathological morphology of the primary tumour and lymph node status, as well as the resulting prognosis and possible indication for adjuvant therapy [3]. In 2009 the FIGO staging system for endometrial cancer was revised, in an attempt to further optimise and develop the staging system [3].

The role of lymphadenectomy as part of surgical staging remains one of the major controversies in the management of endometrial cancer. The concept of sentinel lymph node biopsy in endometrial cancer has been evaluated for a number of years, with promising rates of sensitivity and negative predictive values [4]. The possibility of adequate staging while avoiding systematic lymphadenectomy (SLNE) leads to a significant reduction in the rate of peri- and postoperative morbidity. Nevertheless, the status of sentinel lymph node biopsy (SLN) in endometrial cancer has not yet been fully elucidated and is variously assessed internationally [5–9]. A recent international survey of 489 physicians specialising in gynaecological oncology showed that SLN in endometrial cancer was already implemented by 50.3% of those surveyed from Europe and by 69.5% of those surveyed from USA [9].

The current S3 guideline of the German Cancer Society (DKG)/German Cancer Aid (DKH)/Working Group of Scientific Medical Societies (AWMF) recommends that “sentinel lymph node biopsy alone should be performed in endometrial cancer only in the context of controlled studies” [5–7]. The consensus recommendation of the European Society Medical of Oncology (ESMO), the European Society of Gynaecologic Oncology (ESGO) and the European Society for Radiotherapy and Oncology (ESTRO) likewise assesses SLN as an experimental procedure [10]. By contrast, SLN is evaluated in the recommendations of the National Comprehensive Cancer Network (NCCN) as a selective and tailored procedure to avoid overtreatment as compared with SLNE [8].

This article will provide a concise overview of the current status of SLN in the context of surgical staging of endometrial cancer and will consider historical, technical and prognostic aspects.

The Role of Systematic Lymphadenectomy in the Context of Surgical Staging

In recent decades, the staging concept in endometrial cancer has developed steadily, with a switch in 1988 from clinical staging to surgical staging [3]. Although very many advances were achieved recently in the surgical management of endometrial cancer, which has led to a reduction in morbidity, only surgical staging can currently deliver precise information about possible intra-abdominal tumour spread, confirmation or exclusion of lymph node metastases

and possible involvement of neighbouring organs [11]. At all stages of endometrial cancer, the probability of lymph node metastasis is approximately 15% [12]. The value of identifying affected lymph nodes became particularly relevant when it was shown that the use of systemic therapy leads to an improvement in survival in patients with advanced endometrial cancer when compared with radiotherapy [12, 13].

Different studies investigated the effect and benefit of SLNE with regard to survival of patients with endometrial cancer, but these included only two prospective randomised studies. In the study by Benedetti Panici et al., patients with preoperative FIGO (1988) stage I were randomised to a SLNE arm and a control arm without SLNE [14]. More precise staging was achieved in the SLNE arm because significantly more patients with lymph node metastases were found than in the group without SLNE (13.3 vs. 3.2%) [14]. However, an improvement in disease-free or overall survival due to the SLNE was not found [14]. The ASTEC study likewise investigated the influence of SLNE on the survival rate of patients with preoperative FIGO (1988) stage I endometrial cancer [15]. The authors found that there is no advantage for disease-free or overall survival in favour of performing SLNE and concluded that pelvic SLNE cannot be recommended as a routine procedure for the treatment of patients with early-stage endometrial cancer [15]. Three retrospective studies in low-risk patients with FIGO stage I (G1 and G2, as well as endometrioid histology and tumour diameter < 2 cm) found excellent overall survival when SLNE was omitted [16–18]. An analysis of the SEER database of over 50 000 patients with endometrial cancer arrived at similar results [19].

In contrast to patients with low-risk endometrial cancer, patients with intermediate- and high-risk endometrial cancer could benefit from SLNE [10]. In the SEPAL study, the influence of para-aortic SLNE in addition to pelvic SLNE in patients with intermediate- and high-risk endometrial cancer was investigated for oncological outcome [20]. Patients who had had pelvic and para-aortic SLNE had significantly better survival compared with patients who underwent pelvic SLNE only [20].

The Real-World Problem of Risk-Adapted Indication for Systematic Lymphadenectomy

Based on the available results, clinical practice to date and the current European guidelines and consensus recommendations (DKG-DKH-AWMF, ESMO-ESGO-ESTRO) follow a risk-adapted indication for SLNE; uterine risk factors for lymph node metastasis and prognosis determine whether SLNE is indicated (high-risk group) or not (low-risk group) [5, 10]. For patients with intermediate-risk endometrial cancer (e.g. pT1a, G3, pT1b, G1/2) there is a more or less problematic “can be considered” recommendation [5, 10]. This risk-adapted concept can show numerous limitations: the existing risk of over- or undertreatment of patients; the uterine risk factors can only be determined accurately from the final specimen; no evidence for a survival advantage for SLNE in prospective randomised studies; the systematic surgery and quality of the SLNE cannot be judged objectively in the absence of standardisation; the molecular pathology risk profile of the endome-

trial cancer for the indication for adjuvant therapy is not considered due to the lack of prospective study data.

As regards morbidity in patients with endometrial cancer in whom SLNE was performed, numerous studies describe a significantly increased incidence of both early and late postoperative complications (e.g., development of lymphoedema, neuropathy) [[21,22]]. On the other hand, omitting SLNE in patients with endometrial cancer does not lead to a complete reduction in peri- and postoperative morbidity due to the fact that there is an increase in the probability that adjuvant therapy (systemic therapy, radiation) will be indicated, with a potential for side effects [1].

The SLN procedure could thus represent a compromise between omission of SLNE (undertreatment of the small percentage of patients with positive lymph nodes) and performing SLNE (overtreatment of patients without lymph node metastases).

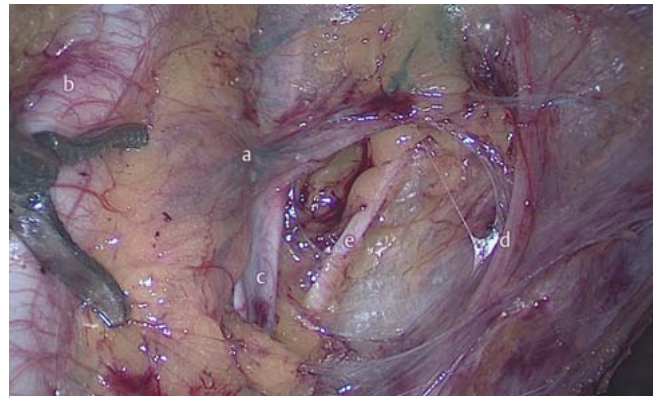
The Sentinel Lymph Node Concept in Endometrial Cancer

The sentinel lymph node concept as part of oncological procedures was first introduced in 1977 by Cabanas for penile cancer [23]. Subsequently established in studies for breast cancer, melanoma and vulvar cancer and now used routinely, it is possible in the same way to identify a sentinel node region within the primary lymphatic drainage area of an endometrial cancer through tracer and/or dye uptake and to remove this after intraoperative localisation by gamma probes and/or direct visualisation (► **Fig. 1**) [11, 24]. The detection rate of sentinel lymph nodes in endometrial cancer is dependent on several anatomical and technical factors: site of injection, injection volume and concentration of the substance as well as type of injected substance: radioactive tracer, fluorescent/blue dyes (e.g. indocyanine green [ICG], isosulfan blue, methylene blue, patent blue) and the visualisation techniques used to display, localise and identify the SLN (direct visualisation, gamma probe lymphoscintigraphy, single photon emission computed tomography [SPECT-CT]) [24, 25].

Technical Aspects of Sentinel Lymph Node Biopsy: Injection Site and Method

The method-related questions as regards the injection site used for the SLN technique are a particular feature of endometrial cancer and are accordingly more challenging when SLN is introduced and used than in the case of focal neoplasms with direct lymphatic drainage, such as breast cancer and vulvar cancer. Three injection sites have been described for lymphatic mapping of endometrial cancer: subserous/myometrial injection into the uterine fundus, hysteroscopy-guided peritumoural injection into the endometrium, and injection into the cervix/isthmocervical injection [26–28].

The fundal, subserous injection technique was used especially with open staging operations and promoted in the early stages of implementation of the sentinel lymph node technique [29]. The most important arguments for the use of this injection technique were the postulated proximity to the tumour and the idea that an

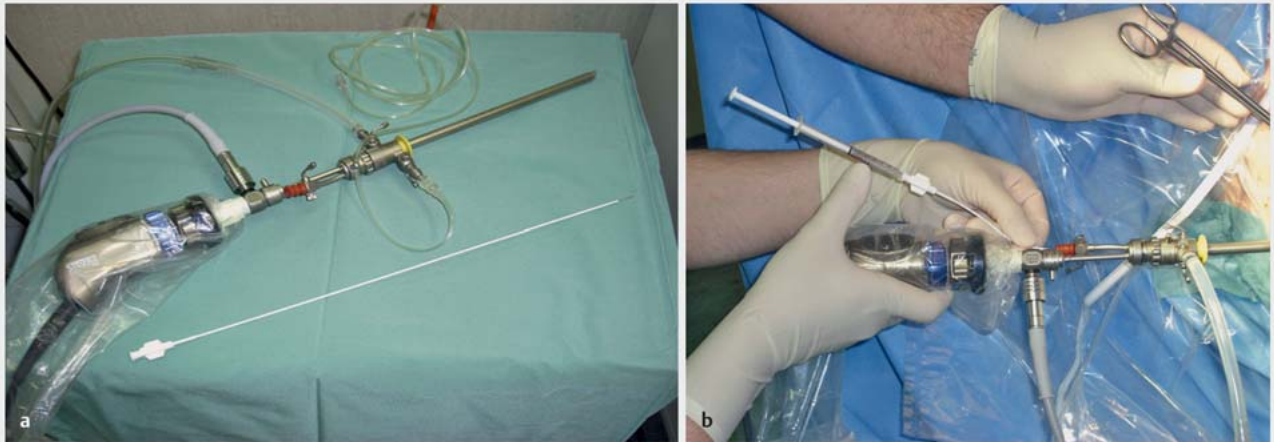


► **Fig. 1** Appearance of the lymphatic vessels and of the sentinel lymph nodes dyed with patent blue after opening the left pelvic retroperitoneum. a = sentinel lymph node and lymphatic drainage route; b = external iliac artery; c = external iliac vein; d = lateral umbilical ligament; e = obturator nerve.

exact illustration of the lymphatic drainage of the uterus can thereby be achieved, especially in the para-aortic lymph node region [30]. The overall detection rates varied considerably in these studies, however (between 0–92%), and an increase in the number of injection sites enabled a higher overall detection rate [29, 31–33]. Moreover, in the last two decades there has been a shift in endometrial cancer staging surgery to minimally invasive procedures so fundal injection to detect the sentinel lymph nodes receded increasingly into the background.

The technique of hysteroscopy-guided injection of the radioactive marker to detect the sentinel lymph node has already been analysed in a number of studies. Detection rates of 30 to 100% have been described (► **Fig. 2**, **Table 1**) [26, 34–37]. The detection rates in the para-aortic lymph node region are higher for the hysteroscopic injection technique compared with cervical injection (► **Table 1**). Nevertheless, peritumoural hysteroscopic injection appears to have lower and less consistent overall detection rates compared with cervical injection (► **Table 1**) [11].

Detection rates with cervical injection of the tracer/dye are between 70–100% (► **Tables 1** and **2**). Ballester et al. used a combination of Tc99m colloid (injection in the cervical stroma at 3, 6, 9 and 12 o'clock) and patent blue (injection in the cervical stroma at 3 and 9 o'clock) and found a detection rate of 89% [2]. Using a similar technique (Tc99m colloid injections at 3 and 9 o'clock, patent blue injections at 3 and 9 o'clock) Abu-Rustum et al. found a detection rate of 86% [38]. Different lymph drainage patterns of cervical cancer and endometrial cancer could give rise to possible concerns regarding the cervical form of injection, so it was initially queried whether this form of injection can deliver reliable information with regard to lymphatic drainage in endometrial cancer [24]. However, Abu-Rustum et al. showed that additional injection in the fundus cannot provide any higher detection rates [39]. Moreover, deep cervical injections (corresponding to the paracervical and parametrial lymphatic drainage routes) using patent blue immediately before hysterectomy demonstrate an adequate course and the possibility of visualising the parauterine lymph drainage routes, the area drained by the uterine vessels and thus



► **Fig. 2** Sentinel node method. a Surgical hysteroscopy with injection needle to deliver tracer, b Technetium99 (colourless tracer in the syringe).

► **Table 1** Sentinel lymph node detection rates depending on the injection site (peritumoural/uterine fundus vs. cervix)/injection method (hysteroscopic injection) (modified from [11]).

Study (year)	n	Tracer/dye	Injection site/ injection method	Overall detection rate (%)	Para-aortic detection rate (%)
Perrone et al. (2008) [26]	17	Tc99	Peritumoural (HSC)	65	18
	23		Cervix	70	0
Rossi et al. (2013) [11]	17	ICG	Peritumoural (HSC)	33	71
	20		Cervix	82	75
Niikura et al. (2013) [34]	55	Patent blue + Tc99	Peritumoural (HSC)	78	56
	45		Cervix	99	0
Sawicki et al. 2015 [35]	82	Patent blue	Fundus	74.4	9.8
	82	Tc99	Cervix	91.5	5
Sahbai et al. (2016) [36]	70	Patent blue + Tc99	Peritumoural (HSC)	69	60
	70		Cervix	83	38
Zuo et al. (2018) [37]	50	CNB	Fundus	92	16
	65		Cervix	100	7.6

ICG: indocyanine green, Tc99: technetium-99, HSC: hysteroscopic injection, CNB: carbon nanoparticles

the largest lymphatic drainage route of the uterus [24]. Although there is still no general consensus regarding the optimal injection site and injection method, cervical injection of the tracer/dye leads to higher detection rates and is more consistently practicable. After cervical injection to detect the sentinel lymph node, however, special attention should also be paid to the para-aortic region, especially in high-risk patients [11].

Technical Aspects of Sentinel Lymph Node Biopsy: Which Tracer/Which Dye?

There have been numerous studies that examined different blue dyes (isosulfan blue, methylene blue, patent blue), combinations of blue dyes and radioactive tracers (especially technetium99m

[Tc99m] nanocolloid) or ICG (fluorescent dye) for displaying the sentinel lymph nodes in endometrial cancer [4, 11]. The blue dyes are injected immediately before the start of the surgery and the colour-marked lymph nodes and lymphatics are identified during operation by direct visualisation. By contrast, sentinel lymph node mapping and detection by a combined method using blue dye and radioactive tracer require more complex coordination and particular quality control at every step of the process.

Hysteroscopy-guided peritumoural (endometrium) or cervical injection of the radioactive tracer (Tc99m nanocolloid) is ideally done on the preoperative day and documented after 4–5 hours using lymphoscintigraphy or single photon emission computed tomography (SPECT-CT) [36]. Additional intraoperative localisation of the labelled lymph nodes is performed through a gamma manual probe [36]. Compared with lymphoscintigraphy,

► **Table 2** Sentinel lymph node detection rates: overall and bilateral detection rates (modified and supplemented from [11]).

Study (year)	n	Injection site	Tracer/dye (combination)	Overall detection rate (%)	Bilateral detection rate (%)
Holloway et al. (2012) [45]	37	Cervix	ICG	100	97*
			Patent blue	100	77
			Patent blue + ICG	100	100
Sinno et al. (2014) [46]	71	Cervix	ICG	92.1*	78.9*
			Patent blue	72.7	42.4
How et al. (2015) [47]	100	Cervix	ICG	87*	65*
			Patent blue	71	43
			Tc99	88	71
Buda et al. (2016) [48]	163	Cervix	ICG	100	85*
			Tc99 + patent blue	97	58
			Patent blue	89	54
Papadia et al. (2017) [49]	147 195	Cervix	ICG	96.9	84.1*
			Patent blue + Tc99	97.3	73.9
Eriksson et al. (2017) [50]	312 160	Cervix	ICG	95*	85*
			Patent blue	81	54
Holloway et al. (2017) [51]	200 180	Cervix	Patent blue	76*	40*
			ICG + patent blue	96.1	83.9
Frumowitz et al. (2018) [58]	176	Cervix	ICG	96*	78*
			Patent blue	74	31
Rozenholc et al. (2019) [52]	132	Cervix	ICG	90.9*	–
			Patent blue	64.4	
Backes et al. (2019) [53]	204	Cervix	ICG	92*	83*
			Isosulfan blue	78	64
Kessous et al. (2019) [42]	80 77	Cervix	ICG + Tc99	97.5	81.3
			ICG + Tc99 + patent blue	93.5	80.5
Cabrera et al. (2020) [43]	49 35	Cervix	Methylene blue + Tc99	94	41
			ICG + Tc99	91	69*

ICG: indocyanine green, Tc99: technetium-99

* significant difference between tracer/dye (combination)

SPECT-CT scanning after tracer injection improves the rate of localisation and detection of the sentinel lymph nodes [25]. Combining dyes with a radioactive tracer has led to better detection rates compared with injection of a blue dye only but the logistical (coordination of gynaecology and nuclear medicine) and financial (additional staff costs, consumables and equipment) effort is greater and also involves disadvantages for the patients, with the inconvenience of an injection on the day before surgery and the additional diagnostic imaging in the form of lymphoscintigraphy or SPECT-CT [11, 35].

ICG is a fluorescent coloured compound that is used in numerous diagnostic procedures (e.g., photometric liver function tests, fluorescence angiography). In 2018 the Federal Drug Administration (FDA) approved the interstitial injection of ICG and the indications for the substance were extended to include visualisation of lymphatics and lymph nodes during lymphatic mapping of endometrial and cervical cancer [40].

The results of the FILM study, an open-label, prospective, randomised international multicentre phase III study, led to the FDA approval of interstitial injection of ICG [41]. In this study, Frumowitz et al.

compared the use of ICG through near-infrared fluorescence imaging with the use of patent blue (defined as treatment standard) for the detection of sentinel lymph nodes in patients with FIGO stage I endometrial cancer [41]. All of the patient were given both dyes; half were initially randomised to ICG analysis and the other half to initial analysis of the patent blue [41]. The intention-to-treat analysis of 176 patients (87 patients after initial ICG injection and 89 patients after initial patent blue injection) showed that the overall detection rate (96 vs. 74%) and the bilateral detection rate (78 vs. 31%) of the sentinel lymph nodes was significantly higher with ICG imaging compared with patent blue imaging [41].

A combination of ICG with Tc99m nanocolloid to show and detect sentinel lymph nodes in patients with endometrial cancer has recently come into the focus of scientific interest. Kessous et al. reported in their study of 157 patients with endometrial cancer that a triple tracer combination (ICG, Tc99m and patent blue) does not lead to a significant improvement in the overall detection rate (93.5 vs. 97.5%) and bilateral detection rate (80.5 vs. 81.3%) compared with a double tracer combination (ICG and

Tc99m) [42]. In a group of 84 patients with endometrial cancer Cabrera et al. compared the sentinel lymph node detection rate after mapping by a combination of ICG and Tc99m (35 patients) to mapping with the combination of ICG and methylene blue (49 patients) [43]. As regards the overall detection rate (93 vs. 94%) there was no significant difference between the 2 groups, but the bilateral detection rate was significantly higher (69 vs. 41%) in the patients who had mapping by means of a combination of ICG and Tc99m [43].

An advantage of the combination of several tracers is the reduction in the rate of failed identification of the sentinel lymph node in endometrial cancer and avoidance of the so-called empty node packet phenomenon, which is described in association with injection of ICG only [43]. The FILM study reported empty node packets in 5% of samples and Thomaier et al. described empty node packets in 7% of samples after imaging the lymph nodes with ICG [41, 44]. The combination of ICG with Tc99m, by adding further preoperative imaging modalities (e.g., SPECT-CT), could lead to an improvement in detection and localisation and to a reduction in the rate of empty node packets [43].

The Overall Detection Rate and the Bilateral Detection Rate of Sentinel Lymph Nodes as Reflected in the Literature

The usefulness of the respective tracer or dye used to image the sentinel lymph nodes is determined by the detection rate (overall detection rate und bilateral detection rate) of the sentinel lymph nodes. As the uterus is a midline organ, bilateral detection of pelvic lymph nodes and also detection of the para-aortic lymph nodes is necessary to enable adequate staging [11]. ► **Table 2** summarises a comparison of the overall and bilateral detection rates of the sentinel lymph nodes after cervical injection of different dyes and dye-tracer combinations.

Possibilities of Standardisation of the Sentinel Lymph Node Concept: Injection Site, Dye/Tracer, Intraoperative Algorithm

Standardisation of surgical procedures and techniques is essential in gynaecological oncology to avoid complications even after difficult intraoperative situations and to keep the operation duration as short as possible. Surgical training is simpler the more standardised a procedure is, and scientific comparison of operative techniques is feasible and useful only then [54]. As well as the correct indication, standardisation of a surgical procedure includes standardisation of the operation steps and the instruments necessary for this plus standardisation of the setting. As regards standardisation of SLN in endometrial cancer, the following aspects should be considered and defined precisely: injection site, tracer/dye, intraoperative algorithm (evaluation, extent of lymph node staging: SLN vs. SLNE).

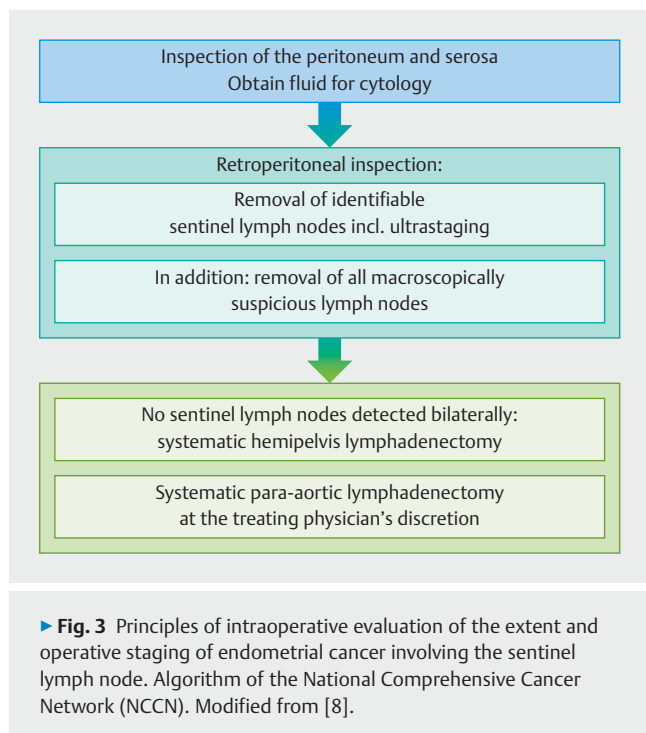
The working group from Memorial Sloan-Kettering Cancer Center (MSKCC) has significantly advanced developments in the area of the sentinel lymph node concept in endometrial cancer and recommends cervical injection (1–3 mm submucosal and 1–2 cm deep into the cervical stroma) of the respective marker(s) for a number of reasons:

1. Most of the lymphatic drainage to the body of the uterus arises from the parametria.
2. The injection site should be quickly and easily accessible.
3. The injection should not be influenced by anatomical variations (the cervix is not infiltrated by tumour in the majority of patients with endometrial cancer).
4. The lymphatic drainage should not be obstructed by previous procedures (e.g., conisation) or tumour infiltration.
5. Injections into the fundal serosa do not include the lymphatic drainage of the parametria and, in addition, the great majority of endometrial cancers do not infiltrate the fundal serosa [24, 55].

As regards standardisation of the dye/tracer, ICG alone or combined injection of ICG and radioactive tracer/patient blue appears to be the best option for the detection of sentinel lymph nodes (► **Table 2**). Limited access to systems for displaying sentinel lymph nodes after ICG (near-infrared fluorescence) or Tc99m labelling (SPECT-CT, gamma hand probe) could limit the available options, however. If fluorescence imaging in the near-infrared area is possible, detection of sentinel lymph nodes with ICG alone is clearly favoured as regards practicability and patient satisfaction [11].

The aim of the NCCN (National Comprehensive Cancer Network) sentinel lymph node algorithm is to identify by SLN the lymph nodes with the highest risk of metastasis in order to limit SLNE and the associated morbidity (► **Fig. 3**). Correct use of the algorithm reduces the false-negative rate to less than 2% [55]. The NCCN algorithm specifies that unilateral pelvic SLNE should always be performed if no sentinel lymph nodes are detected on that side (► **Fig. 1**). Moreover, the morbidity of patients with endometrial cancer can be significantly reduced by the use of the NCCN algorithm [56]. A reduction in operative morbidity (less blood loss, less lymphoedema and shorter operation duration) is reported [56].

In the SHREC study, Persson et al. analysed the effectiveness of an anatomically based sentinel lymph node ICG algorithm for robot-assisted staging of high-risk endometrial cancer [57]. It was shown that use of the sentinel lymph node ICG algorithm by experienced surgeons (> 100 staging operations for endometrial cancer) excluded general lymph node involvement in 99% of cases and thus can replace SLNE in high-risk endometrial cancer [57]. Both algorithms have the potential to establish SLN as a universally applicable concept for routine clinical practice, both for low- and intermediate-risk and for high-risk endometrial cancer. A new version of the DKG-DKH-AWMF guideline could contain the evaluation of the NCCN algorithm (for low- and intermediate-risk cases) and the SLN ICG algorithm (high-risk cases). Prospective studies to compare the current DKG-DKH-AWMF guideline with the NCCN algorithm and SLN ICG algorithm cannot be expected because of the high number of cases necessary.



The Accuracy of Sentinel Lymph Node Biopsy in Endometrial Cancer

The practicability of SLN in endometrial cancer in routine clinical practice and extensive introduction of this technique depend primarily on two factors: the detection rate and the false-negative rate. The detection rate is the proportion of cases in which a sentinel lymph node is identified; failed mapping is the opposite and refers to cases in which no lymph node was detected. Numerous studies in the last decade have shown that SLN in endometrial cancer is reliable with regard to the negative predictive value and sensitivity in combination with ultrastaging.

In 2011 Ballester and colleagues published the results of the first prospective multicentre study worldwide on the detection rate and diagnostic accuracy of SLN in endometrial cancer (SENTI-ENDO study) [2]. All participating patients received a cervical injection of Tc99m on the preoperative day and a cervical injection of patent blue immediately before the surgical procedure. A total of 125 patients from nine centres were analysed in this study; preoperative lymphoscintigraphy detected sentinel lymph nodes in 94 of 118 patients (80%) [2]. Perioperative detection of the sentinel lymph nodes occurred in 77% (95% CI 69–83) of the sentinel lymph nodes from the right half of the pelvis and in 76% (95% CI 68–83) of the sentinel lymph nodes from the left half of the pelvis; the overall sentinel lymph node detection rate per patient was 89% (95% CI 82–93). Para-aortic sentinel lymph nodes were detected in five patients (4%); in the para-aortic region, a median two sentinel lymph nodes were identified and removed. Three patients had false-negative results, which led to a negative predictive value of 97% (95% CI 91–99) and a sensitivity of 84% (95% CI 62–95) [2].

In the FIRES study (a prospective, multicentre study), 344 patients with endometrial cancer were analysed in whom both SLN and SLNE were performed according to the NCCN algorithm [58]. Out of the 293 included patients in whom at least one sentinel lymph node was demonstrated, 37 patients with lymph node involvement were found. One of these 37 patients had negative sentinel lymph nodes but positive lymph nodes after SLNE, which led to a false-negative result [58]. The study resulted in a sensitivity of SLN of 97.2%, a negative predictive value of 99.7% and a false-negative rate of 2.8% [58]. A limitation of the study was the low bilateral detection rate of 52%, which was explained by the authors as the result of the low experience with SLN of the participating centres at the start of the study. However, the results of the FIRES study can only be extrapolated to patients with endometrial cancer in whom at least one sentinel lymph node can be demonstrated [58]. Overall in the FIRES study, no sentinel lymph nodes were identified in 47 patients and five of these patients (11%) had lymph node metastases. These results underscore the benefit of the NCCN sentinel lymph node algorithm for identification of all patients with endometrial cancer and lymph node metastases [11].

The results of the SENTI-ENDO and FIRES studies are corroborated by a meta-analysis of 55 studies with a total of 4915 patients with endometrial cancer [59]. The sensitivity of SLN for the detection of metastatic lymph nodes reached 96% in the meta-analysis with a combined negative predictive value of 99.7% [59]. The low false-negative rates in endometrial cancer are comparable to the detection rates in breast cancer. In patients with breast cancer, it is recommended that axillary lymphadenectomy can be omitted when the detection rate of the sentinel lymph nodes is >90% and a false-negative rate <5% can be confirmed [60]. Khoury-Collado et al. found that a sentinel lymph node detection rate of >90% can be achieved in endometrial cancer after 30 cases, with a false-negative rate of 0% [61].

Atypical Location of the Sentinel Lymph Nodes and Isolated Metastasis in the Para-Aortic Lymph Nodes

A further advantage of SLN is the possibility of identifying lymph nodes in atypical location [62]. In a study with 436 patients, 7.9% of the sentinel lymph nodes were identified in sites that are not included in the area of routine SLNE in endometrial cancer (located in the internal iliac vein area, presacral, parametrial) [62]. The sentinel lymph nodes were the only affected lymph nodes in 46.1% of cases mapped successfully, including 3 cases in which the atypically located lymph nodes were the only affected lymph nodes [62].

The rate of isolated para-aortic metastases after operative staging when pelvic lymph nodes are not affected is between 1–4% and is constant for low- and high-risk endometrial cancer [39, 63, 64]. The inability to diagnose extrapelvic disease manifestation therefore limits the accuracy of SLN. The use of a SLN algorithm, through exact mapping and inclusion of ultrastaging, could

lead to a fall in the rate of “genuine” isolated para-aortic metastases [57].

Sentinel Lymph Node Biopsy in High-Risk Endometrial Cancer

As long as 10 years ago, the authors of the SENTI-ENDO study concluded that SLN in endometrial cancer can represent a compromise between SLNE and omitting lymphadenectomy in patients with low- or intermediate-risk endometrial cancer [2]. Very recently, the results of the FIRES study underscored the acceptable accuracy of SLN in endometrial cancer in routine clinical practice [56]. Nevertheless, reservations were expressed with regard to extrapolating the results of low- and intermediate-risk endometrial cancer to patients with high-risk endometrial cancer and a higher prognostic risk for pelvic and para-aortic lymph node involvement [11]. The question of the safety of SLN in patients with high-risk endometrial cancer has been investigated in a number of observational and prospective studies.

The largest study to date that addresses the question of SLN in high-risk endometrial cancer is the prospective, multicentre (2 high-volume centres) SHREC study from Sweden [57]. Of the 257 patients with FIGO I–II high-risk endometrial cancer who were included in the study and analysed, 54 patients had pelvic lymph node metastases and 52 of the patients with lymph node metastases were identified correctly by the SLN algorithm that was used [57]. The study yielded a sensitivity of 100% and a negative predictive value of 100% for this SLN algorithm, and the bilateral detection rate was 95% [57]. Isolated para-aortic lymph node metastases were diagnosed in two patients (1%) [57]. The rate of para-aortic SLNE was 81% [57].

The results of the SHREC study are similar to the results of the high-risk subgroup (102 of 356 patients, 28.6%) from the FIRES study [56]. One false-negative sentinel lymph node was found among the 102 patients with high-risk endometrial cancer. The rate of para-aortic SLNE was also high in patients in this study and was performed in 74% of patients with high-risk endometrial cancer [56].

In a prospective study of 101 patients with high-risk endometrial cancer, the NCCN algorithm was used as a safe method with an overall detection rate of 89% and a bilateral detection rate of 58% [65]. One false-negative sentinel lymph node was found among 20 patients in whom at least one sentinel lymph node was detected. This resulted in a 5% false-negative rate and sensitivity of 95% in this high-risk population [65]. It was therefore confirmed again that the SLN procedure can identify affected lymph nodes when it was combined with a side-specific SLNE according to the NCCN algorithm [8]. In their group of 128 patients with high-risk endometrial cancer, Touhami et al. reported an overall sentinel lymph node detection rate of 89.8% and a bilateral detection rate of 63.2%. Among the cases with bilateral detection only one false-negative case was diagnosed, resulting in a sensitivity of 95.8% and a negative predictive value of 98.2% [66].

In a retrospective study of 412 patients with intermediate- and high-risk endometrial cancer, Ducie et al. compared the detection rates after SLN (202 patients) and SLNE (210 patients) [67]. The

NCCN algorithm was used in the SLN group. No significant difference was shown between the SLN group and SLNE group as regards the detection rate in FIGO stage IIIC and diagnosis of para-aortic lymph node metastasis [67]. Use of the NCCN algorithm in patients with intermediate- and high-risk endometrial cancer does not lead to a reduction in the overall detection rate of lymph node metastases after SLN compared with SLNE [67].

The Prognostic Significance of Isolated Tumour Cells and Micrometastases

With regard to the histopathological evaluation of the sentinel lymph nodes in endometrial cancer, Delpech et al. recommend the so-called “ultrastaging” protocol because of the small volume of tissue available for examination: a combination of haematoxylin-eosin (H&E) staining and immunohistochemical staining with an anti-cytokeratin antibody mixture (typically AE3 and AE4) [68]. Using the ultrastaging protocol for histopathological processing of the sentinel lymph nodes considerably increases the detection rate of isolated tumour cells (individual tumour cells or cell clusters with a maximum diameter of 0.2 mm) or micrometastases (cell clusters 0.2 to 2 mm in size) in patients with endometrial cancer compared with routine H&E results [69, 70]. The proportion of isolated tumour cells and micrometastases is more than 30% of lymph nodes affected by metastasis and is diagnosed especially in patients with endometrial cancer and a low risk of lymph node metastasis [71].

In the SENTI-ENDO studies, of the 16 patients with positive sentinel lymph nodes, only 7 patients had lymph node metastases that were diagnosed by conventional H&E staining, and in 9 patients the lymph node metastases were diagnosed by ultrastaging [2]. The addition of ultrastaging of the sentinel lymph nodes also discovers those patients with micrometastases in the subgroup of patients with low-risk endometrial cancer [2, 72].

In a multicentre, retrospective study of 304 patients with low- and intermediate-risk endometrial cancer, significantly more (SLN group 16.2% vs. SLNE group 5.1%) involved lymph nodes were found by the SLN method and using ultrastaging, and the false-negative rate of SLN was 0% [68]. By using ultrastaging the indications for adjuvant therapy were extended for patients with micrometastases and performing SLN had no influence on recurrence-free survival [68].

In the largest study to date on the prognostic significance of isolated tumour cells and micrometastases in endometrial cancer 23 (2.7%) patients with isolated tumour cells, 21 (2.5%) patients with micrometastases and 47 (5.6%) patients with macrometastases in the lymph nodes were described out of a total population of 844 patients [73]. Of these, 83% of the patients with isolated tumour cells, 81% of the patients with micrometastases and 89% of the patients with macrometastases received adjuvant chemotherapy [73]. The recurrence-free 3-year survival was significantly better for patients with isolated tumour cells (86%) and patients with micrometastases (86%) compared with patients with macrometastases (71%) and comparable with the outcome of node-negative patients (90%) [73].

A recently published study focussed especially on the influence of adjuvant therapy on isolated tumour cells in sentinel lymph nodes of patients with endometrial cancer [74]. After ultrastaging, 31 (36%) patients with isolated tumour cells were described out of a total of 519 patients. Eleven (35%) patients received adjuvant therapy in the form of chemotherapy and percutaneous radiotherapy, 10 (32%) patients were given percutaneous radiotherapy and 10 (32%) patients had brachytherapy or oncological follow-up only [74]. In this study, too, the recurrence-free 3-year survival was significantly better for patients with isolated tumour cells (96%) and patients with micrometastases (88%) compared with patients with macrometastases (59%) and comparable to the outcome of node-negative patients (86%) [74]. No recurrences were recorded in the group of patients with isolated tumour cells who had brachytherapy or oncological follow-up only [74].

The combination of SLN with the ultrastaging protocol improves the sensitivity of staging in endometrial cancer and enables adjuvant therapy to be adjusted individually. Patients with endometrial cancer and isolated tumour cells in the sentinel lymph nodes have a similarly good prognosis as patients without lymph node involvement. The indication for adjuvant therapy should be established in these cases depending on uterine risk factors [71, 74]. Patients with isolated tumour cells in the sentinel lymph nodes and low-risk endometrial cancer probably do not benefit to a great degree from an additional adjuvant component. However, the prognostic significance of the isolated tumour cells and micrometastases in endometrial cancer remains unclear [75]. The data so far support the adjuvant treatment of patients with micrometastases in a similar way to patients with macrometastases, especially because most of these lesions are not identified by conventional histopathological methods [11].

The Prognostic Status of Sentinel Lymph Node Biopsy

The prognostic status of SLN alone compared with SLNE as part of surgical staging of endometrial cancer has not yet been adequately defined.

In a study of patients with uterine carcinosarcoma, SLN (according to the NCCN algorithm) and SLNE were compared [76]. A total of 136 patients were studied; 48 patients had staging with SLN and 88 patients had pelvic and/or para-aortic SLNE. No significant difference was found between the two groups in median progression-free survival [76]. In a follow-up analysis of the multicentre SENTI-ENDO study, low- and intermediate-risk patients were studied for their long-term course and the influence of SLN on survival [77]. In the 111 patients in whom a sentinel lymph node was detected, no significant difference was shown in recurrence-free survival, independent of whether or not lymph node involvement was present [77].

In another study, the staging results of patients with SLNE (n = 661) and patients with SLN followed by SLNE (n = 119) were compared retrospectively [69]. Despite similar risk factors, significantly more lymph node metastases (30.3 vs. 16.4%) were found in the SLN group and more patients received adjuvant therapy (28.6 vs. 16.3%) than in the SLNE group. The sentinel lymph node

was the only metastasis in 18 (50%) cases and ultimately showed that SLN combined with SLNE significantly increases the detection rate of pelvic lymph node metastases [69].

A recent systematic review included 3536 patients (1249 patients with SLN and 2287 patients with SLNE) from 6 studies [78]. Compared with the SLNE group, significantly more affected lymph nodes were diagnosed in the SLN group (9.9 vs. 14.7%); as regards detection of affected para-aortic lymph nodes no significant difference was found between the two groups [78]. The difference in overall recurrence rate between the two groups was not significant and was 4.3% after SLN and 7.3% after SLNE; the rate of lymph node recurrence also did not differ significantly between the two groups (1.2% after SLN vs. 1.7% after SLNE) [78].

The problem of oncological outcome after SLN compared with SLNE was the particular focus in recent years of a research collaboration between the Mayo Clinic, (Rochester, MN) and the Memorial Sloan Kettering Cancer Center (MSKCC) (New York, NY). In this collaboration, two cohorts of patients with endometrial cancer who had been treated at the two institutions were compared: patients from the MSKCC after SLN according to the NCCN algorithm (between 2006 and 2013) and a cohort of patients from the Mayo Clinic with endometrial cancer who had SLNE between 2004 and 2008 were included in the respective analyses. Zahl Eriksson et al. in a study compared SLN and SLNE in patients with low-risk endometrial cancer [79]. 1135 patients in total were included in this study; 642 patients had SLN and 493 had SLNE. In the SLN group, significantly more patients were diagnosed with pelvic lymph node metastases compared with the SLNE group (5.1 vs. 2.6%), and the rate of para-aortic lymph node metastases was comparable in the two groups (0.8 vs. 1%) [79]. The recurrence-free 3-year survival rate did not differ statistically significantly between the two cohorts and was 94.9% in the SLN group and 96.6% in the SLNE group [79]. In another study, Schlappe et al. investigated the oncological outcomes after SLN compared with SLNE in patients with endometrial cancer and myometrial invasion depth > 50%. The study included 176 patients; 82 had SLN and 94 had SLNE [80]. 9.8% of the patients from the SLN group and 29.8% of the patients from the SLNE group did not receive any adjuvant therapy. In a multivariate analysis, the authors found no difference between the staging method and recurrence and no influence of the staging method (SLN vs. SLNE) on overall survival in the entire cohort [80]. With reference exclusively to the node-negative patients, no difference was found between the two groups with regard to progression-free survival [80]. Another recent study also analysed the outcome after SLN vs. SLNE in patients with clear-cell and serous endometrial cancer [81]. This study included 214 patients, of whom 118 had SLN and 96 had SLNE. The proportion of patients who had received adjuvant therapy was significantly higher in the SLN group at 84 vs. 40% [81]. The recurrence-free 3-year survival was significantly lower in the SLN group (69%) vs. the SLNE group (80%) but the 3-year overall survival did not differ statistically significantly between the two groups (88% SLN vs. 77% SLNE) [81]. It was also shown in this study that performing SLN does not have any negative influence on the overall survival of patients with endometrial cancer compared with SLNE. Finally, Multinu et al. analysed the outcome after SLN vs. SLNE in patients with FIGO stage IIIC endometrial cancer without bulky disease

[82]. The use of the NCCN SLN algorithm had no negative influence on survival in patients with affected lymph nodes without bulky disease, compared with SLNE; the factors determining prognosis were the aggressive histopathological characteristics of the primary tumour [82]. Another controversial aspect in the discussion of SLN is the question of whether patients with positive sentinel lymph nodes benefit from completion of staging by SLNE. In this study by Multinu et al. there was no difference with regard to progression in the area of the lymph nodes between the SLN and the SLNE group. Thus, completing SLNE alone might not represent adequate therapy to prevent lymphatic dissemination [82]. Adjuvant therapy (chemotherapy and/or radiotherapy) appears to have at least partially a positive effect on residual tumour in the lymph nodes after limited staging [82]. If these results are confirmed in prospective studies, this therapeutic effect of adjuvant therapy could play an important role in future decisions regarding the extent of lymph node staging in endometrial cancer [82].

In a retrospective analysis from two centres in Italy, Buda et al. examined the influence on survival of algorithm-based SLN and SLNE [75]. The study included 802 patients with FIGO stage I endometrial cancer. In this study, no difference in recurrence-free survival was found between three staging strategies (SLN, SLNE, SLN and SLNE) [75]. However, more pelvic lymph node metastases were detected by SLN (16.7% after SLN vs. 7.3% after SLNE) [75].

Conclusion

Surgical lymph node staging is one of the most important factors for determining adjuvant therapy for patients with endometrial cancer. The use of SLN has revolutionised the surgical therapy of patients with breast cancer and melanoma so the potential advantages of using SLN in endometrial cancer are countless. The possibility of lymph node staging by SLN while avoiding SLNE leads to a significant reduction in the rate of peri- and postoperative morbidity.

The number of clinical studies that compare the recurrence pattern and survival of patients with endometrial cancer after SLN or pelvic and para-aortic SLNE is relatively small. As regards the prognostic status of SLN, the algorithm-based SLN does not appear to be inferior to SLNE in detecting affected para-aortic lymph nodes and specific recurrence rates (overall recurrence rate and lymph node recurrence). With regard to detection of affected pelvic lymph nodes, SLN appears to be superior to SLNE according to the current data. The prognostic significance of isolated tumour cells and micrometastases in endometrial cancer remains unclear.

Further prospective randomised studies, including the molecular pathology risk profile of endometrial cancer, are essential for better assessment of the long-term effectiveness of SLN, especially in patients with high-risk cancers. According to the recommendation of the current DKG-DKH-AWMF S3 guideline, SLN alone should be performed in endometrial cancer only in controlled studies [5]. Based on the recent data, a new version of the DKG-DKH-AWMF guideline could contain the evaluation regarding the applicability of the available SLN algorithms (for low-, intermediate- and high-risk endometrial cancer).

Conflict of Interest

The authors declare that they have no conflict of interest.

References

- [1] Accessed December 29, 2020 at: https://www.krebsdaten.de/Krebs/DE/Content/Publikationen/Krebs_in_Deutschland/kid_2019/kid_2019_c54_c55_gebaermutterkoerper.pdf?__blob=publicationFile
- [2] Ballester M, Dubernard G, Lecuru F et al. Detection rate and diagnostic accuracy of sentinel-node biopsy in early stage endometrial cancer: A prospective multicentre study (SENTI-ENDO). *Lancet Oncol* 2011; 12: 469–476
- [3] Abu-Rustum NR, Zhou Q, Iasonos A et al. The revised 2009 FIGO staging system for endometrial cancer: should the 1988 FIGO stages IA and IB be altered? *Int J Gynecol Cancer* 2011; 21: 511–516
- [4] Holloway RW, Abu-Rustum NR, Backes FJ et al. Sentinel Lymph Node Mapping and Staging in Endometrial Cancer: A Society of Gynecologic Oncology Literature Review with Consensus Recommendations. *Gynecol Oncol* 2017; 146: 405–415
- [5] Emons G, Steiner E, Vordermark D et al. Interdisciplinary Diagnosis, Therapy and Follow-up of Patients with Endometrial Cancer. Guideline (S3-Level, AWMF Registry Number 032/034-OL, April 2018) – Part 1 with Recommendations on the Epidemiology, Screening, Diagnosis and Hereditary Factors of Endometrial Cancer. *Geburtshilfe Frauenheilkd* 2018; 78: 949–971
- [6] Emons G, Steiner E, Vordermark D et al. Interdisciplinary Diagnosis, Therapy and Follow-up of Patients with Endometrial Cancer. Guideline (S3-Level, AWMF Registry Number 032/034-OL, April 2018) – Part 2 with Recommendations on the Therapy and Follow-up of Endometrial Cancer, Palliative Care, Psycho-oncological/Psychosocial Care/Rehabilitation/Patient Information and Healthcare Facilities. *Geburtshilfe Frauenheilkd* 2018; 78: 1089–1109
- [7] Accessed January 05, 2021 at: https://www.awmf.org/uploads/tx_szleitlinien/032-034OL_S3_Endometriumkarzinom-Diagnostik-Therapie-Nachsorge_2018-04.pdf
- [8] Koh WJ, Abu-Rustum NR, Bean S et al. Uterine Neoplasms, Version 1.2018, NCCN Clinical Practice Guidelines in Oncology. *J Natl Compr Canc Netw* 2018; 16: 170–199
- [9] Casarin J, Multinu F, Abu-Rustum N et al. Factors influencing the adoption of the sentinel lymph node technique for endometrial cancer staging: an international survey of gynecologic oncologists. *Int J Gynecol Cancer* 2019; 29: 60–67
- [10] Colombo N, Creutzberg C, Amant F et al. ESMO-ESGO-ESTRO Endometrial Consensus Conference Working Group. *Ann Oncol* 2016; 27: 16–41
- [11] Rossi EC. Current state of sentinel lymph nodes for women with endometrial cancer. *Int J Gynecol Cancer* 2019; 29: 613–621
- [12] Sueoka K, Umayahara K, Abe A et al. Prognosis for endometrial cancer patients treated with systematic pelvic and para-aortic lymphadenectomy followed by platinum-based chemotherapy. *Int J Gynecol Cancer* 2015; 25: 81–86
- [13] Randall ME, Filiaci VL, Muss H et al. Randomized phase III trial of whole-abdominal irradiation versus doxorubicin and cisplatin chemotherapy in advanced endometrial carcinoma: a Gynecologic Oncology Group Study. *J Clin Oncol* 2006; 24: 36–44
- [14] Benedetti Panici P, Basile S, Maneschi F et al. Systematic pelvic lymphadenectomy vs. no lymphadenectomy in early-stage endometrial carcinoma: Randomized clinical trial. *J Natl Cancer Inst* 2008; 100: 1707–1716
- [15] Kitchener H, Swart AM, Qian Q et al. Efficacy of systematic pelvic lymphadenectomy in endometrial cancer (MRC ASTEC trial): A randomised study. *Lancet* 2009; 373: 125–136

- [16] Eltabbakh GH, Piver MS, Hempling RE et al. Excellent long-term survival and absence of vaginal recurrences in 332 patients with low-risk stage I endometrial adenocarcinoma treated with hysterectomy and vaginal brachytherapy without formal staging lymph node sampling: report of a prospective trial. *Int J Radiat Oncol Biol Phys* 1997; 38: 373–380
- [17] Mariani A, Webb MJ, Keeney GL et al. Low-risk corpus cancer: is lymphadenectomy or radiotherapy necessary? *Am J Obstet Gynecol* 2000; 182: 1506–1519
- [18] Dowdy SC, Borah BJ, Bakkum-Gamez JN et al. Prospective assessment of survival, morbidity, and cost associated with lymphadenectomy in low-risk endometrial cancer. *Gynecol Oncol* 2012; 127: 5–10
- [19] Bendifallah S, Koskas M, Ballester M et al. The survival impact of systematic lymphadenectomy in endometrial cancer with the use of propensity score matching analysis. *Am J Obstet Gynecol* 2012; 206: 500.e1–500.e11
- [20] Todo Y, Kato H, Kaneuchi M et al. Survival effect of para-aortic lymphadenectomy in endometrial cancer (SEPAL study): a retrospective cohort analysis. *Lancet* 2010; 375: 1165–1172
- [21] Kuroda K, Yamamoto Y, Yanagisawa M et al. Risk factors and a prediction model for lower limb lymphedema following lymphadenectomy in gynecologic cancer: a hospital-based retrospective cohort study. *BMC Womens Health* 2017; 17: 50
- [22] Polan RM, Rossi EC, Barber EL. Extent of lymphadenectomy and postoperative major complications among women with endometrial cancer treated with minimally invasive surgery. *Am J Obstet Gynecol* 2019; 220: 263.e1–263.e8
- [23] Cabanas RM. An approach for the treatment of penile carcinoma. *Cancer* 1977; 39: 456–466
- [24] Zivanovic O, Khoury-Collado F, Abu-Rustum NR et al. Sentinel lymph node biopsy in the management of vulvar carcinoma, cervical cancer, and endometrial cancer. *Oncologist* 2009; 14: 695–705
- [25] Sahbai S, Fiz F, Taran F et al. Influence of 99m-Tc-Nanocolloid Activity Concentration on Sentinel Lymph Node Detection in Endometrial Cancer: A Quantitative SPECT/CT Study. *Diagnostics (Basel)* 2020; 10: 700
- [26] Perrone AM, Casadio P, Formelli G et al. Cervical and hysteroscopic injection for identification of sentinel lymph node in endometrial cancer. *Gynecol Oncol* 2008; 111: 62–67
- [27] Robova H, Charvat M, Strnad P et al. Lymphatic mapping in endometrial cancer: Comparison of hysteroscopic and subserosal injection and the distribution of sentinel lymph nodes. *Int J Gynecol Cancer* 2009; 19: 391–394
- [28] Mücke J, Klapdor R, Schneider M et al. Isthmocervical labelling and SPECT/CT for optimized sentinel detection in endometrial cancer: Technique, experience and results. *Gynecol Oncol* 2014; 134: 287–292
- [29] Burke TW, Levenback C, Tornos C et al. Intraabdominal lymphatic mapping to direct selective pelvic and paraaortic lymphadenectomy in women with high-risk endometrial cancer: results of a pilot study. *Gynecol Oncol* 1996; 62: 169–173
- [30] Holub Z, Kliment L, Lukác J et al. Laparoscopically-assisted intraoperative lymphatic mapping in endometrial cancer: preliminary results. *Eur J Gynaecol Oncol* 2001; 22: 118–121
- [31] Echt ML, Finan MA, Hoffman MS et al. Detection of sentinel lymph nodes with lymphazurin in cervical, uterine, and vulvar malignancies. *South Med J* 1999; 92: 204–208
- [32] Altgassen C, Pagenstecher J, Hornung D et al. A new approach to label sentinel nodes in endometrial cancer. *Gynecol Oncol* 2007; 105: 457–461
- [33] Li B, Li XG, Wu LY et al. A pilot study of sentinel lymph nodes identification in patients with endometrial cancer. *Bull Cancer* 2007; 94: E1–E4
- [34] Niikura H, Kaiho-Sakuma M, Tokunaga H et al. Tracer injection sites and combinations for sentinel lymph node detection in patients with endometrial cancer. *Gynecol Oncol* 2013; 131: 299–303
- [35] Sawicki S, Lass P, Wydra D. Sentinel Lymph Node Biopsy in Endometrial Cancer—Comparison of 2 Detection Methods. *Int J Gynecol Cancer* 2015; 25: 1044–1050
- [36] Sahbai S, Taran FA, Fiz F et al. Pericervical Injection of 99mTc-Nanocolloid Is Superior to Peritumoral Injection for Sentinel Lymph Node Detection of Endometrial Cancer in SPECT/CT. *Clin Nucl Med* 2016; 41: 927–932
- [37] Zuo J, Wu LY, Cheng M et al. Comparison Study of Laparoscopic Sentinel Lymph Node Mapping in Endometrial Carcinoma Using Carbon Nanoparticles and Lymphatic Pathway Verification. *J Minim Invasive Gynecol* 2019; 26: 1125–1132
- [38] Abu-Rustum NR, Khoury-Collado F, Pandit-Taskar N et al. Sentinel lymph node mapping for grade 1 endometrial cancer: is it the answer to the surgical staging dilemma? *Gynecol Oncol* 2009; 113: 163–163
- [39] Abu-Rustum NR, Gomez JD, Alektiar KM et al. The incidence of isolated paraaortic nodal metastasis in surgically staged endometrial cancer patients with negative pelvic lymph nodes. *Gynecol Oncol* 2009; 115: 236–238
- [40] Accessed January 07, 2021 at: <https://www.fda.gov/media/124115/download>
- [41] Frumovitz M, Plante M, Lee PS et al. Near-infrared fluorescence for detection of sentinel lymph nodes in women with cervical and uterine cancers (FILM): a randomised, phase 3, multicentre, non-inferiority trial. *Lancet Oncol* 2018; 19: 1394–1403
- [42] Kessous R, How J, Abitbol J et al. Triple tracer (blue dye, indocyanine green, and Tc99) compared to double tracer (indocyanine green and Tc99) for sentinel lymph node detection in endometrial cancer: a prospective study with random assignment. *Int J Gynecol Cancer* 2019; 29: 1121–1125
- [43] Cabrera S, Bebia V, Franco-Camps S et al. Technetium-99 m-indocyanine green versus technetium-99 m-methylene blue for sentinel lymph node biopsy in early-stage endometrial cancer. *Int J Gynecol Cancer* 2020; 30: 311–317
- [44] Thomaier L, Jager L, Stone R et al. Risk of empty lymph node packets in sentinel lymph node mapping for endometrial cancer using indocyanine green. *Int J Gynecol Cancer* 2019; 29: 513–517
- [45] Holloway RW, Bravo RA, Rakowski JA et al. Detection of sentinel lymph nodes in patients with endometrial cancer undergoing robotic-assisted staging: a comparison of colorimetric and fluorescence imaging. *Gynecol Oncol* 2012; 126: 25–29
- [46] Sinno AK, Fader AN, Roche KL et al. A comparison of colorimetric versus fluorometric sentinel lymph node mapping during robotic surgery for endometrial cancer. *Gynecol Oncol* 2014; 134: 281–286
- [47] How J, Gotlieb WH, Press JZ et al. Comparing indocyanine green, technetium, and blue dye for sentinel lymph node mapping in endometrial cancer. *Gynecol Oncol* 2015; 137: 436–442
- [48] Buda A, Crivellaro C, Elisei F et al. Impact of Indocyanine Green for Sentinel Lymph Node Mapping in Early Stage Endometrial and Cervical Cancer: Comparison with Conventional Radiotracer (99m)Tc and/or Blue Dye. *Ann Surg Oncol* 2016; 23: 2183–2191
- [49] Papadia A, Zapardiel I, Bussi B et al. Sentinel lymph node mapping in patients with stage I endometrial carcinoma: a focus on bilateral mapping identification by comparing radiotracer Tc99 m with blue dye versus indocyanine green fluorescent dye. *J Cancer Res Clin Oncol* 2017; 143: 475–480
- [50] Eriksson AG, Beavis A, Soslow RA et al. A Comparison of the Detection of Sentinel Lymph Nodes Using Indocyanine Green and Near-Infrared Fluorescence Imaging Versus Blue Dye During Robotic Surgery in Uterine Cancer. *Int J Gynecol Cancer* 2017; 27: 743–747
- [51] Holloway RW, Ahmad S, Kendrick JE et al. A prospective cohort study comparing colorimetric and fluorescent imaging for sentinel lymph node mapping in endometrial cancer. *Ann Surg Oncol* 2017; 24: 1972–1979

- [52] Rozenholc A, Samouelian V, Warkus T et al. Green versus blue: Randomized controlled trial comparing indocyanine green with methylene blue for sentinel lymph node detection in endometrial cancer. *Gynecol Oncol* 2019; 153: 500–504
- [53] Backes FJ, Cohen D, Salani R et al. Prospective clinical trial of robotic sentinel lymph node assessment with isosulfane blue (ISB) and indocyanine green (ICG) in endometrial cancer and the impact of ultrastaging (NCT01818739). *Gynecol Oncol* 2019; 153: 496–499
- [54] Schreuder HW, Oei G, Maas M et al. Implementation of simulation in surgical practice: minimally invasive surgery has taken the lead: the Dutch experience. *Med Teach* 2011; 33: 105–115
- [55] Khoury-Collado F, St Clair C, Abu-Rustum NR. Sentinel Lymph Node Mapping in Endometrial Cancer: An Update. *Oncologist* 2016; 21: 461–466
- [56] Casarin J, Multinu F, Tortorella L et al. Sentinel lymph node biopsy for robotic-assisted endometrial cancer staging: further improvement of perioperative outcomes. *Int J Gynecol Cancer* 2020; 30: 41–47
- [57] Persson J, Salehi S, Bollino M et al. Pelvic Sentinel lymph node detection in high-risk Endometrial Cancer (SHREC-trial)-the final step towards a paradigm shift in surgical staging. *Eur J Cancer* 2019; 116: 77–85
- [58] Rossi EC, Kowalski LD, Scalici J et al. A comparison of sentinel lymph node biopsy to lymphadenectomy for endometrial cancer staging (FIRES trial): A multicentre, prospective, cohort study. *Lancet Oncol* 2017; 18: 384–392
- [59] Bodurtha Smith AJ, Fader AN, Tanner EJ. Sentinel lymph node assessment in endometrial cancer: a systematic review and meta-analysis. *Am J Obstet Gynecol* 2017; 216: 459–476
- [60] Simmons RM. Review of sentinel lymph node credentialing: how many cases are enough? *J Am Coll Surg* 2001; 193: 206–209
- [61] Khoury-Collado F, Glaser GE, Zivanovic O et al. Improving sentinel lymph node detection rates in endometrial cancer: how many cases are needed? *Gynecol Oncol* 2009; 115: 453–455
- [62] How J, Boldeanu I, Lau S et al. Unexpected locations of sentinel lymph nodes in endometrial cancer. *Gynecol Oncol* 2017; 147: 18–23
- [63] Altay A, Toptas T, Dogan S et al. Analysis of Metastatic Regional Lymph Node Locations and Predictors of Para-aortic Lymph Node Involvement in Endometrial Cancer Patients at Risk for Lymphatic Dissemination. *Int J Gynecol Cancer* 2015; 25: 657–664
- [64] Salehi S, Avall-Lundqvist E, Legerstam B et al. Robot-assisted laparoscopy versus laparotomy for infrarenal paraaortic lymphadenectomy in women with high-risk endometrial cancer: a randomised controlled trial. *Eur J Cancer* 2017; 79: 81–89
- [65] Soliman PT, Westin SN, Dioun S et al. A prospective validation study of sentinel lymph node mapping for high-risk endometrial cancer. *Gynecol Oncol* 2017; 146: 234–239
- [66] Touhami O, Grégoire J, Renaud MC et al. Performance of sentinel lymph node (SLN) mapping in high-risk endometrial cancer. *Gynecol Oncol* 2017; 147: 549–553
- [67] Ducie JA, Eriksson AGZ, Ali N et al. Comparison of a sentinel lymph node mapping algorithm and comprehensive lymphadenectomy in the detection of stage IIIC endometrial carcinoma at higher risk for nodal disease. *Gynecol Oncol* 2017; 147: 541–548
- [68] Delpech Y, Cortez A, Coutant C et al. The sentinel node concept in endometrial cancer: histopathologic validation by serial section and immunohistochemistry. *Ann Oncol* 2007; 18: 1799–1803
- [69] Holloway RW, Gupta S, Stavitzki NM et al. Sentinel lymph node mapping with staging lymphadenectomy for patients with endometrial cancer increases the detection of metastasis. *Gynecol Oncol* 2016; 141: 206–210
- [70] Raimond E, Ballester M, Hudry D et al. Impact of sentinel lymph node biopsy on the therapeutic management of early-stage endometrial cancer: Results of a retrospective multicenter study. *Gynecol Oncol* 2014; 133: 506–511
- [71] Bogani G, Mariani A, Paolini B et al. Low-volume disease in endometrial cancer: The role of micrometastasis and isolated tumor cells. *Gynecol Oncol* 2019; 153: 670–675
- [72] Kim CH, Soslow RA, Park KJ et al. Pathologic ultrastaging improves micrometastasis detection in sentinel lymph nodes during endometrial cancer staging. *Int J Gynecol Cancer* 2013; 23: 964–970
- [73] St Clair CM, Eriksson AG, Ducie JA et al. Low-Volume Lymph Node Metastasis Discovered During Sentinel Lymph Node Mapping for Endometrial Carcinoma. *Ann Surg Oncol* 2016; 23: 1653–1659
- [74] Plante M, Stanleigh J, Renaud MC et al. Isolated tumor cells identified by sentinel lymph node mapping in endometrial cancer: Does adjuvant treatment matter? *Gynecol Oncol* 2017; 146: 240–246
- [75] Buda A, Di Martino G, Restaino S et al. The impact on survival of two different staging strategies in apparent early stage endometrial cancer comparing sentinel lymph nodes mapping algorithm and selective lymphadenectomy: An Italian retrospective analysis of two reference centers. *Gynecol Oncol* 2017; 147: 528–534
- [76] Schiavone MB, Zivanovic O, Zhou Q et al. Survival of patients with uterine carcinosarcoma undergoing sentinel lymph node mapping. *Ann Surg Oncol* 2016; 23: 196–202
- [77] Darai E, Dubernard G, Bats AS et al. Sentinel node biopsy for the management of early stage endometrial cancer: Long-term results of the SENTI-ENDO study. *Gynecol Oncol* 2015; 136: 54–59
- [78] Bogani G, Murgia F, Ditto F et al. Sentinel node mapping vs. lymphadenectomy in endometrial cancer: A systematic review and meta-analysis. *Gynecol Oncol* 2019; 153: 676–683
- [79] Zahl Eriksson AG, Ducie J, Ali N et al. Comparison of a sentinel lymph node and a selective lymphadenectomy algorithm in patients with endometrioid endometrial carcinoma and limited myometrial invasion. *Gynecol Oncol* 2016; 140: 394–399
- [80] Schlappe BA, Weaver AL, Ducie JA et al. Multicenter study comparing oncologic outcomes between two nodal assessment methods in patients with deeply invasive endometrioid endometrial carcinoma: A sentinel lymph node algorithm versus a comprehensive pelvic and paraaortic lymphadenectomy. *Gynecol Oncol* 2018; 151: 235–242
- [81] Schlappe BA, Weaver AL, McGree ME et al. Multicenter study comparing oncologic outcomes after lymph node assessment via a sentinel lymph node algorithm versus comprehensive pelvic and paraaortic lymphadenectomy in patients with serous and clear cell endometrial carcinoma. *Gynecol Oncol* 2020; 156: 62–69
- [82] Multinu F, Ducie JA, Eriksson AGZ et al. Role of lymphadenectomy in endometrial cancer with nonbulky lymph node metastasis: Comparison of comprehensive surgical staging and sentinel lymph node algorithm. *Gynecol Oncol* 2019; 155: 177–185