

The Ductus Venosus

Der Ductus venosus

Author

Markus Born

Affiliation

Department of Radiology, Division of Pediatric Radiology,
University Hospital Bonn, Germany

Key words

ductus venosus, portosystemic shunt, umbilical vein catheter

received 11.05.2020

accepted 18.09.2020

published online 05.11.2020

Bibliography

Fortschr Röntgenstr 2021; 193: 521–526

DOI 10.1055/a-1275-0984

ISSN 1438-9029

© 2020. Thieme. All rights reserved.

Georg Thieme Verlag KG, Rüdigerstraße 14,
70469 Stuttgart, Germany

Correspondence

Dr. Markus Born

Radiology, Pediatric Radiology, University of Bonn,
Venusberg-Campus 1, 53127 Bonn, Deutschland

Tel.: +49/2 28/28 73 32 25

Fax: +49/2 28/28 73 35 66

mark.born@ukbonn.de

ABSTRACT

Background the ductus venosus (DV) is not well known in general radiology, but it plays a role in the daily work of pediatric radiologists. Consequently all general radiologists who also care for a pediatric department should be familiar with the physiological and pathological findings related to the DV. **Methods:** Literature research in Medline, using the keywords “ductus venosus” and “umbilical vein catheter”.

Results and conclusions In the first weeks of life the DV is regularly still patent. It should be recognized as DV and not be mistaken for a pathological portosystemic shunt. The ductus venosus is the lead structure for umbilical vein catheters. Radiologists should be able to assess the correct catheter position. Radiologically important findings of an umbilical vein catheter are mainly malposition and intrahepatic extravasa-

tion. Agenesis of the DV can lead to intra- or extrahepatic compensatory portosystemic shunts, in which as well as in the case of persistent patency of the DV, there may be the necessity for radiological-interventional or surgical occlusion.

Key points:

- In the first weeks of life in infants the Ductus venosus is regularly still patent.
- The Ductus venosus should not be mistaken for a pathological portosystemic shunt.
- An umbilical vein catheter should project onto the Ductus venosus and end caudal to the right atrium.
- Intrahepatic portosystemic shunts in DV agenesis show a high rate of spontaneous closure postnatally.

Citation Format

- Born M. The Ductus Venosus. Fortschr Röntgenstr 2021; 193: 521–526

ZUSAMMENFASSUNG

Hintergrund Der Ductus venosus ist in der Allgemeinradiologie wenig bekannt, spielt aber in der kinderradiologischen Diagnostik durchaus eine Rolle, sodass auch Allgemeinradiologen, die eine pädiatrische Abteilung mitversorgen, die physiologischen und pathologischen Befunde im Zusammenhang mit dem D. venosus kennen sollten. **Methoden:** Literatursuche in MEDLINE nach den Stichworten „ductus venosus“ und „umbilical venous catheter“.

Ergebnisse und Schlussfolgerungen In den ersten Lebenswochen ist der DV noch offen. Er sollte als solcher erkannt und nicht mit einem pathologischen portosystemischen Shunt verwechselt werden. Der Ductus venosus ist Leitstruktur bei der Nabelvenenkatheteranlage, dessen korrekte Lage erkannt werden muss. Radiologisch bedeutsame Befunde eines Nabelvenenkatheters sind vor allem Fehllagen und intrahepatische Paravasate. Eine Agenesie des Ductus venosus kann zu intra- oder extrahepatischen kompensatorischen portosystemischen Shunts führen, bei denen in seltenen Fällen ebenso wie beim persistierenden Ductus venosus die Notwendigkeit eines radiologisch-interventionellen oder chirurgischen Verschlusses bestehen kann.

The Ductus Venosus

The ductus venosus (DV) plays only a minor role in general radiology, as it is a fetal structure that obliterates postnatally and is usually no longer present in adult physiology. For pediatric radiologists, on the other hand, questions requiring knowledge of the anatomy of the ductus venosus are part of everyday diagnostic practice. However, such issues can also be confronted in particular by general radiologists who also serve a pediatric facility. Thus knowledge of radiological imaging of the venous duct can also be important for general radiologists.

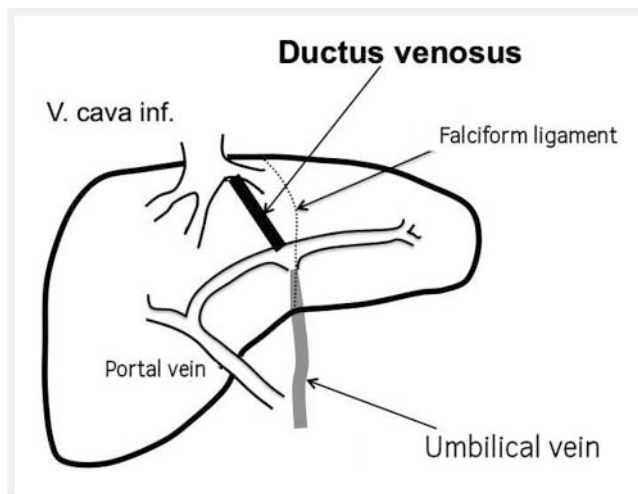
There are various issues that radiologists may face in connection with the ductus venosus. On the one hand, the ductus venosus is important in the postpartum placement of an umbilical vein catheter, where it serves as a guiding structure. Its position can be assessed by the radiologist on a conventional X-ray of the upper abdomen. Misplacement and other complications should be detected. On the other hand, due to the increasing use of MRI and CT, the patent DV is occasionally visualised as a secondary finding in neonates. It should be recognized as such and not be confused with a pathological portosystemic shunt. Also sonographically the DV should be reliably recognized. Thirdly, the radiologist can be called upon to assess pathologies of the ductus venosus, for example duct agenesis with the possible formation of compensatory intra- or extrahepatic shunt connections or a failing spontaneous closure of the ductus venosus.

The present article aims to provide an overview of the above mentioned imaging issues relating to the ductus venosus.

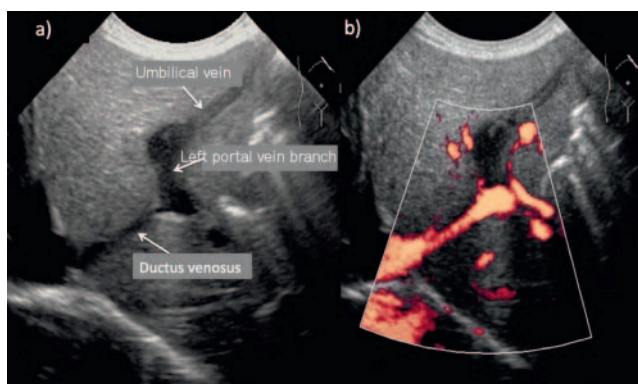
A literature search was carried out in Medline using the keywords “umbilical vein catheter” and “ductus venosus”. The studies thus found were used as a source of evidence for the quantitative data given in this article.

Anatomy and Physiology

The ductus venosus arantii, named after the Italian anatomist Giulio Cesare Aranzi (1530–1589), is a venous fetal intrahepatic shunt connection from the left portal vein to the inferior vena cava or the orifice of the left or middle hepatic vein. Its function is prenatal transport of oxygen-rich umbilical vein blood to the right atrium. The blood from the umbilical cord passes through the umbilical vein to the so-called recessus umbilicalis of the left portal vein, whence it connects to the DV (► Fig. 1). The DV may be slightly offset to the right compared to the umbilical vein in the left portal vein. In the human fetus, about 20–40% of the umbilical venous blood reach the DV in the second half of pregnancy [1–3]. Due to anatomical and hemodynamic conditions, the blood flow from the ductus venosus hardly mixes within the inferior vena cava with the blood coming from the lower half of the body and is channeled directly to the foramen ovale. Through this it reaches the left atrium and enters the systemic circulation where it supplies the developing brain of the fetus with oxygen-rich blood from the placenta [4]. The blood supplying the lower half of the fetus body is less rich in oxygen because it mixes caudal to the aortic arch with the less oxygenated blood from the ductus arteriosus [4].



► Fig. 1 Fetal anatomy of hepatic vessels.



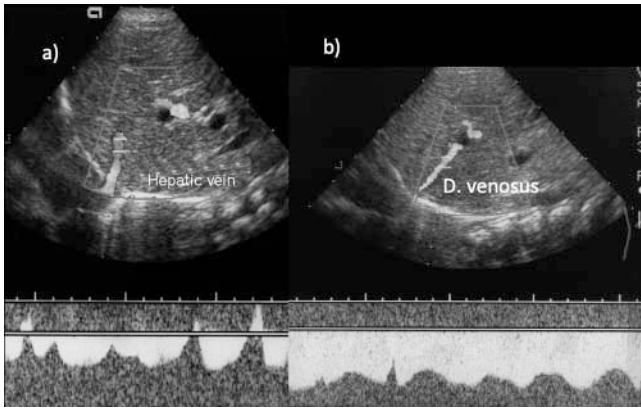
► Fig. 2 Sonographical visualisation of the DV in a nearly sagittal plane. a B-mode image, b colour-doppler mode.

After birth, the umbilical vein and ductus venosus are initially still patent and sonographically well recognizable in a slightly left-turned sagittal view (► Fig. 2).

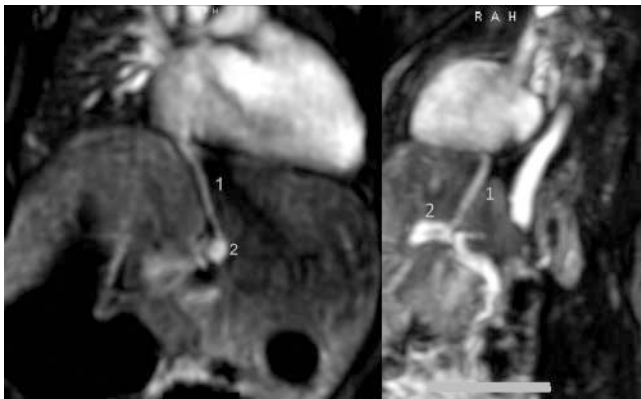
Due to the pressure gradient between the portal vein and the inferior vena cava, the flow in the DV derived via Doppler sonography is directed outwards from the liver with a relatively constant, only slightly modulated amplitude. It differs significantly from the stronger undulating flow in the hepatic veins influenced by cardiac activity as illustrated in ► Fig. 3. The flow in the hepatic veins can undulate even more than shown.

In full-term neonates, the DV closes in the first days or weeks after birth. According to literature it is closed after 7 days in 60 to 75% of cases, after 18 days in 89 to 100% [5, 6]. In premature infants, however, DV seems to close with a slight delay [7, 8].

Due to this early postpartum closure, the DV is rarely visible on MRI. With the increasing use of MRI in full-term and premature infants, however, it is sometimes shown as a patent shunt connection and should then be correctly recognized as a DV and not misinterpreted as a pathological portosystemic shunt (► Fig. 4).



► **Fig. 3** Sonographical view of the liver in a sagittal view. The flow profile of liver veins **a** is different from that of the DV **b**.



► **Fig. 4** Patent DV in a 3 days old girl. MRI, 3D FFE postcontrast. MIP-reconstruction in a coronal and sagittal plane (1 = DV, 2 = left portal vein).

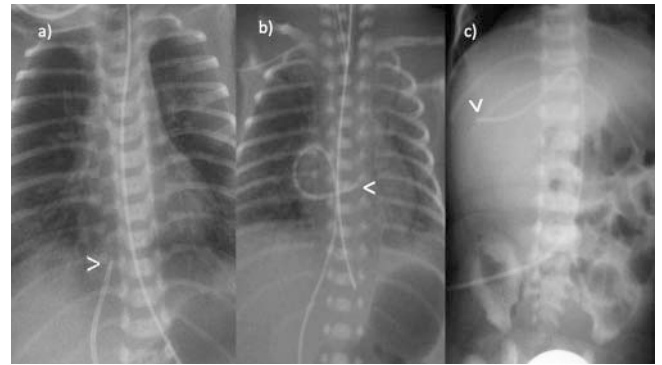
Umbilical Venous Catheter

The open DV enables the neonatologist to apply a central venous catheter postpartum via the umbilical vein (umbilical venous catheter = UVC), which should be identified as such by the radiologist and its position assessed. The catheter tip should project onto the inferior vena cava in the transition to the right atrium (► **Fig. 5a**) [9].

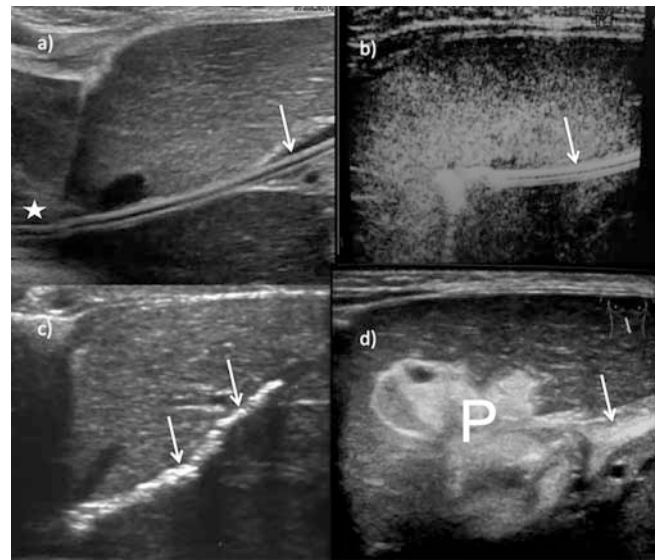
In addition to the occurrence of infections for which the catheter can serve as an entry portal, the main complications of a UVC are primary or migration-induced malpositions, thrombosis, perforations and catheter breaks [10, 11] (► **Fig. 5, 6**).

Umbilical venous catheter malposition

If the UVC is advanced too far, it reaches the right atrium; if advanced even further, it can reach the right ventricle, the superior vena cava, the coronary sinus or the left atrium via the still open oval foramen (► **Fig. 5, 6**). Cardiac malpositions carry the risk of arrhythmias, intracardiac thrombus formation, myocardial perforations with pericardial tamponade, etc., and should therefore be avoided [10].



► **Fig. 5** Umbilical vein catheter on plain film views. **a** normal position. The tip of the catheter (<) lies in the vena cava inferior caudad to the right atrium **b** malposition: the catheter ends in the right atrium **c** malposition: the catheter ends in the right portal vein.



► **Fig. 6** Sonographical view of an umbilical vein catheter and complications of the procedure. **a** malposition of the catheter (arrow): it reaches the right cardiac atrium (asterisk). **b** distal malposition. The catheter (arrow) does not reach the DV. **c** Calcifications (arrows) along the DV as a consequence of catheterization. **d** Intrahepatic paravasation (P) after perforation of the vessel wall. On the right hand side visualisation of the umbilical vein (arrow).

Intrahepatic malposition occurs when the catheter is not advanced far enough or does not enter the DV but deviates into the left or right branch of the portal vein (► **Fig. 5, 6**).

Due to the numerous possibilities of catheter malposition and potentially resulting complications, an X-ray is taken after each umbilical vein catheterization in order to assess the catheter position and correct it if necessary. However, catheter migration is frequently observed over time and can lead to a secondary catheter malposition after initial proper positioning [12, 13].

Perforations

Intrahepatic malpositions of the UVC predestine a perforation of the vascular system [14]. If this occurs intrahepatically, the

infused substances are extravasated into the liver parenchyma, which results in an image of an inhomogeneous, irregularly delimited mass (► Fig. 5) [9]. Depending on the infused fluid and the course over time, it can be echogenic or hypoechoic [9]. Sometimes communication with the umbilical vein can be detected, and over time this extravasation can calcify. If a perforation occurs in the umbilical vein, the infusion solutions applied through the catheter can lead to sonographically detectable free intra-abdominal fluid [11, 15, 16]. Likewise, intra-abdominal hemorrhages have been described [17].

Thrombi

Another complication that can occur after the application of a UVC is the formation of thrombi. Such thrombi can occur in the umbilical vein or in the ductus venosus [9]. Since these two vessels physiologically close after birth, thrombi are of no importance here. They can calcify over time and remain sonographically recognizable as linear echogenic structures (► Fig. 5). In the literature, however, thrombus formation after UVC placement is also described in other veins such as one of the portal vein branches [11, 18], in both portal vein branches or in the main portal vein trunk [10]. Although thrombi of the portal vein branches as a result of umbilical vein catheterization often recede [10, 18], portal hypertension can develop in the absence of spontaneous recanalization, with the corresponding consequences. Thromboembolic events also occur [10, 18].

Catheter breakage

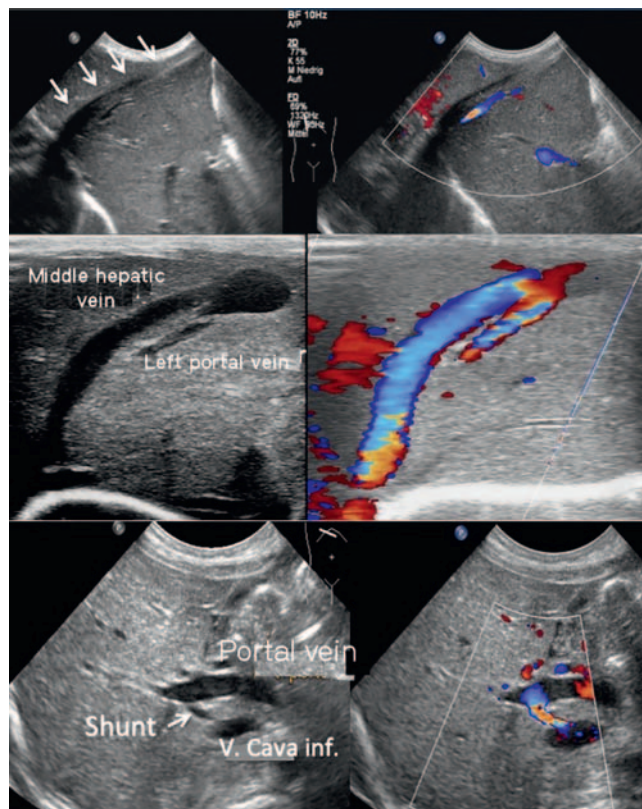
Umbilical vein catheter breakage is uncommon, but is described in the literature. The remaining intracorporal catheter fragment can usually be retrieved with radiographic support via a femoral venous access from the right atrium or via the umbilical vein, but surgical catheter retrieval is also described [19–21].

Ductus Venosus Pathologies

DV pathologies mainly include agenesis and failing closure.

Ductus venosus agenesis

There are no exact data regarding the frequency of DV agenesis. Agenesis of the DV can be completely asymptomatic in about 20% of cases and has a good prognosis in these cases [2], but it may also be associated with various other pathological changes including cardiac defects, chromosomal anomalies, the formation of portacaval shunts or portal vein agenesis [2]. The consequences may be fetal hydrops and fetal heart failure, so the prognosis in these cases is poor, and prenatal mortality, including the number of iatrogenic terminations of pregnancy, is high. In the case of DV agenesis, frequently associated abnormalities of the vascular system can be observed, through which the umbilical cord blood reaches the systemic circulation of the fetus. The umbilical vein can connect directly to the intrahepatic inferior vena cava instead of the left branch of the portal vein (► Fig. 7), or intrahepatic or extrahepatic portosystemic shunt connections can form. The frequency of a congenital portosystemic shunt is reported to be 1:30 000 births regardless of DV pathology [22]. In general, por-



► Fig. 7 Agenesia of dv. Upper row: ectopic course of the umbilical vein (arrows) connecting to the confluence of the liver veins. In this postnatal examination the umbilical vein is already closed. Middle row: Intrahepatic portosystemic shunt from the right portal vein to the middle liver vein. Due to the high flow volume the liver vein is substantially dilated. Lower row: short intrahepatic portosystemic shunt from the right portal vein to the inferior vena cava in an 8 days old girl with trisomy 21.

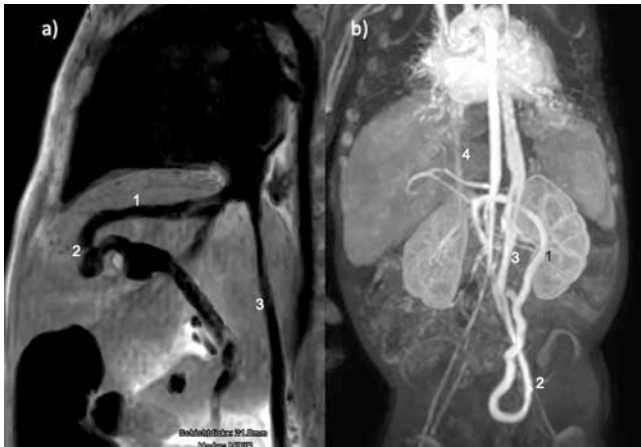
tosystemic shunts can be classified according to Morgan and Superina [23].

Intrahepatic portosystemic shunts can be well-visualized postnatally (► Fig. 8), and have a high spontaneous closure rate [2, 24–26]. However, they should be checked at greater intervals, since in the case of failing spontaneous closure, interventional or surgical closure may be necessary [2, 24]. A need for intervention arises if a shunt becomes symptomatic and leads to increasing levels of ammonia or galactose in the serum or to cardiological stress due to the shunt volume. Extrahepatic portosystemic shunts can close spontaneously, but may also have to be closed interventionally or surgically, depending on the symptoms.

Persistent DV

There are few reports in the literature regarding failing spontaneous closure of the DV within the first weeks of life [27].

Possible symptoms are: increased liver enzymes, increased levels of direct bilirubin, galactosemia, hyperammonemia and liver dysfunction up to and including liver failure and increased cardiac stress [27, 28]. An association with cardiac defects, especially pulmonary arterial hypertension, is also observed in up to 25% of



► **Fig. 8** **a** Intrahepatic portosystemic shunt. MRI with sagittal T2w MIP-reconstruction (1 = middle liver vein, 2 = shunt between portal vein and middle liver vein, 3 = inferior vena cava). **b** extrahepatic shunt with complex vessel malformation: collateral vein (1) from the lower mesenteric vein to pelvic veins (2). Drainage via left vena hemiazygos (3). Hypoplastic vena cava inferior (4).

cases [27]. Apparently prostaglandin medication and altered hemodynamics in pulmonary arterial hypertension contribute to keeping the DV patent [8, 27]. An association with liver masses has also been described [27].

Depending on the accompanying symptoms, a patent DV must be closed either by intervention or surgery. A multi-stage procedure may be necessary to avoid portal hypertension. Measurement of the portal venous pressure increase after temporary occlusion can be helpful here [29]. Interventional and surgical occlusion of persistent DV beyond infancy even through adulthood are also described in the literature with good success and normalization of liver enzymes and serum bilirubin or ammonia levels [29–31].

Conflict of Interest

The authors declare that they have no conflict of interest.

Literatur

- [1] Haugen G, Kiserud T, Godfrey K et al. Portal and umbilical venous blood supply to the liver in the human fetus near term. *Ultrasound Obstet Gynecol* 2004; 24: 599–605
- [2] Strizek B, Zamprakov A, Gottschalk I et al. Prenatal Diagnosis of Agenesis of Ductus Venosus: A Retrospective Study of Anatomic Variants, Associated Anomalies and Impact on Postnatal Outcome. *Ultraschall in Med* 2019; 40 (3): 333–339. doi:10.1055/s-0043-115109
- [3] Kiserud T. Hemodynamics of the ductus venosus. *Eur J Obstet Gynecol Reprod Biol* 1999; 84 (2): 139–147
- [4] Morton S, Brodsky D. Fetal Physiology and the Transition to Extrauterine Life. *Clin Perinatol* 2016; 43 (3): 395–407
- [5] Fugelseth D, Lindemann R, Liestøl K et al. Ultrasonographic study of ductus venosus in healthy neonates. *Arch Dis Child Fetal Neonatal Ed* 1997; 77 (2): F131–F134
- [6] Loberant N, Barak M, Gaitini D et al. Closure of the ductus venosus in neonates: findings on real-time gray-scale, color-flow Doppler, and duplex Doppler sonography. *Am J Roentgenol* 1992; 159 (5): 1083–1085
- [7] Kondo M, Itoh S, Kunikata T et al. Time of closure of ductus venosus in term and preterm neonates. *Arch Dis Child Fetal Neonatal Ed* 2001; 85 (1): F57–F59
- [8] Fugelseth D, Lindemann R, Liestøl K et al. Postnatal closure of ductus venosus in preterm infants < or = 32 weeks. An ultrasonographic study. *Early Hum Dev* 1998; 53 (2): 163–169
- [9] Schlesinger AE, Braverman RM, DiPietro MA. Pictorial essay. Neonates and umbilical venous catheters: normal appearance, anomalous positions, complications, and potential aid to diagnosis. *Am J Roentgenol* 2003; 180 (4): 1147–1153
- [10] Selvam S, Humphrey T, Woodley H et al. Sonographic features of umbilical catheter-related complications. *Pediatr Radiol* 2018; 48 (13): 1964–1970. doi:10.1007/s00247-018-4214-9
- [11] Derinkuyu BE, Boyunaga OL, Damar C et al. Hepatic Complications of Umbilical Venous Catheters in the Neonatal Period: The Ultrasound Spectrum. *J Ultrasound Med* 2018; 37 (6): 1335–1344. doi:10.1002/jum.14443
- [12] Hoellering A, Tshamala D, Davies MW. Study of movement of umbilical venous catheters over time. *J Paediatr Child Health* 2018; 54 (12): 1329–1335. doi:10.1111/jpc.14073.o
- [13] Franta J, Harabor A, Soraisham AS. Ultrasound assessment of umbilical venous catheter migration in preterm infants: a prospective study. *Arch Dis Child Fetal Neonatal Ed* 2017; 102 (3): F251–F255. doi:10.1136/archdischild-2016-311202
- [14] Grizelj R, Vukovic J, Bojanic K et al. Severe liver injury while using umbilical venous catheter: case series and literature review. *Am J Perinatol* 2014; 31 (11): 965–974. doi:10.1055/s-0034-1370346
- [15] Pegu S, Murthy P. Ascites with hepatic extravasation of total parenteral nutrition (TPN) secondary to umbilical venous catheter (UVC) malposition in an extremely preterm baby. *BMJ Case Rep* 2018; 2018: doi:10.1136/bcr-2018-22637
- [16] Hartley M, Rupp Mohanram G, Ahmed I. TPNoma: an unusual complication of umbilical venous catheter malposition. *Arch Dis Child Fetal Neonatal Ed* 2019; 104 (3): F326. doi:10.1136/archdischild-2018-315960
- [17] Kanto WP, Parrish RA. Perforation of the peritoneum and intra-abdominal hemorrhage: A complication of umbilical vein catheterizations. *Am J Dis Child* 1977; 131: 1102–1103
- [18] Kim JH, Lee YS, Kim SH et al. Does umbilical vein catheterization lead to portal venous thrombosis? Prospective US evaluation in 100 neonates. *Radiology* 2001; 219 (3): 645–650
- [19] Saha B, Saha AK. Distal Migration and Successful Retrieval of a Broken Umbilical Venous Catheter in a Neonate. *Indian Pediatr* 2019; 56 (2): 149
- [20] Akin A, Bilici M, Demir F et al. Percutaneous retrieval of umbilical vein catheter fragment in an infant two months after embolization. *Turk J Pediatr* 2018; 60 (2): 191–193. doi:10.24953/turkjped.2018.02.012
- [21] Varan B, Yakut K, Harman A. Transcatheter retrieval of embolized catheter using venovenous loop in a neonate. *Turk J Pediatr* 2018; 60 (1): 113–115. doi:10.24953/turkjped.2018.01.020
- [22] Bernard O, Franchi-Abella S, Branchereau S et al. Congenital portosystemic shunts in children: recognition, evaluation, and management. *Semin Liver Dis* 2012; 32 (4): 273–287. doi:10.1055/s-0032-1329896
- [23] Morgan G, Superina R. Congenital absence of the portal vein: two cases and a proposed classification system for portasystemic vascular anomalies. *J Pediatr Surg* 1994; 29 (9): 1239–1241
- [24] Han BH, Park SB, Song MJ et al. Congenital portosystemic shunts: prenatal manifestations with postnatal confirmation and follow-up. *J Ultrasound Med* 2013; 32 (1): 45–52

- [25] Paganelli M, Lipsich JE, Sciveres M et al. Predisposing Factors for Spontaneous Closure of Congenital Portosystemic Shunts. *The Journal of Pediatrics* 2015; 167 (4): 931–935
- [26] Francois B, Gottrand F, Lachaux A et al. Outcome of intrahepatic portosystemic shunt diagnosed prenatally. *Eur J Pediatr* 2017; 176 (12): 1613–1618. doi:10.1007/s00431-017-3013-x
- [27] Poeppelman RS, Tobias JD. Patent Ductus Venosus and Congenital Heart Disease: A Case Report and Review. *Cardiol Res* 2018; 9 (5): 330–333. doi:10.14740/cr777w
- [28] Kamali L, Moradi M, Ebrahimian S et al. Patent ductus venosus in an infant with direct hyperbilirubinemia. *Clin Case Rep* 2019; 7 (7): 1430–1434. doi:10.1002/ccr3.2266
- [29] Ikeda S, Yamaguchi Y, Sera Y et al. Surgical correction of patent ductus venosus in three brothers. *Dig Dis Sci* 1999; 44 (3): 582–589
- [30] Yoshimoto Y, Shimizu R, Saeki T et al. Patent ductus venosus in children: a case report and review of the literature. *J Pediatr Surg* 2004; 39 (1): E1–E5
- [31] Perini MV, Starkey GM, Goh SK et al. Laparoscopic treatment of a patent ductus venosus and the use of indocyanine green to monitor perioperative hepatic function. *J Surg Case Rep* 2018; 2018 (2): rjy026. doi:10.1093/jscr/rjy026