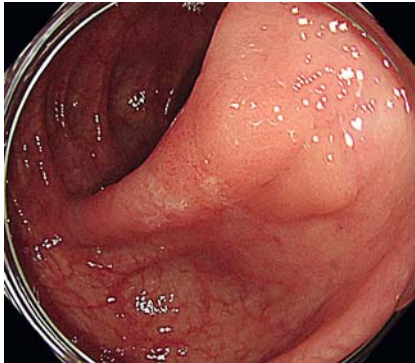
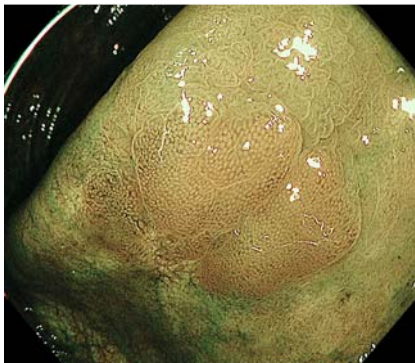


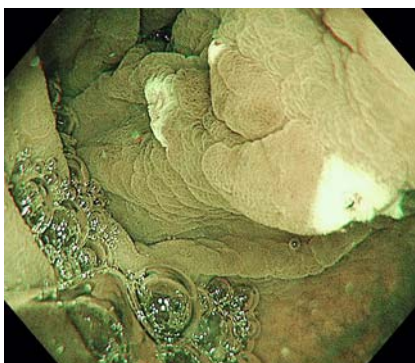
Underwater endoscopic mucosal resection for complete R0 removal of colorectal polyp in a patient with ulcerative colitis



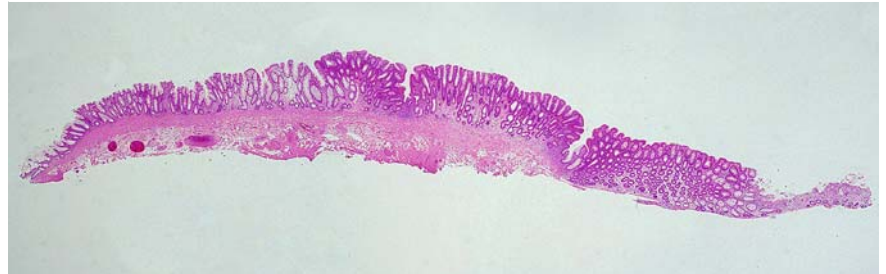► **Fig. 1** Colonoscopy shows a 15-mm, flat, elevated lesion with a scar located in the sigmoid colon.



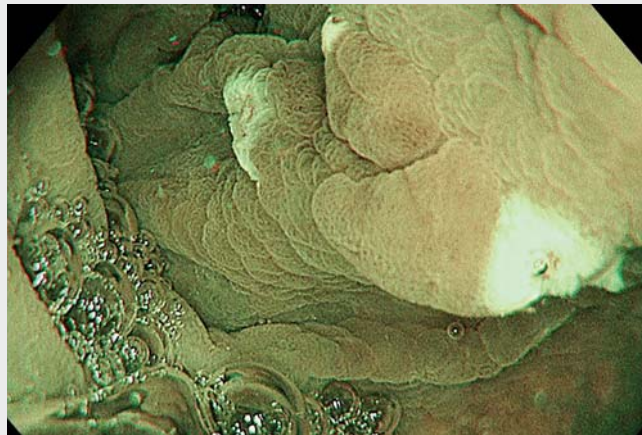
► **Fig. 2** Narrow-band imaging magnifying endoscopy shows regular vessels and surface structures, classified as type 2A according to the Japan Narrow-Band Imaging Expert Team classification.



► **Fig. 3** Water immersion provides a "float" effect, floating the lesion away from the muscularis layer, thus allowing wide-field resection of the polyp.



► **Fig. 4** Microscopic findings show excision of a low-grade tubular adenoma with negative margin.



► **Video 1** Colorectal polyp in a patient with ulcerative colitis is removed by underwater endoscopic mucosal resection. This eliminates the need for submucosal injection and provides a "floating" effect that facilitates the snaring of the scarred polyp.

Current guidelines recommend endoscopic resection for superficial colorectal neoplasia in patients with ulcerative colitis, particularly for a clearly visible lesion with distinct margins [1]. However, endoscopic removal of colorectal polyps is technically challenging in patients with ulcerative colitis. Endoscopic submucosal dissection (ESD) enables complete removal of such polyps but presents some technical difficulties and is time consuming [2].

A 73-year-old man with pancolitis-type ulcerative colitis maintained remission with the administration of oral and rectal

5-aminosalicylate and underwent colonoscopy for surveillance. We observed no active mucosal inflammation over the entire colon. However, there was a 15-mm flat elevated lesion in the sigmoid colon. Biopsy of the lesion suggested low-grade adenoma. Colonoscopy after 2 months revealed a 15-mm lesion with a scar caused by the previous biopsy (► **Fig. 1**). Narrow-band imaging magnifying endoscopy showed regular vessels and surface structures with clear demarcation, thus indicating an adenoma (► **Fig. 2**). Submucosal fibrosis caused by previous inflammation and biopsies

made complete removal using conventional endoscopic resection, such as endoscopic mucosal resection (EMR) and ESD, difficult. We performed underwater EMR (UEMR) for the lesion (► **Fig. 3**; ► **Video 1**) [3]. En bloc resection was achieved without any complications. Histopathological examination revealed complete removal of the low-grade tubular adenoma with severe fibrosis in the submucosal layer (► **Fig. 4**).

Submucosal fibrosis makes recognizing an adequate depth for dissection in ESD difficult [4]. However, UEMR eliminates the need for submucosal injection. The “floating” and “heat-sink” effects facilitate the grasping and removal of large or scarred polyps [5]. This is the first case to demonstrate the usefulness of UEMR for the management of superficial colorectal neoplasia in patients with ulcerative colitis. Thus, UEMR can be considered a safe, time-saving, and effective option.

Endoscopy_UCTN_Code_TTT_1AQ_2AD

Acknowledgments

We gratefully acknowledge the work of the past and present members of our institution.

Competing interests

The authors declare that they have no conflict of interest.

The authors

Kazuya Hosotani¹, **Satoko Inoue**¹, **Kana Takahashi**², **Shigeo Hara**², **Tetsuro Inokuma**¹

- 1 Department of Gastroenterology, Kobe City Medical Center General Hospital, Kobe, Japan
- 2 Department of Clinical Pathology, Kobe City Medical Center General Hospital, Kobe, Japan

Corresponding author

Kazuya Hosotani, MD
2-1-1 Minatojima-minamimachi, Chuo-ku,
Kobe, Hyogo 650-0047, Japan
kzyhosotani@gmail.com

References

- [1] Laine L, Kaltenbach T, Barkun A et al. SCENIC international consensus statement on surveillance and management of dysplasia in inflammatory bowel disease. *Gastrointest Endosc* 2015; 81: 489–501
- [2] Suzuki N, Toyonaga T, East JE. Endoscopic submucosal dissection of colitis-related dysplasia. *Endoscopy* 2017; 49: 1237–1242
- [3] Binmoeller KF, Weilert F, Shah J et al. “Underwater” EMR without submucosal injection for large sessile colorectal polyps (with video). *Gastrointest Endosc* 2012; 75: 1086–1091
- [4] Mizuno KI, Yokoyama J, Terai S. Management of endoscopic submucosal dissection for ulcerative colitis-associated neoplasia: tips and pitfalls. *Dig Endosc* 2019; 31 (Suppl. 01): 44–45
- [5] Hosotani K, Imai K, Hotta K et al. Underwater endoscopic mucosal resection for complete R0 removal of residual adenoma at a perforated scar in patient with colostomy. *Endoscopy* 2017; 49: E121–E122

Bibliography

Endoscopy 2022; 54: E3–E4
DOI 10.1055/a-1346-8769
ISSN 0013-726X
published online 16.2.2021
© 2021. Thieme. All rights reserved.
Georg Thieme Verlag KG, Rüdigerstraße 14,
70469 Stuttgart, Germany

ENDOSCOPY E-VIDEOS
<https://eref.thieme.de/e-videos>



Endoscopy E-Videos is a free access online section, reporting on interesting cases and new

techniques in gastroenterological endoscopy. All papers include a high quality video and all contributions are freely accessible online.

This section has its own submission website at
<https://mc.manuscriptcentral.com/e-videos>