

# Spray coagulation with snare-tip versus argon plasma coagulation: An ex vivo study evaluating tissue effects



## Authors

Andrew Fetz<sup>1</sup>, David Farnell<sup>2</sup>, Shayan Irani<sup>3</sup>, S. Ian Gan<sup>1</sup>

## Institutions

- 1 Gastroenterology Department, Vancouver General Hospital, University of British Columbia, Vancouver, BC, Canada
- 2 Pathology Department, Vancouver General Hospital, University of British Columbia, Vancouver, BC, Canada
- 3 Digestive Disease Institute, Virginia Mason Medical Center, Seattle, Washington, United States

submitted 20.8.2020

accepted after revision 9.12.2020

## Bibliography

Endosc Int Open 2021; 09: E790–E795

DOI 10.1055/a-1373-4162

ISSN 2364-3722

© 2021. The Author(s).

This is an open access article published by Thieme under the terms of the Creative Commons Attribution-NonDerivative-NonCommercial License, permitting copying and reproduction so long as the original work is given appropriate credit. Contents may not be used for commercial purposes, or adapted, remixed, transformed or built upon. (<https://creativecommons.org/licenses/by-nc-nd/4.0/>)

Georg Thieme Verlag KG, Rüdigerstraße 14,  
70469 Stuttgart, Germany

## Corresponding author

S. Ian Gan MD FRCPC, Vancouver General Hospital, 5153-  
2775 Laurel St., Vancouver, BC, V5Z 1M9, Canada  
Fax: +1-604-875-5378  
[ian.gan@vch.ca](mailto:ian.gan@vch.ca)

Supplementary material is available under  
<https://doi.org/10.1055/a-1373-4162>

## ABSTRACT

**Background and study aims** Argon plasma coagulation (APC) is an effective and safe modality for many gastrointestinal conditions requiring hemostasis and/or ablation. However, it can be quite costly. A potentially more cost-effective alternative is snare-tip spray coagulation (SC). This study aimed to determine whether SC would be a safe and effective alternative to APC using an ex-vivo model.

**Methods** Using two resected porcine stomach, 36 randomized gastric areas were ablated for 2 seconds with either APC at 1.0L/min 20W (APC20) and 1.4L/min 40W (APC40) or SC with Effect 2 60W (SC60) and 80W (SC80) from 3 mm. Extent of tissue injury was then analyzed histopathologically.

**Results** The mean coagulation depth was  $790 \pm 159 \mu\text{m}$  and  $825 \pm 467 \mu\text{m}$  for SC60 (n=9) and SC80 (n=8), respectively. This was compared to  $539 \pm 151 \mu\text{m}$  for APC20 (n=8) and  $779 \pm 267 \mu\text{m}$  for APC40 (n=9). Mean difference (MD) in coagulation depth between SC60 and APC40 was  $12 \mu\text{m}$  (95% confidence interval [CI],  $-191$  to  $214 \mu\text{m}$ ;  $P=0.91$ ) and was  $47 \mu\text{m}$  (95%CI,  $-162$  to  $255 \mu\text{m}$ ;  $P=0.81$ ) between SC80 and APC40. There was a greater depth of injury with APC40 (MD,  $240 \mu\text{m}$ ; 95%CI,  $62$  to  $418 \mu\text{m}$ ;  $P=0.04$ ) and with SC60 (MD,  $252 \mu\text{m}$ ; 95%CI,  $141$  to  $362 \mu\text{m}$ ;  $P=0.004$ ) when compared to APC20. Mean cross-sectional area of coagulation was  $2.39 \pm 0.852 \text{ mm}^2$  for SC60 and  $2.54 \pm 1.83 \text{ mm}^2$  for SC80 compared to  $1.22 \pm 0.569 \text{ mm}^2$  for APC20 and  $1.99 \pm 0.769 \text{ mm}^2$  for APC40. Seventy-eight percent reached the muscularis mucosa (MM) and 11% the submucosa in the SC60 group compared to 50% and 38% in SC80 and 56% and 11% in APC40, respectively. Thirty-eight percent of APC20 specimens reached the MM. The muscularis propria was unaffected.

**Conclusions** This small ex-vivo study suggests that SC60 and SC80 may be safe alternatives to APC40 with comparable coagulation depths and area effects.

## Introduction

Argon plasma coagulation (APC) is an electro-surgical monopolar procedure that has been well established as an effective and safe modality for endoscopically managing a variety of gastro-

intestinal conditions involving hemostasis and ablation. Its application has been demonstrated in the electrocoagulation of angiodysplastic lesions, gastric antral vascular ectasia (GAVE) syndrome, radiation telangiectasias, and ulcer hemostasis, as

well as in ablative treatments of Barrett's esophagus and esophageal, gastric, and colonic tumors [1–5].

Argon gas, chosen for its inert and ionizable properties, is conducted through a coagulation probe within the endoscope onto the desired tissue. A high-frequency electrical energy then ionizes the gas, thereby transforming it into electrically conducting argon plasma. This allows for the conduction of current without contact onto tissue and thus produces the tissue effect of superficial coagulation. Altering the duration of activation, distance to tissue, flow rate of argon gas, and the mode settings on the generator results in different tissue effect and offers flexibility depending on the nature of the condition [6]. In general, APC has been favored in many clinical settings as it results in tissue damage of limited depth, leading to ablation of superficial layers while minimizing the risk of perforation [7].

To use APC, an argon-compatible, high-frequency monopolar generator, an APC unit, an argon gas source, and other dedicated equipment need to be established. In addition, disposable APC probes made of flexible Teflon tube surrounding a tungsten electrode are needed for each procedure. The cost associated with acquiring this equipment and its ongoing use can be quite high. As such, the evaluation of a cost-effective alternative is crucial to ensure sustainability in a healthcare environment with finite resources.

A potential alternative to APC available on newer electrosurgical units is the use of spray coagulation (SC) using a polypectomy snare tip or monopolar ball [8]. With SC, a similar non-contact surface coagulation with low penetration depth is achieved by using high peak voltage allowing the energy to arc across an air gap [9, 10]. To our knowledge, a direct comparison between the efficacy and safety of SC and APC for achieving hemostasis has not been performed.

In this study, we compared the tissue effects of SC and APC, evaluating the spread and depth of electrocoagulation in ex vivo pig stomach models. Using frequently used standard settings from each modality, we aimed to determine if SC would be an appropriate alternative to APC in managing conditions where APC is currently indicated.

## Methods

### Electrosurgical equipment and technique:

All procedures in the study were completed using the ESG-300 electrosurgical generator MAPC system (Olympus, Tokyo, Japan). Olympus argon axial probes with a diameter of 2.3 mm were used for all APC settings and Olympus SnareMaster 15-mm oval stiff snares, with a wire diameter of 0.47 mm and sheath diameter of 2.6 mm, were used for all SC settings. Snare tips were fixed in position approximately 1 mm outside the sheath of the snare.

A height gauge was used to secure the respective instrument probe, without using a flexible endoscope, at approximately 90° and to standardize the distance from probe tip to mucosa to approximately 3 mm to ensure consistency of technique during the study (**Supplemental Fig. 1**).

### Sample preparation and group parameters

Two adult porcine stomach were obtained and each was resected along the greater and lesser curvature into two separate specimens. Thirty-six randomized gastric areas each were ablated with either APC or SC using the forced APC settings of 1.0 L/min 20 W (APC20) and 1.4 L/min 40 W (APC40) and SC settings of Effect 2 60 W (SC60) and 80 W (SC80). The duration of coagulation for each area was 2 seconds.

### Pathological examination

After coagulation, each ablation site was transected perpendicular to the mucosal surface allowing for full thickness section through the stomach wall. Each section was fixed in 10% buffered formalin and embedded in paraffin wax for microscopic evaluation as per standard pathology laboratory procedures. One representative hematoxylin and eosin-stained histology section was then obtained from each ablation site. The histology slides were digitally scanned and QuPath (Quantitative Pathology & Bioimage Analysis) software was used to assess each histology slide. The slides were accessed by a board-certified anatomical pathologist (D. F.) who was blind to the particular endoscopic treatment associated with each ablation site. Anatomical depth of cautery artifact extent (mucosa, muscularis mucosa, submucosa, and muscularis propria, each broken into thirds: superficial, mid, and deep) was visually assessed. In addition, depth of cautery artifact ( $\mu\text{m}$ ), width of cautery artifact ( $\mu\text{m}$ ), and cross-sectional area of cautery artifact ( $\mu\text{m}^2$ ) were measuring using QuPath. Unfortunately, two ablation sites were lost during processing.

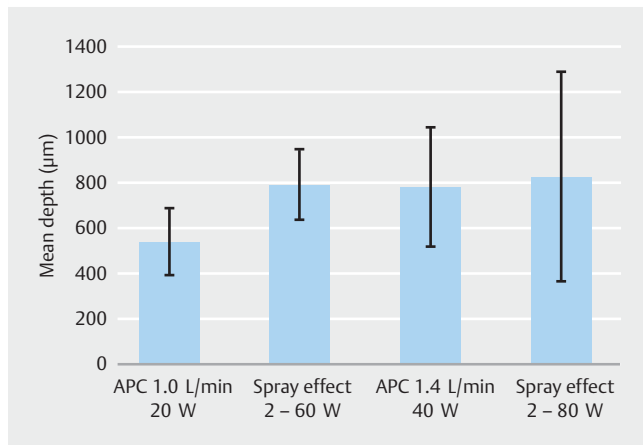
### Statistical analysis

The depth of tissue injury in APC40 was estimated to be about  $750 \pm 130 \mu\text{m}$  based on preliminary data. Allowing for a difference of 25% in the other groups with similar standard deviation, while using a significance level of 5% and a statistical power of 80%, the total number of cases calculated was  $n = 8$  per group.

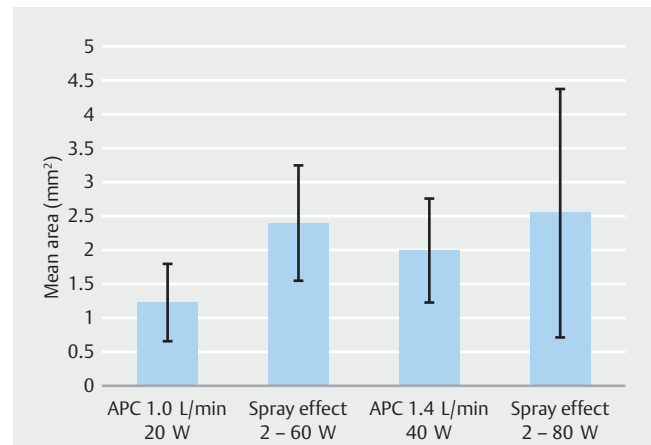
The depth and cross-sectional surface area of necrosis and coagulation, as well as extension into each of the stomach layers, for APC and SC using the settings above were collected and analyzed using descriptive statistics (means and standard deviations). Any comparisons between groups were completed using a two-tailed *t*-test assuming unequal variance and 95% confidence interval between means were determined. Statistical significance was considered at  $P < 0.05$ .

## Results

The mean coagulation depths measured microscopically are shown in ► **Fig. 1**. The mean difference in depth of thermal injury was  $12 \mu\text{m}$  (95% confidence interval [CI],  $-191$  to  $214 \mu\text{m}$ ;  $P = 0.91$ ) for SC60 and APC 40 and was  $47 \mu\text{m}$  (95%CI,  $-162$  to  $255 \mu\text{m}$ ;  $P = 0.81$ ) when comparing SC80 with APC40. Mean depth of thermal injury was greater by  $240 \mu\text{m}$  (95%CI,  $62$  to  $418 \mu\text{m}$ ;  $P = 0.04$ ) in APC40 compared with APC20 and by  $252 \mu\text{m}$  (95%CI,  $141$  to  $362 \mu\text{m}$ ;  $P = 0.004$ ) in SC60 when com-



► **Fig. 1** Mean coagulation depth in µm (± SD) for APC and spray coagulation determined histologically.

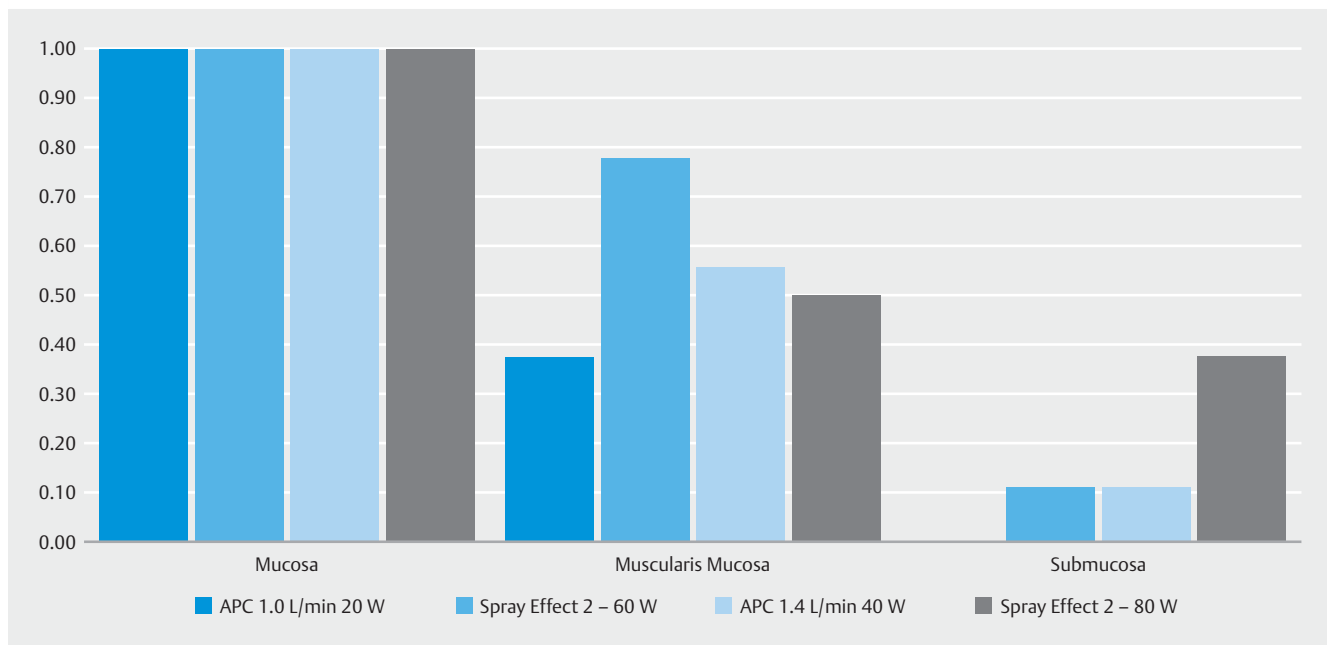


► **Fig. 2** Mean coagulation cross-sectional area in mm<sup>2</sup> (± SD) for APC and spray coagulation determined histologically.

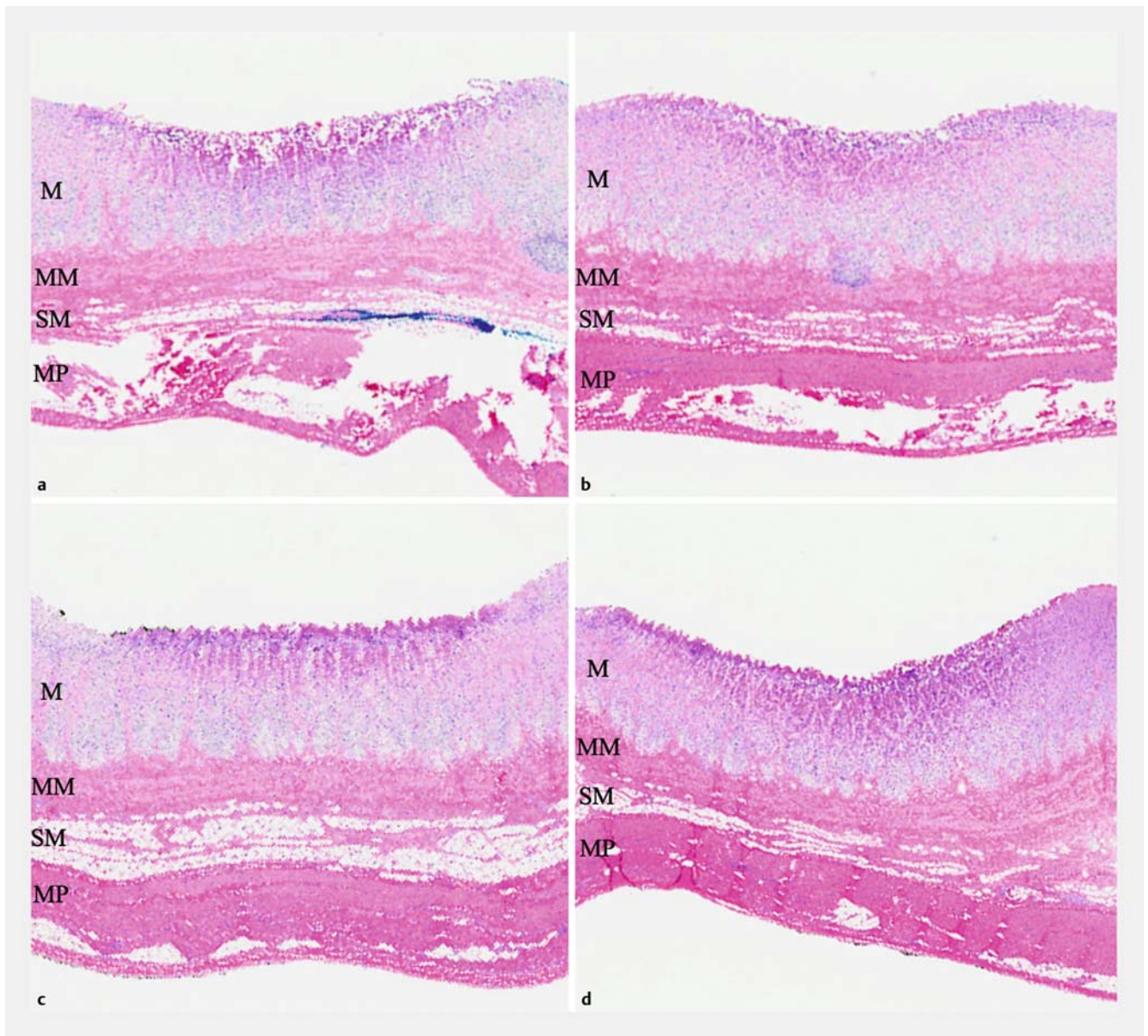
pared to APC20. SC80 trended towards a greater depth as well by 287 µm (95%CI, 167 to 407 µm;  $P=0.13$ ) compared to APC20.

The mean cross-sectional area of thermal injury measured histologically is presented in ► **Fig. 2**. The mean difference seen comparing either SC60 or SC80 to APC40 was not statistically significant but slightly larger at 0.404 mm<sup>2</sup> (95%CI, -0.347 to 1.15 mm<sup>2</sup>;  $P=0.31$ ) and 0.549 mm<sup>2</sup> (95%CI, -0.818 to 1.92 mm<sup>2</sup>;  $P=0.45$ ), respectively. APC40 and SC60 showed a larger mean area of thermal injury at 0.769 mm<sup>2</sup> (95%CI, 0.129 to 1.41 mm<sup>2</sup>;  $P=0.03$ ) and 1.17 mm<sup>2</sup> (95%CI, 0.490 to 1.85 mm<sup>2</sup>;  $P=0.06$ ), respectively, when compared to APC20. The mean difference between SC80 and APC20 was 1.32 mm<sup>2</sup> (95%CI, -0.014 to 2.65 mm<sup>2</sup>;  $P=0.38$ ).

Cautery effect and tissue damage to the layers of the gastric wall after treatment are shown in ► **Fig. 3**. During all settings, damage to the mucosa was observed. With APC40, tissue damage to the muscularis mucosa and the submucosa were seen in five of nine and one of nine specimens, respectively. This was compared to seven of nine and one of nine in the SC60 samples, and four of eight and three of eight in the SC80 samples. In APC20, damage to the muscularis mucosa was seen in three of eight cases, and no damage to submucosa was observed. No damage to the muscularis propria layer was observed in any of the experimental settings. ► **Fig. 4** shows examples of histological sections of the thermal damage to the stomach layers.



► **Fig. 3** Proportion of specimens with cautery effect to gastric wall layers by each modality.



► **Fig. 4** Histological sections demonstrating the depth of thermal damage (hematoxylin-eosin stained) by APC using settings 1.4L/min 40W (a), 1.0L/min 20W (c) and spray coagulation using Effect 2 – 60W (b) and 80W (d).

## Discussion

Noncontact thermoablative procedures like APC are commonly used to control superficial bleeding and for ablative procedures due to its relative safety profile and ease of use. The rates of complication of APC differ depending on operator experience and anatomical site of use, but in one large study, colonic perforation was cited at around 0.3% [11]. Lower risk of deep tissue injury and perforation compared to other coagulative procedures is theorized to be related to the arcing of the transmitted current away from the desiccated and high-resistance tissue to undessicated, lower-resistance areas using the spread of the ionized argon gas.

SC is also a form of coagulation that involves fulguration and has been used in electrosurgery for sealing off small hidden

vessels, areas with large bleeding potential, and to destroy surface layers of cells in an area in which a suspicious lesion had been removed to prevent possible migration of malignant cells. To our knowledge, its use has largely been in the surgical setting, as well as in endoscopic submucosal dissection, but its use in general endoscopic hemostasis and tissue ablation has been limited. The authors have considerable experience (unpublished) with snare-tip SC in the clinical setting, both for hemostasis and ablation, and to date no complications have arisen, and its use appears safe. As such, SC has largely been used by the authors to replace APC. Our current practice has been to have the nurse or technician withdraw the snare tip to just inside the sheath, rather than to have the tip extended past the sheath edge. This in turn reduces the risk of contact between

the tip and mucosa. For this study, however, we found that in our initial attempts to mimic the clinical setting with the snare tip within the sheath, there were difficulties in forming a consistent arc, likely an artifact of the somewhat artificial ex-vivo nature of the study. As such, the tip was kept extended 1 mm outside of the sheath edge and a distance from mucosa was maintained as per established study protocol.

The APC settings used in the study were chosen as they are typical of those used clinically and are suggested by the manufacturer of our electrosurgical system, Olympus, for hemostasis and ablative procedures in the colon and small bowel (APC20) and the stomach (APC40). The SC settings were chosen on the basis of what has been used clinically in our two endoscopy units (Effects 1 and 2, 60W). We observed that in the ex-vivo setting, the thermal effects did not appear to be as robust as what is normally seen clinically, and as such we opted to evaluate SC at a higher wattage (80W) in the ex-vivo setting as well. We do acknowledge that the settings studied were specific to our electrosurgical system. However, although not tested in our current study, similar settings can likely be identified on generators from other brands to produce the desired tissue effects.

The present study comparing the depth and spread of tissue injury of APC and SC provides some evidence that SC with a snare tip is a safe alternative to APC using the appropriate settings. Our data show that SC60 and SC80 produced similar depth and cross-sectional area of thermal effects as APC40. Albeit, greater variability was seen with SC80. Notably, thermal effects into the muscularis propria were not seen in any of the specimens in these controlled settings. Given the similarities in the depth and cross-sectional area of thermal effects, this may suggest that the risk of perforation in SC60 are similar to what is seen with APC40, and other SC settings can be identified to produce similar effects to what is seen with a corresponding APC setting. Similar to APC, care should be taken when using SC to avoid unintended and extended direct contact with the mucosa in order to reduce the risk of complications such as perforations.

One advantage of SC over traditional APC is its ability to reach more tortuous area owing to potentially easier passage of snare catheters compared to APC catheters. Recently, H.H. Yen reported a case of obscure GI bleeding in which SC was used in a double-balloon enteroscope as a rescue therapy to APC to control bleeding from a jejunal angioectasia. Due to the high resistance and complex path of the instrument channel in enteroscopy, multiple APC probes were fractured. In the end, successful hemostasis was achieved with SC using a standard snare tip [8]. The authors of the current study also have anecdotal evidence suggesting that snare sheaths are easier to pass down enteroscope channels than similarly sized APC catheters.

Using a standard snare-tip to achieve superficial hemostasis also offers a greater convenience for the operator and an endoscopy center, as well as likely a lower cost of snares and materials when compared to the use of argon and APC catheters. Most sites performing endoscopy have equipment dedicated to standard polypectomy and using similar equipment for

different clinical applications may simplify processes and improve workflow. In order to run APC, additional dedicated equipment and costly disposable probes are needed. Although a complete cost comparison was not performed in this present study, if SC is as effective as APC in hemostasis and ablation and can result in non-inferior re-bleeding and complication rates, it may also be a more cost-effective alternative. Currently at our center, the typical cost of each APC probe is approximately \$ 600CAD, compared to the polypectomy snares used in the study, which each cost approximately \$ 8CAD.

There are several limitations to the current study. This was an ex-vivo animal model limited to two porcine stomachs. Generalizability and translation of the results to living human tissue may be imperfect. Physical properties of different living tissues, inflammatory response to coagulation in vivo, and the local gastrointestinal environment may affect the true coagulative effects seen in vivo. Previous studies comparing ex vivo data to in vivo data for APC suggest that penetration depth seen in ex vivo models may vary when translated in the in vivo setting [12, 13]. In addition, only a limited number of applications for each setting were compared using 2 seconds of non-contact coagulation in same location from a controlled distance in an attempt to compare the modalities in a standardized method. The small sample size likely played a factor in the lack of statistical significance seen when comparing the cross-sectional areas between APC20 and SC60. It is also important to consider that in clinical practice, non-contact applications generally involve creating an arc of conduction with constant movement and spreading of coagulation across a tissue. This generally equates to a greater variability in the time of coagulation that the tissue experiences. Furthermore, although attempts to standardize the distance from probe to mucosa were made, slight variation in mucosa wall height was out of experimental control. This study also only examined forced APC settings and comparisons between SC with pulsed and precise APC settings were not completed.

## Conclusions

In conclusion, SC60 appears to produce comparable tissue effects as forced APC40 in our ex-vivo model. This may suggest that they have a similar safety profile in the clinical setting. SC80 may also be an appropriate alternative. However, further studies comparing efficacy and safety in in vivo models or in the clinical setting, as well as studies assessing other SC settings to find comparable tissue effects to APC20 are warranted and will hopefully consolidate its use in daily practice.

## Acknowledgements

The authors thank Michael Flanagan and Kevin Opsahl with the Olympus team for their assistance with the equipment used in the study; personnel at the Robert H.N. Ho Research Centre wet research lab for use of their space and their assistance with the handling of the porcine stomach; and Simon Cheung with the anatomical pathology department for assistance in fixing and preparing specimens for histopathological analysis.

## Competing interests

---

Drs. Irani and Gan have served as consultants for Boston Scientific. Dr. Irani has received research funding from Boston Scientific in the past. Dr. Gan has given presentations on behalf of Boston Scientific and has received an unrestricted grant from Mylan Pharmaceuticals in the past. Equipment support for the study was provided by Olympus Canada.

## References

---

- [1] Vargo JJ. Clinical applications of the argon plasma coagulator. *Gastrointest Endosc* 2004; 59: 81–88
- [2] Mendonca EQ, de Oliveira JF, Maluf-Filho F. Argon plasma coagulation and radiofrequency ablation in nonvariceal upper gastrointestinal bleeding. *Tech Gastrointest Endosc* 2016; 18: 203–209
- [3] Weiner J, Schwartz D, Martinez M et al. Long-term results on the efficacy of argon plasma coagulation for patients with chronic radiation proctitis after conventionally fractionated, dose-escalated radiation therapy for prostate cancer. *Pract Radiat Oncol* 2017; 7: e35–e42
- [4] Akhtar K, Byrne JP, Bancewicz J et al. Argon beam plasma coagulation in the management of cancers of the esophagus and stomach. *Surg Endosc* 2000; 14: 1127–1130
- [5] Brooker JC, Saunders BP, Shah SG et al. Treatment with argon plasma coagulation reduces recurrence after piecemeal resection of large sessile colonic polyps: a randomized trial and recommendations. *Gastrointest Endosc* 2002; 55: 371–375
- [6] Wahab PJ, Mulder CJ, Den Hartog G et al. Argon plasma coagulation in flexible gastrointestinal endoscopy: pilot experiences. *Endoscopy* 1997; 29: 176–181
- [7] Watson JP, Bennett MK, Griffin SM et al. The tissue effect of argon plasma coagulation on esophageal and gastric mucosa. *Gastrointest Endosc* 2000; 52: 342–345
- [8] Yen HH. Gastrointestinal: Spray coagulation with snare tip as a rescue therapy to argon plasma coagulation for bleeding jejunal angioectasia. *J Gastroen Hepatol* 2017; 32: 1909
- [9] Matsui N, Akahoshi K, Nakamura K et al. Endoscopic submucosal dissection for removal of superficial gastrointestinal neoplasms: A technical review. *World J Gastroenterol* 2012; 4: 123
- [10] MHRA 04080 High power electrosurgery review. 2004
- [11] Panos MZ, Koumi A. Argon plasma coagulation in the right and left colon: safety–risk profile of the 60W–1.2 l/min setting. *Scand J Gastroenterol* 2014; 49: 632–641
- [12] Norton ID, Wang L, Levine SA et al. In vivo characterization of colonic thermal injury caused by argon plasma coagulation. *Gastrointest Endosc* 2012; 55: 631–636
- [13] Goulet CJ, DiSario JA, Emerson L et al. In vivo evaluation of argon plasma coagulation in a porcine model. *Gastrointest Endosc* 2007; 65: 457–462