







Endoscopic management of superficial nonampullary duodenal tumors: European Society of Gastrointestinal Endoscopy (ESGE) Guideline



Authors

Geoffroy Vanbiervliet¹, Alan Moss^{2,3}, Marianna Arvanitakis⁴, Urban Arnelo⁵, Torsten Beyna⁶ , Olivier Busch⁷, Pierre H. Deprez⁸ , Lumir Kunovsky^{9,10} , Alberto Larghi¹¹, Gianpiero Manes¹² , Bertrand Napoleon¹³, Kumanan Nalankilli^{2,3}, Manu Nayar¹⁴, Enrique Pérez-Cuadrado-Robles¹⁵ , Stefan Seewald¹⁶, Marin Strijker⁷, Marc Barthet¹⁷ , Jeanin E. van Hooft¹⁸

Institutions

- 1 Department of Digestive Endoscopy, Centre Hospitalier Universitaire de Nice, Nice, France
- 2 Department of Endoscopic Services, Western Health, Melbourne, Australia
- 3 Department of Medicine - Western Health, Melbourne Medical School, The University of Melbourne, Victoria, Australia
- 4 Gastroenterology, Hepatopancreatology, and Digestive Oncology, Erasme Hospital, Université Libre de Bruxelles, Brussels, Belgium
- 5 Department of Surgery, Centre for Digestive Diseases, Karolinska University Hospital, Stockholm, Sweden
- 6 Department of Gastroenterology, Evangelisches Krankenhaus Düsseldorf, Düsseldorf, Nordrhein-Westfalen, Germany
- 7 Department of Surgery, Cancer Center Amsterdam, Amsterdam UMC, University of Amsterdam, Amsterdam, The Netherlands
- 8 Gastroenterology and Hepatology Department, Cliniques universitaires Saint-Luc, Université Catholique de Louvain, Brussels, Belgium
- 9 Department of Gastroenterology and Internal Medicine, University Hospital Brno, Faculty of Medicine, Masaryk University, Brno, Czech Republic
- 10 Department of Surgery, University Hospital Brno, Faculty of Medicine, Masaryk University, Brno, Czech Republic
- 11 Digestive Endoscopy Unit, Fondazione Policlinico Universitario A. Gemelli IRCCS, Università Cattolica del Sacro Cuore, Rome, Italy
- 12 Aziende Socio Sanitaria Territoriale Rhodense, Gastroenterology, Garbagnate Milanese, Italy
- 13 Service de Gastroentérologie, Hôpital Privé Jean Mermoz, Ramsay Générale de Santé, Lyon, France
- 14 Department of Gastroenterology, Freeman Hospital, Newcastle upon Tyne, UK
- 15 Department of Gastroenterology, Georges-Pompidou European Hospital, AP-HP Centre - Université de Paris, Paris, France
- 16 Center of Gastroenterology Centre, Klinik Hirslanden, Zurich, Switzerland
- 17 Department of Gastroenterology, Hôpital Nord, Assistance publique des hôpitaux de Marseille, Marseille, France
- 18 Department of Gastroenterology and Hepatology, Leiden University Medical Center, The Netherlands

published online 1.4.2021

Bibliography

Endoscopy 2021; 53: 522–534

DOI 10.1055/a-1442-2395

ISSN 0013-726X

© 2021. European Society of Gastrointestinal Endoscopy

All rights reserved.

This article is published by Thieme.

Georg Thieme Verlag KG, Rüdigerstraße 14,

70469 Stuttgart, Germany

Appendix 1s

Supplementary material is available at

<https://doi.org/10.1055/a-1442-2395>

Corresponding author

Geoffroy Vanbiervliet, MD PhD, Endoscopie Digestive, Hôpital L'Archet 2, Centre Hospitalier Universitaire de Nice, 151 Route de Saint Antoine de Ginestière, CS 23079, 06200 Nice Cedex 3, France
vanbiervliet.g@chu-nice.fr

MAIN RECOMMENDATIONS

1 ESGE recommends that all duodenal adenomas should be considered for endoscopic resection as progression to invasive carcinoma is highly likely.

Strong recommendation, low quality evidence.

2 ESGE recommends performance of a colonoscopy, if that has not yet been done, in cases of duodenal adenoma.

Strong recommendation, low quality evidence.

3 ESGE recommends the use of the cap-assisted method when the location of the minor and/or major papilla and their relationship to a duodenal adenoma is not clearly established during forward-viewing endoscopy.

Strong recommendation, moderate quality evidence.

4 ESGE recommends the routine use of a side-viewing endoscope when a laterally spreading adenoma with extension to the minor and/or major papilla is suspected.

Strong recommendation, low quality evidence.

5 ESGE suggests cold snare polypectomy for small (<6 mm in size) nonmalignant duodenal adenomas.

Weak recommendation, low quality evidence.

6 ESGE recommends endoscopic mucosal resection (EMR) as the first-line endoscopic resection technique for nonmalignant large nonampullary duodenal adenomas.

Strong recommendation, moderate quality evidence.

7 ESGE recommends that endoscopic submucosal dissection (ESD) for duodenal adenomas is an effective resection technique only in expert hands.

Strong recommendation, low quality evidence.

8 ESGE recommends using techniques that minimize adverse events such as immediate or delayed bleeding or perforation. These may include piecemeal resection, defect closure techniques, noncontact hemostasis, and other emerging techniques, and these should be considered on a case-by-case basis.

Strong recommendation, low quality evidence.

9 ESGE recommends endoscopic surveillance 3 months after the index treatment. In cases of no recurrence, a further follow-up endoscopy should be done 1 year later. Thereafter, surveillance intervals should be adapted to the lesion site, en bloc resection status, and initial histological result.

Strong recommendation, low quality evidence.

SOURCE AND SCOPE

This is the second part of a two-part guideline from the European Society of Gastrointestinal Endoscopy (ESGE) that covers the endoscopic management of superficial nonampullary tumors of the duodenum. The companion guideline gives guidance on ampullary tumors.

1 Introduction

Superficial nonampullary duodenal tumors (SNADTs) are less frequently observed compared with adenomas in the other areas of the gastrointestinal (GI) tract but recent studies have shown a gradual increase in incidence of these lesions [1]. This increase could be explained by some environmental factors but also by better accuracy of gastroscopy and new endoscopic detection technologies. Endoscopy has taken the main role in management of these lesions, particularly in a curative setting. Nevertheless, diagnostic and therapeutic strategies need to be clearly defined.

Lesions associated with predisposing genetic syndromes, including familial adenomatous polyposis (FAP), or of submucosal or neuroendocrine origin, will not be discussed here as they are considered in another Guideline from the European Society of Gastrointestinal Endoscopy (ESGE) [2]. While the indications for endoscopic treatment and follow-up may be different between the sporadic and polyposis-related forms, the

statements regarding diagnosis, evaluation, technical modalities of SNADT treatment, and management of complications are similar.

2 Methods

ESGE commissioned this Guideline (Guideline Committee Chair, J.v.H) and appointed a guideline leader (G.V.) who invited the listed authors to participate in the project development. The key questions were prepared by the guideline leader on two topics (endoscopic management of ampullary tumors and of preneoplastic duodenal lesions) and then approved by the other project members. The coordinating team established task force subgroups, each with its own leader, that were assigned key questions (see **Appendix 1s**, online-only Supplementary Material).

Each task force performed a systematic literature search to prepare evidence-based and well-balanced statements on their assigned key questions. The literature search was performed for English-language articles in MEDLINE, Embase, and the Cochrane database, focusing on meta-analyses and fully published prospective studies, particularly randomized controlled trials (RCTs), performed in humans. Retrospective analyses and pilot studies were also included if they addressed topics not covered in the prospective studies. The Grading of Recommendations Assessment, Development and Evaluation (GRADE) system was adopted to define the strength of recommendation and quality of evidence. Each task force proposed statements

ABBREVIATIONS

APC	argon plasma coagulation
CA-EGD	cap-assisted esophagogastroduodenoscopy
CT	computed tomography
EMR	endoscopic mucosal resection
ERCP	endoscopic retrograde cholangiopancreatography
ESD	endoscopic submucosal dissection
ESGE	European Society of Gastrointestinal Endoscopy
EUS	endoscopic ultrasound
EUS-BD	endoscopic ultrasound-guided biliary drainage
EUS-FNA/B	endoscopic ultrasound fine-needle aspiration/biopsy
FAP	familial adenomatous polyposis
FTRD	full-thickness resection device
GI	gastrointestinal
GRADE	Grading of Recommendations Assessment, Development and Evaluation
IDUS	intraductal ultrasound
IHC	immunohistochemistry
MRCP	magnetic resonance cholangiopancreatography
NBI	narrow band imaging
OR	odds ratio
OTS	over-the-scope
RCT	randomized controlled trial
RFA	radiofrequency ablation
SEMS	self-expandable metal stent
SNADT	superficial nonampullary duodenal tumor
U-EMR	underwater endoscopic mucosal resection

on their assigned key questions which were discussed during a web meeting in July 2020. Literature searches were re-run in September 2020. This time-point should be the starting point in the search for new evidence for future updates to this Guideline.

In September 2020, a draft prepared by G.V. was sent to all group members for review. The draft was also reviewed by two external reviewers and then sent for further comments to the ESGE national societies and individual members. After agreement on a final version, the manuscript was submitted to the journal *Endoscopy* for publication. All authors agreed on the final revised version.

This Guideline was issued in 2021 and will be considered for review in 2025, or sooner if new and relevant evidence becomes available. Any updates to the Guideline in the interim period will be noted on the ESGE website: <http://www.esge.com/esge-guidelines.html>.

3 Diagnosis of superficial nonampullary duodenal tumors

3.1 Epidemiology, histology, presentation, and predictive factors

RECOMMENDATION

ESGE recommends that all duodenal adenomas should be considered for endoscopic resection as progression to invasive carcinoma is highly likely.
Strong recommendation, low quality evidence.

RECOMMENDATION

ESGE recommends performance of a colonoscopy, if that has not yet been done, in cases of duodenal adenoma.
Strong recommendation, low quality evidence.

The prevalence of SNADTs is relatively low, reported as between 1.0% to 1.5% in retrospective series [3, 4] and 4.6% in a prospective one [5]. Among these and another retrospective series, the overall prevalence of adenoma ranged only from 0.03 to 0.4% [3, 5, 6].

In contrast to ampullary tumors, duodenal adenomas are less often sporadic, being associated in 60% of cases with FAP [7]. The other predisposing genetic syndrome is *MUTYH*-associated polyposis in which the prevalence of duodenal adenomas is estimated to be 17%–25% of patients [8]. Some independent predictive factors for sporadic duodenal adenomas have recently been determined, including current smoking (odds ratio [OR] 3.35, 95%CI 1.79–6.30), Barrett's esophagus (OR 4.23, 95%CI 2.17–8.25), fundic gland polyp (OR 2.29, 95%CI 1.29–4.06), and malignant disease (OR 2.84, 95%CI 1.57–5.15) [9]. When the patient presents with predictive factors, a careful gastroscopic examination of the whole duodenum must be carried out with fulfilment of the appropriate quality criteria [10].

In addition, a meta-analysis of several case-control studies (24 studies, 37 152 participants) has suggested an association between sporadic duodenal adenoma and colorectal adenoma [11]. The largest case-control study on the subject, published after the above meta-analysis, included 203 277 patients (537 with duodenal adenomas) who underwent upper and lower gastrointestinal endoscopy. Patients with duodenal adenoma showed a significantly higher prevalence of all types of colonic adenomas (OR 2.65, 95%CI 2.16–3.25), advanced colonic adenomas (OR 4.30, 95%CI 3.24–5.70), and colorectal cancer (OR 3.13, 95%CI 1.38–7.12), without location preference between left and right colon [12].

Most of the lesions are diagnosed incidentally during a gastroscopy, with initial histopathological findings of low grade dysplasia [13]. After a follow-up of 6 months, 20.9% (9/43) of low grade dysplasia adenomas showed progression to high grade dysplasia, including 4.7% in situ carcinomas [13]. High grade dysplasia diagnosis at first biopsy and a lesion diameter

of ≥ 20 mm are significantly predictive of progression to adenocarcinoma [13].

The progression from adenoma to adenocarcinoma is of two types [14]. In the first, intestinal-type lesions in proximal and distal duodenum follow the adenoma–carcinoma sequence, similarly to carcinogenesis in the colon. Secondly, progression of a de novo gastric type, including gastric foveolar-type or pyloric gland adenoma, is independent of the usual Wnt/ β -catenin pathway and is associated with gastric duodenal metaplasia in the proximal segment (bulb). The gastric-type lesion is more frequently diagnosed as carcinoma, with a tendency to poorer prognosis [15]. The intestinal-type progression is associated with classic adenomas, most of which are located in the second part of the duodenum and are the most common form of presentation.

3.2 Endoscopic assessment, biopsy, and staging

RECOMMENDATION

ESGE recommends the use of the cap-assisted method when the location of the minor and/or major papilla and their relationship to a duodenal adenoma is not clearly established during forward-viewing endoscopy. Strong recommendation, moderate quality evidence.

RECOMMENDATION

ESGE recommends the routine use of a side-viewing endoscope when a laterally spreading adenoma with extension to the minor and/or major papilla is suspected. Strong recommendation, low quality evidence.

RECOMMENDATION

ESGE suggests the use of magnifying chromoendoscopy for endoscopic diagnosis and staging of duodenal lesions. Weak recommendation, low quality evidence.

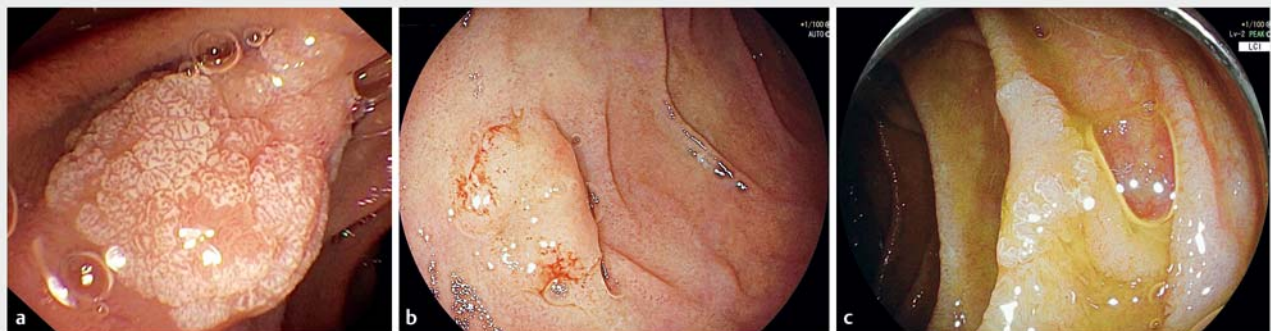RECOMMENDATION

ESGE suggests that if endoscopic features are suggestive of superficial duodenal adenoma, the use of biopsy for histological assessment should be limited prior to endoscopic resection, since its additional diagnostic yield might be limited and resection might be compromised. Weak recommendation, low quality evidence.

The macroscopic presentation for sporadic duodenal adenoma is mainly milk-white or reddish mucosa (► **Fig. 1**) [16, 17], and the morphology of the lesion is usually 0-IIa in the Paris classification [17–19]. The associations between the macroscopic type or the tumor size and malignancy have been analyzed with conflicting results [1, 13, 20, 21]. Nevertheless, Paris 0-IIc or III lesions with ulcerated forms and loss of superficial pit pattern remain potentially significantly more likely to have an unfavorable outcome and to be invasive and therefore more likely to lead to a definitive histological finding.

Evaluation of the extent of the SNADT may require some technical adaptations. The use of a transparent cap on the tip of a forward-viewing endoscope (cap-assisted esophagogastroduodenoscopy [CA-EGD]), for the duodenal folds and the area of the ampulla, enhances visualization and targeting of lesions especially at the genu superius [22]. It also has been shown to effectively visualize the ampulla, with failure rates of only 3%–9% [23–26]. Although CA-EGD appears significantly better than standard gastroscopy to explore the papilla, comparative studies of CA-EGD versus side-viewing duodenoscopy had conflicting results [25–27]. CA-EGD can therefore be used when the location of the papilla and its relationship to the duodenal adenoma have not been definitively established. However, the use of a side-viewing endoscope remains essential when extension of the lesion to the papilla is suspected.

Indigo carmine chromoendoscopy has consistently been shown to increase detection rates especially in high risk populations [28–31]. The use of narrow-band imaging (NBI) also improved the detection capability for duodenal adenomas in a



► **Fig. 1** Sporadic duodenal adenoma: different macroscopic presentations. **a** Type 0-I with milk-white mucosa; **b** Type 0-IIa with reddish mucosa; **c** Type 0-IIa with milk-white mucosa.

prospective study in patients with FAP [21]. The magnifying NBI criteria for microsurface structures and microvessel patterns were reported to be useful to distinguish neoplastic from non-neoplastic lesions [32,33]. Considering the pit and vascular patterns in the largest retrospective study of 107 patients (114 lesions), and using a propensity score-matching analysis, NBI showed sensitivity of 92% (95%CI 86–98), specificity 79% (95%CI 67–91), positive predictive value 87% (95%CI 80–95), negative predictive value 87% (95%CI 77–97), and accuracy 87% (95%CI 81–94), with good interobserver agreement (κ coefficient 0.60–0.76) [33]. NBI was also useful for distinguishing between low and high grade dysplasia and adenocarcinoma [34–36]). Crystal violet staining appears more accurate for differentiating adenoma with low grade dysplasia from high grade dysplasia and adenocarcinoma when compared to white light endoscopy [37]. Nevertheless, it failed to show any significant superiority in a comparative retrospective study with NBI chromoendoscopy; the latter may be preferable because it is a simple, less time-consuming procedure [38].

Recent studies have reported limited diagnostic performance for endoscopic duodenal biopsy sampling [1, 32, 33, 39, 40]. A multicenter case series of 364 patients with histologically proven adenoma found significantly higher diagnostic performance for preoperative endoscopic assessment (with high resolution endoscopy) compared to biopsies, for sensitivity (77% vs. 58%, $P < 0.01$) and accuracy (75% vs. 68%, $P = 0.03$) [1]. In a retrospective analysis of 95 resected duodenal adenomas, the sensitivity of biopsies was only 37.5% (95%CI 18.8–59.4) for prediction of final histologic diagnosis of carcinoma [40]. Furthermore, preoperative biopsies can induce submucosal fibrosis that makes endoscopic resection more difficult and increases the risk of adverse events. Thus, Kinoshita et al. [40] noted a conversion from endoscopic mucosal resection (EMR) to endoscopic submucosal dissection (ESD) because of the non-lifting sign in 24.6% of cases, to which prior biopsies may have contributed.

4 Endoscopic treatment of small (<6 mm) duodenal adenomas

RECOMMENDATION

ESGE suggests cold snare polypectomy for small (<6 mm in size) nonmalignant duodenal adenomas.
Weak recommendation, low quality evidence.

Traditionally, duodenal adenomas were removed by hot snare polypectomy. However, hot snare polypectomy has associated risks of delayed bleeding, post-polypectomy syndrome, and perforation that are higher compared with those of the stomach and colon, because of the thin and vascular walls of the duodenum [41, 42].

Cold snare polypectomy is the preferred technique for removal of small duodenal adenomas <6 mm in size. The evidence for this was initially extrapolation from studies on small

colonic polyps [41, 43]. Recently, increasing evidence is supporting the use of cold snare polypectomy for small polyps in the duodenum, even in polyposis syndromes such as FAP [44–46]. In a prospective study of 30 patients, 39 lesions (mean [SD] size 3.9 [1.2] mm, range 2–6 mm) were removed via cold forceps polypectomy (9 lesions in 8 patients) or cold snare polypectomy (30 lesions in 22 patients) [47]. The en bloc resection rate was 77.8% for cold forceps polypectomy and 96.7% for cold snare polypectomy. No delayed bleeding or perforation occurred, and the recurrence rate was 0% at 3 months [47].

5 Endoscopic treatment of large duodenal adenomas

5.1 Duodenal EMR in management of large adenomas

RECOMMENDATION

ESGE recommends EMR as the first-line endoscopic resection technique for nonmalignant large nonampullary duodenal adenomas.

Strong recommendation, moderate quality evidence.

The largest prospective study on EMR of duodenal adenomas included 110 patients with 118 lesions (mean size 15 mm, range 4–70) and showed a complete resection rate of 94.1% of lesions [48]. Adverse events were noted in 22.9% (mainly delayed bleeding in 18.6% of lesions) and major adverse events occurred in 15.3% of all lesions with a procedure-related mortality of 1.7% ($n = 2$ patients) [48]. Nearly all other studies of duodenal EMR are retrospective and, when compared to EMR for similar-sized lesions elsewhere in the gastrointestinal tract, show higher rates of complications such as intraprocedural bleeding, post-procedural bleeding, and perforation [19, 42, 49–51]. In a systematic review and meta-analysis that included 440 patients with 485 duodenal nonampullary adenomas from 14 retrospective studies published up to May 2015, the mean polyp size ranged from 13 to 35 mm and complete endoscopic resection by polypectomy or EMR was achieved in 93% of lesions [52]. The overall bleeding rate including intra- and post-procedural bleeding was 16% and the pooled delayed bleeding rate was 5%. The rate of perforation was 1% and the rate of surgical intervention because of noncurative EMR or adverse events was 2%. There was no procedure-related mortality [52].

In more recent retrospective studies, high rates of complete endoscopic resection (90.5%–96.1%) have been obtained with EMR, whereas the adverse event rates ranged from 2% to 24.4% [17, 19, 53–61]. Increasing lesion size was associated with reduced rates of en bloc resection as well as increased rate of adverse events [50, 53, 55–57, 62]. However, the majority of duodenal EMR adverse events can be safely managed endoscopically [54, 55, 60].

► **Table 1** Outcomes of endoscopic mucosal resection (EMR) for superficial nonampullary duodenal lesions in recent literature.

First author, year	Participants, n (Lesions, n), Study design	En bloc resection, n/N (%)	Complete resection ¹ , n/N (%)	Overall morbidity, n/N (%)	Residual adenoma ² , n/N (%)	Recurrence, n/N (%)
Probst, 2020 [48]	110 (118), Prospective	46/118 (39.0%)	111/118 (94.1%)	27/118 (22.9%)	19/93 (20.4%)	NA
Kuroki, 2020 [17]	163 (171), Retrospective ³	152/157 (93%)	141/157 (90%)	9/157 (5.7%)	NA	2/157 (1%)
Na, 2020 [61]	92 (95), Retrospective ⁴	49/59 (83.1%)	48/59 (81.4%)	7/59 (11.9%)	NA	0/59 (0)
Zou, 2019 [58]	54 (54), Retrospective ⁵	8/21 (38.1%)	NA	2/21 (9.6%)	NA	4/21 (19%)
Tomizawa, 2018 [55]	142 (166), Retrospective	88/166 (53%)	130/142 (92%)	18/166 (11%)	NA	32/142 (23%)
Valerii, 2018 [54]	68 (75), Retrospective	42/75 (56%)	75/75 (100%)	16/75 (21.3%)	9/68 (14.5%)	6/68 (10.9%)
Klein, 2017 [63]	102 (102), Retrospective	NA	95/102 (93.1%)	19/102 (18.6%)	14/79 (17.7%)	6/55 (10%)
Valli, 2017 [56]	78 (78), Retrospective	28/78 (35.9%)	71/78 (91%)	9/78 (11.6%)	7/78 (9%)	0/78 (0)
Jamil, 2017 [53]	42 (49), Retrospective	10/49 (20.4%)	38/42 (90.5%)	10/59 (16.9%)	4/42 (9.5%)	0/32 (0)
Navaneethan, 2016 [52]	440 (485), Systematic review	– 45%	– 93% (95%CI 89–97%)	– Delayed bleeding: 5% (95%CI 2%–7%) Perforation: 1% (95%CI 1%–3%)	NA	– 15% (95%CI 7%–23%)

NA, Not available; 95%CI, 95% confidence interval.

¹ Complete resection was defined as a complete removal of the lesion after the first endoscopic treatment session.

² Residual adenoma was defined when tumoral tissue was confirmed by histology at the first endoscopic follow-up.

³ 157 lesions only treated by EMR.

⁴ 59 lesions only treated by EMR.

⁵ 21 patients only treated by EMR.

► **Table 1** summarizes the outcomes from recent EMR studies and the findings of the abovementioned systematic review [52].

5.2 Emerging and alternative EMR techniques

Underwater EMR (U-EMR) may improve duodenal EMR outcomes [59,64,65]. The filling of the lumen with water in U-EMR would theoretically limit the risk of ensnaring the muscularis propria layer. In a recent retrospective Japanese study, 104 patients underwent U-EMR for duodenal nonampullary adenomas of size ≤ 20 mm [59]. The complete resection rate without conversion to ESD was higher with U-EMR (87%) compared with conventional EMR (70%) ($P < 0.01$). There was no difference in adverse event rates between the two techniques [59].

Recently, the efficacy and safety of piecemeal cold snare EMR for large duodenal adenomas were evaluated in small retrospective series [66,67]. In a study of 15 patients with lesions ranging from 10 to 60 mm in size, the technical success rate was 100% with no cases of perforation and with only one case of delayed bleeding in a patient who was on warfarin [67].

5.3 Duodenal ESD in management of large adenomas

RECOMMENDATION

ESGE recommends that ESD for duodenal adenomas is an effective resection technique only in expert hands. Strong recommendation, low quality evidence.

RECOMMENDATION

ESGE recommends that duodenal ESD should be reserved for select indications at expert ESD centers. Strong recommendation, low quality evidence.

ESD for adenomas in the duodenum is more challenging than in other locations such as the esophagus stomach, or rectum. In expert Asian centers, larger lesions (> 20 mm) are often considered for ESD at the outset [68], whereas in Western

centers this technique is usually reserved for cases of suspected superficial submucosal invasion, or for nonmalignant lesions that are nonlifting due to de novo submucosal fibrosis or secondary to previous biopsy or incomplete resection. However, duodenal ESD is associated with a high incidence of adverse events, even in experienced centers [69–72]. Perforation incidences of 13%–50% have been reported [39, 73–79].

Since a previous ESGE Guideline that recommended against routine use of ESD in the duodenum because of its high risk of perforation [80], further series have been published, mainly from expert Asian centers. En bloc resection rates of higher than 90% have been reported, even in lesions larger than 20 mm [74, 75]. Nevertheless, more limited duodenal ESD data from Europe are available [20, 81, 82], and the largest series reported a disappointing en bloc resection rate of 29.7%, with a 14.7% recurrence rate [20]. Furthermore, comparative data analysis between EMR and ESD showed better R0 rates for large lesions with ESD but no differences in long-term outcomes and survival [20, 61, 74, 76, 82]. However, intraprocedural perforation (up to 30%) and delayed perforation was significantly associated with ESD [20, 61, 75, 77, 83]. Therefore, in most cases, the focus of duodenal endoscopic resection should primarily be on safety, rather than on achieving en bloc or R0 resection. The superior safety profile of EMR compared to ESD lends greater weight to EMR's being the first-line technique for duodenal adenomas in most cases, despite the higher recurrence rate with EMR, that may require further endoscopic therapy.

► **Table 2** shows comparative results for EMR and ESD of superficial nonampullary duodenal adenomas.

5.4 Alternative modalities to EMR or ESD for duodenal adenomas

RECOMMENDATION

ESGE suggests that, in expert hands, endoscopic full-thickness resection could be an alternative to surgery or ESD for select cases of nonlifting duodenal adenomas up to 25 mm in size without signs of deep submucosal invasion.

Weak recommendation, very low quality evidence.

Endoscopic full-thickness resection applying an over-the-scope (OTS) clip-based technique (i. e., with a full-thickness resection device [FTRD]) has been used for the resection of difficult and nonlifting duodenal lesions [84–87]. Currently, limited data from retrospective studies and small case series have shown technical success rates of 85%–100%, high rates of complete resection of the target lesion (75%–80%), and very low rates of major complications. However, these studies included heterogeneous duodenal lesions, and the FTRD has some technical limitations in the upper gastrointestinal tract (the large diameter of the bulky device makes passage through the upper esophageal sphincter and the pylorus challenging). The device size limits en bloc resection to lesions ≤ 25 mm in size [85]. Furthermore, a minimum distance of 20 mm is required between

► **Table 2** Retrospective comparative results of endoscopic mucosal resection (EMR) and endoscopic submucosal dissection (ESD) for treatment of superficial nonampullary duodenal adenomas. (Statistically significant values are in bold.)

First author, year		EMR, n/N (%)	ESD, n/N (%)	P value
Na, 2020 [61]	Complete resection	48/59 (81.4%)	8/11 (80%)	>0.99
	Morbidity	7/59 (11.9%)	5/11 (45.5%)	0.03
	Recurrence	0	0	1
Esaki, 2020 [83]	Complete resection	20/28 (71.4%)	25/28 (83.3%)	0.18
	Morbidity	1/28 (3.6%)	5/28 (17.9%)	0.19
	Recurrence	1/28 (3.6%)	0/28 (0)	1
Yahagi, 2018 [75]	Complete resection	123/146 (82.2%)	148/174 (85.1%)	0.65
	Morbidity			
	▪ Delayed bleeding	2/146 (1.4%)	9/174 (5.2%)	0.072
	▪ Perforation	1/146 (0.68%)	27/174 (15.5%)	<0.001
	Recurrence	NA	NA	–
Pérez-Cuadrado-Robles, 2018 [20]	Complete resection	43/129 (35.5%)	7/37 (19.4%)	0.069
	Morbidity			
	▪ Delayed bleeding	12/129 (9.3%)	3/37 (8.1%)	0.823
	▪ Perforation	3/129 (2.3%)	6/37 (16.2%)	0.001
	Recurrence	17/129 (16.7%)	5/37 (14.7%)	0.788
Hoteya, 2017 [77]	Complete resection	33/55 (60%)	65/74 (87.8%)	NA
	Morbidity	5/55 (9%)	22/74 (29.7%)	NA
	Recurrence	2/55 (3.6%)	0/74 (0)	NA

NA, not available.

the lesion and the major papilla, to avoid the risk of clipping and closing the bile duct or pancreatic duct, with potentially severe consequences [85].

Recent small case series have demonstrated a good safety and efficacy profile for combined laparoscopic and endoscopic surgery in patients with advanced duodenal adenomas or early adenocarcinomas [88–92]. Ichikawa et al. [92] reported no local or distant recurrence at a median follow-up of 14 months

in 10 patients with mucosal adenocarcinoma treated with combination laparoscopic and endoscopic surgery. In a retrospective observational study by Ojima et al. [91], this technique showed no adverse events (0%) compared to ESD (28%). However, larger prospective studies are needed to confirm these results.

5.5 Role of tumor-destruction techniques

RECOMMENDATION

ESGE suggests that an additive role for ablative or other tumor-destruction techniques is minimal because of lack of efficacy.

Weak recommendation, low quality evidence.

Historically, several complementary tissue destruction techniques had been used for nonampullary duodenal lesions. These included monopolar/bipolar coagulation, lasers such as the Nd-YAG [93–95], photodynamic therapy [96], and cryotherapy [97, 98]. However, most of these have been abandoned because of lack of efficacy or unacceptable adverse events [95, 96].

Argon plasma coagulation (APC) is still used [60, 99–101], although it is not effective as a primary therapy, showing adenoma recurrence rates of 39%–75% [7, 102–104]. APC has been used as an adjunctive technique to eliminate residual adenoma when technical difficulties resulted in incomplete endoscopic resection [99, 100, 104–111]. However, in one such study, the reported recurrence rate was high at 25.7% [105]. In another study by Apel et al. [99], the use of APC for residual duodenal adenoma did not lead to eradication in most of the lesions. However, a study by Alexander et al. [100] showed complete eradication of residual adenoma using APC in all 5 patients reported in the study. Given these findings, a careful endoscopic surveillance is required.

5.6 Prevention of delayed adverse events after duodenal endoscopic resection

RECOMMENDATION

ESGE recommends using techniques that minimize adverse events such as immediate or delayed bleeding or perforation. These may include piecemeal resection, defect closure techniques, noncontact hemostasis, and other emerging techniques, and these should be considered on a case-by-case basis.

Strong recommendation, low quality evidence.

RECOMMENDATION

ESGE recommends that the high adverse event rate with duodenal resection may be reduced by mucosal defect closure techniques such as endoscopic clipping or OTS clipping, and by noncontact hemostatic measures. Strong recommendation, low quality evidence.

The evidence for routine prophylactic clip closure following duodenal EMR is limited. Prophylactic through-the-scope clipping was associated with a significant reduction in delayed bleeding (0% vs. 22%, $P=0.044$) when compared to no prophylaxis, in a retrospective study involving 43 duodenal EMR sessions [50]. In a prospective study using U-EMR for 31 duodenal adenomas of size ≤ 20 mm, clip closure of the defect was performed for all lesions with no procedure-related adverse events being reported [64]. However, the risk of perforation due to clip application and large resection sites that cannot be fully closed are limiting factors, and therefore clips should be applied carefully and their use considered on a case-by-case basis.

Noncontact hemostatic products have been successfully used to minimize bleeding following duodenal EMR; however the evidence is still limited [112, 113].

In the multivariate analysis of a recent case series of duodenal ESDs, lesion location in the duodenal flexure, lesion size >40 mm, and occupied duodenal circumference of $>50\%$ were associated with increased adverse events [114]. In a recent large retrospective Japanese study involving 168 patients, the rate of delayed adverse events after duodenal ESD was significantly reduced when the mucosal defect was completely closed, compared with only partial closure or no closure (1.7% vs. 25% vs. 15.6%, respectively, $P<0.01$) [115]. These data were confirmed by two more studies where delayed bleeding was effectively prevented by prophylactic endoscopic closure of the defect [18, 116]. Recently, closure of the defect by OTS clipping has also been shown to be effective in reducing delayed adverse events after ESD [117]. Furthermore, the additional use of conventional through-the-scope clips, to cover the inverted submucosa after defect closure with OTS clipping, was found to significantly reduce the risk of delayed bleeding [118].

6 Follow-up, risk and management of recurrence after endoscopic duodenal resection

RECOMMENDATION

ESGE recommends that recurrences after endoscopic treatment for superficial nonampullary duodenal lesions can be managed endoscopically, if this is deemed technically feasible and in the absence of suspected malignancy.

Strong recommendation, low quality evidence.

RECOMMENDATION

ESGE suggests that the choice of endoscopic technique to manage recurrent adenoma should be left to the discretion of the endoscopist, according to the morphology of the lesion and patient characteristics.
Weak recommendation, very low quality evidence.

RECOMMENDATION

ESGE recommends endoscopic surveillance 3 months after the index treatment. In cases of no recurrence, a further follow-up endoscopy should be done 1 year later. Thereafter, surveillance intervals should be adapted to the lesion site, en bloc resection status, and initial histological result.
Strong recommendation, low quality evidence.

Over a median follow-up period ranging from 6 to 72 months, the local recurrence rate after EMR was 15% (95%CI 7%–23%) in the largest review of the literature [52]. Advanced histopathology, defined as the presence of villous changes (OR 4.86, 95%CI 1.62–14.63) or high grade dysplasia, was shown to increase the risk of local recurrence [52, 56, 62]. Similarly, increasing lesion size was associated with a higher recurrence rate [19, 52, 55, 63, 106]. With regard to the techniques originally used to remove the lesion, no significant difference in recurrence rate was observed between EMR versus ESD or EMR versus hybrid ESD [18, 81]. After a median follow-up of 6.5 months (2–125), Pérez-Cuadrado-Robles et al. [20] showed 5/37 recurrences (14.7%) after ESD and 17/129 (16.7%) after EMR ($P=0.788$). Furthermore, there were no demonstrable differences in recurrence rates between en bloc or piecemeal EMR in the largest review of duodenal EMR studies [52].

The available studies have shown that recurrent lesions are usually small in size and can be successfully treated endoscopically in most cases by an expert endoscopist [19, 119]. In the review from Navaneethan et al., six studies reported the outcomes of managing recurrent adenoma, and further endoscopic therapy was successful in 62% (95%CI 37%–87%) [52]. In the absence of relevant comparative data, no specific endoscopic technique could be preferentially recommended to manage adenoma recurrence.

Regarding the surveillance interval after index endoscopy, expert opinions are in favor of a first endoscopy at 3–6 months. The evidence for this approach is limited, but it has been recently supported by a prospective study showing that at 3 months, residual or recurrent adenoma was noted in 20.4% of patients who then had endoscopic re-treatment [48]. Valerii et al. [54] retrospectively reported 15 recurrences in 62 lesions, with 9 of them (60%) being found at the first follow-up endoscopy performed 3 months after the initial endoscopic treatment. A second surveillance endoscopy 1 year later seems to be advisable, if no residual or recurrent adenoma has been detected during the first surveillance endoscopy [41, 48, 52, 120].

Subsequent surveillance intervals should then be individualized, taking into account lesion factors (size, high grade dysplasia, or villous component) and patient factors (age, comorbidities) [52]. Late recurrences are uncommon, but possible.

7 Role of surgery for nonmalignant sporadic duodenal adenomas

The literature on duodenal surgery for SNADT is limited and mainly consists of studies on patients with FAP, as detailed in the ESGE Guideline for FAP [2]. For sporadic nonmalignant duodenal lesions, less invasive options such as transduodenal excision and segmental duodenal resection are preferred compared with pancreaticoduodenectomy or pancreas-sparing duodenectomy, as the less invasive approaches demonstrate lower morbidity rates [121–124]. A retrospective study of 86 patients showed morbidity rates of 17% after transduodenal excision compared with 40% and 45% after pancreaticoduodenectomy and pancreas sparing duodenectomy, respectively [121]. In three other retrospective studies, the morbidity rate for pancreaticoduodenectomy was significantly higher compared to the less invasive transduodenal excision or segmental duodenal resection [7, 122, 125]. However, a 5-year recurrence rate of 32% after transduodenal excision for villous adenomas is reported [121]. Therefore, postoperative endoscopic surveillance is mandatory after surgery, and endoscopic resection of recurrences following surgery is still possible [125].

In a cohort of 121 patients with nonampullary duodenal lesions, 91 were treated by EMR, as opposed to surgical therapy with pancreas-sparing duodenectomy [125]. The recurrence rate during follow-up was significantly higher in the EMR than in the surgical group (32% vs. 0%, $P<0.001$). However, there was a trend towards higher adverse event rates in the surgical group than in the EMR group (26% vs. 15%), although it should be noted that larger and more advanced lesions had been treated in the surgical group [125]. Other studies have also shown lower mortality and morbidity, shorter procedural time and shorter hospital stay in endoscopically treated patients [7, 118, 122, 124]. Therefore, while adenoma recurrence is low following pancreas-sparing duodenectomies, the high morbidity and mortality associated with these procedures make them options of last resort for most cases of sporadic duodenal adenoma [7, 125].

Finally, in cases of confirmed duodenal malignancy, an oncological resection including lymph node dissection, such as achieved by pancreaticoduodenectomy is required, whereas pancreas-sparing duodenectomy and transduodenal excision are not oncological resections and are reserved for premalignant lesions only.

Disclaimer

The legal disclaimer for ESGE guidelines [126] applies to this Guideline.

Acknowledgments

ESGE wishes to thank, for the added value they have brought to the final manuscript, the two external reviewers, Professor Schalk van der Merwe of the University Hospital-Gasthuisberg, University of Leuven, Belgium, and Dr. Udayakumar Navaneethan, Digestive Health Institute, Orlando, Florida, USA, and also Drs. Khalil Bedran, St George Hospital University Medical Center, Beirut, Lebanon, Marco Bustamente-Balén, La Fe University Hospital, Valencia, Spain, Gertran Rasschaert, Universitair Ziekenhuis Brussel, Belgium, and Suzane Ribeiro, Ghent University Hospital, Belgium, for their comments.

Competing interests

M. Arvanitakis has received lecture fees from Olympus. T. Beyna provides consultancy to and gives lectures for Boston Scientific and Cook Medical (ongoing). J.E. van Hooft's department has received research grants from Cook Medical (from 2014 to 2019) and Abbott (from 2014 to 2017); she has received lecture fees from Medtronic (from 2014 to 2015, 2019) and Cook Medical (from 2019); and she has received consultancy fees from Boston Scientific (from 2014 to 2017). G. Vanbiervliet has provided consultancy to Boston Scientific and Cook Medical (both from 2019 to present). U. Arnelo, M. Barthet, O. Busch, P. Deprez, A. Larghi, G. Manes, A. Moss, K. Nalankilli, B. Napoleon, M. Nayar, E. Pérez-Cuadrado-Robles, L. Kunovsky, S. Seewald, and M. Strijker, declare that they have no conflicts of interest.

References

- [1] Goda K, Kikuchi D, Yamamoto Y et al. Endoscopic diagnosis of superficial non-ampullary duodenal epithelial tumors in Japan: Multi-center case series. *Dig Endosc* 2014; 26: (Suppl. 02): 23–29
- [2] van Leerdam ME, Roos VH, van Hooft JE et al. Endoscopic management of polyposis syndromes: European Society of Gastrointestinal Endoscopy (ESGE) Guideline. *Endoscopy* 2019; 51: 877–895
- [3] Jung SH, Chung WC, Kim EJ et al. Evaluation of non-ampullary duodenal polyps: comparison of non-neoplastic and neoplastic lesions. *World J Gastroenterol* 2010; 16: 5474–5480
- [4] Höchter W, Weingart J, Seib HJ et al. [Duodenal polyps. Incidence, histologic substrate and significance] [Article in German]. *Dtsch Med Wochenschr* 1984; 109: 1183–1186
- [5] Jepsen JM, Persson M, Jakobsen NO et al. Prospective study of prevalence and endoscopic and histopathologic characteristics of duodenal polyps in patients submitted to upper endoscopy. *Scand J Gastroenterol* 1994; 29: 483–487
- [6] Alkhatib AA. Sporadic nonampullary tubular adenoma of the duodenum: Prevalence and patients' characteristics. *Turk J Gastroenterol* 2019; 30: 112–113
- [7] Johnson MD, Mackey R, Brown N et al. Outcome based on management for duodenal adenomas: sporadic versus familial disease. *J Gastrointest Surg* 2010; 14: 229–235
- [8] Syngal S, Brand RE, Church JM et al. ACG clinical guideline: Genetic testing and management of hereditary gastrointestinal cancer syndromes. *Am J Gastroenterol* 2015; 110: 223–262; quiz 263
- [9] Matsuzaki J, Suzuki H, Shimoda M et al. Clinical and endoscopic findings to assist the early detection of duodenal adenoma and adenocarcinoma. *United Eur Gastroenterol J* 2019; 7: 250–260
- [10] Bisschops R, Areia M, Coron E et al. Performance measures for upper gastrointestinal endoscopy: a European Society of Gastrointestinal Endoscopy (ESGE) Quality Improvement Initiative. *Endoscopy* 2016; 48: 843–864
- [11] Wu Z-J, Lin Y, Xiao J et al. Clinical significance of colonoscopy in patients with upper gastrointestinal polyps and neoplasms: a meta-analysis. *PLoS One* 2014; 9: e91810
- [12] Genta RM, Hurrell JM, Sonnenberg A. Duodenal adenomas coincide with colorectal neoplasia. *Dig Dis Sci* 2014; 59: 2249–2254
- [13] Okada K, Fujisaki J, Kasuga A et al. Sporadic nonampullary duodenal adenoma in the natural history of duodenal cancer: a study of follow-up surveillance. *Am J Gastroenterol* 2011; 106: 357–364
- [14] Niwa A, Kuwano S, Tomita H et al. The different pathogeneses of sporadic adenoma and adenocarcinoma in non-ampullary lesions of the proximal and distal duodenum. *Oncotarget* 2017; 8: 41078–41090
- [15] Toya Y, Endo M, Akasaka R et al. Clinicopathological features and magnifying chromoendoscopic findings of non-ampullary duodenal epithelial tumors. *Digestion* 2018; 97: 219–227
- [16] Tsuji S, Doyama H, Tsuji K et al. Preoperative endoscopic diagnosis of superficial non-ampullary duodenal epithelial tumors, including magnifying endoscopy. *World J Gastroenterol* 2015; 21: 11832–11841
- [17] Kuroki K, Sanomura Y, Oka S et al. Clinical outcomes of endoscopic resection for superficial non-ampullary duodenal tumors. *Endosc Int Open* 2020; 8: E354–E359
- [18] Pérez-Cuadrado-Robles E, Quénéhervé L, Margos W et al. ESD versus EMR in non-ampullary superficial duodenal tumors: a systematic review and meta-analysis. *Endosc Int Open* 2018; 6: E998–E1007
- [19] Klein A, Nayyar D, Bahin FF et al. Endoscopic mucosal resection of large and giant lateral spreading lesions of the duodenum: success, adverse events, and long-term outcomes. *Gastrointest Endosc* 2016; 84: 688–696
- [20] Pérez-Cuadrado-Robles E, Quénéhervé L, Margos W et al. Comparative analysis of ESD versus EMR in a large European series of non-ampullary superficial duodenal tumors. *Endosc Int Open* 2018; 6: E1008–E1014
- [21] Lopez-Ceron M, van den Broek FJC, Mathus-Vliegen EM et al. The role of high-resolution endoscopy and narrow-band imaging in the evaluation of upper GI neoplasia in familial adenomatous polyposis. *Gastrointest Endosc* 2013; 77: 542–550
- [22] Yap CK, Ng HS. Cap-fitted gastroscopy improves visualization and targeting of lesions. *Gastrointest Endosc* 2001; 53: 93–95
- [23] Choi YR, Han J-H, Cho YS et al. Efficacy of cap-assisted endoscopy for routine examining the ampulla of Vater. *World J Gastroenterol* 2013; 19: 2037–2043
- [24] Kallenberg FGJ, Bastiaansen BAJ, Dekker E. Cap-assisted forward-viewing endoscopy to visualize the ampulla of Vater and the duodenum in patients with familial adenomatous polyposis. *Endoscopy* 2017; 49: 181–185
- [25] Abdelhafez M, Phillip V, Hapfelmeier A et al. Cap assisted upper endoscopy for examination of the major duodenal papilla: a randomized, blinded, controlled crossover study (CAPPa Study). *Am J Gastroenterol* 2017; 112: 725–733
- [26] Abdelhafez M, Phillip V, Hapfelmeier A et al. Comparison of cap-assisted endoscopy vs. side-viewing endoscopy for examination of the major duodenal papilla: a randomized, controlled, non-inferiority crossover study. *Endoscopy* 2019; 51: 419–426
- [27] Shi X, Luo H, Ning B et al. Effect of cap-assisted esophagogastroduodenoscopy on examination of the major duodenal papilla: a non-inferior, randomized controlled trial. *Endoscopy* 2019; 51: 427–435

- [28] Kiesslich R, Mergener K, Naumann C et al. Value of chromoendoscopy and magnification endoscopy in the evaluation of duodenal abnormalities: a prospective, randomized comparison. *Endoscopy* 2003; 35: 559–563
- [29] Picasso M, Filiberti R, Bianchi S et al. The role of chromoendoscopy in the surveillance of the duodenum of patients with familial adenomatous polyposis. *Dig Dis Sci* 2007; 52: 1906–1909
- [30] Dekker E, Boparai KS, Poley JW et al. High resolution endoscopy and the additional value of chromoendoscopy in the evaluation of duodenal adenomatosis in patients with familial adenomatous polyposis. *Endoscopy* 2009; 41: 666–669
- [31] Hurley JJ, Thomas LE, Walton S-J et al. The impact of chromoendoscopy for surveillance of the duodenum in patients with MUTYH-associated polyposis and familial adenomatous polyposis. *Gastrointest Endosc* 2018; 88: 665–673
- [32] Shahid MW, Buchner A, Gomez V et al. Diagnostic accuracy of probe-based confocal laser endomicroscopy and narrow band imaging in detection of dysplasia in duodenal polyps. *J Clin Gastroenterol* 2012; 46: 382–389
- [33] Yamasaki Y, Takeuchi Y, Kanesaka T et al. Differentiation between duodenal neoplasms and non-neoplasms using magnifying narrow-band imaging – Do we still need biopsies for duodenal lesions? *Dig Endosc* 2020; 32: 84–95
- [34] Yoshimura N, Goda K, Tajiri H et al. Endoscopic features of nonampullary duodenal tumors with narrow-band imaging. *Hepatogastroenterology* 2010; 57: 462–467
- [35] Kikuchi D, Hoteya S, Iizuka T et al. Diagnostic algorithm of magnifying endoscopy with narrow band imaging for superficial non-ampullary duodenal epithelial tumors. *Dig Endosc* 2014; 26: (Suppl. 02): 16–22
- [36] Kakushima N, Yoshida M, Yamaguchi Y et al. Magnified endoscopy with narrow-band imaging for the differential diagnosis of superficial non-ampullary duodenal epithelial tumors. *Scand J Gastroenterol* 2019; 54: 128–134
- [37] Toya Y, Endo M, Oizumi T et al. Diagnostic algorithm of magnifying endoscopy with crystal violet staining for non-ampullary duodenal epithelial tumors. *Dig Endosc* 2020; 32: 1066–1073
- [38] Mizumoto T, Sanomura Y, Tanaka S et al. Clinical usefulness of magnifying endoscopy for non-ampullary duodenal tumors. *Endosc Int Open* 2017; 5: E297–E302
- [39] Kakushima N, Kanemoto H, Sasaki K et al. Endoscopic and biopsy diagnoses of superficial, nonampullary, duodenal adenocarcinomas. *World J Gastroenterol* 2015; 21: 5560–5567
- [40] Kinoshita S, Nishizawa T, Ochiai Y et al. Accuracy of biopsy for the preoperative diagnosis of superficial nonampullary duodenal adenocarcinoma. *Gastrointest Endosc* 2017; 86: 329–332
- [41] Ma MX, Bourke MJ. Management of duodenal polyps. *Best Pract Res Clin Gastroenterol* 2017; 31: 389–399
- [42] Chen W-C, Wallace MB. Endoscopic management of mucosal lesions in the gastrointestinal tract. *Expert Rev Gastroenterol Hepatol* 2016; 10: 481–495
- [43] Ferlitsch M, Moss A, Hassan C et al. Colorectal polypectomy and endoscopic mucosal resection (EMR): European Society of Gastrointestinal Endoscopy (ESGE) Clinical Guideline. *Endoscopy* 2017; 49: 270–297
- [44] Hamada K, Takeuchi Y, Ishikawa H et al. Feasibility of cold snare polypectomy for multiple duodenal adenomas in patients with familial adenomatous polyposis: a pilot study. *Dig Dis Sci* 2016; 61: 2755–2759
- [45] Patel NJ, Ponugoti PL, Rex DK. Cold snare polypectomy effectively reduces polyp burden in familial adenomatous polyposis. *Endosc Int Open* 2016; 4: E472–474
- [46] Hamada K, Takeuchi Y, Ishikawa H et al. Safety of cold snare polypectomy for duodenal adenomas in familial adenomatous polyposis: a prospective exploratory study. *Endoscopy* 2018; 50: 511–517
- [47] Maruoka D, Matsumura T, Kasamatsu S et al. Cold polypectomy for duodenal adenomas: a prospective clinical trial. *Endoscopy* 2017; 49: 776–783
- [48] Probst A, Freund S, Neuhaus L et al. Complication risk despite preventive endoscopic measures in patients undergoing endoscopic mucosal resection of large duodenal adenomas. *Endoscopy* 2020; 52: 847–855
- [49] Fanning SB, Bourke MJ, Williams SJ et al. Giant laterally spreading tumors of the duodenum: endoscopic resection outcomes, limitations, and caveats. *Gastrointest Endosc* 2012; 75: 805–812
- [50] Lépilliez V, Chemaly M, Ponchon T et al. Endoscopic resection of sporadic duodenal adenomas: an efficient technique with a substantial risk of delayed bleeding. *Endoscopy* 2008; 40: 806–810
- [51] Bourke MJ. Endoscopic resection in the duodenum: current limitations and future directions. *Endoscopy* 2013; 45: 127–132
- [52] Navaneethan U, Hasan MK, Lourdasamy V et al. Efficacy and safety of endoscopic mucosal resection of non-ampullary duodenal polyps: a systematic review. *Endosc Int Open* 2016; 4: E699–708
- [53] Jamil LH, Kashani A, Peter N et al. Safety and efficacy of cap-assisted EMR for sporadic nonampullary duodenal adenomas. *Gastrointest Endosc* 2017; 86: 666–672
- [54] Valerii G, Tringali A, Landi R et al. Endoscopic mucosal resection of non-ampullary sporadic duodenal adenomas: a retrospective analysis with long-term follow-up. *Scand J Gastroenterol* 2018; 53: 490–494
- [55] Tomizawa Y, Ginsberg GG. Clinical outcome of EMR of sporadic, non-ampullary, duodenal adenomas: a 10-year retrospective. *Gastrointest Endosc* 2018; 87: 1270–1278
- [56] Valli PV, Mertens JC, Sonnenberg A et al. Nonampullary duodenal adenomas rarely recur after complete endoscopic resection: a Swiss experience including a literature review. *Digestion* 2017; 96: 149–157
- [57] Singh A, Siddiqui UD, Konda VJ et al. Safety and efficacy of EMR for sporadic, nonampullary duodenal adenomas: a single U.S. center experience (with video). *Gastrointest Endosc* 2016; 84: 700–8
- [58] Zou J, Chai N, Linghu E et al. Clinical outcomes of endoscopic resection for non-ampullary duodenal laterally spreading tumors. *Surg Endosc* 2019; 33: 4048–4056
- [59] Kiguchi Y, Kato M, Nakayama A et al. Feasibility study comparing underwater endoscopic mucosal resection and conventional endoscopic mucosal resection for superficial non-ampullary duodenal epithelial tumor < 20 mm. *Dig Endosc* 2020; 32: 753–760
- [60] Cosgrove N, Siddiqui AA, Kistler CA et al. Endoscopic mucosal resection of large non-ampullary duodenal polyps: technical aspects and long-term therapeutic outcomes. *Minerva Gastroenterol Dietol* 2016; 62: 131–137
- [61] Na HK, Kim DH, Ahn JY et al. Clinical outcomes following endoscopic treatment for sporadic nonampullary duodenal adenoma. *Dig Dis* 2020; 38: 364–372
- [62] Cassani LS, Lanke G, Chen H-C et al. Comparison of nonampullary duodenal adenomas in patients with familial adenomatous polyposis versus patients with sporadic adenomas. *Gastrointest Endosc* 2017; 85: 803–812
- [63] Klein A, Ahlenstiel G, Tate DJ et al. Endoscopic resection of large duodenal and papillary lateral spreading lesions is clinically and economically advantageous compared with surgery. *Endoscopy* 2017; 49: 659–667
- [64] Yamasaki Y, Uedo N, Takeuchi Y et al. Underwater endoscopic mucosal resection for superficial nonampullary duodenal adenomas. *Endoscopy* 2018; 50: 154–158

- [65] Shibukawa G, Irisawa A, Sato A et al. Endoscopic mucosal resection performed underwater for nonampullary duodenal epithelial tumor: evaluation of feasibility and safety. *Gastroenterol Res Pract* 2018; doi:10.1155/2018/7490961
- [66] Javia SB, Chathadi K. Cold snare piecemeal endoscopic mucosal resection of a very large duodenal adenoma. *Endoscopy* 2019; 51: E217–E218
- [67] Choksi N, Elmunzer BJ, Stidham RW et al. Cold snare piecemeal resection of colonic and duodenal polyps ≥ 1 cm. *Endosc Int Open* 2015; 3: E508–E513
- [68] Ochiai Y, Kato M, Kiguchi Y et al. Current status and challenges of endoscopic treatments for duodenal tumors. *Digestion* 2019; 99: 21–26
- [69] Shibagaki K, Ishimura N, Kinoshita Y. Endoscopic submucosal dissection for duodenal tumors. *Ann Transl Med* 2017; 5: 188
- [70] Yamamoto Y, Yoshizawa N, Tomida H et al. Therapeutic outcomes of endoscopic resection for superficial non-ampullary duodenal tumor. *Dig Endosc* 2014; 26: (Suppl. 02): 50–56
- [71] Maple JT, Abu Dayyeh BK, Chauhan SS et al. Endoscopic submucosal dissection. *Gastrointest Endosc* 2015; 81: 1311–1325
- [72] Deprez PH, Bergman JJ, Meisner S et al. Current practice with endoscopic submucosal dissection in Europe: position statement from a panel of experts. *Endoscopy* 2010; 42: 853–858
- [73] Jung JH, Choi KD, Ahn JY et al. Endoscopic submucosal dissection for sessile, non-ampullary duodenal adenomas. *Endoscopy* 2013; 45: 133–135
- [74] Matsumoto S, Yoshida Y. Selection of appropriate endoscopic therapies for duodenal tumors: an open-label study, single-center experience. *World J Gastroenterol* 2014; 20: 8624–8630
- [75] Yahagi N, Kato M, Ochiai Y et al. Outcomes of endoscopic resection for superficial duodenal epithelial neoplasia. *Gastrointest Endosc* 2018; 88: 676–682
- [76] Honda T, Yamamoto H, Osawa H et al. Endoscopic submucosal dissection for superficial duodenal neoplasms. *Dig Endosc* 2009; 21: 270–274
- [77] Hoteya S, Furuhashi T, Takahito T et al. Endoscopic submucosal dissection and endoscopic mucosal resection for non-ampullary superficial duodenal tumor. *Digestion* 2017; 95: 36–42
- [78] Hoteya S, Yahagi N, Iizuka T et al. Endoscopic submucosal dissection for non-ampullary large superficial adenocarcinoma/adenoma of the duodenum: feasibility and long-term outcomes. *Endosc Int Open* 2013; 1: 2–7
- [79] Nonaka S, Oda I, Tada K et al. Clinical outcome of endoscopic resection for nonampullary duodenal tumors. *Endoscopy* 2015; 47: 129–135
- [80] Pimentel-Nunes P, Dinis-Ribeiro M, Ponchon T et al. Endoscopic submucosal dissection: European Society of Gastrointestinal Endoscopy (ESGE) Guideline. *Endoscopy* 2015; 47: 829–854
- [81] Basford PJ, George R, Nixon E et al. Endoscopic resection of sporadic duodenal adenomas: comparison of endoscopic mucosal resection (EMR) with hybrid endoscopic submucosal dissection (ESD) techniques and the risks of late delayed bleeding. *Surg Endosc* 2014; 28: 1594–1600
- [82] Santos-Antunes J, Baldaque-Silva F, Marques M et al. Real-life evaluation of the safety, efficacy and therapeutic outcomes of endoscopic submucosal dissection in a Western tertiary centre. *United Eur Gastroenterol J* 2018; 6: 702–709
- [83] Esaki M, Haraguchi K, Akahoshi K et al. Endoscopic mucosal resection vs endoscopic submucosal dissection for superficial non-ampullary duodenal tumors. *World J Gastrointest Oncol* 2020; 12: 918–930
- [84] Andrisani G, Di Matteo FM. Endoscopic full-thickness resection of duodenal lesions (with video). *Surg Endosc* 2020; 34: 1876–1881
- [85] Bauder M, Schmidt A, Caca K. Endoscopic full-thickness resection of duodenal lesions—a retrospective analysis of 20 FTRD cases. *United Eur Gastroenterol J* 2018; 6: 1015–1021
- [86] Schmidt A, Meier B, Cahyadi O et al. Duodenal endoscopic full-thickness resection (with video). *Gastrointest Endosc* 2015; 82: 728–733
- [87] Schmidt A, Beyna T, Schumacher B et al. Colonoscopic full-thickness resection using an over-the-scope device: a prospective multicentre study in various indications. *Gut* 2018; 67: 1280–1289
- [88] Ohata K, Nonaka K, Sakai E et al. Novel technique of endoscopic full-thickness resection for superficial nonampullary duodenal neoplasms to avoid intraperitoneal tumor dissemination. *Endosc Int Open* 2016; 4: E784–E787
- [89] Irino T, Nunobe S, Hiki N et al. Laparoscopic-endoscopic cooperative surgery for duodenal tumors: a unique procedure that helps ensure the safety of endoscopic submucosal dissection. *Endoscopy* 2015; 47: 349–351
- [90] Kakushima N, Yoshida M, Yabuuchi Y et al. Present status of endoscopic submucosal dissection for non-ampullary duodenal epithelial tumors. *Clin Endosc* 2020; 53: 652–658
- [91] Ojima T, Nakamori M, Nakamura M et al. Laparoscopic and endoscopic cooperative surgery versus endoscopic submucosal dissection for the treatment of low-risk tumors of the duodenum. *J Gastrointest Surg* 2018; 22: 935–940
- [92] Ichikawa D, Komatsu S, Dohi O et al. Laparoscopic and endoscopic co-operative surgery for non-ampullary duodenal tumors. *World J Gastroenterol* 2016; 22: 10424–10431
- [93] Ghilain JM, Dive C. Endoscopic laser therapy for small villous adenomas of the duodenum. *Endoscopy* 1994; 26: 308–310
- [94] Paraf F, Naveau S, Zourabichvili O et al. Endoscopic laser therapy for duodenal villous adenoma. *Dig Dis Sci* 1989; 34: 1466–1467
- [95] Norton ID, Geller A, Petersen BT et al. Endoscopic surveillance and ablative therapy for periampullary adenomas. *Am J Gastroenterol* 2001; 96: 101–106
- [96] Milkvy P, Messmann H, Debinski H et al. Photodynamic therapy for polyps in familial adenomatous polyposis – a pilot study. *Eur J Cancer* 1995; 31A: 1160–1165
- [97] Ooka K, Celli R, Farrell JJ. Cryoablation of a duodenal adenoma with intramucosal carcinoma. *VideoGIE* 2017; 2: 244–246
- [98] Raphael KL, Benias PC, Trindade AJ. Salvage CryoBalloon cryotherapy ablation for a duodenal adenoma. *Endoscopy* 2020; 52: E189–E190
- [99] Apel D, Jakobs R, Spiethoff A et al. Follow-up after endoscopic snare resection of duodenal adenomas. *Endoscopy* 2005; 37: 444–448
- [100] Alexander S, Bourke MJ, Williams SJ et al. EMR of large, sessile, sporadic non-ampullary duodenal adenomas: technical aspects and long-term outcome (with videos). *Gastrointest Endosc* 2009; 69: 66–73
- [101] Koritala T, Zolotarevsky E, Bartley AN et al. Efficacy and safety of the band and slough technique for endoscopic therapy of non-ampullary duodenal adenomas: a case series. *Gastrointest Endosc* 2015; 81: 985–988
- [102] Jaganmohan S, Lynch PM, Raju RP et al. Endoscopic management of duodenal adenomas in familial adenomatous polyposis—a single-center experience. *Dig Dis Sci* 2012; 57: 732–737
- [103] Fawal H, Gambiez L, Raad A et al. Management of duodenal adenomatosis in patients with familial adenomatous polyposis. *Ann Chir* 2003; 128: 594–598
- [104] Min YW, Min B-H, Kim ER et al. Efficacy and safety of endoscopic treatment for nonampullary sporadic duodenal adenomas. *Dig Dis Sci* 2013; 58: 2926–2932
- [105] Navaneethan U, Lourdasamy D, Mehta D et al. Endoscopic resection of large sporadic non-ampullary duodenal polyps: efficacy and long-term recurrence. *Surg Endosc* 2014; 28: 2616–2622

- [106] Abbass R, Rigaux J, Al-Kawas FH. Non-ampullary duodenal polyps: characteristics and endoscopic management. *Gastrointest Endosc* 2010; 71: 754–759
- [107] Aschmoneit-Messer I, Richl J, Pohl J et al. Prospective study of acute complication rates and associated risk factors in endoscopic therapy for duodenal adenomas. *Surg Endosc* 2015; 29: 1823–1830
- [108] Tsiamoulos ZP, Peake ST, Bourikas LA et al. Endoscopic mucosal ablation: a novel technique for a giant non-ampullary duodenal adenoma. *Endoscopy* 2013; 45: (Suppl. 02): E12–E13
- [109] Kedia P, Brensinger C, Ginsberg G. Endoscopic predictors of successful endoluminal eradication in sporadic duodenal adenomas and its acute complications. *Gastrointest Endosc* 2010; 72: 1297–1301
- [110] Manner H, May A, Rabenstein T et al. Prospective evaluation of a new high-power argon plasma coagulation system (hp-APC) in therapeutic gastrointestinal endoscopy. *Scand J Gastroenterol* 2007; 42: 397–405
- [111] Eswaran SL, Sanders M, Bernadino KP et al. Success and complications of endoscopic removal of giant duodenal and ampullary polyps: a comparative series. *Gastrointest Endosc* 2006; 64: 925–932
- [112] Leblanc S, Vienne A, Dhooge M et al. Early experience with a novel hemostatic powder used to treat upper GI bleeding related to malignancies or after therapeutic interventions (with videos). *Gastrointest Endosc* 2013; 78: 169–175
- [113] Naseer M, Lambert K, Hamed A et al. Endoscopic advances in the management of non-variceal upper gastrointestinal bleeding: A review. *World J Gastrointest Endosc* 2020; 12: 1–16
- [114] Kato M, Sasaki M, Mizutani M et al. Predictors of technical difficulty with duodenal ESD. *Endosc Int Open* 2019; 7: E1755–E1760
- [115] Kato M, Ochiai Y, Fukuhara S et al. Clinical impact of closure of the mucosal defect after duodenal endoscopic submucosal dissection. *Gastrointest Endosc* 2019; 89: 87–93
- [116] Hoteya S, Kaise M, Iizuka T et al. Delayed bleeding after endoscopic submucosal dissection for non-ampullary superficial duodenal neoplasias might be prevented by prophylactic endoscopic closure: analysis of risk factors. *Dig Endosc* 2015; 27: 323–330
- [117] Tashima T, Ohata K, Sakai E et al. Efficacy of an over-the-scope clip for preventing adverse events after duodenal endoscopic submucosal dissection: a prospective interventional study. *Endoscopy* 2018; 50: 487–496
- [118] Ohata K, Sakai E, Suzuki Y et al. Risk factors of delayed bleeding after endoscopic resection of superficial non-ampullary duodenal epithelial tumors and prevention by over-the-scope and conventional clipping. *Dig Endosc* 20.05 2020: doi:10.1111/den.13729
- [119] Kakushima N, Kanemoto H, Tanaka M et al. Treatment for superficial non-ampullary duodenal epithelial tumors. *World J Gastroenterol* 2014; 20: 12501–12508
- [120] Gaspar JP, Stelow EB, Wang AY. Approach to the endoscopic resection of duodenal lesions. *World J Gastroenterol* 2016; 22: 600–617
- [121] Farnell MB, Sakorafas GH, Sarr MG et al. Villous tumors of the duodenum: reappraisal of local vs. extended resection. *J Gastrointest Surg* 2000; 4: 13–21, discussion 22–23
- [122] Perez A, Saltzman JR, Carr-Locke DL et al. Benign non-ampullary duodenal neoplasms. *J Gastrointest Surg* 2003; 7: 536–541
- [123] Bjork KJ, Davis CJ, Nagorney DM et al. Duodenal villous tumors. *Arch Surg* 1990; 125: 961–965
- [124] Xu M, Wu J, Yu L et al. Surgical versus endoscopic resection of large sessile duodenal and papillary lesions. *Eur J Gastroenterol Hepatol* 2020; 32: 48–53
- [125] Bartel MJ, Puri R, Brahmhatt B et al. Endoscopic and surgical management of nonampullary duodenal neoplasms. *Surg Endosc* 2018; 32: 2859–2869
- [126] Hassan C, Ponchon T, Bisschops R et al. European Society of Gastrointestinal Endoscopy (ESGE) Publications Policy – Update 2020. *Endoscopy* 2020; 52: 123–126