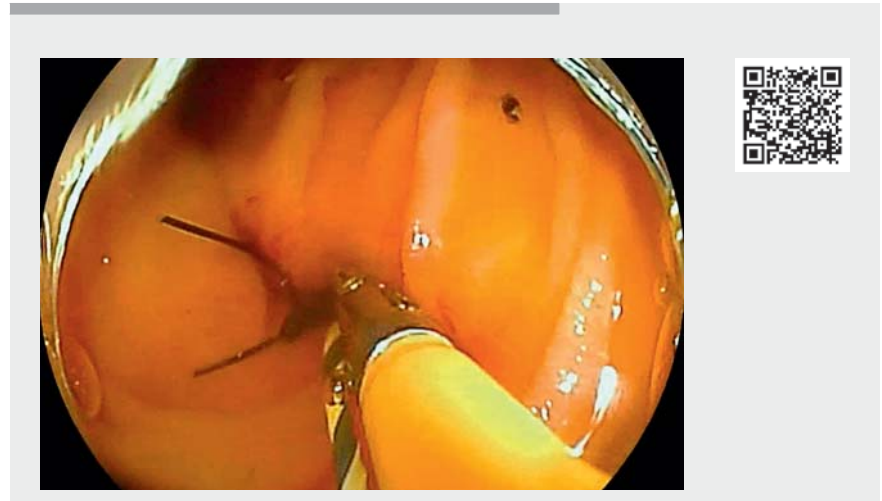


The “zipline” technique for double-balloon enteroscopy-assisted removal of a migrated stent in a peripheral bile duct

Double-balloon enteroscopy-assisted endoscopic retrograde cholangiopancreatography (DBE-ERCP) facilitates management of pancreatobiliary disorders in cases with surgically altered anatomy [1–3]. However, owing to difficulties in positioning the biliary orifice and obtaining a suitable angulation of the bile duct and endoscope, it can be challenging to access a peripheral bile duct during DBE-ERCP. Here we present a case where a migrated stent in the bile duct at segment III (B3) was successfully removed using the previously reported technique (▶ **Video 1**) [4].

A 61-year-old man with a history of Roux-en-Y reconstruction was referred to our institution for management of a migrated plastic stent (▶ **Fig. 1**). We inserted a double balloon endoscope (EI-580BT; Fujifilm, Tokyo, Japan) and removed a plastic stent placed across the anastomosis site using a snare. Following biliary cannulation, a 0.025-inch guidewire was passed into B3. While we were attempting to grasp the migrated stent using a wire-guided basket catheter after balloon dilation of the anastomosis site, the stent migrated further into the peripheral portion of B3. Therefore, we added a looped nylon thread to one cup of the forceps (Radial Jaw 4 pediatric; Boston Scientific, Natick, Massachusetts, USA) and inserted the forceps with the loop over the prepositioned guidewire (▶ **Fig. 2**). The stent was readily grasped and withdrawn to the jejunum. We then withdrew the stent through the endoscope using the snare. Radial Jaw has been one of the most popular series of biopsy forceps and has hole(s) at each cup that enable the at-



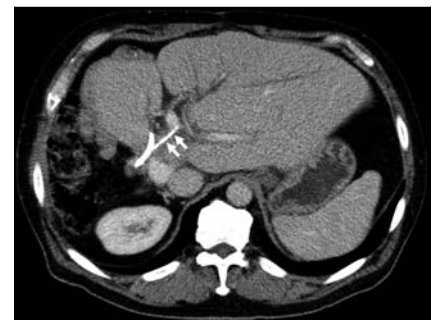▶ **Video 1** The “zipline” technique utilized to access a peripheral bile duct and remove a migrated plastic stent during double-balloon enteroscopy-assisted endoscopic retrograde cholangiopancreatography.

tachment of a looped thread. Wire-guided biopsy forceps are not available for DBE-ERCP owing to the limited length of the shaft [5]. The “zipline” technique during DBE-ERCP may facilitate target biopsy of the peripheral bile duct as well as stent removal.

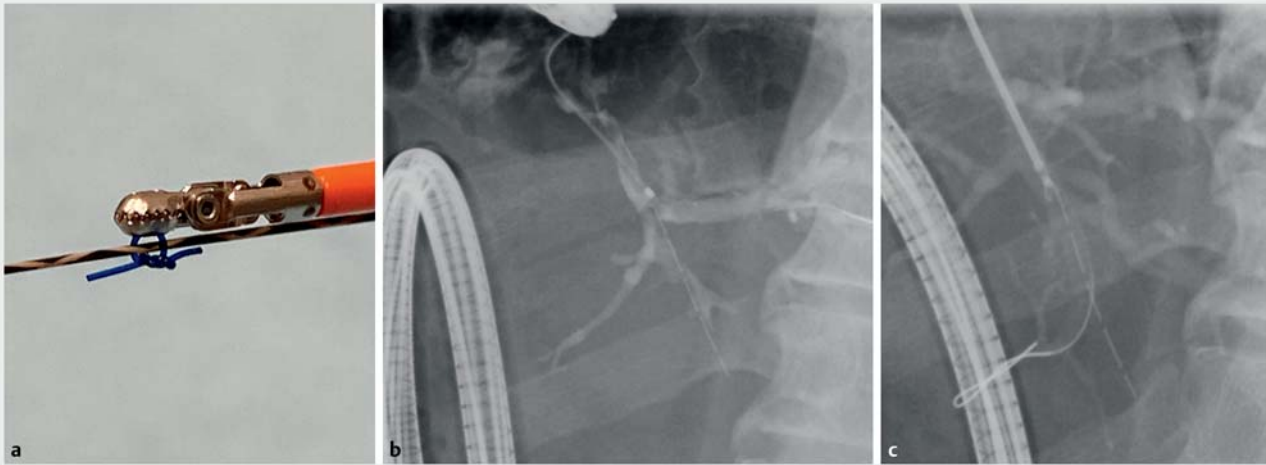
Endoscopy_UCTN_Code_TTT_1AR_2AZ

Competing interests

Dr. Nakai declares research funding from Boston Scientific Japan, Century Medical, Fujifilm, Gadelius Medical, Hitachi Medical, Kaneka, and Medico's Hirata. This work was not supported by any of those companies. The other authors declare no conflicts of interest related to this article.






▶ **Fig. 1** Computed tomography delineating a migrated stent in B3 (arrows) of a patient with a history of Roux-en-Y reconstruction. The patient underwent extended right hepatectomy with hepaticojejunostomy for intraductal papillary neoplasm of the bile duct. Proximal migration of a stent for the hepaticojejunostomy anastomosis site caused cholangitis, and a plastic stent was placed across the anastomosis site in a previous hospital.



► **Fig. 2** The “zipline” technique utilized to remove a migrated stent in B3. **a** Biopsy forceps with a looped nylon thread passed through the holes of one cup, which allows the forceps to be advanced over a guidewire. **b** Double-balloon enteroscopy-assisted cholangiogram delineating a migrated stent in B3. **c** The stent grasped via the zipline technique. We successfully passed the threaded forceps into B3. We readily grasped and removed the migrated stent.

The authors

Tsuyoshi Hamada¹  Hirofumi Kogure¹ 
 Ryunosuke Hakuta^{1,2}, Yousuke Nakai^{1,2} 
 Kazuhiko Koike¹

- 1 Department of Gastroenterology, Graduate School of Medicine, The University of Tokyo, Tokyo, Japan
- 2 Department of Endoscopy and Endoscopic Surgery, The University of Tokyo Hospital, Tokyo, Japan

Corresponding author

Yousuke Nakai, MD

Department of Endoscopy and Endoscopic Surgery, The University of Tokyo Hospital, 7-3-1 Hongo, Bunkyo City, Tokyo 113-8655, Japan
 Fax: +81-3-5800-9801
 ynakai-tky@umin.ac.jp

References

- [1] Sato T, Kogure H, Nakai Y et al. A prospective study of fully covered metal stents for different types of refractory benign biliary strictures. *Endoscopy* 2020; 52: 368–376
- [2] Anvari S, Lee Y, Patro N et al. Double-balloon enteroscopy for diagnostic and therapeutic ERCP in patients with surgically altered gastrointestinal anatomy: a systematic review and meta-analysis. *Surg Endosc* 2021; 35: 18–36
- [3] Yamada A, Kogure H, Nakai Y et al. Performance of a new short-type double-balloon endoscope with advanced force transmission and adaptive bending for pancreaticobiliary intervention in patients with surgically altered anatomy: a propensity-matched analysis. *Dig Endosc* 2019; 31: 86–93
- [4] Hamada T, Takahara N, Nakai Y et al. The “zipline” technique for endoscopic transpapillary biliary biopsy. *Endoscopy* 2020; 52: 236–237
- [5] Ogura T, Okuda A, Nishioka N et al. Transluminal antegrade biopsy using a novel forceps biopsy device for hepaticojejunostomy stricture. *Endoscopy* 2020. doi:10.1055/a-1260-2982 Online ahead of print

Bibliography

Endoscopy 2022; 54: E353–E354
DOI 10.1055/a-1530-4969
ISSN 0013-726X
published online 19.7.2021
 © 2021. Thieme. All rights reserved.
 Georg Thieme Verlag KG, Rüdigerstraße 14,
 70469 Stuttgart, Germany

ENDOSCOPY E-VIDEOS
<https://eref.thieme.de/e-videos>



Endoscopy E-Videos is an open access online section, reporting on interesting cases and new techniques in gastroenterological endoscopy. All papers include a high quality video and all contributions are freely accessible online. Processing charges apply (currently EUR 375), discounts and waivers acc. to HINARI are available.

This section has its own submission website at
<https://mc.manuscriptcentral.com/e-videos>