

## A rare complication of endoscopic ligation (“loop-and-let-go”) for management of a giant colonic lipoma

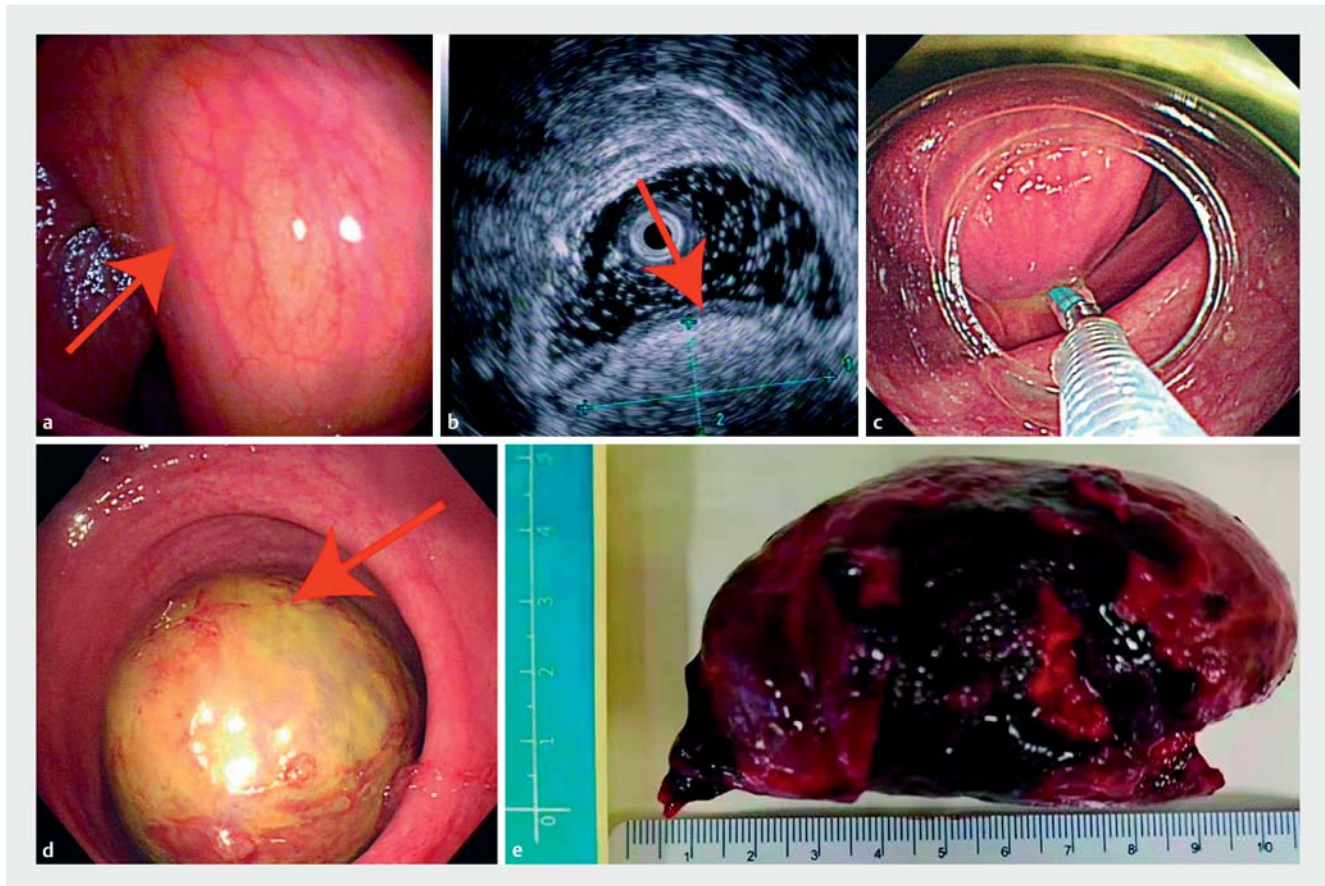
A 65-year-old man presented with a 6-month history of intermittent lower gastrointestinal bleeding and lower abdominal pain. Colonoscopy revealed a soft, yellowish submucosal tumor measuring around 10 cm with a short, wide pedicle in the transverse colon (► **Fig. 1 a**). Endoscopic ultrasonography showed a hyperechoic lesion originating from the submucosal layer (► **Fig. 1 b**). As the endoscopic signs were compatible with a colonic lipoma, we performed endoscopic ligation (“loop-and-let-go”) to treat the giant lipoma (► **Fig. 1 c**). The symptoms of bleeding and abdominal pain were relieved. Unfortunately, on the 15th day after the procedure the patient

suffered from severe lower abdominal pain and vomiting. Emergency colonoscopy showed that the shedding tumor was contributing to rectal occlusion (► **Fig. 1 d**), and it was removed from the rectum using oval forceps (► **Fig. 1 e**; ► **Video 1**).

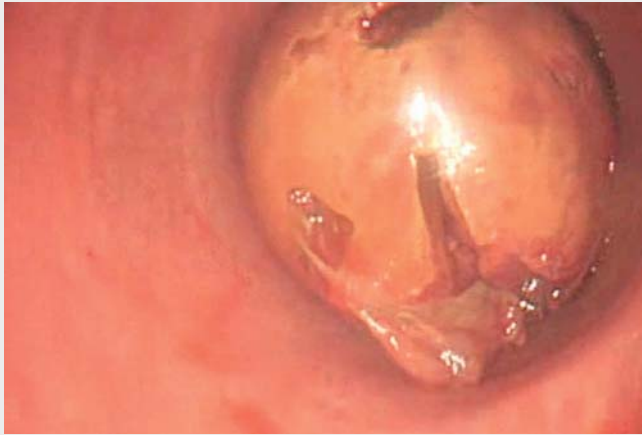Colonic lipomas are uncommon benign gastrointestinal subepithelial tumors, with a reported prevalence of 0.3% [1]. Most colonic lipomas are usually asymptomatic and detected incidentally during colonoscopy. When colonic lipomas become larger or symptomatic, they should be removed [2]. A prospective study demonstrated that the “loop-and-let-go” technique is feasible and safe for re-

moval of giant colonic lipomas (ranging in size from 2 cm to 6 cm) because it avoids electrocautery and eliminates the risk of bleeding and perforation [3]. However, in the present case this technique was performed to remove a colonic lipoma as large as 10 cm, and in this patient the shedding tumor contributed to rectal occlusion. We offer this reminder of this possible complication of rectal occlusion when the “loop-and-let-go” technique is employed to remove a giant colonic lipoma.

Endoscopy\_UCTN\_Code\_CPL\_1AJ\_2AH



► **Fig. 1** **a** A soft, yellowish giant submucosal tumor in the transverse colon; **b** a hyperechoic lesion originating from the submucosal layer; **c** endoscopic ligation (“loop-and-let-go”) to treat the giant lipoma; **d** the shedding tumor obstructing the rectum; **e** the shed tumor.



**Video 1** Removing the shedding tumor from the rectum using oval forceps.

## Funding

Technical Research and Development Project of Shenzhen  
No. JCYC20170307100911479  
Technical Research and Development Project of Shenzhen  
No. JCYJ20150403101028164  
Technical Research and Development Project of Shenzhen  
No. JCYJ20190807145617113  
Three Engineering Training Funds in Shenzhen  
No. SYLY201718  
Three Engineering Training Funds in Shenzhen  
No. SYJY201714  
Three Engineering Training Funds in Shenzhen  
No. SYLY201801  
Natural Science Foundation of Guangdong Province  
<http://dx.doi.org/10.13039/501100003453>  
2018A0303100024  
National Natural Science Foundation of China  
<http://dx.doi.org/10.13039/501100001809>  
No. 81800489

## Competing interests

The authors declare that they have no conflict of interest.

## The authors

**De-feng Li<sup>\*</sup>, Chao Zheng<sup>\*</sup>, Su-zhu Zhu, Li-juan Ye, Ben-hua Wu, Jun Yao<sup>✉</sup>, Li-sheng Wang**  
Department of Gastroenterology, Shenzhen People's Hospital, Guangdong, P. R. China

## Corresponding author

**Jun Yao, MD**  
No. 1017, Dongmen North Road, Luohu District, Shenzhen, Guangdong 518020, P. R. China  
[yj\\_1108@126.com](mailto:yj_1108@126.com)

## References

- [1] Mantzoros I, Raptis D, Pramateftakis MG et al. Colonic lipomas: our experience in diagnosis and treatment. *Tech Coloproctol* 2011; 15: S71–S73
- [2] Nallamothe G, Adler DG. Large colonic lipomas. *Gastroenterol Hepatol* 2011; 7: 490–492
- [3] Ivekovic H, Rustemovic N, Brkic T et al. Endoscopic ligation (“loop-and-let-go”) is effective treatment for large colonic lipomas: a prospective validation study. *BMC Gastroenterol* 2014; 14: 122–126

## Bibliography

*Endoscopy* 2022; 54: E340–E341  
**DOI** 10.1055/a-1540-6031  
**ISSN** 0013-726X  
**published online** 19.7.2021  
© 2021. Thieme. All rights reserved.  
Georg Thieme Verlag KG, Rüdigerstraße 14, 70469 Stuttgart, Germany

## ENDOSCOPY E-VIDEOS

<https://eref.thieme.de/e-videos>



*Endoscopy E-Videos* is an open access online section, reporting on interesting cases and new techniques in gastroenterological endoscopy. All papers include a high quality video and all contributions are freely accessible online. Processing charges apply (currently EUR 375), discounts and waivers acc. to HINARI are available.

This section has its own submission website at <https://mc.manuscriptcentral.com/e-videos>

\* These authors contributed equally to this work.