

Embolization of Hemorrhoidal Arteries: A Novel Endovascular Therapy Option for the Treatment of Hemorrhoidal Disease

Hämorrhoidenembolisation: Eine neue minimalinvasive endovaskuläre Therapieoption bei Hämorrhoidalleiden

Authors

Ludger Feyen¹ , Patrick Freyhardt^{2, 1}, Peter Schott¹, Christoph Wullstein³, Alexandra Dimitriou-Zarra³, Marcus Katoh¹

Affiliations

- 1 Department of Diagnostic and Interventional Radiology, HELIOS Klinikum Krefeld, Germany
- 2 School of Medicine, University Witten-Herdecke Faculty of Health, Witten, Germany
- 3 Department of General, Abdominal and Minimally Invasive Surgery, HELIOS Klinikum Krefeld, Germany

Key words

hemorrhoids, embolization, rectal artery

received 05.01.2021

accepted 12.09.2021

published online 18.11.2021

Bibliography

Fortschr Röntgenstr 2022; 194: 266–271

DOI 10.1055/a-1662-5487

ISSN 1438-9029

© 2021. Thieme. All rights reserved.

Georg Thieme Verlag KG, Rüdigerstraße 14, 70469 Stuttgart, Germany

Correspondence

Dr. Ludger Feyen

Institut für Diagnostische und Interventionelle Radiologie, HELIOS Klinikum Krefeld, Lutherplatz 40, 47805 Krefeld, Germany

Tel.: +49/21 51/32 25 61

ludger.feyen@helios-kliniken.de

ABSTRACT

Background Hemorrhoids are a widespread disease. Treatment options range from dietary measures to open surgery. A novel treatment approach is the embolization of the hemorrhoidal arteries.

Method A review was performed based on a selective literature search in PubMed representing the current state of research. The keywords “hemorrhoid” and “embolization” and “emborrhoid” were used. In addition, technical details of the hemorrhoidal embolization procedure are explained.

Results and Conclusion Embolization of hemorrhoidal arteries is a safe treatment, which allows efficient symptom control even in patients with contraindications for open surgery.

Key Points:

- Embolization of hemorrhoidal arteries is a new approach to the treatment of hemorrhoids.
- Embolization of hemorrhoidal arteries is feasible in patients with contraindications for open surgery such as hypercoagulable states and contraindications for general anesthesia.
- The endovascular approach causes no rectal and anal trauma and associated complications can be avoided.
- The treatment of bleeding hemorrhoids seems to be particularly effective.
- No ischemic complications have been reported so far when coils as well as particles were used.

Citation Format

- Feyen L, Freyhardt P, Schott P et al. Hämorrhoidenembolisation: Eine neue minimalinvasive endovaskuläre Therapieoption bei Hämorrhoidalleiden. Fortschr Röntgenstr 2022; 194: 266–271

ZUSAMMENFASSUNG

Hintergrund Das Hämorrhoidalleiden ist eine weit verbreitete Erkrankung. Die Behandlung erfolgt stadienabhängig und reicht von diätetischen Maßnahmen bis zur offenen Operation. Ein neues Behandlungskonzept stellt die Hämorrhoidalarterienembolisation dar.

Methode Es erfolgte eine selektive Literaturrecherche in PubMed, die den aktuellen Forschungsstand repräsentiert. Es wurden die Schlagwörter „hemorrhoid“ und „embolization“ sowie „emborrhoid“ verwendet. Ferner wird an einem Fallbeispiel das technische Vorgehen detailliert beschrieben.

Ergebnisse und Schlussfolgerungen Die Hämorrhoidalarterienembolisation ist ein nebenwirkungsarmes Verfahren, welches eine effektive Symptomkontrolle erlaubt und insbesondere bei Patienten mit Kontraindikationen für eine Operation angewendet werden könnte.

Pathophysiology of hemorrhoids

The hemorrhoidal plexus is a spongy vascular cushion at the ano-rectal junction above the dentate line. The plexus is comprised of an arteriovenous conglomerate of vessels, the smooth musculus canalis ani, and elastic connective tissue fibers. The physiological vascular cushion helps to seal the anus and primarily contains terminal branches of the superior rectal artery. Additional feeder vessels come from the internal iliac artery via the middle rectal artery and from the internal pudendal artery via the inferior rectal artery [1]. The vascular cushion receives nutrients from the vessels branching into the intermediate spaces [2].

The terms hemorrhoidal disease or symptomatic hemorrhoids are used to describe symptoms caused by enlarged hemorrhoids [3]. Hemorrhoidal disease is one of the most common diseases in industrialized countries with an incidence of approximately 4% of the total population [4]. Transanal bleeding, stool leakage, itching, and burning are typical symptoms of hemorrhoidal disease [3].

The integrity of the hemorrhoidal plexus is compromised in hemorrhoidal disease. In addition to vascular changes, there are inflammatory changes and degenerative processes involving the elastic tissue and the muscle fibers that hold the hemorrhoidal cushions in place [5]. The degeneration of supportive tissue results in enlargement and downward displacement of the corpus cavernosum recti [6].

On the vascular level, a significantly greater diameter and a greater and faster blood flow in the branches of the superior rectal artery were seen compared to healthy subjects [7]. In this study, the vascular caliber also correlated with the severity of the disease.

With respect to molecular pathology, there are indications of increased angiogenesis in hemorrhoid tissue with pathological changes. In addition to an increase in the number of blood vessels, increased expression of the vascular endothelial growth factor was found in tissue samples [8]. In addition, an overexpression of zinc-dependent matrix metalloproteinase 9 was detected in hemorrhoid tissue [9]. In addition to the destruction of elastic fibers, the activated proteinase results in increased activity of angioproliferative transforming growth factor- β [10].

Diagnosis and therapy

Hemorrhoidal disease is divided into four grades according to Goligher [11]. In grade one, proctoscopy shows slight bulging of the hemorrhoids. In grade two, the hemorrhoids prolapse into the anal canal on defecation with spontaneous reduction. In the case of grade three hemorrhoids, the prolapsed hemorrhoids protrude outside the anal canal and do not spontaneously reduce but can be manually repositioned. Grade four hemorrhoids are irreducible and constantly prolapsed.

The spectrum of treatment options ranges based on grade from basic treatment consisting of a high-fiber diet, exercise, and fluids to sclerotherapy, rubber band ligation, and surgical interventions.

According to the current S3 guidelines, sclerotherapy can be performed in the case of grade one and grade two hemorrhoids [12]. A sclerosing agent is injected in the region of the feeding arteries or into the hemorrhoids during proctoscopy. The most common complications include urological side effects like prostatitis, urinary retention, and hematuria in up to 31% of cases [13]. There is a high recurrence rate of up to 81% after 4 years [14].

In grade two hemorrhoids, rubber band ligation is recommended [12]. The hemorrhoid tissue is tied off at the base with a rubber band. The tissue dies and falls off. The resulting scarring results in repair of the remaining hemorrhoid tissue. Pain and bleeding are the most common complications. In newer studies, rebleeding was seen in up to 13% of cases and local pain in up to 45% [15, 16]. According to the current S3 guidelines, contraindications are coagulations disorders and the intake of potent anti-coagulation medications [12]. Surgical treatment is indicated in the case of grade three or four hemorrhoids. Resection procedures are divided into segmental resection and circular resection procedures. One of the segmental resection procedures presumably used most frequently in Germany is the Milligan-Morgan hemorrhoidectomy procedure [12, 17]. The hemorrhoidal cushions are removed and the proximal arterial blood supply is stopped. Newer methods include stapled hemorrhoidopexy and Doppler-guided ligature. In the case of stapled hemorrhoidopexy, a circular stapling device is used to remove a ring of rectal mucosa [18]. This results in lifting of the hemorrhoids in the cranial direction and ligation of the terminal branches of the superior rectal artery. In the case of Doppler-guided ligature of hemorrhoidal arteries, the arteries are identified and ligated using a special proctoscope under Doppler ultrasound guidance [19]. These surgical treatments are performed under general anesthesia. Depending on the method, anal and rectal trauma can occur.

Hemorrhoid embolization

Endovascular hemorrhoid embolization is a new treatment for hemorrhoidal disease. Due to the newness of the method, it has not yet been included in the guidelines. However, according to current data, hemorrhoid embolization seems to be particularly suitable for patients with problematic bleeding in grade two or three hemorrhoidal disease and for patients with contraindications for surgery. The latter group includes, for example, patients taking potent anticoagulation medications and patients who cannot undergo sedation [20]. The procedure can be performed in addition to prior hemorrhoid operations. If hemorrhoid embolization does not achieve the desired effect, surgical treatment can be performed. The technique is described in detail based on the example of a case treated at the authors' hospital.

A 56-year-old man presented with recurrent at times massive perianal bleeding and chronic itching. Prior treatment with rubber band ligation did not provide lasting success. A previously performed colonoscopy to rule out other differential diagnoses, e.g. tumors, which can cause recurrent bleeding, was unremarkable. Proctoscopy showed two grade two and one grade three hemorrhoids.

After the administration of local anesthesia, the common femoral artery was punctured using the Seldinger technique and a 4F sheath was inserted. A 4F diagnostic catheter in SHK 1 configuration (Cordis Corporation, Miami Lakes USA) was inserted into the inferior mesenteric artery and nonselective angiography with manual contrast injection was performed (see ► Fig. 1). Superselective probing of the superior rectal artery with a 2.4F microcatheter (Direxion, Boston Scientific Corporation, USA) and 0.016" microwire (Fathom, Boston Scientific Corporation, USA) using the coaxial technique was then performed. For exact evaluation of the blood supply to the hemorrhoidal plexus and the position of the terminal branches, cone beam CT with manual contrast injection was performed with the catheter positioned above the branching into the terminal branches (see ► Fig. 2). In total there were four terminal branches with a typical horizontal course in anteroposterior projection at the level of the cranial symphysis. The terminal branches were probed individually with a microwire and microcatheter using the roadmap technique and were first embolized with 250- μ m hydrogel particles (Embozene, Boston Scientific, USA) and then embolized with 0.018" microcoils. In the case of forced contrast injection into the right anterior terminal branch, anastomosis to the medial rectal artery (► Fig. 3), which was also occluded with a microcoil, was seen. In total, 13 figure-eight 2 \times 5 mm coils, 14 straight 5 mm coils, and 1 VortX 3 \times 2.5 mm coils (Boston Scientific, USA) were used. The goal was to achieve complete stasis in the vessels and absence of contrast enhancement of the hemorrhoidal plexus (► Fig. 4). The foreign material was removed and a compression bandage was applied.

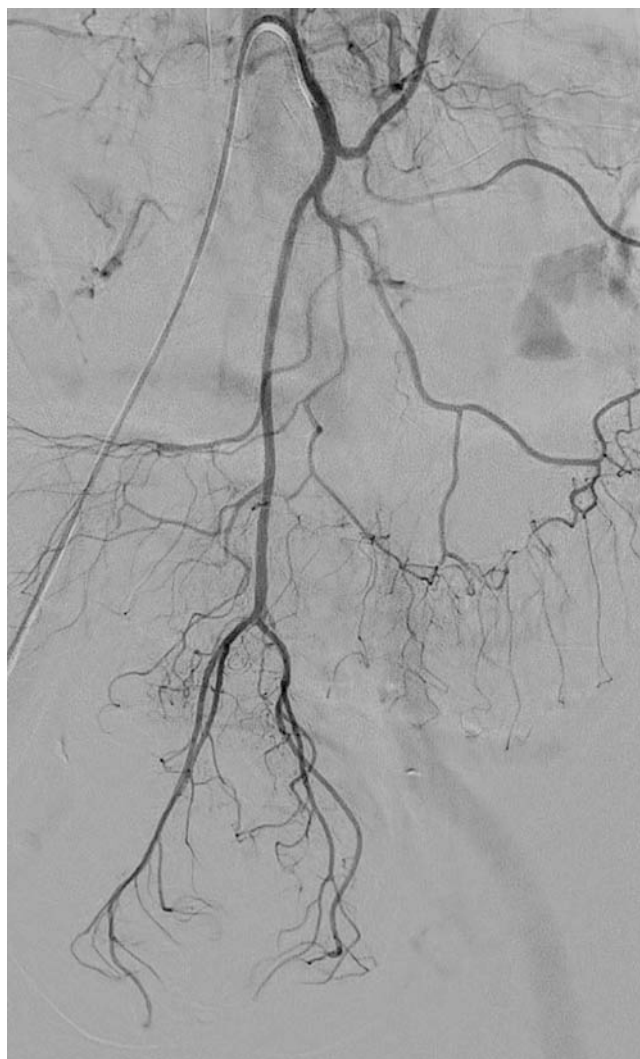After a complication-free course, the patient was discharged the next day.

The six-week proctoscopic follow-up examination showed minimal reduction of the hemorrhoids. However, over the next six months, the patient was completely symptom-free and without further bleeding.

Results

The endovascular hemorrhoid embolization technique was first described in the Russian literature [21]. In 2014 in a small case series including three patients, some of whom had previously undergone surgery, Vidal reported a significant reduction in disabling bleeding [22].

Fourteen patients with grade two to four hemorrhoids, with half of the patients having previously undergone surgery and ten having been treated with anticoagulants or having hypocoagulation due to liver cirrhosis, were treated in a further study by Vidal et al. [23]. A temporary, painful perianal reaction occurred in one case. In this first study, incomplete embolization was initially performed. To avoid ischemic complications, only two of the four terminal branches of the superior rectal artery were occluded in the first six patients. Due to rebleeding, complete embolization was performed in further sessions in four patients. In total, clinical improvement was seen after one month in 72% of patients. Patients with contraindications for surgical treatment and patients with persistent symptoms in spite of prior surgery were treated in another study by Vidal's working group. Primarily grade

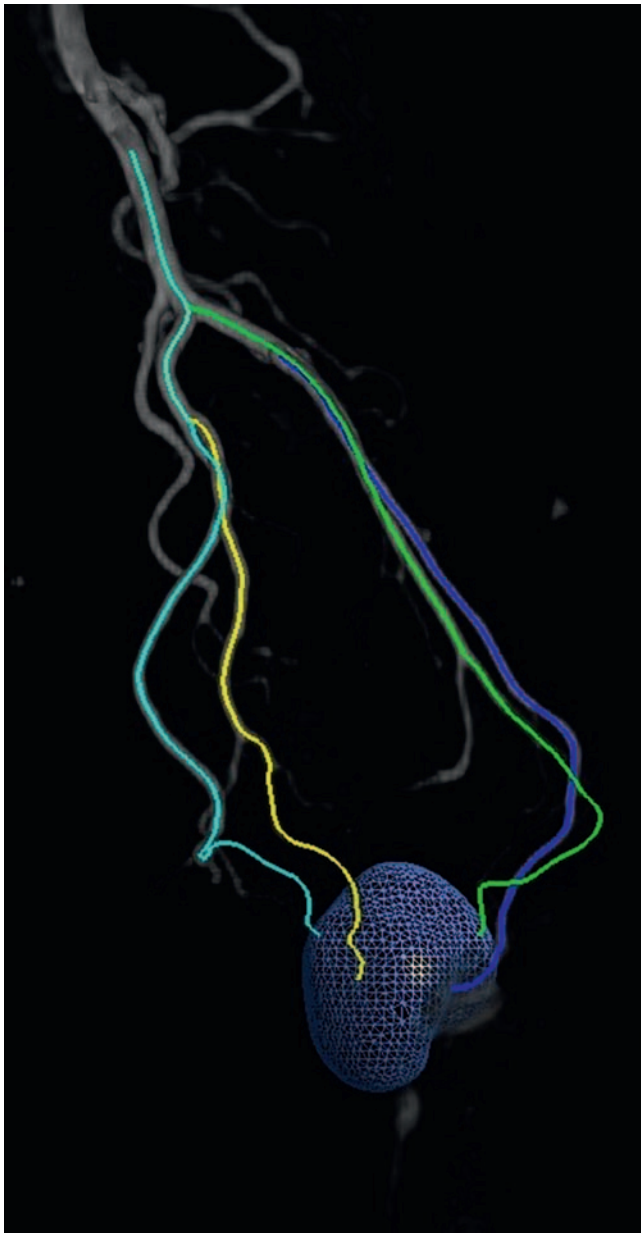


► Fig. 1 Digital subtraction angiography of the inferior mesenteric artery. The terminal branches of the superior rectal artery are visualized at the bottom of the image. Due to the large size of the depicted inferior mesenteric artery, deep intubation with a 4F catheter is possible without risk.

two hemorrhoids were treated and an improvement of symptoms was seen in 72% of patients [24]. In the study by Tradi et al., grade two and three hemorrhoids were treated [25]. An improvement of symptoms was seen in approximately two-thirds of patients. In particular, decreased bleeding rates, improved quality of life, and reduction of hemorrhoids were observed. Coils were exclusively used to embolize the distal terminal branches of the rectal artery in the studies mentioned above.

However, relevant anastomosis of the medial rectal artery or a co-dominant supply of the hemorrhoidal plexus via branches of the medial rectal artery was observed in up to one fourth of patients in the case of forced contrast injection. These patients benefited less frequently from hemorrhoid embolization [25].

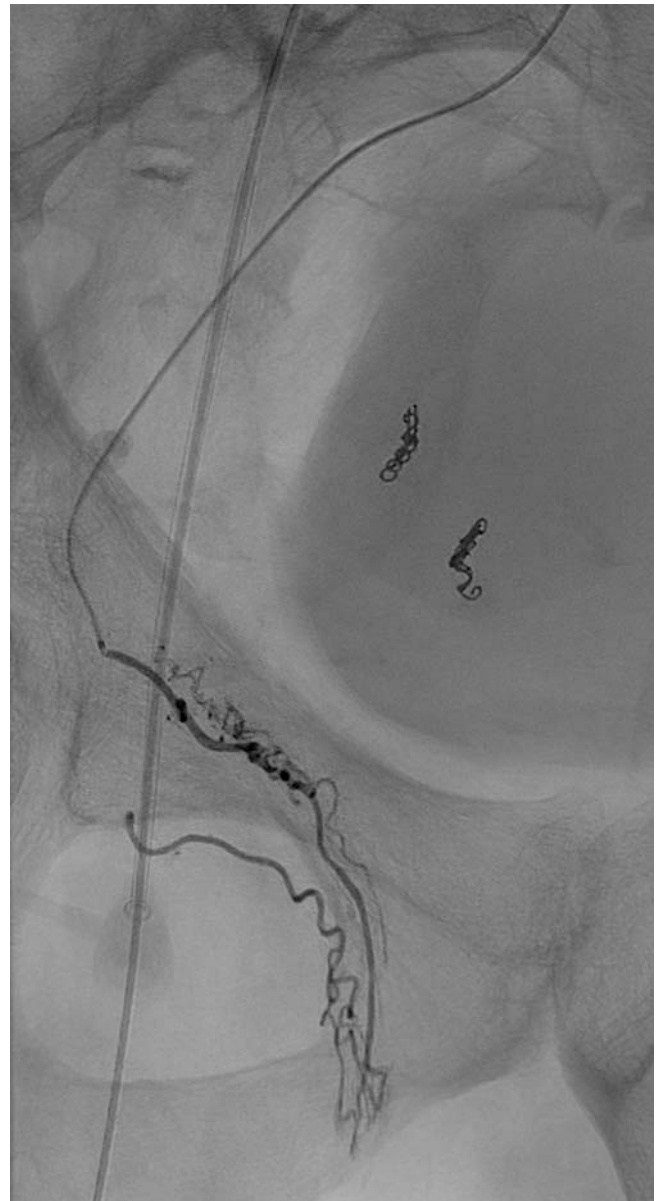The lack of occlusion of additional dominant arteries of the hemorrhoidal plexus apparently results in incomplete embolization and consequently in a worse outcome.



► **Fig. 2** Cone-beam CT of the superior rectal artery. The vessel branches that feed the hemorrhoidal plexus are pictured. The blue region of interest incorporates the hemorrhoid plexus. The area was segmented to automatically detect the depicted vessel feeders with the EmboGuide system (EmboGuide, Philips healthcare, Eindhoven, The Netherlands). The utilization of the EmboGuide system in this context currently constitutes an off-label use.

Therefore, in the case we described, superselective particle embolization was performed before coil embolization to also treat branches of the medial rectal artery. Inadvertent embolization in other regions/organs due to flow direction is not to be expected. Therefore, such collaterals are not a contraindication but rather an indication for additional particle embolization in order to achieve an embolization result that is as complete as possible.

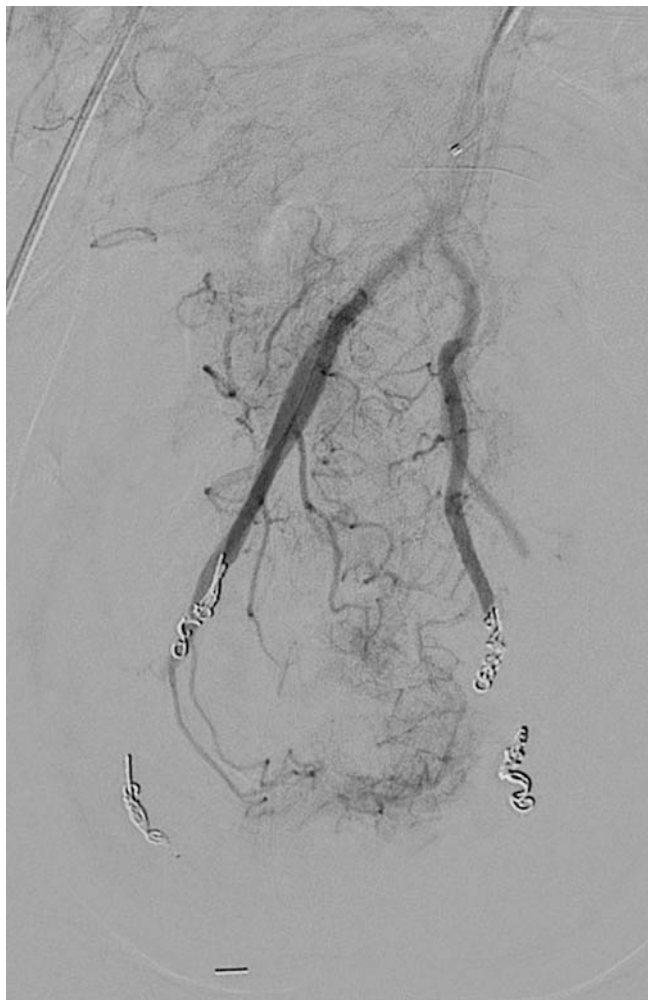Zakarchenko treated 40 patients with grade one to three hemorrhoids [26]. Additional particles were also used for emboli-



► **Fig. 3** Forced contrast injection into the right anterior terminal branch of the superior rectal artery. Retrograde display of a feeder vessel from the medial rectal artery to the hemorrhoidal plexus.

zation in this study. For this purpose a 5F catheter was advanced to the point of branching and into the terminal branches of the superior rectal artery. From this position, less selective embolization with polyvinyl alcohol particles with a size of 300 μm was performed in addition to the application of metal coils [26]. No complications were observed in this study. A reduction in hemorrhoid size and symptom improvement were seen in 83 % of patients with grade three hemorrhoids and in 94 % of patients with grade one or two hemorrhoids. Moreover, the contractility of the anal sphincter remained unchanged one month after treatment. The average decrease in blood flow to the hemorrhoids measured on Doppler ultrasound was 50 %.

In the study by Moggia, the procedure was used in patients with bleeding hemorrhoids and resulted in symptom improve-



► **Fig. 4** Final angiogram. Complete stasis in the distal terminal branches of the superior rectal artery that feed the hemorrhoidal plexus.

ment and improved quality of life in 87.5% of patients. Complications were not observed within the follow-up period of 12 months [27].

Conclusion

Hemorrhoidal disease is one of the most common diseases in industrialized countries. Treatments range from basic dietary measures to open surgery. Some promising studies on hemorrhoid embolization have recently been published. A significant and lasting decrease in symptoms without relevant side effects was able to be shown. This minimally invasive endovascular procedure could be a useful addition to established treatments for patients at high risk for surgical procedures.

Conflict of Interest

The authors declare that they have no conflict of interest.

References

- [1] Aigner F, Bodner G, Conrad F et al. The superior rectal artery and its branching pattern with regard to its clinical influence on ligation techniques for internal hemorrhoids. *Am J Surg* 2004; 187: 102–108. doi:10.1016/j.amjsurg.2002.11.003
- [2] Lierse W. [Anatomy and pathophysiology of hemorrhoids]. *Langenbecks Arch Chir Suppl II Verh Dtsch Ges Chir* 1989; 769–772
- [3] Aigner F, Conrad F, Haunold I et al. [Consensus statement haemorrhoidal disease]. *Wien Klin Wochenschr* 2012; 124: 207–219. doi:10.1007/s00508-011-0107-8
- [4] Cataldo P, Ellis CN, Gregorcyk S et al. Practice parameters for the management of hemorrhoids (revised). *Dis Colon Rectum* 2005; 48: 189–194. doi:10.1007/s10350-004-0921-4
- [5] Morgado PJ, Suarez JA, Gomez LG et al. Histoclinical basis for a new classification of hemorrhoidal disease. *Dis Colon Rectum* 1988; 31: 474–480. doi:10.1007/BF02552621
- [6] Thomson WH. The nature of haemorrhoids. *Br J Surg* 1975; 62: 542–552. doi:10.1002/bjs.1800620710
- [7] Aigner F, Bodner G, Gruber H et al. The vascular nature of hemorrhoids. *J Gastrointest Surg* 2006; 10: 1044–1050. doi:10.1016/j.gassur.2005.12.004
- [8] Han W, Wang ZJ, Zhao B et al. [Pathologic change of elastic fibers with difference of microvessel density and expression of angiogenesis-related proteins in internal hemorrhoid tissues]. *Zhonghua Wei Chang Wai Ke Za Zhi* 2005; 8: 56–59
- [9] Kronberger IE. Pathogenese des Hämorrhoidalleidens. *coloproctology* 2018; 40: 247–250. doi:10.1007/s00053-018-0265-5
- [10] Yoon SO, Park SJ, Yun CH et al. Roles of matrix metalloproteinases in tumor metastasis and angiogenesis. *J Biochem Mol Biol* 2003; 36: 128–137. doi:10.5483/bmbrep.2003.36.1.128
- [11] Goligher JC, Duthie HL, Nixon HH. *Surgery of the anus, rectum, and colon*. 3rd ed. London: Baillière Tindall; 1975
- [12] Joos AAR, Borschitz T, Brand J et al. S3-Leitlinie-Hämorrhoidalleiden. *AWMF Online* 2019. p. www.awmf.org
- [13] Al-Ghnam R, Leather AJ, Rennie JA. Survey of methods of treatment of haemorrhoids and complications of injection sclerotherapy. *Ann R Coll Surg Engl* 2001; 83: 325–328
- [14] Kanellos I, Goulimaris I, Christoforidis E et al. A comparison of the simultaneous application of sclerotherapy and rubber band ligation, with sclerotherapy and rubber band ligation applied separately, for the treatment of haemorrhoids: a prospective randomized trial. *Colorectal disease: the official journal of the Association of Coloproctology of Great Britain and Ireland* 2003; 5: 133–138. doi:10.1046/j.1463-1318.2003.00395.x
- [15] Lu LY, Zhu Y, Sun Q. A retrospective analysis of short and long term efficacy of RBL for hemorrhoids. *Eur Rev Med Pharmacol Sci* 2013; 17: 2827–2830
- [16] Su MY, Chiu CT, Lin WP et al. Long-term outcome and efficacy of endoscopic hemorrhoid ligation for symptomatic internal hemorrhoids. *World J Gastroenterol* 2011; 17: 2431–2436. doi:10.3748/wjg.v17.i19.2431
- [17] Kraemer M, Bussen D, Leppert R et al. [Country-wide survey of therapeutic procedures in hemorrhoids and anal fissure]. *Chirurg* 1998; 69: 215–218. doi:10.1007/s001040050401
- [18] Beattie. Lam. Loudon. A prospective evaluation of the introduction of circumferential stapled anoplasty in the management of haemorrhoids and mucosal prolapse. *Colorectal disease: the official journal of the Association of Coloproctology of Great Britain and Ireland* 2000; 2: 137–142. doi:10.1046/j.1463-1318.2000.00125.x

- [19] Morinaga K, Hasuda K, Ikeda T. A novel therapy for internal hemorrhoids: ligation of the hemorrhoidal artery with a newly devised instrument (Moricorn) in conjunction with a Doppler flowmeter. *Am J Gastroenterol* 1995; 90: 610–613
- [20] Laubert T, Kahlke V. Hämorrhoidenoperation. *coloproctology* 2020; 42: 30–36. doi:10.1007/s00053-019-00415-x
- [21] Galkin EV. [Interventional radiology of chronic hemorrhoids]. *Vestnik rentgenologii i radiologii* 1994; 4: 52–56
- [22] Vidal V, Louis G, Bartoli JM et al. Embolization of the hemorrhoidal arteries (the emborrhoid technique): a new concept and challenge for interventional radiology. *Diagn Interv Imaging* 2014; 95: 307–315. doi:10.1016/j.diii.2014.01.016
- [23] Vidal V, Sapoval M, Sielezneff Y et al. Emborrhoid: a new concept for the treatment of hemorrhoids with arterial embolization: the first 14 cases. *Cardiovasc Intervent Radiol* 2015; 38: 72–78. doi:10.1007/s00270-014-1017-8
- [24] Moussa N, Sielezneff I, Sapoval M et al. Embolization of the superior rectal arteries for chronic bleeding due to haemorrhoidal disease. *Colorectal disease: the official journal of the Association of Coloproctology of Great Britain and Ireland* 2017; 19: 194–199. doi:10.1111/codi.13430
- [25] Tradi F, Louis G, Giorgi R et al. Embolization of the Superior Rectal Arteries for Hemorrhoidal Disease: Prospective Results in 25 Patients. *Journal of Vascular and Interventional Radiology* 2018; 29: 884–892.e1. doi:10.1016/j.jvir.2018.01.778
- [26] Zakharchenko A, Kaitoukov Y, Vinnik Y et al. Safety and efficacy of superior rectal artery embolization with particles and metallic coils for the treatment of hemorrhoids (Emborrhoid technique). *Diagn Interv Imaging* 2016; 97: 1079–1084. doi:10.1016/j.diii.2016.08.002
- [27] Moggia E, Talamo G, Gallo G et al. Do We Have Another Option to Treat Bleeding Hemorrhoids? The Emborrhoid Technique: Experience in 16 Patients. *Reviews on recent clinical trials* 2020. doi:10.2174/1574887115666200313102246