Artikel online veröffentlicht: 23.05.2022

Innovative Technologies for Optimized Artificial Vision

OPEN ACCESS

Author
Peter Walter[1, 2]

Affiliations
1 Klinik für Augenheilkunde
2 Uniklinik RWTH Aachen

Key words
Artificial Vision, Blindness, Retinal Implants, Cortical Implants, retinal dystrophy, macular degeneration

Bibliography
Laryngo-Rhino-Otol 2022; 101: S79–S89
DOI 10.1055/a-1671-1825
ISSN 0940-6689
© 2022. Thieme. All rights reserved.
This is an open access article published by Thieme under the terms of the Creative Commons Attribution-NonDerivative-NonCommercial-License, permitting copying and reproduction so long as the original work is given appropriate credit. Contents may not be used for commecial purposes, or adapted, remixed, transformed or built upon. (https://creativecommons.org/licenses/by-nc-nd/4.0/)
Georg Thieme Verlag KG, Rüdigerstraße 14, 70469 Stuttgart, Germany

Correspondence
Prof. Dr. Peter Walter
Department of Ophthalmology
University Hospital RWTH Aachen
Pauwelsstr. 30
D-52074 Aachen
Tel.: +49/241/8088191; Fax: +49/241/8082408
pwalter@ukaachen.de

ABSTRACT

Despite significant advances in the treatment of severe eye diseases, certain forms of blindness cannot be cured or improved to this day. These include, for example, retinitis pigmentosa, a hereditary degeneration of photoreceptors. Technology approaches with implantable visual prostheses based on electrical stimulation of remaining neurons in the retina or cortex, have already been tested in a number of patients with limited results. New findings in the biology of these diseases as well as new technological developments give hope for better results in the future.

Contents

1. Definition of “artificial vision” 2
1.1 Visual aids without direct coupling to the nervous system 2
1.2 Visual aids with indirect coupling to the nervous system 2
1.3 Visual aids with direct coupling to the nervous system 2
2. Range of indication for artificial vision 3
3. Outcomes of former approaches 4
4. Reasons for the limited effect 5
4.1 Number, size, and density of electrodes 5
4.2 Size of the stimulator 6
4.3 Stimulation algorithm 6
4.4 Biological intrinsic activity 7
4.5 Training and rehabilitation 7
4.6 Surgical aspects 7
5. Innovative approaches 7
5.1 Reduction of the electrode size, increase of the electrode density 7
5.2 Increase of the stimulation surface 7
5.3 Charge-controlled stimulation vs. power/tension-controlled stimulation 8
5.4 Bidirectional approach with local analysis of the intrinsic activity 8
5.5 Power supply and packaging 8
6. Discussion 8
7. Conclusion and outlook 9
References 9

1 Definition of "artificial vision"

The term of "artificial vision" has two different aspects, a technical and a medical one. In the technical sense, it describes the vision for machines meaning the control of automats and technical devices that require three-dimensional representation of the space for their actions. A good example is autonomously driving vehicles that are equipped with numerous cameras and sensors allowing real-time depiction of the environment and thus the basis for driving decisions. Another example for their application is the control of robots of which the actuators interact with objects.

In the medical sense, however, artificial vision is the restoration of the visual ability in blind or severely impaired people. The technical restoration or improvement of the vision is only reasonable in cases of substantial impairment of the vision when all conventional approaches can only achieve restoration in a very limited way. The following definition for blindness applies in Germany: If the better eye achieves a visual acuity of or less than 1/50, a person is considered as blind. This means that the better eye of a person can identify an object from a distance of 1 m that a person with normal sight recognizes from a distance of 50 m. This is approximately the threshold that is taken into consideration for this kind of procedures. Different approaches may be applied.

1.1 Visual aids without direct coupling to the nervous system

Visual aids without direct coupling to the nervous system are camera systems that recognize objects in the environment and inform the user by means of language. These systems are able to read out texts, assign faces to persons and name them. They may also read certain code systems like barcodes and in this way they can for example identify products in the supermarket and inform about the prizes. A good example for this kind of visual aids is the ORCAM system. Experience shows that mostly young technophils like using these systems and benefit from them (Moisseiev & Mannis, 2016).

1.2 Visual aids with indirect coupling to the nervous system

Visual aids with indirect coupling to the nervous system are characterized by a physical contact between the system and the organism, which is the case for example with the Brain Port system. Hereby, the recognition of the environment takes place by means of a camera system. An encoder calculates weak pulses of electric current from the camera picture that are issued via an electrode matrix. This matrix is placed on the tongue and the user learns to perceive these pulses with the highly sensitive tongue surface and to associate them with an object (Lee et al., 2014).

1.3 Visual aids with direct coupling to the nervous system

Visual aids with direct coupling to the nervous system are the classic implants for artificial vision. They typically consist of a camera replacing the light-sensitive cells of the retina and a visual neuroprocessor that, based on the camera picture, calculates the pulse sequences required for stimulation. These data are sent mostly inductively together with an energy stream via a transmitter into the implanted stimulation system (▶ **Fig. 1**).

The artificial visual perception is performed by an electrical stimulation of neurons in the visual system; the stimulation electrodes may be implanted at different sites of the visual system (Ayton et al., 2020; P. Walter, 2016). Depending on the implantation site, different systems and approaches are available (see ▶ **Figs 2** and ▶ **3**).

1.3.0. In cases of **transchoroidal approach**, the stimulation electrodes are placed in the suprachoroidal space, i. e. between the sclera and the choroid. Some experiences with a series of test subjects are available. The major problem in this context is the low spatial resolution of the system because the stimulation electrodes are rather distant from the target structures, i. e. the retinal neurons (Ayton et al., 2014; Fujikado et al., 2016; Nishida et al., 2015; Shivdasani et al., 2014). ▶ **Fig. 1** describes schematically the stimulation electrodes "C" below the choroid on the optic coherence tomography scan (OCT) showing a section through the fovea of the healthy retina.

1.3.1. In the context of the **epiretinal approach**, electrodes are implanted on the retinal surface. ▶ **Fig. 2** shows the electrodes "A" on the retinal surface. Superficially, the layer of the retinal ganglion cells is found that from an information-technological point of view represents the outlet of the retina with its axons as optic nerve. The target of epiretinal stimulation is the retinal ganglion cell. The major challenge in this regard is the stable and atraumatic fixation of the electrode array on the retina. Regarding this approach, experiences with about 350 patients are available who have been implanted with such a system (da Cruz et al., 2016).

1.3.2. In cases of **subretinal retina implant** applied in blind patients, the electrode matrix "B" is inserted under the retina in the subretinal space. The subretinal space is defined as the space between the photoreceptor layer and the retinal pigment epithelium. In the OCT section of ▶ **Fig. 3**, two white lines characterize this area. There is the ellipsoid zone representing the transition between the external and internal segment of the photoreceptors and below, the retinal pigment epithelium is seen. This space is of embryonic origin, the connection between the external parts of the photoreceptors and the pigment epithelium cells are rather functional and mainly maintained by osmotic gradients and active transport. In advanced cases of retinal degeneration, however, the RPE may be firmly connected with atrophic photoreceptor residues. Even the RPE is often atrophic, the connection in these cases is often difficult to solve. The target of stimulation is the bipolar cell. The major challenge in this context is the energy supply of the system and the long-term stability of the complex structures (K. Stingl et al., 2017).

1.3.3. In the context of stimulation of the **optic nerve** by means of cuff electrodes or directly with fine, penetrating electrodes, the electrode matrix is placed directly around the optic nerve or pierced into the optic nerve. For this approach, only very few data with patients are available. Also with these stimulators, phosphenes could be triggered; however, systematic development on product level has not taken place. One of the major problems of this approach is the spatial resolution of responses because the target structures in the optic nerve are extremely dense (Duret et al., 2006; Veraart, Duret, Brelen, Delbeke, & ieee, 2004; Veraart, Duret, Brelen, Oozeer, & Delbeke, 2004).

1.3.4. The stimulation of the **lateral geniculate nuclei** has only been simulated up to now. Even if neurosurgeons confirm the feasi-

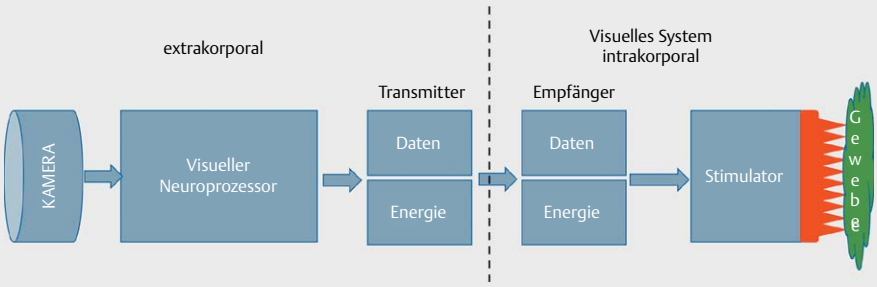

▶ **Fig. 1** Basic principle of telemetric visual prosthesis. A direct cable connection between body cavities or organs and the environment should possibly be avoided.

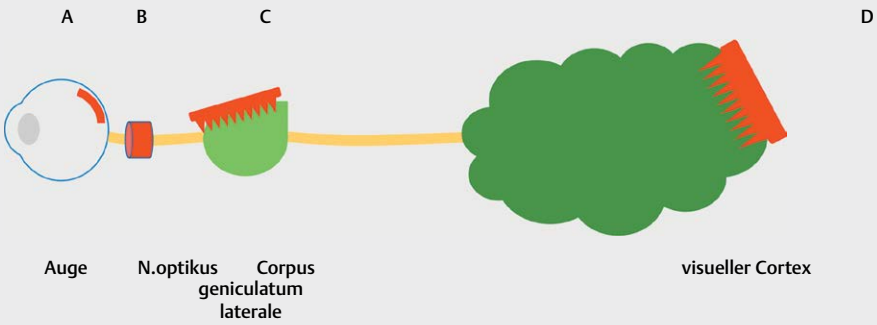

▶ **Fig. 2** Overview about possible implantation sites for visual prostheses that are being developed internationally in different projects. **a** Visual prostheses with direct or indirect contact to the retina: retinal implants. **b** Visual prostheses with stimulation electrode at the visual nerve. **c** Stimulation electrodes at the lateral geniculate nucleus. **d** Cortical prosthesis.

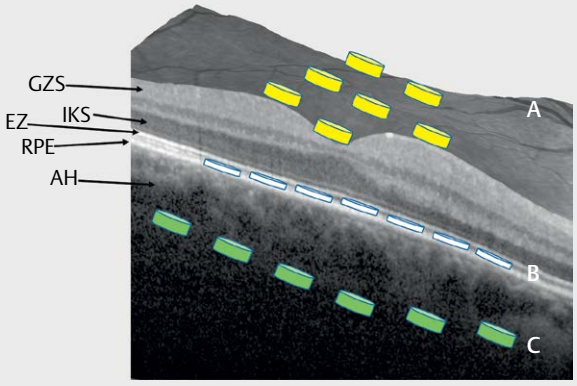

▶ **Fig. 3** Implantation of technical visual prostheses and their stimulation electrodes in different target regions of the retina. **a** epiretinal. **b** subretinal. **c** suprachoroidal. GZS: ganglion cell layer. IKS: inner nuclear layer. EZ: ellipsoid zone. PRE: retinal pigment epithelium. AH: choroid.

bility of the approach to this structure, a clinical application has not been reported until today.

1.3.5. In cases of the **cortical approach**, a stimulator structure is inserted in the visual cortex, i. e. V1. In V1 of the cortex in the posterior cranial fossa, the visual cortex is located at the occipital pole. In the cortex, a distorted topography of the display of the visual world prevails in comparison to the retina. Each side of the visual cortex contains parts of the contralateral visual field and the visual information that falls onto the fovea is represented in a much larger cortical area than the periphery. The phenomenon is called cortical amplification. Stimulation electrodes in the cortex are controlled via a camera system and a neuroprocessor calculating stimulation pulses from the picture data that are necessary to successfully stimulate the cell groups in the cortex. In a pilot study, few patients had undergone surgery (second Sight website) (Rosenfeld, 2015). As far as it is known, the surgeries have been successful and the patients have reported about phosphene perceptions. It is unknown if they differ systematically from perceptions after retinal stimulation.

2. Range of indication for artificial vision

Solutions to restore the vision of blind people are reasonable when other procedures are not applicable or failed. A typical indication is retinitis pigmentosa (RP). This hereditary disease is characterized by a progressive loss of photoreceptors while typically first the rods

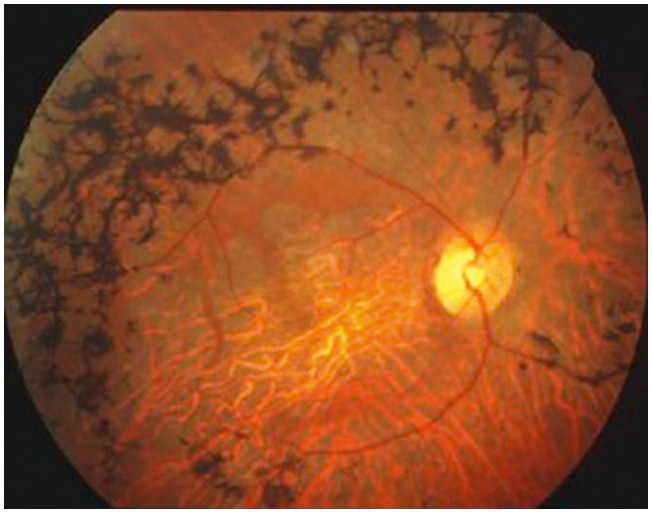

▶ **Fig. 4** Typical image of clinical funduscopy of a patient suffering from retinitis pigmentosa (RP). The name-giving pigment clumping is visible, stenosis of the vessels, paling of the temporal papilla of the optic nerve as well as atrophic retinal center.



▶ **Fig. 5** Optic coherence tomography (OCT) scan in case of an atrophic lesion performed in the context of age-related macular degeneration (AMD) with geographic atrophy. The imaging reveals a resolution of the normal layers in the area of the fovea (see ▶ **Fig. 1**) mainly in the area of the external retina located above the choroid. An area is seen that looks like punched. In fact, RPE is no longer identified.

and later also the cones lose their function. Clinically, first night blindness occurs, then the field of vision is increasingly impaired in a circular way. In the last stages of the disease, so-called tunnel vision develops, and this last island gets finally lost so that blindness is the final stage of the disease. Besides paling of the papilla, funduscopy often reveals the name-giving clumping of the pigment predominantly in the middle periphery (▶ **Fig. 4**). The origin of retinitis pigmentosa is a mutation in the genes that code for essential enzymes and other proteins of the visual process. It may be the case of the rhodopsin gene, the gene for phosphodiesterase, or the gene for the ATP transportation as well as several others. Overall, more than 178 genes are known in humans the mutation of which may lead to RP (Gene Database NCBI, retrieved on August 6, 2021).

Another disease requiring currently a system for artificial vision is geographic atrophy. It is a manifestation of the frequently observed age-related macular degeneration (AMD) that is characterized by a progressive loss of the retinal pigment epithelium (RPE). Also this disease finally leads to blindness because the RPE loss concerns the macula and because the photoreceptors cannot work without RPE. Other than in cases of RP, the field of vision remains, however, the central visual acuity disappears. Faces are no longer recognized; texts can no longer be read. In western countries, AMD is considered as most frequent origin of blindness. Beside smoking and certain genetic constellations, the most important risk factor is the age. While the exudative type of this disease can nowadays successfully be treated with anti-VEGF products, there is currently no approved therapy for the atrophic type.

Both diseases are characterized by photoreceptor failure that may be bridged by means of electric stimulation of the postsynaptic neurons in the retina. In cases of glaucoma for example, which is typically but not exclusively a pressure-related degeneration of the optic nerve, the retinal ganglion cells fail. With progression, the disease may lead to blindness. However, retinal stimulation is not taken into consideration because the original neuron of the retina is destroyed and can no longer be stimulated. This type of blindness might only be treated by means of a stimulator in the area of the CGL or V1, i. e. in a cortical way. The same is true for severe damage of the eye or tumors. In cases of perfusion-related blindness like the bilateral stenosis of the posterior cerebral arteries, even cortical stimulation scenarios are no longer appropriate. In general, the groups working on the development of such systems focus on the treatment of RP and the more frequently diagnosed AMD.

3. Outcomes of former approaches

Currently, experience in higher numbers of patients is only available for conditions after implantation of the ARGUS II system (epiretinal stimulator) and the Alpha IMS/AMS system (subretinal stimulator). All other systems have only been applied in very small numbers of patients in pilot studies. The experiences with these two approved systems can be summarized in that way that implantation is generally feasible, the complication rate is manageable and the benefit for vision is limited.

For the ARGUS II system, long-term data (more than 5 years after implantation) have been published on the achieved visual acuity and on the safety and complications. With the system, the patients were able to identify and localize a light spot on a screen much better than without the system. About 40 % of the patients had a measurable visual acuity of 2.9 logMAR corresponding to 0.001. Significant improvements were also found in mobility and orientation tasks. The most important complications included hypotension and conjunctival erosion (S. Rizzo et al., 2020; Schaffrath et al., 2019).

For the subretinal Alpha IMS/AMS system, the functional results have been published by of Stingl and Gekeler from Tübingen. All patients were able to recognize and localize light. The identification of movement, however, was rather difficult. In some patients, the resolution ability amounted to 1–0.1 cycles per degree. Two patients revealed visual signs and – similar to the Argus II system

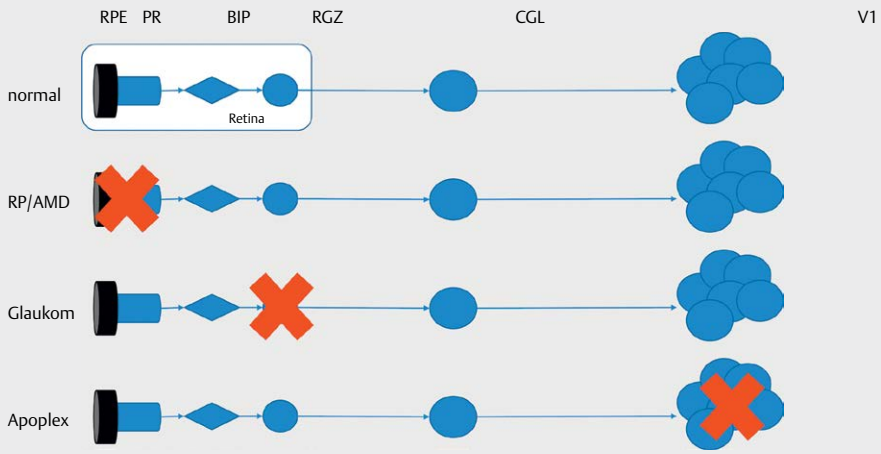

▶ **Fig. 6** Above, normal information flow from the retina with the retinal pigment epithelium (PRE), and photoreceptors (PR), bipolar cells (BIP) and retinal ganglion cells (RGZ) as well as lateral geniculate nuclei (CGL) and the visual cortex (V1). The red X show the sites of the lesion in the respective diseases. Stimulation concepts only make sense when the stimulation occurs on the left side of the failure. This means that blindness in cases of glaucoma or after apoplexy cannot be treated with a retinal implant.

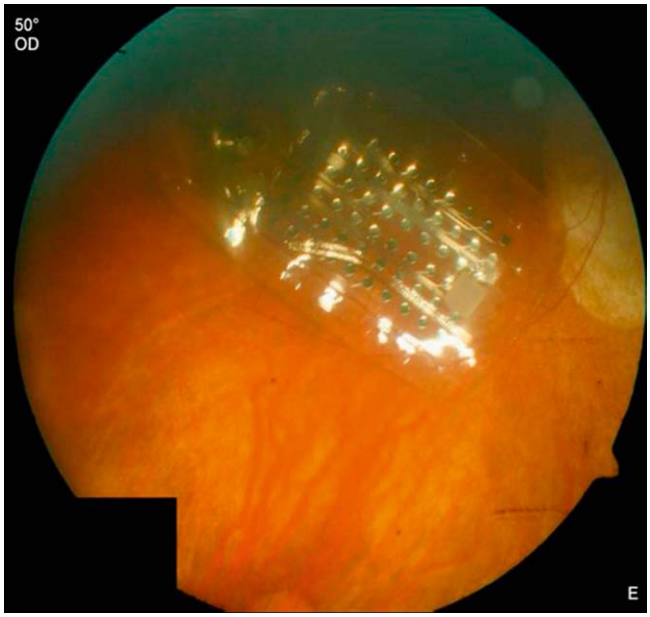

▶ **Fig. 7** Image of the fundus after implantation of an ARGUS II retinal prosthesis system. The sheet with 60 stimulus electrodes is seen on the retinal surface.

▶ **Fig. 8** Perforation of an Argus II receiver coil through the conjunctiva in the lower fornix. Despite multiple coverages, the implant had to be removed.

– tests regarding orientation and mobility turned out to be better (Gekeler et al., 2018; K Stingl et al., 2015; K. Stingl et al., 2017).

Both systems were applied exclusively in patients who had a visual acuity of hand movements or less and no usable field of vision. After implantation, the patients achieved a max. acuity of 1/40 with a very small field of vision. For many patients, this objective improvement of the visual acuity was not relevant in everyday life. The limited functional success finally led to the fact that the systems were no longer applied in practice and the manufacturers stopped the production and unfortunately even the support.

4. Reasons for the limited effect

4.1 Number, size, and density of electrodes

In a healthy human retina, more than 7 million cones and 100 million rods are found on the average as light-sensitive elements (information input) and 1.2 million ganglion cells (information output). In between, there is a complex network structure of vertical and horizontal synapses layers that process the input information of the light-sensitive elements and forward them in form of action potentials via the axons of the optic nerve to higher visual centers.

In the fovea alone, there are about 150,000 rods per mm². Considering the technical data of the implants, immediately the significantly lower number of input and output elements becomes obvious. The ARGUS II system used 60 epiretinal electrodes (output level of the retina) with a diameter of 200 µm on a surface of 5 × 3 mm. In the Alpha IMS/AMS chip 1,600 electrodes were installed subretinally on a surface of 4 × 3.2 mm (input level).

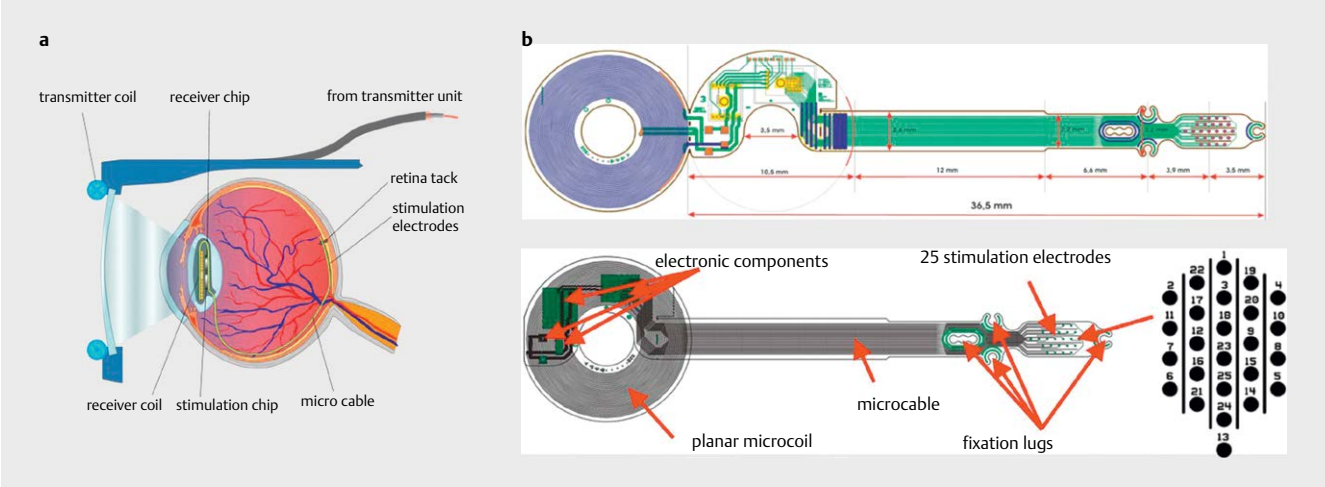

▶ **Fig. 9** On the left: EPIRET III concept. The stimulator foil is located epiretinally and is fixed with a retina tack. The data of the stimulation-pulse sequences are transmitted to the system via a flexible cable connection by an implanted receiver instead of the lens. A transmitter coil provides the receiver with energy and data that a visual neuroprocessor has calculated from a camera picture. The neuroprocessor determines which pulse is released at which electrode at which time. On the right: Layout of the EPIRET III system with receiver coil, miniaturized ASIC components fold on it and the following cable connection to the actual stimulator.

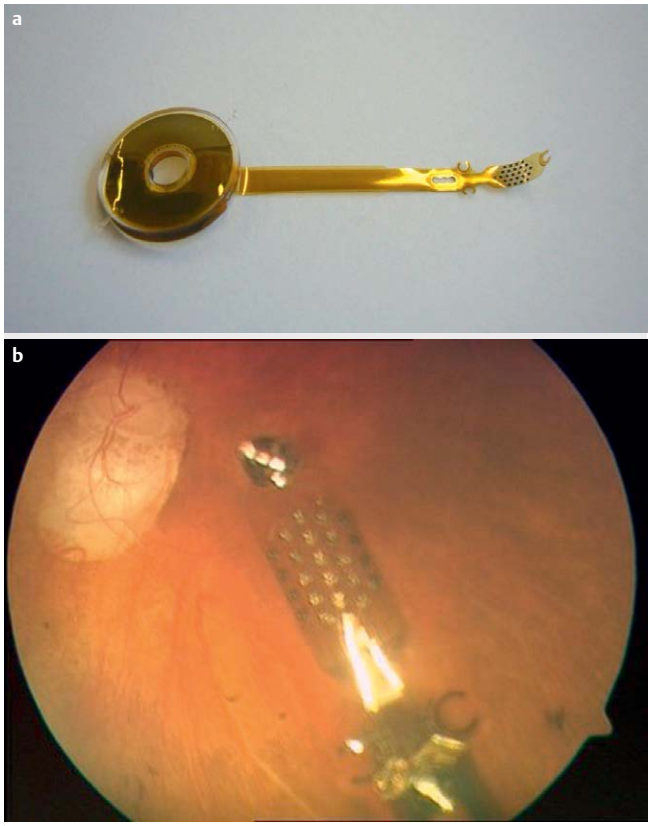

▶ **Fig. 10** On the left: EPIRET III system after encapsulation with polydimethylsiloxane (PDMS). On the right: EPIRET III stimulator fixed on the retinal surface of a patient with two retinal tacks.

The electrodes themselves have clearly larger sizes than single bipolar cells or single ganglion cells. So it may be expected that the stimulation with the electrode always leads to activation or inhibition of an entire group of retinal neurons. However, it is unknown how the group of stimulated or inhibited neurons is composed. Current stimulation algorithms do not consider this problem and therefore perception cannot be triggered despite intensive stimulation with simultaneous irritation of inhibitory and excitatory neurons.

4.2 Size of the stimulator

The stimulators of the ARGUS II and Alpha IMS/AMS systems until now were relatively small compared to the retinal surface. The entire surface of the human retina is approximately 590 mm². The surfaces of the approved stimulators are 12–15 mm² large, which is less than 3 % of the overall retinal surface. The visual field where perceptions could be restored is relatively small. A good description to illustrate the size of the restored visual field is the surface of a normal piece of paper (DIN A4) at arm's length in front of the eye. Accordingly, the implant users had to apply a certain technique in order to use the systems in daily life. They performed head movements to scan relevant parts of their surroundings and to focus them on the active surface of the implant ("head scanning").

4.3 Stimulation algorithm

The approved implants typically used biphasic current or voltage pulses in order to stimulate retinal neurons. The biphasic pulses should be charge-balanced so that no additional charge remains in the tissue at the end of the pulse for biocompatibility reasons. Nonetheless, even with biphasic pulses, electrical charge must not be introduced in high quantities into the tissue. The generally accepted biocompatible threshold for the retina amounts to 1 mC/cm² for electrodes with a diameter of 100 µm (J. Rizzo, Wyatt, Loewenstein, Kelly, & Shire, 2003). This represents the maximum of stimulation. At the lower edge, the perception threshold is defined. For each electrode, it is defined at which electrical charge a subjective perception may be registered in form of phosphenes. The stimula-

tion may occur on each electrode between this perception threshold and the upper level. Typically, the intensity range or the gray value of a pixel or pixel area (region of interest, ROI) from the camera picture is distributed on the field between both thresholds. The lighter the camera pixel or ROI is, the stronger is the stimulation. Theoretically, this approach is suitable for the activation of the so-called ON cells in the retina. If, however, the OFF canals are activated in this way, a stimulus is triggered that counteracts the actual effect mechanism, which leads to confusion and possibly even extinction of the visual perception.

4.4 Biological intrinsic activity

The decline of photoreceptors in the retina as consequence of a hereditary or other retinal degeneration does not lead to the fact that signals are no longer transmitted via the optic nerve to higher visual centers. The retinal ganglion cells have a spontaneous activity that can be measured even without visual stimuli. In different animal models of advanced retinal degeneration it can be shown that this spontaneous activity is significantly altered. In these cases wave-like spontaneous variations of the extracellular field potential, so-called oscillations, and also action potential spike bursts recordable, sometimes coupled to certain edges of these oscillations. It is not fully clarified how this abnormal spontaneous activity develops. First findings show that the electrical stimulation is particularly difficult in retinas revealing such a behavior (Biswas et al., 2014; Haselier et al., 2017).

4.5 Training and rehabilitation

In all types of electrical stimulation with implantable systems, the developers suggest that patients are trained with specific programs. The intention is to exercise how the impression of artificial vision may be integrated in daily life. Concerning our own patients, we sometimes had the feeling that the training is very exhausting for the patients and after a certain time it is even no longer perceived as such. The effect of the training was considered as being too low compared to the efforts undertaken. Especially in the context of the first two implant prototypes it was not known how training may be performed. There were no experiences, and results from animal experiments could not be applied.

4.6 Surgical aspects

In experimental implantations with lab animals as well as in follow-up examinations after implantation in patients, characteristic problems and complications become obvious. In the context of the subretinal approach with the Alpha IMS/AMS system, the surgery duration is rather long with 3–5 hours. In particular laying the cable connections between the actual implant in the eye and the power transmission system, which is comparable to the one of a cochlea implant system, is a highly demanding process that cannot be performed by an ophthalmologist alone but needs the support of an ENT surgeon. The implantation in the subretinal space is not trivial because the stimulator sheet has to remain imperatively in the correct layer when it is advanced between the choroid and the retina. Hereby, often a protective foil is used that is expected to impede perforation of the retina by the implant. In single cases, however, the retina may be perforated. Postoperatively, only few complications were observed with the Alpha AMS/IMS system. Only a displacement of the implant was found in rare cases. The lifetime of the device was the most important factor for this system. The stability of the system was rather poor, and a high number of implant failures was observed.

With regard to epiretinal systems, positioning and fixation of the implant on the retinal surface are of major importance. The more remote the stimulation electrode is from its target (the retinal ganglion cells), the more difficult is the stimulation. The standard fixation of epiretinal systems consisted of applying mechanical devices like retinal nails that mechanically fix the implant to the retina.

In the context of the Argus II system, the main problem was the size of the extraocular components of the implant that were inserted below the conjunctiva. This included in particular the receiver coil for the telemetry of energy and data and the cable passage through the sclera to the retina. At these points, perforations of the conjunctiva occurred. The coverage of these defects was a complex intervention associated with high risk of recurrence. In our own patients, we observed purulent endophthalmitis that required the immediate removal of the implant and led to a significantly long-term defect healing.

In general, epiretinal implants could be implanted more easily and within shorter time because the intervention was exclusively performed at the eye.

5. Innovative approaches

5.1 Reduction of the electrode size, increase of the electrode density

The disproportion between the target cell size and density requires stimulation structures with many more electrodes, much smaller electrodes, and a much higher electrode density, possibly even in a geometric configuration that corresponds to the natural arrangement of the target cells.

Stimulation electrodes, however, cannot be minimized due to technical limitations because a certain charge has to be released into the tissue. The smaller the electrode is, the higher is the charge density in the material and in the tissue, which may have a negative effect on the tissue as well as the material of the stimulation electrode if certain maximum values are exceeded. Since always aqueous conditions prevail at the electrode in or at the tissue, the excess of the limit values may lead to tissue and material damaging electrolysis of the water. Very small electrodes need to have a particularly large surface, which may be achieved by coating a classic metal electrode for example with activated iridium oxide. But also other materials may be applied such as PDOT or nanostructures like carbon nanotubes.

Another problem of highly dense stimulator structures consists in the necessary supply of all these electrodes with data and energy. In this context, intelligent bus systems are taken into consideration that might be used to connect the electrodes in such stimulator chips. Alternatively, optic transmission systems for data and power supply may be applied.

5.2 Increase of the stimulation surface

The stimulators that have been approved up to now activate only a very small surface of the retina so that the restored visual field is

proportionally small. Different teams have worked on increasing the surface of the stimulator chip. In the VLARS project, the team of Aachen has developed a stimulator with a diameter of 12 mm that covers 110 mm² of the retinal surface and that could be equipped with 250 electrodes of the technologies used at that time. This size was achieved by means of a highly flexible polyimide substrate with iridium oxide coated gold electrodes. A significant design characteristic of these structures was the wing-like structure that could be folded like an umbrella during implantation and therefore be implanted via a relatively small incision (Lohmann et al., 2019; Waschkowski et al., 2014).

5.3 Charge-controlled stimulation vs. power/tension-controlled stimulation

The electrical stimulation of nerve cells is mostly performed in a power- or tension-controlled way. However, for the tissue and material compatibility, mainly the charge is relevant that flows from the electrode into the tissue and back. Therefore, stimulators were conceived that maintain these parameters constant and control them very accurately (Erbsloh et al., 2017).

5.4 Bidirectional approach with local analysis of the intrinsic activity

Regarding the approaches that have been pursued up to now, the stimulation consists of a defined algorithm that transforms the brightness of pixels of a camera picture into current of a biphasic impulse. The brighter the pixel is, the stronger is the impulse set.

This regulation of the intensity occurs in an intensity range that is considered as biocompatible. However, the implanted electrodes are not always found in the area of neurons or neuron clusters for which such an ON behavior applies. Many antagonistic cell interconnections exist in the retina that lead for example to the fact that a retinal ganglion cell is inhibited with increasing lighting (OFF pathway). If this circuit is stimulated with the classic intensity-controlled algorithm, significant confusion develops because the cell stimulation does not correspond to the actual picture. In addition, the cellular connections are sometimes significantly "mixed up" in cases of advanced degeneration. As illustrated above, retinal ganglion cells show an abnormal spike behavior in the degeneration. Spontaneous bursts of action potentials and wave-like alterations of the field potentials (oscillations) occur. How neuron clusters may be optimally stimulated when they are altered in this way, is currently not clear. So it seems to be reasonable to first define which properties the neurons have that are in contact with the stimulation electrodes. For this reason, we promoted already very early bidirectional retina implants that have measurement channels beside stimulation electrodes allowing an electrophysiological definition of the spontaneous and stimulated activity of the near-electrode neurons in the retina (Montes et al., 2019; Peter Walter, 2016).

5.5 Power supply and packaging

In the EPIRET 3 project, we investigated if it was possible to construct and implant a stimulator that had no cable connection to the exterior but worked completely by telemetry. In a pilot study, we successfully implanted the EPIRET 3 system in six blind RP patients. The system completely uses the inductive power and data transmission via a coil system that on one hand can be installed in the glasses frame and on the other hand integrated in an artificial lens as a module of the intraocular system. The energy transmission occurs via a constant electromagnetic field on which the data stream is modulated. In the artificial lens, also the electronics for decoding of the data stream and for controlling the power sources for stimulation electrodes are found beside the receiver coil.

With the EPIRET III system, we could control 25 electrodes at the same time and achieve perception of simple patterns in otherwise blind people. Within the six weeks of implantation, no severe complications occurred. Theoretically, such approaches are suitable to avoid all complications that are associated with a cable passage through the sclera (Menzel-Severing et al., 2012; Mokwa et al., 2008; Roessler et al., 2009; Trieu, Goertz, Koch, Mokwa, & Walter, 2009).

6. Discussion

Beside the technical methods to restore the vision of blind people or people with severe visual impairment, there are also more biologically oriented procedures.

For genetic diseases, gene therapy seems to be the most reasonable approach because of possible causal option. A good example is RPE65 variant of RP where a defect is observed in the all-trans retinylester isomerase. When this defect is homozygous, the regeneration of the rhodopsin as visual pigment of the rods can no longer occur correctly. The affected patients go blind already in the first years of life. The disease is also called Leber's congenital atrophy (LCA) (Cideciyan & Jacobson, 2019). For this condition, the Voretigene Neparvove (AAV2-hRPE65v2) was developed which is an adenovirus-based RP65 gene construct that is meanwhile approved for the treatment of LCA (Russell et al., 2017).

Also gene editing techniques with modern CRISP/CAS systems are discussed as gene therapeutic approaches (Diakatou, Manes, Bocquet, Meunier, & Kalatzis, 2019). In clinical trials, already gene therapeutic approaches have been applied in other indications of retinal diseases.

Necrotic photoreceptors or atrophic retinal pigment epithelium can possibly be replaced by stem or other cells of embryonic origin. Early clinical experiments with iris pigment epithelium or retinal pigment epithelium showed a certain functional gain but also a series of complications like secondary atrophy in the transplantation area (Aisenbrey et al., 2007; Aisenbrey et al., 2006; ALGVERE, BERGLIN, GOURAS, & SHENG, 1994; Thumann et al., 2000).

The use of stem cells seems to be promising at first sight, however, clinical trials performed until now reveal rather limited results (Aghaizu et al., 2017; Tibbetts, Samuel, Chang, & Ho, 2012).

A very interesting approach is the genetic modification of ganglion cells of the retina with the insertion of genes for light-sensitive membrane proteins. In this way, the ganglion cells become light-sensitive and may serve as substitute of the photoreceptors. Since these light-sensitive proteins mostly need much more light than the visible light, they have to be stimulated by a laser scanner that is integrated in the glasses frame in front of the eye (Al-Atabany & Degenaar, 2011; Al-Atabany, McGovern, Mehran, Berlinguer-Palmini, & Degenaar, 2013; Barrett, Berlinguer-Palmini, & De-

genaar, 2014; Barriga-Rivera & Suaning, 2018; Busskamp & Roska, 2011; Dong et al., 2012; Garg & Federman, 2013).

Without any doubt, the gene therapy is the only causal therapy for a gene defect. However, this therapy has to be started early because it cannot revitalize already dead cells. Under clinical aspects, approaches with stem cells or the optogenetic approach are still in a rather experimental stage. Therefore, in cases of advanced degeneration with a significant loss of cells the technological approach seems to be the most suitable one in the sense of bridging lost neurological-sensory functions.

7. Conclusion and outlook

Strategies that have been pursued up to now, led to poorly convincing results in the clinical application. However, it could be shown in more than 400 patients with retinitis pigmentosa, which is a hereditary retinal degeneration leading to blindness, that both systems of ARGUS III and ALPHA IMS/AMS lead to reproducible visual perceptions. But the benefit for the patients in daily life was limited and the efforts for implantation were very high. The reasons for the limited outcome were due to technical factors as well as biological aspects. New strategies for development of such systems, consider these weaknesses and try to find solutions at least for parts of these issues.

Currently, further systems are included in clinical trials, however, reliable results have not been systematically published until now. It can be expected that new projects will generate new knowledge that will be the basis for the new development of these kinds of systems.

Conflict of interest

The authors declare that they have no conflict of interest.

References

[1] Aghaizu N, Kruczek K, Gonzalez-Cordero A, Ali R, Pearson R, Dunnett S, Bjorklund A. Pluripotent stem cells and their utility in treating photoreceptor degenerations. Functional Neural Transplantation Iv: Translation To Clinical Application, Pt B 2017; 231: 191–223. doi:10.1016/bs.pbr.2017.01.001

[2] Aisenbrey S, Bartz-Schmidt KU, Walter P, Hilgers RD, Ayertey H, Szurman P, Thumann G. Long-term follow-up of macular translocation with 360 retinotomy for exudative age-related macular degeneration. Archives of Ophthalmology 2007; 125: 1367–1372. doi:10.1001/archopht.125.10.1367

[3] Aisenbrey S, Lafaut BA, Szurman P, Hilgers RD, Esser P, Walter P, Thumann G. Iris pigment epithelial translocation in the treatment of exudative macular degeneration - A 3-year follow-up. Archives of Ophthalmology 2006; 124: 183–188. doi:10.1001/archopht.124.2.183

[4] Al-Atabany W, Degenaar P. Scene Optimization for Optogenetic Retinal Prosthesis. 2011 Ieee Biomedical Circuits and Systems Conference (Biocas) 2011; 432–435

[5] Al-Atabany W, McGovern B, Mehran K, Berlinguer-Palmini R, Degenaar P. A Processing Platform for Optoelectronic/Optogenetic Retinal Prosthesis. Ieee Transactions on Biomedical Engineering 2013; 60: 781–791. doi:10.1109/TBME.2011.2177498

[6] Algvere P, Berglin L, Gouras P, Sheng Y. Transplantation of Fetal Retinal-Pigment Epithelium in Age-Related Macular Degeneration with Subfoveal Neovascularization. Graefes Archive For Clinical and Experimental Ophthalmology 1994; 232: 707–716. doi:10.1007/BF00184273

[7] Ayton L, Barnes N, Dagnelie G, Fujikado T, Goetz G, Hornig R, Petoe M. An update on retinal prostheses. Clinical Neurophysiology 2020; 131: 1383–1398. doi:10.1016/j.clinph.2019.11.029

[8] Ayton L, Blamey P, Guymer R, Luu C, Nayagam D, Sinclair N, Res BVA. First-in-Human Trial of a Novel Suprachoroidal Retinal Prosthesis. Plos One 2014; 9. doi:10.1371/journal.pone.0115239

[9] Barrett J, Berlinguer-Palmini R, Degenaar P. Optogenetic approaches to retinal prosthesis. Visual Neuroscience 2014; 31: 345–354. doi:10.1017/S0952523814000212

[10] Barriga-Rivera A, Suaning G. Visual prostheses, optogenetics, stem cell and gene therapies: splitting the cake. Neural Regeneration Research 2018; 13: 805–806. doi:10.4103/1673-5374.232469

[11] Biswas S, Haselier C, Mataruga A, Thumann G, Walter P, Muller F. Pharmacological Analysis of Intrinsic Neuronal Oscillations in rd10 Retina. Plos One 2014; 9: doi:10.1371/journal.pone.0099075

[12] Busskamp V, Roska B. Optogenetic approaches to restoring visual function in retinitis pigmentosa. Current Opinion in Neurobiology 2011; 21: 942–946. doi:10.1016/j.conb.2011.06.001

[13] Cideciyan A, Jacobson S. Leber Congenital Amaurosis (LCA): Potential for Improvement of Vision. Investigative Ophthalmology & Visual Science 2019; 60: 1680–1695. doi:10.1167/iovs.19-26672

[14] da Cruz L, Dorn J, Humayun M, Dagnelie G, Handa J, Barale P, Grp AIS. Five-Year Safety and Performance Results from the Argus II Retinal Prosthesis System Clinical Trial. Ophthalmology 2016; 123: 2248–2254. doi:10.1016/j.ophtha.2016.06.049

[15] Diakatou M, Manes G, Bocquet B, Meunier I, Kalatzis V. Genome Editing as a Treatment for the Most Prevalent Causative Genes of Autosomal Dominant Retinitis Pigmentosa. International Journal of Molecular Sciences 2019; 20: doi:10.3390/ijms20102542

[16] Dong N, Sun X, Degenaar P, Kollias N, Choi B, Zeng H, Mandelis A. IMPLANTABLE OPTRODE DESIGN FOR OPTOGENETIC VISUAL CORTICAL PROSTHESIS. Photonic Therapeutics and Diagnostics Viii, Pts 1 and 2 2012; 8207: doi:10.1117/12.912386

[17] Duret F, Brelen M, Lambert V, Gerard B, Delbeke J, Veraart C. Object localization, discrimination, and grasping with the optic nerve visual prosthesis. Restorative Neurology and Neuroscience 2006; 24: 31–40

[18] Erbsloh A, Viga R, Walter P, Kokozinski R, Grabmaier A, Soc IC. Implementation of a Charge-Controlled Stimulation Method in a Monolithic Integrated CMOS-Chip for Excitation of Retinal Neuron Cells 2017

[19] Fujikado T, Kamei M, Kishima H, Morimoto T, Kanda H, Sakaguchi H, Ozawa M. One-Year Outcomes of 49-Channel Suprachoroidal-Transretinal Stimulation (STS) Retinal Prosthesis in Patients with Advanced Retinitis Pigmentosa. Investigative Ophthalmology & Visual Science 2016; 57:

[20] Garg S, Federman J. Optogenetics, visual prosthesis and electrostimulation for retinal dystrophies. Current Opinion in Ophthalmology 2013; 24: 407–414. doi:10.1097/ICU.0b013e328363829b

[21] Gekeler K, Bartz-Schmidt K, Sachs H, MacLaren R, Stingl K, Zrenner E, Gekeler F. Implantation, removal and replacement of subretinal electronic implants for restoration of vision in patients with retinitis pigmentosa. Current Opinion in Ophthalmology 2018; 29: 239–247. doi:10.1097/ICU.0000000000000467

[22] Haselier C, Biswas S, Rosch S, Thumann G, Muller F, Walter P. Correlations between specific patterns of spontaneous activity and stimulation efficiency in degenerated retina. Plos One 2017; 12: doi:10.1371/journal.pone.0190048

[23] Lee V, Nau A, Laymon C, Chan K, Rosario B, Fisher C. Successful tactile based visual sensory substitution use functions independently of visual pathway integrity. Frontiers in Human Neuroscience 2014; 8: doi:10.3389/fnhum.2014.00291

[24] Lohmann TK, Haiss F, Schaffrath K, Schnitzler AC, Waschkowski F, Barz C, Walter P. The very large electrode array for retinal stimulation (VLARS)? A concept study. Journal of Neural Engineering 2019; 16: doi:10.1088/1741-2552/ab4113

[25] Menzel-Severing J, Laube T, Brockmann C, Bornfeld N, Mokwa W, Mazinani B, Roessler G. Implantation and explantation of an active epiretinal visual prosthesis: 2-year follow-up data from the EPIRET3 prospective clinical trial. Eye 2012; 26: 502–509. doi:10.1038/eye.2012.35

[26] Moisseiev E, Mannis M. Evaluation of a Portable Artificial Vision Device Among Patients With Low Vision. Jama Ophthalmology 2016; 134: 748–752. doi:10.1001/jamaophthalmol.2016.1000

[27] Mokwa W, Goertz A, Koch C, Krisch I, Trieu HK, Walter P.Ieee. Intraocular Epiretinal Prosthesis to Restore Vision in Blind Humans. In 2008 30th Annual International Conference of the Ieee Engineering in Medicine and Biology Society 2008; Vols 1–8: pp. 5790-+

[28] Montes VR, Gehlen J, Luck S, Mokwa W, Muller F, Walter P, Offenhausser A. Toward a Bidirectional Communication Between Retinal Cells and a Prosthetic Device – A Proof of Concept. Frontiers in Neuroscience 2019; 13: 19. doi:10.3389/fnins.2019.00367

[29] Nishida K, Sakaguchi H, Kamei M, Cecilia-Gonzalez C, Terasawa Y, Velez-Montoya R, Quiroz-Mercado H. Visual Sensation by Electrical Stimulation Using a New Direct Optic Nerve Electrode Device. Brain Stimulation 2015; 8: 678–681. doi:10.1016/j.brs.2015.03.001

[30] Rizzo J, Wyatt J, Loewenstein J, Kelly S, Shire D. Perceptual efficacy of electrical stimulation of human retina with a microelectrode array during short-term surgical trials. Investigative Ophthalmology & Visual Science 2003; 44: 5362–5369. doi:10.1167/iovs.02-0817

[31] Rizzo S, Barale PO, Ayello-Scheer S, Devenyi RG, Delyfer MN, Korobelnik JF, Humayun MS. ADVERSE EVENTS OF THE ARGUS II RETINAL PROSTHESIS Incidence, Causes, and Best Practices for Managing and Preventing Conjunctival Erosion. Retina-the Journal of Retinal and Vitreous Diseases 2020; 40: 303–311. doi:10.1097/iae.0000000000002394

[32] Roessler G, Laube T, Brockmann C, Kirschkamp T, Mazinani B, Goertz M, Walter P. Implantation and Explantation of a Wireless Epiretinal Retina Implant Device: Observations during the EPIRET3 Prospective Clinical Trial. Investigative Ophthalmology & Visual Science 2009; 50: 3003–3008. doi:10.1167/iovs.08-2752

[33] Rosenfeld J. The Development of a Wireless Multi-electrode Cortical Prosthesis for Restoration of Vision in Blind Individuals. Journal of Neurosurgery 2015; 123: A486–A486

[34] Russell S, Bennett J, Wellman J, Chung D, Yu Z, Tillman A, Maguire A. Efficacy and safety of voretigene neparvovec (AAV2-hRPE65v2) in patients with RPE65-mediated inherited retinal dystrophy: a randomised, controlled, open-label, phase 3 trial. Lancet 2017; 390: 849–860. doi:10.1016/S0140-6736(17)31868-8

[35] Schaffrath K, Schellhase H, Walter P, Augustin A, Chizzolini M, Kirchhof B, Rizzo S. One-Year Safety and Performance Assessment of the Argus II Retinal Prosthesis: A Postapproval Study. Jama Ophthalmology 2019; 137: 896–902. doi:10.1001/jamaophthalmol.2019.1476

[36] Shivdasani M, Sinclair N, Dimitrov P, Varsamidis M, Ayton L, Luu C, Consortium BVA. Factors Affecting Perceptual Thresholds in a Suprachoroidal Retinal Prosthesis. Investigative Ophthalmology & Visual Science 2014; 55: 6467–6481. doi:10.1167/iovs.14-14396

[37] Stingl K, Bartz-Schmidt K, Besch D, Chee C, Cottriall C, Gekeler F, Zrenner E. Subretinal Visual Implant Alpha IMS – Clinical trial interim report. Vision Research 2015; 111: 149–160. doi:10.1016/j.visres.2015.03.001

[38] Stingl K, Schippert R, Bartz-Schmidt KU, Besch D, Cottriall CL, Edwards TL, Zrenner E. Interim Results of a Multicenter Trial with the New Electronic Subretinal Implant Alpha AMS in 15 Patients Blind from Inherited Retinal Degenerations. Frontiers in Neuroscience 2017; 11: doi:10.3389/fnins.2017.00445

[39] Thumann G, Aisenbrey S, Schraermeyer U, Lafaut B, Esser P, Walter P, Bartz-Schmidt KU. Transplantation of autologous iris pigment epithelium after removal of choroidal neovascular membranes. Archives of Ophthalmology 2000; 118: 1350–1355. Retrieved from<Go to ISI>://WOS:000089793800004

[40] Tibbetts M, Samuel M, Chang T, Ho A. Stem cell therapy for retinal disease. Current Opinion in Ophthalmology 2012; 23: 226–234. doi:10.1097/ICU.0b013e328352407d

[41] Trieu HK, Goertz M, Koch C, Mokwa W, Walter P. Implants for Epiretinal Stimulation of Retinitis Pigmentosa Patients. In O. Dossel & W. C. Schlegel (Eds.), *World Congress on Medical Physics and Biomedical Engineering, Vol 25, Pt 11: Biomedical Engineering for Audiology, Ophthalmology, Emergency and Dental Medicine* (Vol. 25, pp. 80-+) 2009;

[42] Veraart C, Duret F, Brelen M, Delbeke J.Ieee. Vision rehabilitation with the optic nerve visual prosthesis. Proceedings of the 26th Annual International Conference of the Ieee Engineering in Medicine and Biology Society 2004; Vols 1–7: 26 4163–4164

[43] Veraart C, Duret F, Brelen M, Oozeer M, Delbeke J. Vision rehabilitation in the case of blindness. Expert Review of Medical Devices 2004; 1: 139–153. doi:10.1586/17434440.1.1.139

[44] Walter P. A fully intraocular approach for a bi-directional retinal prosthesis. In: V. P. Gabel (Ed.), Artificial Vision.2016: pp. 151–161 Springer; Heidelberg, New York:

[45] Walter P. Future Developments in Retinal Prostheses. Klinische Monatsblatter Fur Augenheilkunde 2016; 233: 1238–1243. doi:10.1055/s-0042-115411

[46] Waschkowski F, Hesse S, Rieck AC, Lohmann T, Brockmann C, Laube T, Roessler G. Development of very large electrode arrays for epiretinal stimulation (VLARS). Biomedical Engineering Online 2014; 13: doi:10.1186/1475-925x-13-11