

CT Planning prior to Transcatheter Mitral Valve Replacement (TMVR)

CT-Planung vor kathetergestütztem Mitralklappenersatz (TMVR)

Authors

Linda Heiser¹, Robin F. Gohmann¹ , Thilo Noack², Katharina Renatus^{1,3}, Philipp Lurz^{4,5}, Holger Thiele^{3,4,5}, Patrick Seitz^{1*}, Matthias Gutberlet^{1,3,5*} 

Affiliations

- 1 Department of Diagnostic and Interventional Radiology, Heart Center Leipzig, Leipzig, Germany
- 2 Department of Cardiac Surgery, Heart Center Leipzig, University of Leipzig, Leipzig, Germany
- 3 Medical Faculty, University of Leipzig, Leipzig, Germany
- 4 Department of Cardiology, Heart Center Leipzig, University of Leipzig, Leipzig, Germany
- 5 LHI, Leipzig Heart Institute, Leipzig, Germany

Key words

TMVI, TMVR, transcatheter mitral valve implantation, transcatheter mitral valve replacement, computed tomography, CT

received 30.07.2021

accepted 09.11.2021

published online 10.03.2022

Bibliography

Fortschr Röntgenstr 2022; 194: 373–383

DOI 10.1055/a-1718-4182

ISSN 1438-9029

© 2022, Thieme. All rights reserved.

Georg Thieme Verlag KG, Rüdigerstraße 14, 70469 Stuttgart, Germany

Correspondence

Dr. Linda Heiser

Department of Diagnostic and Interventional Radiology, Heart Center Leipzig, Strümpellstraße 39, 04289 Leipzig, Germany

Tel.: +49/341/865 17 02

Linda.Heiser@helios-gesundheit.de

ABSTRACT

Background Transcatheter mitral valve replacement (TMVR) is a treatment option for patients with therapy refractory high-grade mitral valve regurgitation and a high perioperative risk.

During TMVR, the mitral annulus cannot be visualized directly. Therefore, comprehensive pre-interventional planning and a precise visualization of the patient's specific mitral valve anatomy, outflow tract anatomy and projected anchoring of the device are necessary.

Aim of this review-article is, to assess the role of pre-procedural computed tomography (CT) for TMVR-planning

Methods Screening and evaluation of relevant guidelines (European Society of Cardiology [ESC], American Heart Association [AHA/ACC]), meta-analyses and original research using the search terms “TMVR” or “TMVI” and “CT”. In addition to this, the authors included insight from their own clinical experience.

Results CT allows for accurate measurement of the mitral annulus with high spatial and adequate temporal resolution in all cardiac phases. Therefore, CT represents a valuable method for accurate prosthesis-sizing.

In addition to that, CT can provide information about the valvular- and outflow-tract-anatomy, mitral valve calcifications, configuration of the papillary muscles and of the left ventricle. Additionally, the interventional access-route may concomitantly be visualized.

Conclusion CT plays, in addition to echocardiographic imaging, a central role in pre-interventional assessment prior to TMVR. Especially the precise depiction of the left ventricular outflow tract (LVOT) provides relevant additional information, which is very difficult or not possible to be acquired in their entirety with other imaging modalities.

Key Points:

- CT plays a central role in pre-interventional imaging for TMVR.
- CT-measurements allow for accurate prosthesis-sizing.
- CT provides valuable information about LVOT-anatomy, mitral calcifications and interventional access-route.

Citation Format

- Heiser L, Gohmann RF, Noack T et al. CT Planning prior to Transcatheter Mitral Valve Replacement (TMVR). Fortschr Röntgenstr 2022; 194: 373–383

ZUSAMMENFASSUNG

Hintergrund Der Transkatheter-Mitralklappenersatz (TMVR) ist ein interventionelles Verfahren zur Behandlung einer hochgradigen Mitralklappeninsuffizienz bei Patienten mit hohem operativen Risiko.

Während der Intervention ist keine direkte Sicht auf die Mitralklappe gegeben, wodurch beispielweise eine intraoperative Größenauswahl der Mitralklappenprothese nicht möglich ist. Daher sind im Vorfeld der Prozedur sowohl die Bestimmung und Ausmessung der individuellen Mitralklap-

* The authors contributed equally as senior authors.

penanatomie als auch eine Beurteilung hinsichtlich der morphologischen Eignung bezüglich Ausflusstraktanatomie und der voraussichtlichen Verankerung der geplanten Mitralklappenprothese mittels einer nicht invasiven Darstellung erforderlich.

Ziel dieses Review-Artikels ist es, die Rolle der Computertomografie (CT) im Rahmen der Planung für TMVR einzuordnen.

Methode Begutachtung und Einordnung der aktuellen Behandlungsleitlinien der entsprechenden Fachgesellschaften (European Society of Cardiology [ESC], American Heart Association [AHA/ACC]) sowie von Metaanalysen und Originalstudien, welche den Suchbegriffen „TMVR“ bzw. „TMVI“ und

„CT“ enthielten. Ergänzend dazu wurden Erkenntnisse aus der eigenen klinischen Erfahrung der Autoren eingebracht.

Schlussfolgerung Mit der CT sind die Vermessung des Mitralklappenannulus mit hoher räumlicher und adäquater zeitlicher Auflösung und damit eine zuverlässige präinterventionelle Größenbestimmung der zu implantierenden Mitralklappenprothese möglich. Des Weiteren können mittels der CT Aussagen über die Klappen- und Ausflusstraktanatomie, Mitralklappenverkalkungen, die Konfiguration von Papillarmuskeln und des linken Ventrikels getroffen werden. Darüber hinaus können mittels der CT alle potenziellen Zugangswege für die Intervention dargestellt werden.

Introduction

Mitral valve regurgitation (MR) represents the most common valvular cardiac disease in the western world. Prevalence is age-dependent and increases with age; above the age of 75 years, it increases to as much as 10% in the normal population [1].

The origin can be classified as either primary or secondary MR. Primary MR is due to degenerative or destructive causes resulting in pathological changes in the valve annulus and leaflets and ultimately to inadequate valve closure. The most common cause is mitral valve prolapse [2]. Secondary insufficiency generally occurs in the course of annulus dilation due to left atrial dilation (atrial mitral insufficiency) or alteration of left ventricular geometry as consequence of primary or secondary cardiomyopathy [3, 4].

According to the current European treatment guidelines, early surgical mitral valve repair or surgical valve replacement is primarily recommended in patients with symptomatic high-grade primary MR and left ventricular ejection fraction (LVEF) > 30%. Optimization of drug therapy is recommended first in patients with severely impaired LVEF (< 30%). In the absence of successful therapy, surgical or interventional therapy may be performed after interdisciplinary decision making in the Heart Team. Interventional or surgical treatment of secondary MR is the subject of ongoing debate. Thus, in current treatment recommendations, surgical therapy is recommended only when bypass surgery is performed simultaneously and LVEF > 30% (class I, level of evidence C). Surgical mitral valve therapy alone may be considered if LVEF < 30% and operative risk is low (class IIa, level of evidence C). If the operative risk is increased, interventional reconstruction/replacement may be considered (class IIb, level of evidence C) [5].

Due to the increasing prevalence of MR in older age and the associated rise in surgical risk, different interventional procedures have been developed as an alternative to drug or surgical therapy alone. Various approaches are available for interventional treatment of the mitral valve. A basic distinction can be made between transcatheter mitral valve repair and transcatheter mitral valve replacement (TMVR). According to their therapeutic approach, reconstructive interventional procedures can be divided into ring annuloplasty (e. g. Cardioband), coaptation (e. g. MitraClip, PASCAL), and neochord (e. g. NeoChord, Harpoon) procedures [6]. All procedures are subject to anatomical and morphological

selection criteria. If these are not met, TMVR is another treatment option.

In addition to treating MR, transcatheter mitral valve replacement (TMVR) can also be used to treat calcified mitral valve stenosis or as part of a “*valve-in-ring*” or “*valve-in-valve*” procedure [7].

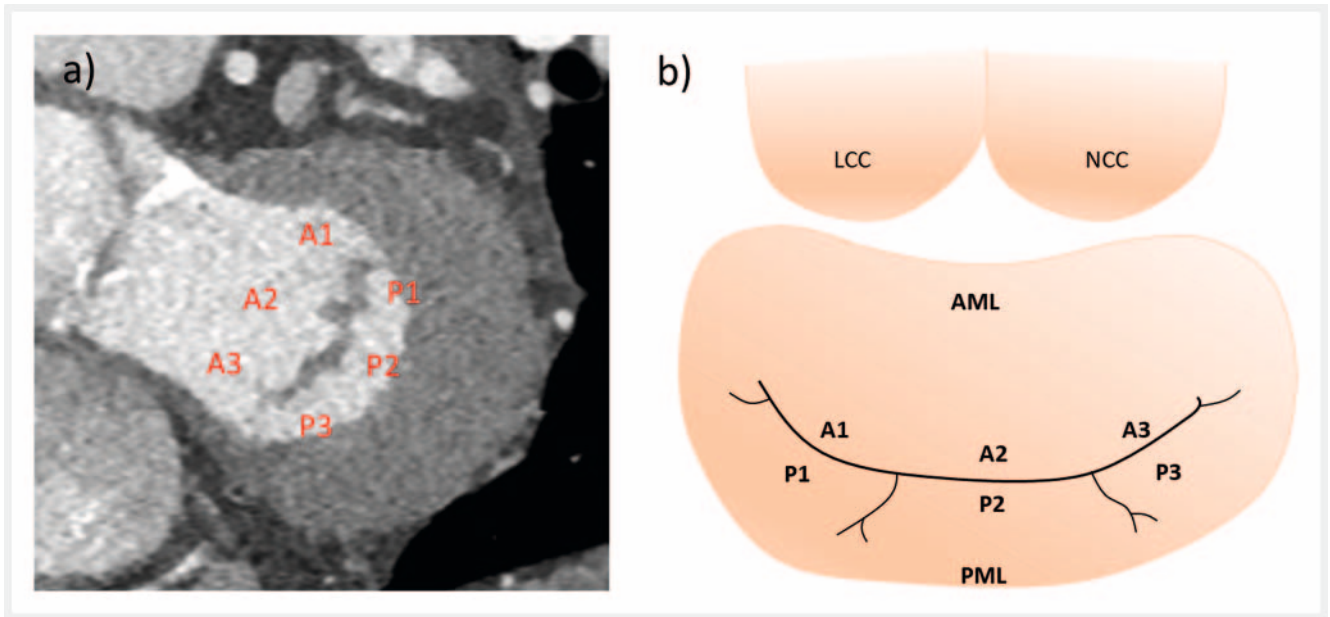
Specific measurements of the complex three-dimensional anatomy of the mitral valve annulus and surrounding structures are necessary for pre-interventional planning of a TMVR; a CT examination with ECG gating is a suitable method for this due to its high spatial and adequate temporal resolution.

CT shows higher reliability compared to echocardiography with respect to the measurement of the annulus and sizing of the prosthetic valve [8]. The key advantage of CT scanning over other non-invasive imaging modalities is the ability to visualize the entire cardiac anatomy, including the coronary arteries and the potential access routes as well as the estimation of the postinterventionally altered left ventricular outflow tract (“*neo-LVOT*”) in a single examination within a few seconds.

Features of Mitral Valve Anatomy

The mitral valve consists of two connective tissue leaflets, an anterior (AML) and posterior (PML) mitral valve leaflet, each of which can be subdivided into three segments (► **Fig. 1**). Both valve leaflets merge at the medial and lateral commissure. In addition to the leaflets, the functional unit of the mitral valve is completed by the annulus as well as the holding mechanism. The anterior third of the annulus is formed by the fibrous component, at the end of which there are two connective tissue-compacted areas: the medial and lateral trigonum. These trigones, together with the AML and through their direct relationship to the aortic valve and the left ventricular outflow tract (LVOT), form what is known as the aortomitral continuity. The posterior two-thirds form the muscular portion of the annulus. The subvalvular portion of the valve is composed of the chordae tendineae and papillary muscles that connect the mitral valve leaflets to the left ventricular myocardium [9–11].

The complexity of the mitral valve anatomy is based on the saddle-shaped three-dimensional dynamic form of the annulus (► **Fig. 2a, b**). This saddle-shaped annulus has its highest point in the middle of the anterior third and extends to the level of the



► **Fig. 1** Segments of the mitral valve. Short-axis view through the mitral valve (in systole) **(a)**. The three anterior (A1–A3) and posterior (P1–P3) valvular segments can be identified in the CT as shown above. Additionally, the anatomic structure of the mitral valve is schematically depicted in **b** (modified from Capoulade *et al.* [37]). (AML = anterior mitral leaflet, PML = posterior mitral leaflet, LCC = left coronary cusp of the aortic valve, NCC = non-coronary cusp of the aortic valve).

aortic valve, more specifically to the insertion of the left coronary and the aortic cusp. Another, smaller elevation is found at the insertion of the posterior leaflet. The lowest points of the annulus are formed by the trigones [12, 13].

Available Devices

Challenges to secure placement and anchoring of the prosthesis during TMVR include the complex anatomy of the mitral valve, annulus dynamics and aortomitral continuity. For example, the annulus increases in size by up to 20% during systole [14]. In addition, implantation of the prosthesis carries the risk of obstruction because of the close spatial relationship of the mitral valve annulus to the LVOT.

The various conceivable solutions for taking these anatomical and physiological conditions into account result in a variety of devices which differ, for example, by the anchoring mechanism and in their position relative to the annulus (► **Table 1**, ► **Fig. 3**).

At this time, there are more than 30 devices available, some of which are summarized in ► **Table 1** [10, 15–18]. Currently the most common one is the Tendyne device (Abbott Cardiovascular, Plymouth, USA), which is the only apparatus with CE certification for use in routine clinical practice. In addition, off-label use with a prosthesis for transcatheter aortic valve implantation, e. g., the Sapien 3 (Edwards Lifesciences, Inc., Irvine, CA, USA), is also possible [19]. Other devices are currently undergoing clinical trials.

The chosen access route should be as perpendicular as possible to the annulus in order to achieve optimal deployment and anchorage of the device, thus reducing the risk of LVOT obstruction or paravalvular leak. On the one hand, a transapical approach can be selected, since the imaginary central axis between annulus

and apex of the left ventricle (LV) can usually be projected well and determined by CT (► **Fig. 4**) [20–23]. On the other hand, the less invasive transfemoral-transseptal access is also an option for prosthesis implantation, which does not require opening of the thorax by mini-thoracotomy as in the transapical approach, thus allowing a purely endovascular procedure [24]. In the context of transseptal puncture, CT can provide helpful additional information for visualizing the best possible procedure regarding access to the left atrium and mitral valve [10].

In a 2017 meta-analysis by del Val *et al.*, the proportion of successful implantations in the reviewed studies was approximately 92% of the total procedures performed. LVOT obstruction was observed in only 0.4% of patients [25].

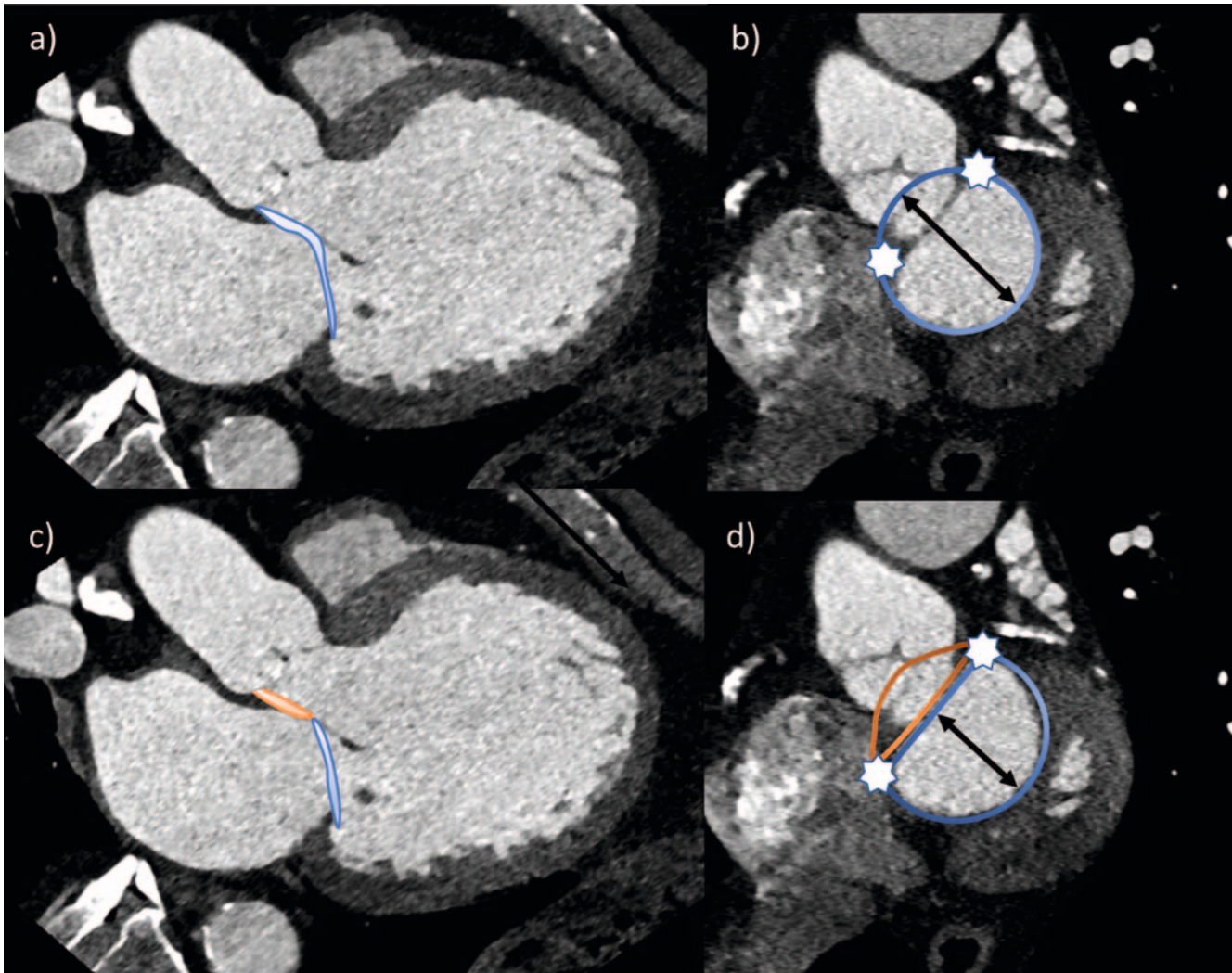
CT Scanning Protocol

A CT scanner with the highest possible temporal resolution is advantageous due to the need to visualize heart structures as artifact-free as possible throughout the cardiac cycle.

With only a few exceptions, a helical scan of the heart with retrospective ECG gating should be employed in order to allow measurement in multiple cardiac phases and to create dynamic reconstructions of mitral valve motion as a moving image series over the cardiac cycle. Supplemental cardiac calcium scoring should be considered to plan the cardiac scan window and positively identify mitral valve calcifications [26].

Additionally, a depiction of the anticipated access route is useful. If a transapical approach is anticipated, supplementary imaging or reconstruction of the thorax may be helpful.

Optimally, imaging of cardiac anatomy should be performed as a helical scan of the heart using retrospective ECG gating imme-

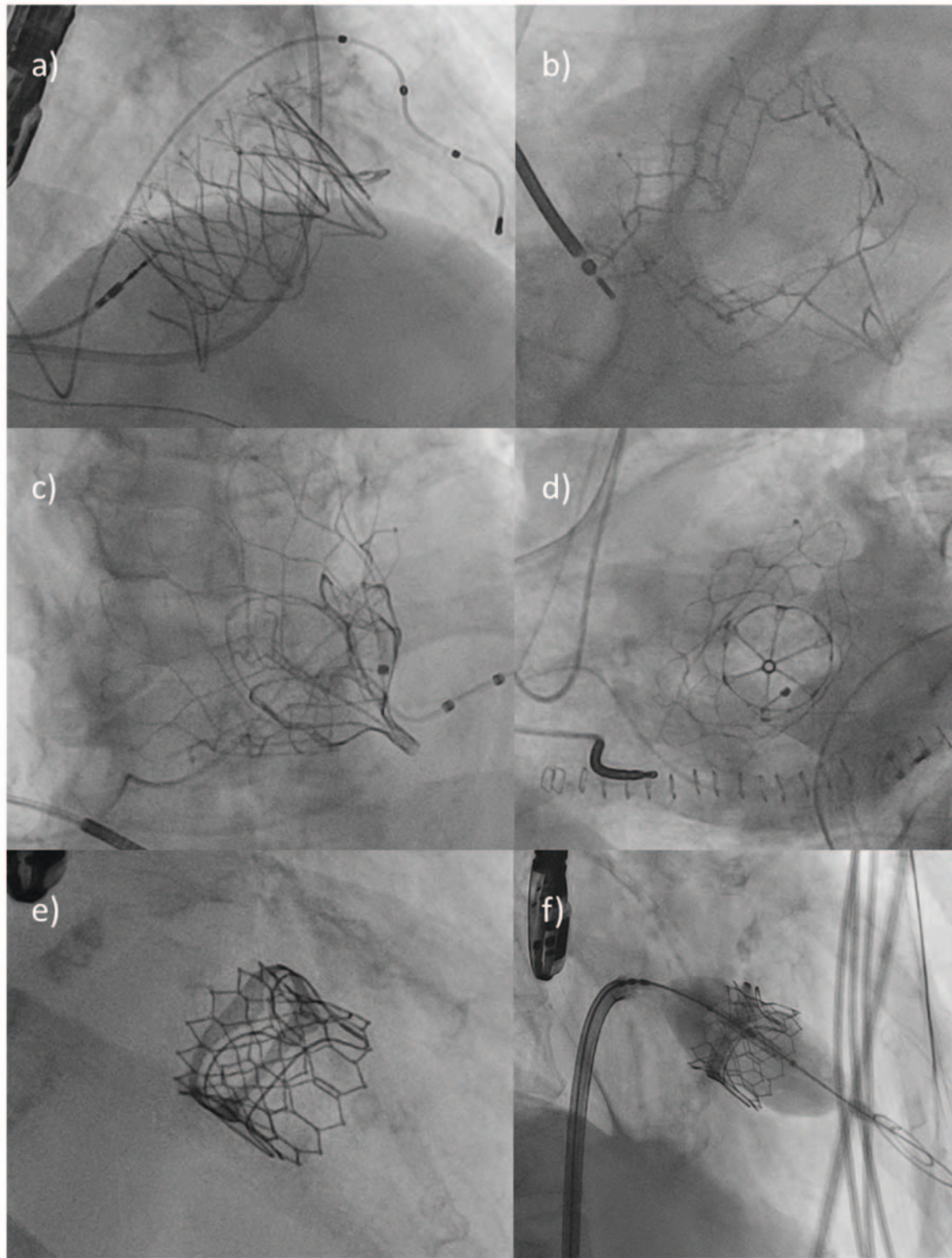


► **Fig. 2** Mitral valve annulus in saddle-shape (**a, b**) and in D-shape (**c, d**). The anterior part of the mitral valve annulus is included in the saddle-shape (blue contour in **a, b**). Therefore, AP (black lines in **b, d**) is larger in saddle-shape than in D-shape configuration (blue contour in **c, d**). In the D-shaped annulus, the anterior part (orange contour in **c, d**) is not included. The white stars in **b, d** mark the trigones. (AP = anterior-posterior diameter).

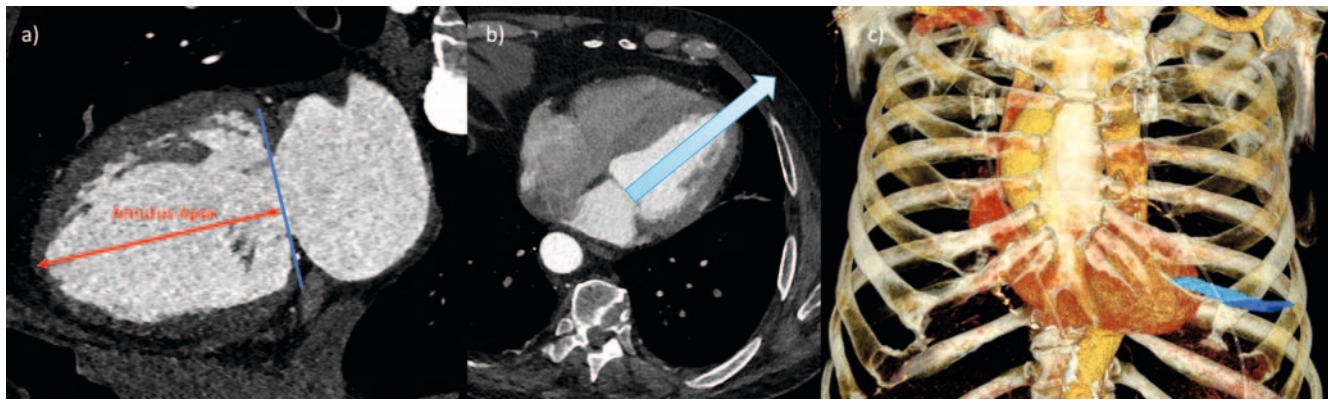
► **Table 1** Overview of the most common devices for TMVR

Device (manufacturer)	Rate of successful implantations (%)	LVOT-obstruction (%)	Access route	Anchoring mechanisms	Relevant sizing-parameters
Tendyne (Abbott)	93.3	0	transapical	“apical tether”	AP; LM
Tiara (Neovasc)	84.2	0	transapical	Capture of trigona	Perimeter; LM
Intrepid (Medtronic)	96	0	transapical	Radial force	Perimeter; AP; LM
Sapien III (Edwards)	76.7	N/A	transseptal-transfemoral	Radial force	Area, Perimeter, max. Diameter

Overview of commonly used valve prostheses for TMVR, their complications rates and important parameters regarding implantation/planning (modified from Ranganath et al. [10] (TMVR = transcatheter mitral valve replacement, LVOT = left ventricular outflow tract, AP = Anterior-posterior diameter, LM = Lateromedial diameter, N/A = not available).



► **Fig. 3** Peri-interventional fluoroscopic representation of various TMVR devices. **a, b** The TIARA device is configured in the shape of a crown. The anchoring takes place by capturing the trigones using the myocardial shelf. **c, d** The Tendyne device is configured conically. It is anchored via an “apical tether”. **e, f** Sapien 3 in mitral position (here as valve-in-valve implantation) in a previously implanted biological mitral valve prosthesis. In contrast to the other devices, the Sapien 3 is expanded via balloon (**f**). (TMVR = transcatheter mitral valve replacement).



► **Fig. 4** Planning for transapical approach. **a** The annulus-apex distance (red line) is determined in a two-chamber view and corresponds to the distance from the middle of the mitral valve plane (blue line) to the LV apex. **b** If the annulus-apex-line is elongated until it intersects the thoracic wall (blue arrow), the optimal trajectory for a transapical approach can be planned. The use of a scan of the complete thorax is recommended for identification and counting of the correct intercostal space (ICR). In the depicted case, the optimal transapical access route is located in the 5. ICR. **c** This can be visualized as 3D-reconstruction.

diately followed by an untriggered scan utilizing the same contrast bolus for imaging of the access pathway. In order to achieve sufficient contrast, it is recommended to adapt the amount of contrast medium to the scan time and, if necessary, the patient's cardiac output. The typically flattened contrast kinetics in patients with high-grade MR can be counteracted with an appropriately high flow rate (>5 ml/s).

Cardiac scan reconstruction should be performed in 5% increments with respect to the RR interval and the use of the smallest possible slice thickness and increment is recommended.

To shorten the switching time, it may be useful to vary the scan direction so that the helical scan of the heart is performed in caudocranial scan direction and remaining volume is scanned in the opposite direction.

Using a scan mode with retrospective ECG gating provides a comparatively high probability for possibly diagnostic assessment of the coronary arteries since correction of arrhythmias can be achieved via manual editing of the ECG-based reconstruction parameters [27]. Furthermore, even with higher heart rates or arrhythmia, diagnostic coronary imaging is more likely to be possible in this scan mode compared to using prospective ECG triggering [28]. Therefore, evaluation of a CT scan for planning TMVR should include assessment of the coronary arteries with respect to anomalies and possible stenosis.

Saddle vs. D-Shape

Accurate measurement of the mitral valve annulus is the focus of preinterventional CT planning. The anatomically saddle-shaped form of the annulus makes it difficult to establish a two-dimensional plane that can be easily measured. Therefore, it is advantageous to simplify the complex 3-dimensional shape of the annulus to a 2-dimensional contour by projecting suitable landmarks. This projection takes the simplified form of a virtual "D" (► Fig. 2c, d). With this "D-shaped" configuration the trigona fibrosa are connected by a virtual line and the anterior horn, which is not contained in the two-dimensional plane, is neglected [11, 12]. Looking at

the shape of the most commonly used devices, such as Tiara or Tendyne, the cross-section at the level of the landing zone also corresponds most closely to a "D-shaped" configuration. Likewise, use of the D-shape is advantageous with respect to the correct evaluation of a possible LVOT obstruction. Neglecting the anterior horn reduces the probability of an oversized prosthesis, while assuming an approximately tubular deployment of the prosthesis allows for a more realistic representation of the actual position of the implanted device, especially with regard to the positional relationship to the LVOT or the assumed configuration of the "neo-LVOT" after implantation [29].

Step-by-Step Instructions

To set the correct annulus plane, it is useful to have dedicated postprocessing software that allows the preparation of multiplanar reconstructions (MPR) in several planes. However, this can also be done with most radiological image storage and communication systems (PACS). For this purpose, it is recommended to link the related planes and visualize their alignment using a crosshair.

► Fig. 5 illustrates an image-by-image representation of the previously described steps.

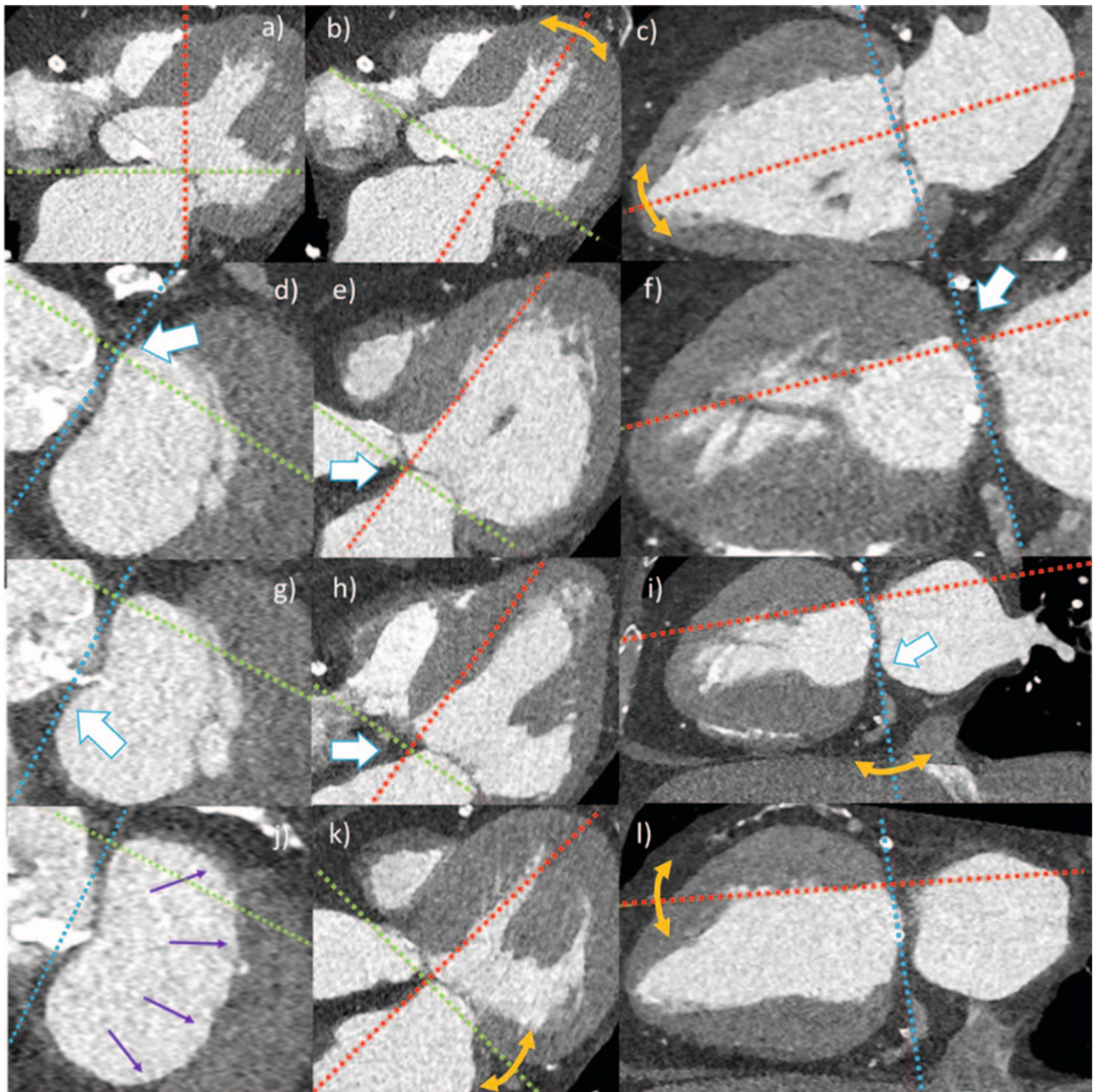
This created sectional plane now allows the determination of the relevant measurement values for sizing of the valve prosthesis (► Fig. 6), which should be performed in an analogous manner in systole and diastole.

The most common measured values to be determined are shown in ► Fig. 6 and summarized in List 1 [29].

Risk Factors of LVOT Obstruction

Proper selection of prosthesis type and size is important, since LVOT obstruction is a potential and relevant complication of TMVR.

The native LVOT is located between the basal interventricular septum and the aortomitral continuity (► Fig. 7a). Due to protrusion



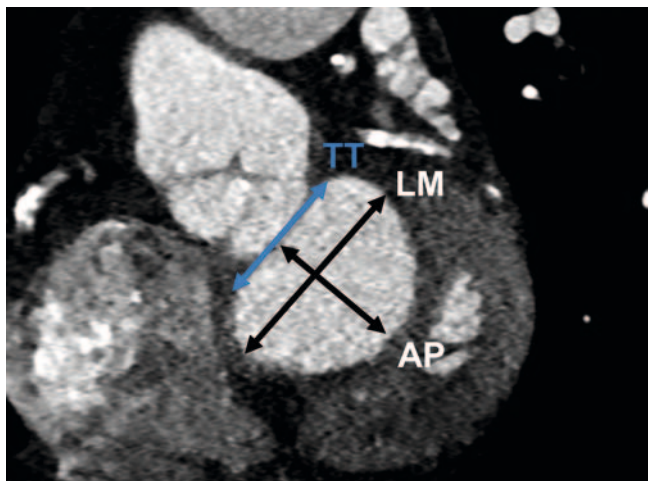
► **Fig. 5** Step-by-step instructions for setting the mitral valve annulus using CT. All available planes should be considered simultaneously for each setting step, employing postprocessing software with the possibility of creating multiplanar reconstructions.

Step 1 (a–c): Rough approach to the mitral valve plane. The crosshairs are centered on the middle of the mitral valve plane (a). Subsequently, the second and third planes (b, c) are aligned along the AV valve plane. A rough orientation to the LV apex is helpful for alignment in basal-apical direction.

Step 2 (d–f): Setting the left trigonum. In the short-axis view, the location of the left trigonum is identified and put in the crosshairs are (white arrow in d, e, f). When set correctly, it is shown as a triangularly configured, clearly defined structure.

Step 3 (g–i): Setting the right trigonum. By rotating the second plane (i), the right trigonum fibrosum (white arrow in g, h, i) is also adjusted in short axis view (g) until it can be seen as a clearly delineated triangular structure. Once this is achieved, TT and thus the septal contour of the mitral valve annulus are correctly set.

Step 4 (j–l): Setting the lateral annulus contour. In the short axis (j), the crosshairs are set to the TT. The lateral annulus contour (purple arrows in j) is now adjusted in the second plane (k, l) until a D-shape is seen in short axis view (j) and the lateral contour is completely occupied by the mitral valve annulus. (TT = inter-trigonal distance, AV valve plane = atrioventricular valve plane).



► **Fig. 6** Mitral valve annulus in D-Shape: The central measured values are TT, LM and AP (TT = inter-trigonal distance, LM = lateral-medial diameter, AP = anterior-posterior diameter).

sion of the prosthesis into the left ventricle, the resulting elongation of the native LVOT and interaction with the AML result in the formation of a so-called “neo-LVOT” (► **Fig. 7b, c**).

The risk of obstruction grows with increasing size and protrusion of the device. According to the current state of knowledge, limit values for the area of the “neo-LVOT” are 1.7–1.9 cm² and are device-specific [30].

Patient-specific characteristics included aortomitral angulation (► **Fig. 7d**), left ventricular dimension and basal septal thickness (► **Table 1**).

Aortomitral angulation influences the subsequent position and alignment of the prosthesis and describes the angle between the respective orthogonal to the mitral and aortic valve planes (► **Fig. 7d**). Theoretically, an approximately parallel alignment of both axes would be optimal, whereas the risk of obstruction increases significantly if this approaches or exceeds 90° [29, 31].

Hypertrophy of the basal interventricular septum (> 15 mm) may also lead to narrowing of the LVOT (or “neo-LVOT”). In addition, a small left ventricular cavity is another risk factor in this regard. In patients with secondary MR, the LV is usually clearly dilated, whereas in patients with primary MR the mostly hyperdynamic LV function leads to a systolic reduction in the LV cavity [12].

Landing Zone

CT also provides information on the so-called landing zone of the device, which is influenced by numerous factors such as the presence/distribution of annular calcification or the development of a myocardial shelf.

Myocardial shelf

The anatomical difference between the landing zone in primary and secondary MR is important in pre-interventional planning. Secondary MR is often associated with regional wall movement disorders and dilation of the LV, which leads to displacement of

the papillary muscles as well as ultimately to annulus dilation. Furthermore, remodeling of the basal myocardium also disrupts the actual linear connection between the left atrial and left ventricular myocardium, resulting in the so-called “myocardial shelf”. The size of the “myocardial shelf” depends on several factors; typically, it is largest in the presence of LV dilation combined with posterior wall infarction. Importantly, the “myocardial shelf” is also subject to dynamic size change and may even disappear altogether during systole. Determining the exact extent of the myocardial shelf is important because some self-expanding systems require a persistent shelf for anchorage. In patients with primary MR, there is typically no “myocardial shelf” present [29, 32, 33].

Mitral valve calcification

Calcification of the mitral valve annulus, trigona fibrosa or valve leaflets may also influence intervention planning and can be well visualized by CT (► **Fig. 8**). Generally, calcifications are found in the posterior portion of the annulus fibrosus and are particularly present in elderly patients [34, 35].

Computed tomographic imaging in short-axis view (► **Fig. 8a**) is particularly suitable for describing calcifications. According to Guerrero *et al.* [36] an association was found between minor calcifications of the mitral valve and an increased likelihood of migration of the TMVR device; a score was used for quantification and standardized recording of the calcifications. This score refers to the thickness of annular calcifications, their extension in relation to the circumference, the involvement of the trigona and the valve leaflets [36].

Annulus-Apex Connection

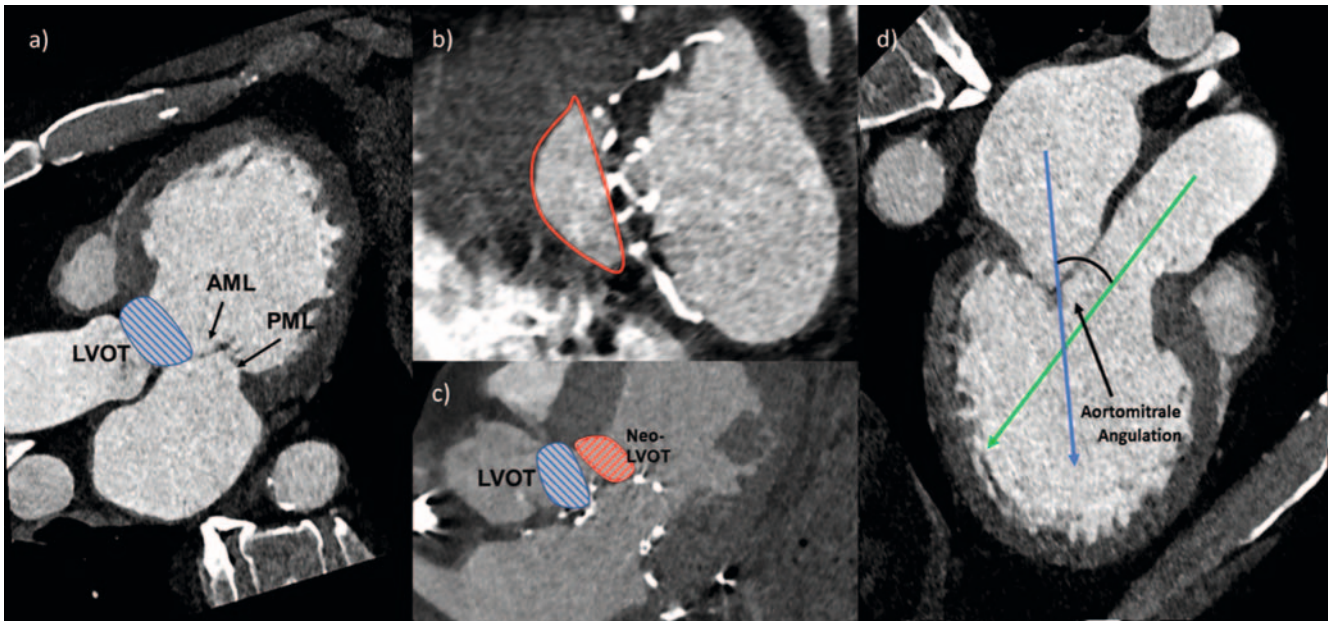
The orientation and length of the annulus-apex line represent (► **Fig. 4a**) additional relevant information for TMVR planning. To achieve this, an orthogonal connecting line is drawn from the center of the mitral valve plane to the epicardial contour of the LV apex (► **Fig. 4a**) [31]. This facilitates the planning of a transapical access route, since the necessary length and orientation of the delivery system can be assessed here (► **Fig. 4**).

The location of the LV apex with respect to the center of the mitral valve plane may vary from patient to patient [31]. Visualization of the actual anatomy can provide information on whether deviating from a strictly transapical access path will allow better alignment of the delivery system.

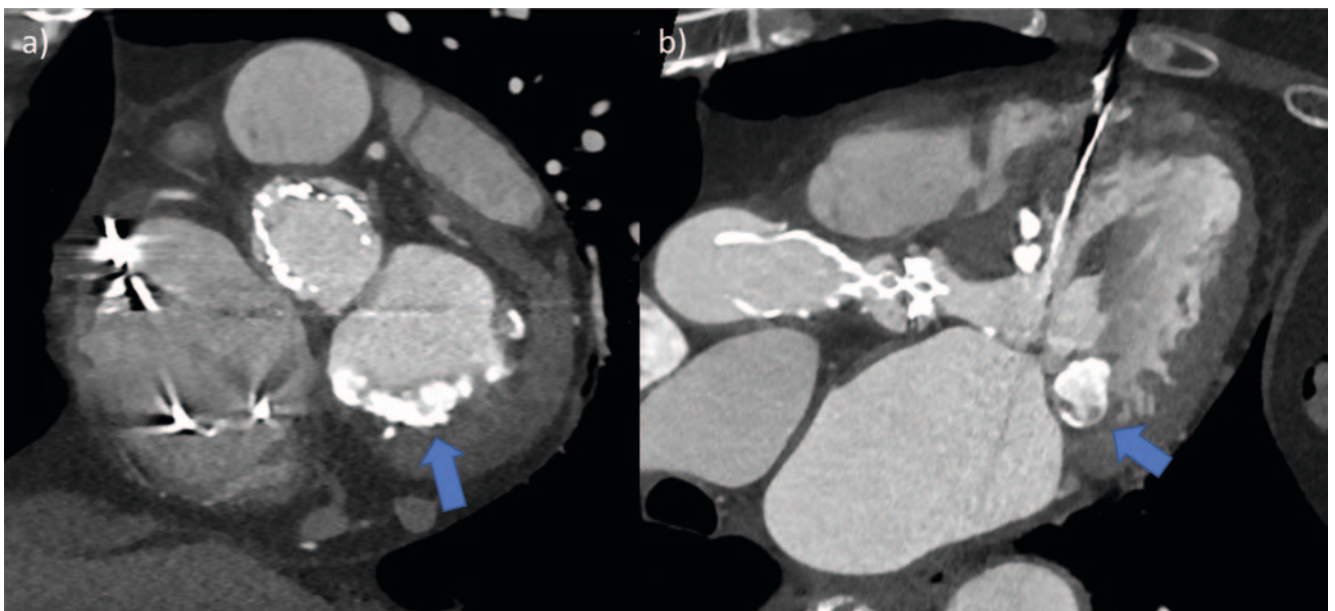
In extension of the annulus apex line, the corresponding intercostal space should be indicated where it intersects the thoracic wall (► **Fig. 4b**). This may be helpful in planning the exact transapical access route. A 3D reconstruction is particularly suitable for illustration (► **Fig. 4c**).

Report and Documentation

Due to the complexity of the evaluation, the use of a standardized report template and uniform image documentation is recommended to increase clarity and comprehensiveness of the report.



► **Fig. 7** Left ventricular outflow tract before and after TMVR and aortomitral angulation. CT-plains in 3-chamber (a, c, d) and short axis view (a, d) before (a, d) and after TMVR (b, c). a Native LVOT (blue hatched area) and well visible AML and PML. b, c The native LVOT (blue hatched area) remains unchanged in the distal part even after TMVR. However, after TMVR the outflow tract anatomy changes and the lateral contour of the neo-LVOT (red bordered area in b and red hatched area in c) is deformed by the valve prosthesis and significantly narrowed compared to the native LVOT. d The aortomitral angulation results from the intersection of the orthogonal to the center of the aortic valve plane (green arrow) and the mitral valve plane (blue arrow). In this example, the measured angle is 49°.



► **Fig. 8** Extensive calcifications of the mitral valve annulus. The short-axis view and the three-chamber view show pronounced calcifications of the mitral valve annulus (blue arrows). These are most prominent along the segments P2 and P3. In this case, the specific configuration of the annular calcification are consistent with “caseating calcification” (blue arrow in b).

On the one hand, MPRs in short-axis view and in 2- and 3-chamber view should be prepared for general overview. On the other hand, moving image series over the cardiac cycle along the mitral valve annulus and in 2-chamber and 3-chamber view should also be obtained to visualize the dynamic and anatomical changes within the cardiac cycle.

It is recommended that measurement of the mitral valve annulus should be performed using the standardized mitral valve plane setting in “D-Shape”, as described previously.. An overview of relevant measured values can be found in List 1; these should also be documented as image findings.

LIST 1: RELEVANT PARAMETERS FOR STANDARDIZED REPORTING OF TMVR-PLANNING-CT

Mitral annulus (diastolic and systolic measurements)

- TT, AP, LM
- perimeter and area
- leaflet morphology

Additional parameters

LVOT (diastolic and systolic measurements)

- minimal/maximal diameter
- perimeter and Area
- aortomitral angulation
- enddiastolic septum thickness
- minimal LV-diameter

Landing zone

- presence, distribution and quantity of mitral annulus calcifications
- “myocardial shelf”

Access route

- transapical: annulus-apex distance, ICS for optimal trajectory
- transfemoral-transseptal: course of Vv. femorales, Vv. Iliacales and V. cava inferior

Other aspects

Coronary arteries

- In case of diagnostic depicted coronary arteries: Rule-out of obstructive CAD possible?
- (If desired Calcium-Score)

Thorax/abdomen

- Other pathological findings in the scanned volume?

(TMVR = transcatheter mitral valve replacement, TT = inter-trigonal distance, AP = anterior-posterior diameter, LM = lateral-medial diameter, ICS = intercostal space, LV = left ventricle, LVOT = left ventricular outflow tract, CAD = coronary artery disease).

Summary

CT represents the central imaging modality for TMVR planning. With this imaging modality, both a visualization of the anatomical conditions and an individual and patient-centered interventional planning and prosthesis selection are reliably possible.

The mitral valve annulus should be set in a D-shape configuration and using definite anatomical landmarks for reproducibility of two-dimensional sizing. Calcifications of the annulus can be estimated very well using computed tomography and can be easily described with regard to location and distribution.

Furthermore, CT allows detailed visualization of the size and configuration of the LVOT and thus allows estimation of the likelihood of postinterventional LVOT obstruction.

Appropriate visualization capabilities are available for both a transapical and a transfemoral-transseptal approach, allowing planning of the optimal interventional procedure.

The collected measured values and qualitative statements on intervention planning should be recorded in a standardized report.

Conflict of Interest

The authors declare that they have no conflict of interest.

References

- [1] Nkomo VT et al. Burden of valvular heart diseases: a population-based study. *Lancet* 2006; 368: 1005–1011
- [2] Nishimura RA, Bonow RO. Percutaneous Repair of Secondary Mitral Regurgitation – A Tale of Two Trials. *N Engl J Med* 2018; 379: 2374–2376
- [3] Levine RA et al. Mitral valve disease – morphology and mechanisms. *Nat Rev Cardiol* 2015; 12: 689–710
- [4] Delgado V et al. Assessment of mitral valve anatomy and geometry with multislice computed tomography. *JACC Cardiovasc Imaging* 2009; 2: 556–565
- [5] Baumgartner H et al. 2017 ESC/EACTS Guidelines for the Management of Valvular Heart Disease. *Rev Esp Cardiol (Engl Ed)* 2018; 71: 110
- [6] Noack T et al. Transcatheter mitral valve repair: review of current techniques. *Indian J Thorac Cardiovasc Surg* 2020; 36 (Suppl. 1): 53–63
- [7] Yoon SH et al. Transcatheter Mitral Valve Replacement for Degenerated Bioprosthetic Valves and Failed Annuloplasty Rings. *J Am Coll Cardiol* 2017; 70: 1121–1131
- [8] Binder RK, Webb JG. Percutaneous mitral and aortic paravalvular leak repair: indications, current application, and future directions. *Curr Cardiol Rep* 2013; 15: 342
- [9] Garbi M, Monaghan MJ. Quantitative mitral valve anatomy and pathology. *Echo Res Pract* 2015; 2: R63–R72
- [10] Ranganath P et al. CT for Pre- and Postprocedural Evaluation of Transcatheter Mitral Valve Replacement. *Radiographics* 2020; 40: 1528–1553
- [11] Blanke P et al. A simplified D-shaped model of the mitral annulus to facilitate CT-based sizing before transcatheter mitral valve implantation. *J Cardiovasc Comput Tomogr* 2014; 8: 459–467
- [12] Blanke P et al. Multimodality Imaging in the Context of Transcatheter Mitral Valve Replacement: Establishing Consensus Among Modalities and Disciplines. *JACC Cardiovasc Imaging* 2015; 8: 1191–1208
- [13] Asgar AW. Sizing the Mitral Annulus: Is CT the Future? *JACC Cardiovasc Imaging* 2016; 9: 281–282
- [14] Noack T et al. Dynamic mitral valve geometry in patients with primary and secondary mitral regurgitation: implications for mitral valve repair-dagger. *Eur J Cardiothorac Surg* 2019; 56: 983–992
- [15] Muller DWM et al. Transcatheter Mitral Valve Replacement for Patients With Symptomatic Mitral Regurgitation: A Global Feasibility Trial. *J Am Coll Cardiol* 2017; 69: 381–391
- [16] Bapat V et al. Early Experience With New Transcatheter Mitral Valve Replacement. *J Am Coll Cardiol* 2018; 71: 12–21
- [17] Guerrero M et al. 1-Year Outcomes of Transcatheter Mitral Valve Replacement in Patients With Severe Mitral Annular Calcification. *J Am Coll Cardiol* 2018; 71: 1841–1853

- [18] Cheung A. Early experience of TIARA transcatheter mitral valve replacement system. *Ann Cardiothorac Surg* 2018; 7: 787–791
- [19] Guerrero M et al. Thirty-Day Outcomes of Transcatheter Mitral Valve Replacement for Degenerated Mitral Bioprostheses (Valve-in-Valve), Failed Surgical Rings (Valve-in-Ring), and Native Valve With Severe Mitral Annular Calcification (Valve-in-Mitral Annular Calcification) in the United States: Data From the Society of Thoracic Surgeons/American College of Cardiology/Transcatheter Valve Therapy Registry. *Circ Cardiovasc Interv* 2020; 13: e008425
- [20] Vahanian A, Urena M, Himbert D. Transcatheter Mitral Valve Replacement: The End of the Beginning? *J Am Coll Cardiol* 2019; 73: 1261–1263
- [21] Sondergaard L et al. Transcatheter mitral valve implantation via transapical approach: an early experience. *Eur J Cardiothorac Surg* 2015; 48: 873–877; discussion 877–878
- [22] Cheung A et al. Short-term results of transapical transcatheter mitral valve implantation for mitral regurgitation. *J Am Coll Cardiol* 2014; 64: 1814–1819
- [23] Regueiro A et al. Transcatheter Mitral Valve Replacement: Insights From Early Clinical Experience and Future Challenges. *J Am Coll Cardiol* 2017; 69: 2175–2192
- [24] Urena M et al. Transseptal Transcatheter Mitral Valve Replacement Using Balloon-Expandable Transcatheter Heart Valves: A Step-by-Step Approach. *JACC Cardiovasc Interv* 2017; 10: 1905–1919
- [25] Del Val D et al. Early Experience With Transcatheter Mitral Valve Replacement: A Systematic Review. *J Am Heart Assoc* 2019; 8: e013332
- [26] Leschka S et al. Scan length adjustment of CT coronary angiography using the calcium scoring scan: effect on radiation dose. *Am J Roentgenol* 2010; 194: W272–W277
- [27] Gohmann RF et al. Combined Coronary CT-Angiography and TAVI-Planning: A Contrast-Neutral Routine Approach for Ruling-out Significant Coronary Artery Disease. *J Clin Med* 2020; 9: 1623
- [28] Seitz P, Gottschling S, Lücke C et al. Pre-procedural high-pitch coronary CT angiography assessment of patients undergoing transcatheter aortic valve implantation (TAVI) without patient-specific adjustment: analysis of diagnostic performance. *Clinical Radiology* 2021; 76: 862.e29–862.e36
- [29] Blanke P et al. Mitral Annular Evaluation With CT in the Context of Transcatheter Mitral Valve Replacement. *JACC Cardiovasc Imaging* 2015; 8: 612–615
- [30] Reid A et al. Neo-LVOT and Transcatheter Mitral Valve Replacement: Expert Recommendations. *JACC Cardiovasc Imaging* 2021; 14: 854–866
- [31] Blanke P et al. Predicting LVOT Obstruction in Transcatheter Mitral Valve Implantation: Concept of the Neo-LVOT. *JACC Cardiovasc Imaging* 2017; 10: 482–485
- [32] Naoum C et al. Mitral Annular Dimensions and Geometry in Patients With Functional Mitral Regurgitation and Mitral Valve Prolapse: Implications for Transcatheter Mitral Valve Implantation. *JACC Cardiovasc Imaging* 2016; 9: 269–280
- [33] Faggioni L et al. Preprocedural planning of transcatheter mitral valve interventions by multidetector CT: What the radiologist needs to know. *Eur J Radiol Open* 2018; 5: 131–140
- [34] Korn D, Desanctis RW, Sell S. Massive calcification of the mitral annulus. A clinicopathological study of fourteen cases. *N Engl J Med* 1962; 267: 900–909
- [35] Abramowitz Y et al. Concomitant mitral annular calcification and severe aortic stenosis: prevalence, characteristics and outcome following transcatheter aortic valve replacement. *Eur Heart J* 2017; 38: 1194–1203
- [36] Guerrero M et al. A Cardiac Computed Tomography-Based Score to Categorize Mitral Annular Calcification Severity and Predict Valve Embolization. *JACC Cardiovasc Imaging* 2020; 13: 1945–1957
- [37] Capoulade R et al. Multimodality imaging assessment of mitral valve anatomy in planning for mitral valve repair in secondary mitral regurgitation. *J Thorac Dis* 2017; 9 (Suppl. 7): S640–S660

CORRECTION

CT Planning prior to Transcatheter Mitral Valve Replacement (TMVR)

Heiser L, Gohmann RF, Noack T et al. CT Planning prior to Transcatheter Mitral Valve Replacement (TMVR). *Fortschr Röntgenstr* 2022; 194: 373–383

Correction on page 374, 375. The correct sentence is: This saddle-shaped annulus has its highest point in the middle of the anterior third and extends to the level of the aortic valve, more specifically to the insertion of the left coronary and the **acoronary** cusp.