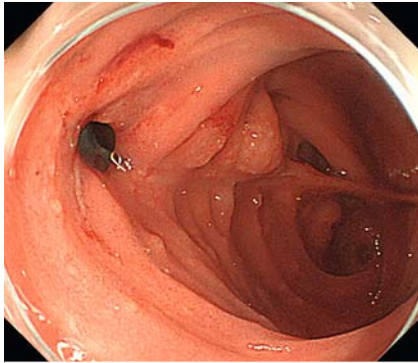
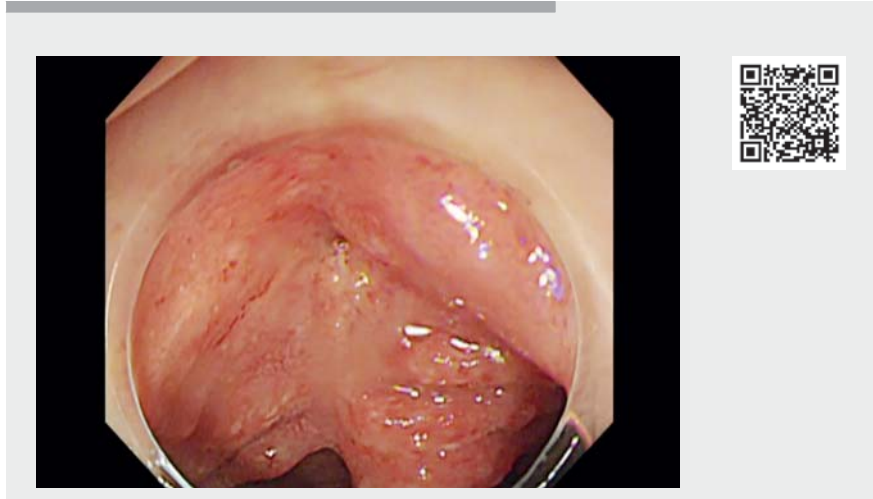

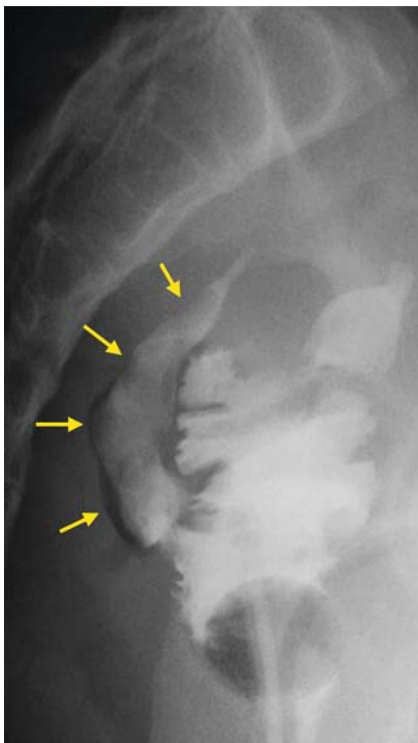
## Endoscopic sinusotomy using the small-ceramic-tip-insulated electrosurgical knife for chronic pouch sinus after ileal pouch anal anastomosis in ulcerative colitis: a case report



► **Fig. 1** The orifice of the presacral sinus at the suture line of the ileal pouch was observed.



► **Video 1** Endoscopic sinusotomy using ITknife nano.



► **Fig. 2** A presacral sinus opening to the ileal pouch was observed by amidotrizoic acid enema.

A 23-year-old man with a history of total colectomy and ileal pouch anal anastomosis for ulcerative colitis had a presacral sinus opening along the suture line of the ileal pouch after surgery that had been performed 2 years previously (► **Fig. 1**, ► **Fig. 2**). Computed tomography-guided drainage, endoscopic sinus clipping closure, and transanal sinusotomy were performed; however, repeated amidotrizoic acid enema indicated a persistent presacral pouch sinus. Consequently, endoscopic sinusotomy was performed to unify the sinus and the ileal pouch (► **Video 1**).

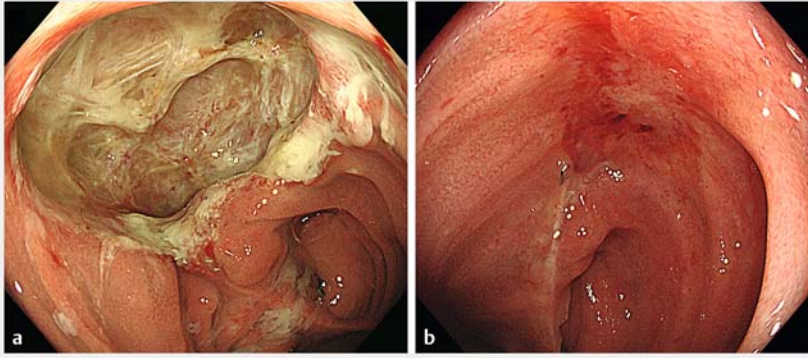
The orifice of the sinus was initially incised using a needle knife (Olympus, Tokyo, Japan) and was subsequently widened using an ITknife nano (Olympus), with an insulated ball tip; this prevents blinded tissue injuries behind the septum. A transendoscopic amidotrizoic acid enema was administered again to confirm the direction of the sinus. After

unifying the sinus and the ileal pouch, the surrounding mucosa was removed by snare resection, and triamcinolone was injected into the sinus wall to maintain its integrity, as its early closure could have led to a recurrence. A follow-up endoscopy 3 weeks later revealed ulceration of the unified sinus wall, which gradually epithelialized within 9 months (► **Fig. 3**). Endoscopic sinusotomy is a safe and effective approach, and is associated with fewer adverse events when compared with surgical therapies [1]. The ITknife nano can prevent blinded tissue injuries and helps widen the sinus effectively.

Endoscopy\_UCTN\_Code\_TTT\_1AQ\_2AF


### Competing interests

The authors declare that they have no conflict of interest.



► **Fig. 3** **a** The ulceration of the unified sinus wall was observed 3 weeks later. **b** The sinus was almost epithelialized within 9 months.

### The authors

Hidenori Tanaka<sup>1</sup>, Shiro Oka<sup>2</sup>, Ken Yamashita<sup>1</sup>, Ryohei Hayashi<sup>1</sup>, Yusuke Watadani<sup>3</sup>, Hiroki Ohge<sup>3</sup>, Shinji Tanaka<sup>1</sup> 

- 1 Department of Endoscopy, Hiroshima University Hospital, Hiroshima, Japan
- 2 Department of Gastroenterology and Metabolism, Hiroshima University Hospital, Hiroshima, Japan
- 3 Department of Surgery, Hiroshima University Hospital, Hiroshima, Japan

### Corresponding author

**Shiro Oka, MD**

Department of Gastroenterology and Metabolism, Hiroshima University Hospital, 1-2-3, Kasumi, Minamiku, Hiroshima 734-8551, Japan  
 Fax: +81-82-257-5939  
 oka4683@hiroshima-u.ac.jp

### Reference

- [1] Lan N, Hull TL, Shen B. Endoscopic sinusotomy versus redo surgery for the treatment of chronic pouch anastomotic sinus in ulcerative colitis patients. *Gastrointest Endosc* 2019; 89: 144–156

### Bibliography

*Endoscopy* 2022; 54: E728–E729  
**DOI** 10.1055/a-1769-4612  
**ISSN** 0013-726X  
**published online** 10.3.2022  
 © 2022. Thieme. All rights reserved.  
 Georg Thieme Verlag KG, Rüdigerstraße 14, 70469 Stuttgart, Germany

### ENDOSCOPY E-VIDEOS

<https://eref.thieme.de/e-videos>



*Endoscopy E-Videos* is an open access online section, reporting on interesting cases and new techniques in gastroenterological endoscopy. All papers include a high quality video and all contributions are freely accessible online. Processing charges apply (currently EUR 375), discounts and waivers acc. to HINARI are available.

This section has its own submission website at <https://mc.manuscriptcentral.com/e-videos>