

DWI of the Breast – Possibilities and Limitations

Diffusionsbildgebung der Mamma – Möglichkeiten und Limitationen der DWI

Authors

Hans Jonas Meyer , Mireille Martin, Timm Denecke

Affiliation

Diagnostic and Interventional Radiology, University of Leipzig
Faculty of Medicine, Leipzig, Germany

Key words

DWI, breast cancer, ADC

received 12.03.2021

accepted 25.01.2022

published online 19.04.2022

Bibliography

Fortschr Röntgenstr 2022; 194: 966–973

DOI 10.1055/a-1775-8572

ISSN 1438-9029

© 2022. Thieme. All rights reserved.

Georg Thieme Verlag KG, Rüdigerstraße 14,
70469 Stuttgart, Germany

Correspondence

Hans Jonas Meyer

Diagnostische und Interventionelle Radiologie, Universität
Leipzig Medizinische Fakultät, Liebigstraße 20, 04103 Leipzig,
Germany

Tel.: +49/3 45/5 57 24 46

hans-jonas.meyer@medizin.uni-leipzig.de

ABSTRACT

Background The MRI of the breast is of great importance in the diagnosis of disorders of the breast. This can be stated for the primary diagnosis as well as the follow up. Of special interest is diffusion weighted imaging (DWI), which has an increasingly important role. The present review provides results regarding the diagnostic and prognostic relevance of DWI for disorders of the breast.

Methods Under consideration of the recently published literature, the clinical value of DWI of the breast is discussed. Several diagnostic applications are shown, especially for the primary diagnosis of unclear tumors of the breast, the prediction of the axillary lymph node status and the possibility of a native screening. Moreover, correlations between DWI and histopathology features and treatment prediction with DWI are provided.

Results Many studies have shown the diagnostic value of DWI for the primary diagnosis of intramammary lesions. Benign lesions of the breast have significantly higher apparent

diffusion coefficients (ADC values) compared to malignant tumors. This can be clinically used to reduce unnecessary biopsies in clinical routine. However, there are inconclusive results for the prediction of the histological subtype of the breast cancer. DWI can aid in the prediction of treatment to neoadjuvant chemotherapy.

Conclusion DWI is a very promising imaging modality, which should be included in the standard protocol of the MRI of the breast. DWI can provide clinically value in the diagnosis as well as for prognosis in breast cancer.

Key Points:

- DWI can aid in the discrimination between benign and malignant tumors of the breast and therefore avoiding unnecessary biopsies.
- The ADC value cannot discriminate between immunohistochemical subtypes of the breast cancer
- The ADC value of breast cancer increases under neoadjuvant chemotherapy and can by this aid in treatment prediction.
- There is definite need of standardisation for clinical translation

Citation Format

- Meyer HJ, Martin M, Denecke T. DWI of the Breast – Possibilities and Limitations. Fortschr Röntgenstr 2022; 194: 966–973

ZUSAMMENFASSUNG

Hintergrund Die MRT-Untersuchung der Mamma ist von zentraler Bedeutung in der Diagnostik der Erkrankungen der Mamma. Dies gilt sowohl für die Primärdiagnostik als auch die Verlaufsbeurteilung. Obwohl dabei die frühe Kontrastmittelanreicherung derzeit die wichtigste diagnostische Sequenz darstellt, erlangt vor allem die Diffusionswichtung (DWI) eine zunehmende Bedeutung in der Bildgebung, nicht zuletzt aufgrund ihrer Unabhängigkeit von einer Kontrastmittelgabe. Die vorliegende Übersichtsarbeit stellt die diagnostische und prognostische Relevanz der DWI bei Erkrankungen der Mamma vor.

Methoden Unter Berücksichtigung der veröffentlichten Literatur stellt dieser Übersichtsartikel den möglichen klinisch relevanten Nutzen der DWI der Mamma dar. Es werden verschiedene diagnostische Anwendungen erläutert, insbesondere zur Primärdiagnostik von unklaren Raumforderungen der Mamma, und der Möglichkeit eines nativen Screenings.

Weiterhin werden Korrelationen mit histopathologischen Eigenschaften und die Vorhersage des Therapieansprechens der neoadjuvanten Chemotherapie diskutiert.

Ergebnisse Viele Studien zeigten den diagnostischen Wert der DWI in der primären Dignitätseinschätzung von intramammären Herdbefunden. Benigne Läsionen der Mamma weisen signifikant höhere „Apparent diffusion coefficients“ (ADC-Werte) auf als maligne Tumoren. Dies kann klinisch genutzt werden, um unnötige Biopsien zu reduzieren. Zur Differenzierung der Subtypen des Mammakarzinoms wurden hingegen inkonklusive Ergebnisse veröffentlicht, sodass die DWI nicht sicher den immunhistochemischen Subtyp vorher-

sagen kann. Die DWI kann jedoch helfen, durch ein Ansteigen des ADC-Werts das Ansprechen der neoadjuvanten Chemotherapie vorherzusagen.

Schlussfolgerung Die DWI ist eine vielversprechende Untersuchungstechnik, die zum Standardprotokoll der Mamma-MRT gehören sollte. Sie kann vor allem bei der Diagnosestellung klinisch relevante Zusatzinformationen liefern. Bezüglich der prognostischen Relevanz, der Vorhersage von Subtypen oder dem Proliferationsindex gibt es jedoch keine Evidenz für einen Zusatznutzen. Die Technik benötigt vor allem noch vermehrte Standardisierung, um den ADC-Wert als klinischen Biomarker reliabel verwenden zu können.

Introduction

Next to mammography and ultrasound, magnetic resonance imaging (MRI) of the breast is the imaging method of choice for diagnosing diseases of the breast [1, 2]. A multiparametric protocol is used with T2-weighted sequences, T1-weighted dynamic contrast-enhanced sequences, and diffusion-weighted imaging (DWI), which is increasingly being performed also in the clinical routine [2, 3].

DWI is based on the Brownian motion of water molecules and can be quantified with the apparent diffusion coefficient (ADC) value [3, 4]. This can reflect the microstructure of tissues [4, 5]. The rationale for this is that the motion of protons is primarily limited by cells and cell membranes. Therefore, tissue with higher cellularity limit the diffusion more greatly than tissue with lower cellularity [5, 6]. Furthermore, tumors with a larger nuclear size seem to have lower ADC values [6]. This was seen in a number of preclinical and clinical studies including multiple tumor entities and regions of the body [5]. Smaller studies were able to show that ADC values correlate with the cellularity and the tumor stroma of breast tumors, e. g., fibroadenomas [7], various types of breast cancer [8, 9], and mucinous breast carcinoma [10], so that these properties of DWI also apply for tumors of the breast.

As a result, DWI has already been included in the clinical MRI protocol at many centers. However, it must be noted that DWI has not yet been included in the official BI-RADS criteria [3] and therefore cannot yet be used for the BI-RADS classification of MRI findings.

It should be mentioned the DWI does not require contrast agent for acquisition. Thus, primarily with the help of DWI, a non-contrast breast MRI protocol could be established in the future.

DWI should be performed on an MRI scanner with a Tesla strength of 1.5 T or higher using a dedicated breast coil. As a rule, DWI should be acquired prior to the administration of contrast agent since some studies have reported an effect of contrast agent on ADC values. Fat saturation is needed and should be performed using the spectral fat saturation technique (SPAIR technique). The single-shot echo planar imaging (EPI) sequence as used in most studies serves as the basis of DWI. Multi-shot echo planar imaging can be used to reduce possible susceptibility arti-

facts and thus to achieve better image quality. A recently published consensus statement provides an overview of the individual features of the DWI technique in breast MRI [3].

Multiple different DWI techniques are used. The sequence of the clinical routine is based on two different DWI sequences with varying b-values [3, 4]. A b-value of 0 to 50 s/mm² is recommended as the low b-value and 800 s/mm² as the high b-value [3]. The ADC map is then calculated from these sequences with linear fitting.

There has recently been increased research interest in modern DWI methods. The intravoxel-incoherent motion imaging method (IVIM), which is based on multiple low b-values, is of particular interest. Tissue perfusion can be reflected by this IVIM method. Therefore, this technique can determine the perfusion fraction (f) [11]. This value should correlate, for example, with the perfusion from the contrast-enhanced perfusion weighting and even be associated with the vascular density of tumors [11, 12].

A further method is diffusion kurtosis imaging (DKI), which is based on high b-values of greater than 1500 s/mm² and should be associated with the microstructure of the tumor [13]. The parameters kurtosis and diffusivity can be determined by this technique. However, the clinical benefit of these new parameters is still a topic of current research. All of these techniques have already been examined with respect to breast MRI [14, 15].

The European Society of Breast Imaging (EUSOBI) provided a comprehensive list of the various imaging biomarkers of breast imaging and classified them according to evidence class. The ADC value of DWI is classified as evidence class I.

The goal of this article is to discuss the clinical benefits and limitations of diffusion weighting in breast MRI with respect to diagnostic and prognostic possibilities.

Primary diagnosis of breast lesions via DWI

Most studies on DWI examine the diagnostic possibilities of DWI with regard to determining the status of lesions and tumors of the breast [16] (► Fig. 1, 2). The level of evidence is highest for the use of DWI to determine the status of breast lesions. This application can be considered the most clinically relevant use for DWI [16–21].

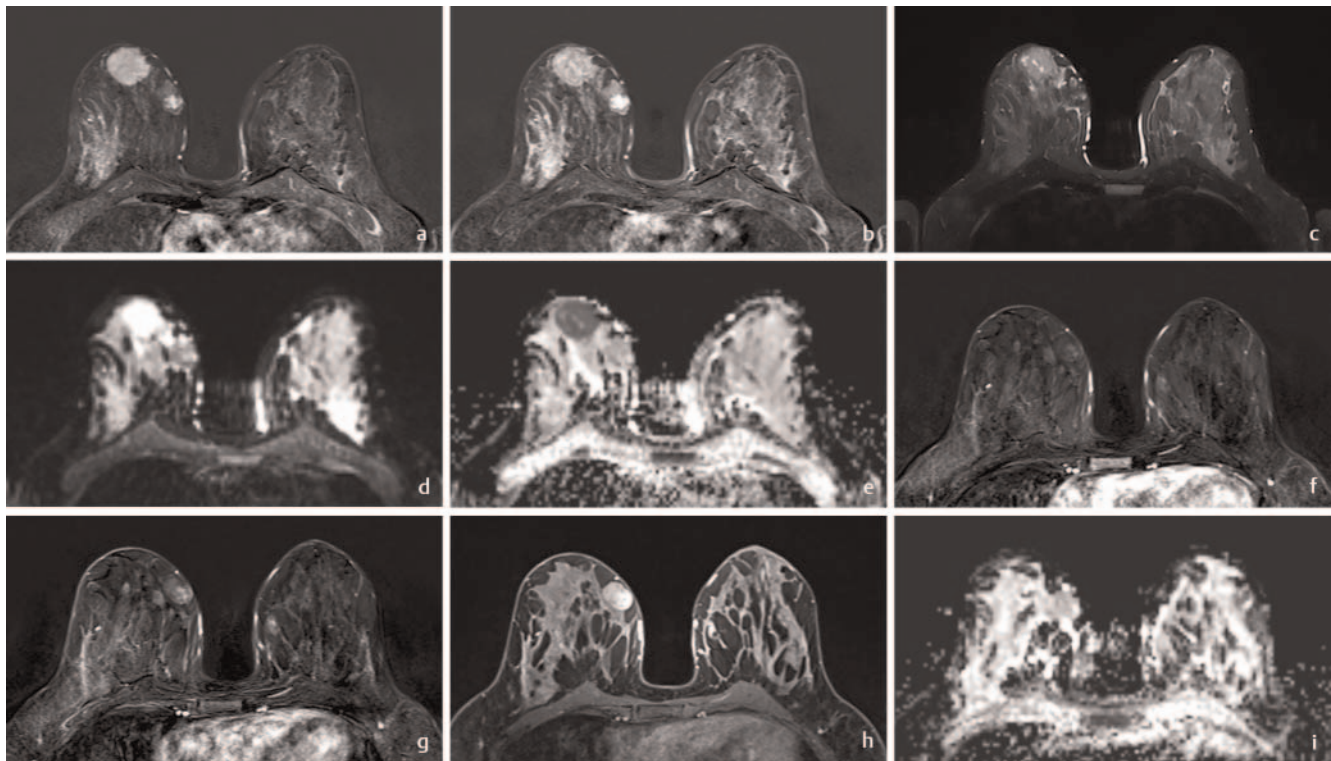


Fig. 1 **a** Early subtraction after contrast media application. Parenchyma contrast enhancement consistent with MRM density III. Visualization of a large suspicious mass on the right side located in the lower quadrants (BI-RADS 5). Medial from there is another smaller suspicious mass (BI-RADS 5). **b** Last subtraction of the contrast media dynamics. Both masses show partial contrast media uptake. **c** T2-sequence with TIRM-technique. The larger mass has small cystic areas centrally. **d** Corresponding DWI (b-value of 800 s/mm²). The larger mass has a hyperintense signal intensity consistent with a diffusion restriction, the smaller one is isointense. **e** The resulting ADC map shows that the larger mass has a low ADC value of 0.8×10^{-3} mm²/s, while the smaller has a value of 1.5×10^{-3} mm²/s. Both masses were histologically proven. The larger one was invasive ductal breast cancer, and the smaller one was a fibroadenoma. **f** Early subtraction after contrast media application after neoadjuvant chemotherapy. Both masses are decreasing in size after therapy in this contrast media phase. The histopathologically proven breast carcinoma is no longer detectable. **g** Last subtraction of the contrast media dynamics. The fibroadenoma shows delayed contrast media uptake consistent with a benign tumor. **h** T1-weighted sequence after contrast media application with fat saturation. **i** No residual tumor of the breast carcinoma can be seen on the ADC maps. The ADC value of the fibroadenoma remains unchanged (1.5×10^{-3} mm²/s).

Therefore, initial studies already showed that the combination of DWI and dynamic contrast-enhanced MRI (DCE-MRI) has a higher specificity than DCE-MRI alone [17, 18].

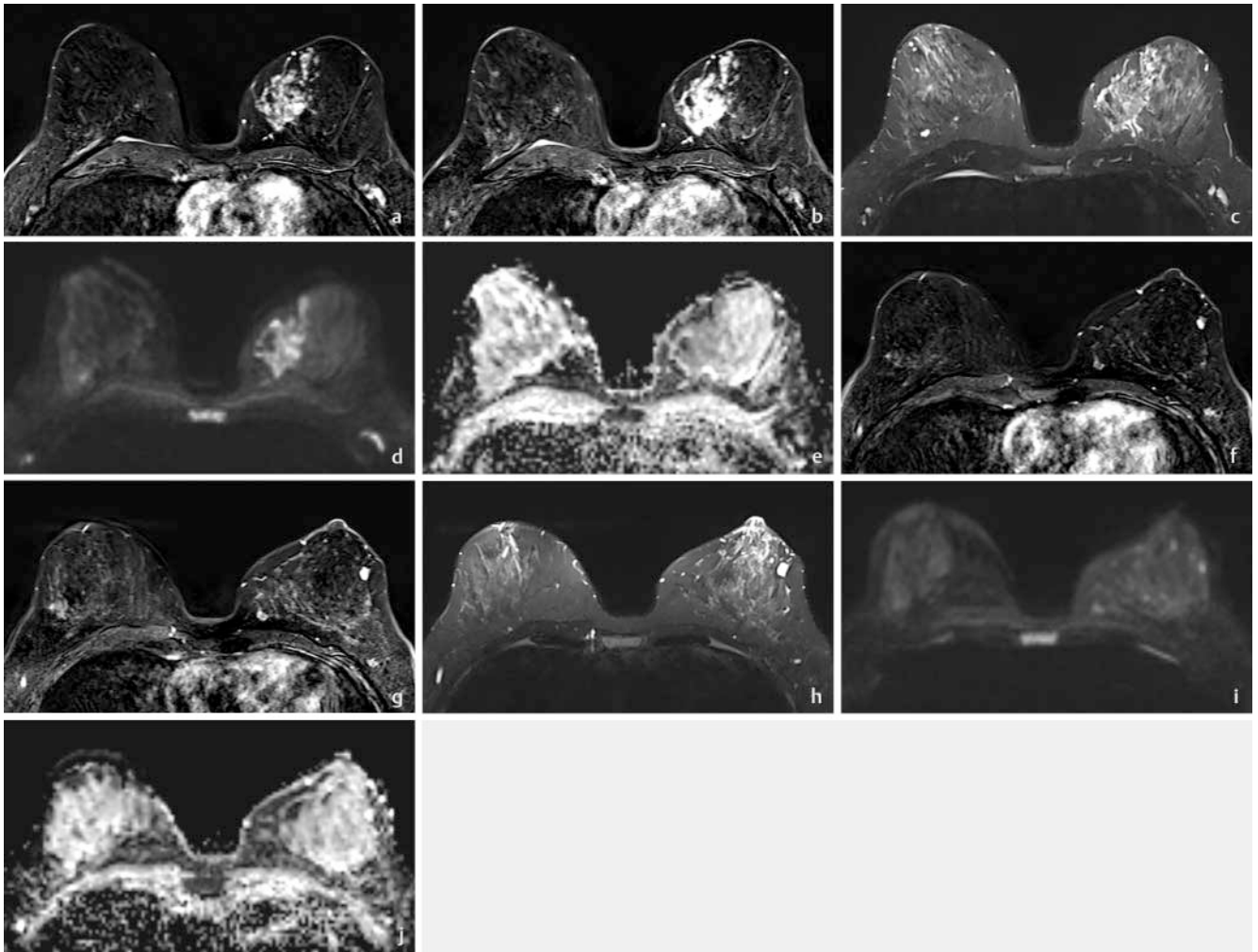
DWI is capable of differentiating malignant from benign breast lesions. A recently published meta-analysis examined the extent to which ADC values differ between benign and malignant lesions based on 123 studies including 13 847 breast lesions [19]. The mean ADC value was 1.03×10^{-3} mm²/s for malignant tumors and 1.5×10^{-3} mm²/s for benign lesions. A cutoff value of 1.0×10^{-3} mm²/s was recommended since no benign lesions were identified below this value [19]. It is notable that the results in these studies were largely independent of Tesla strength (1.5 T compared to 3 T), the b-values that were used (600–650, 750–850, and 1000 s/mm²), and the region of interest (ROI) measurement (single slice measurement compared to measurement of the entire tumor) [19].

However, mucinous breast carcinoma, which can have very high ADC values (up to approximately 1.5×10^{-3} mm²/s) and can therefore be confused with benign lesions in DWI, must be mentioned as a limitation [10].

A recently published prospective multicenter study shows that an ADC cutoff value of 1.53×10^{-3} mm²/s can lower the biopsy rate by 20.9% without reducing sensitivity [20]. 67 patients with 81 lesions were examined in this study. It is noteworthy that the diagnostic accuracy for non-mass lesions was slightly lower than for masses (0.72 compared to 0.79) [20]. Another multicenter study including 657 patients also showed that DWI is capable of further categorizing lesions characterized as BI-RADS 4 on contrast-enhanced MRI [21]. Using an ADC cutoff of 1.5×10^{-3} mm²/s allowed the noninvasive downgrading of lesions thereby lowering the rate of unnecessary biopsies by 32.6%.

There is currently no consensus regarding ROI measurement criteria. Some approaches measure the entire tumor, while other approaches measure a mean ADC value on only one slice. A multicenter study showed that the mean ADC value measured on one slice could be sufficient and has a similar diagnostic quality to more complex measurement methods [22].

In summary, DWI and ADC value can help to better assess the status of lesions and even to decrease the need for biopsy. For the clinical routine, it is recommended to measure the ADC value on a representative slice and to include this information in the report.



► **Fig. 2** **a** Early subtraction after contrast media application. Some small foci located in the right breast. Visualization of a mass in the left breast located in the left upper medial quadrant (BI-RADS 5). **b** Last subtraction of the contrast media dynamics. The rim of the mass shows progressive contrast media uptake. **c** T2-weighted sequence with TIRM technique. An intermediate T2-hyperintense signal can be seen. **d** DWI (b-value of 800 s/mm^2) shows diffusion restriction with a correspondingly lowered ADC value ($0.9 \times 10^{-3} \text{ mm}^2/\text{s}$) of the ADC map **e**. **f** Early subtraction of the contrast media dynamics. One axial slide at the mammillary level shows another smaller mass on the left side. Planned breast-conserving therapy can only be performed with only one quadrant involved. **g** Last subtraction of the contrast media dynamics. Progressive contrast media uptake can be seen. **h** T2-weighted sequence in TIRM technique. The mass has a T2-hyperintense signal. **i** The corresponding DWI shows only moderate hyperintense signal intensity, consistent with a T2 shine-through effect. The corresponding ADC map shows high ADC values (ADC value of $1.6 \times 10^{-3} \text{ mm}^2/\text{s}$) consistent with a benign tumor. The smaller mass was a histologically proven fibroadenoma, and the bigger mass was an invasive ductal breast cancer.

Added clinical benefit of DWI

The relevant added clinical benefit of DWI compared to established imaging methods should be noted to highlight the necessity of the sequence in routine diagnostics. A very interesting multicenter study including 414 patients evaluated the use of ADC value alone, the Kaiser Score, the combination of the two [23]. The Kaiser Score yielded better diagnostic accuracy particularly in subcentimeter lesions. In the collective as a whole, the ADC value had comparable sensitivity to the Kaiser Score with respect to preventing unnecessary biopsies. Interestingly, the Kaiser Score alone was superior to the combination of Kaiser Score and ADC for preventing unnecessary biopsies.

In an earlier study, the quantitative ADC value with a cutoff of $1.0 \times 10^{-3} \text{ mm}^2/\text{s}$ (suspicious for malignancy) or $1.4 \times 10^{-3} \text{ mm}^2/\text{s}$ (intermediate) was used as an additional diagnostic method for contrast-enhanced BI-RADS evaluation [24]. A higher specificity could be achieved by including the ADC value [24].

Based on this data, it can be concluded that DWI with the ADC value can help to increase the specificity of BI-RADS reporting by including an additional parameter. However, if a lesion has already been classified based on the Kaiser Score, which combines different parametric findings of contrast-enhanced MRI, the ADC value is no longer beneficial and cannot further increase the specificity. Finally, the implementation of the Kaiser Score in the daily routine is simpler and more time-efficient than use of ADC values.

DWI as a prognostic marker

Various studies have evaluated the extent to which DWI and ADC value can predict disease course in breast cancer patients [16]. In most studies, ADC value was associated with already established prognostic parameters, like immunohistochemical markers [16].

The study by Kim et al., which directly correlated the ADC value with metastasis-free survival, should be mentioned as an important study [25]. A specially calculated ADC difference value based on 258 patients was used in this study [25]. Interestingly, this ADC value as an independent prognostic factor with a hazard ratio of 4.5 in the multivariate analysis was of even greater prognostic relevance than the presence of axillary lymph node metastases with a hazard ratio of 3.3. This study thus indicated that the ADC value could be more important than one of the most important clinically established prognostic factors.

However, it must be stated that the quality of these studies is low and large multicenter analyses are needed to show the prognostic relevance of the ADC value.

Correlation with the proliferation index Ki-67

Various studies have attempted to identify a correlation between the ADC value and the proliferation index Ki-67 [26]. For the Ki-67 index only the number of cells in mitosis per 100 cells are measured [27]. This is an established prognostic biomarker for breast cancer [27].

A first meta-analysis examining all oncological studies on the correlation of ADC values with the Ki-67 index yielded a mean correlation coefficient of $r = -0.44$, (95% CI = [-0.51; -0.37]) [26]. However, for the breast cancer subgroup analysis, no statistical significance was found ($r = -0.22$ (95% CI = [-0.50; 0.06]) [26].

In multiple smaller studies, a significant moderate correlation between the ADC value and the Ki-67 index was identified [28, 29]. In contrast, in other studies, no reliable correlation between ADC value and Ki-67 was found [30, 31].

This was confirmed by a recently published multicenter study based on data from 870 patients from six centers. Only a weak correlation was identified ($r = -0.20$) [32]. This also resulted in low AUC values for the differentiation between low and high Ki-67 expression for multiple clinical Ki-67 cutoffs (Ki-67 value of 10% to 50%, AUC values of 0.64 to 0.58) [32].

Available studies tend to indicate that ADC value cannot be used to make a reliable conclusion about the Ki-67 index.

DWI for discriminating between immunohistochemical subtypes

Numerous studies have attempted to establish significant differences in ADC value between the various immunohistochemical subtypes of breast cancer [17]. Therefore, some significant differences in ADC value as a function of hormone receptor status were identified [16]. It was also shown that estrogen or progesterone receptor-positive tumors have slightly lower ADC values than hormone receptor-negative tumors [16]. Individual studies showed

that the Her2-positive subtype has the highest ADC values while other studies showed that the triple-negative subtype has higher ADC values than other subtypes [30, 33]. However, the literature is inconclusive since a number of studies could not show any significant differences in ADC value between immunohistochemical subtypes [16].

A meta-analysis based on 28 studies including 2990 tumors examined this data and did not show any significant differences in ADC value between the different immunohistochemical subtypes [34].

It must therefore be noted that DWI is not capable of reflecting the immunohistochemical characterization of tumors.

DWI for predicting axillary lymph node status

Axillary lymph node status is one of the most important prognostic markers in breast cancer [35]. Multiple studies have examined whether the ADC value of an axillary lymph node could help to differentiate between benign and metastatic lymph nodes and whether the ADC value of the primary tumor differs significantly between node-positive and node-negative tumors [36–38].

Promising studies regarding both the ADC value of axillary lymph nodes and the ADC value of the primary tumor have been published [36–38]. Therefore, malignant axillary lymph nodes showed significantly lower ADC values than uninvolved lymph nodes.

In a meta-analysis based on 875 benign and 547 malignant lymph nodes, benign lymph nodes had a mean ADC value of $1.17 \times 10^{-3} \text{ mm}^2/\text{s}$ [95% CI 1.02–1.32], while malignant lymph nodes had a mean ADC value of $0.90 \times 10^{-3} \text{ mm}^2/\text{s}$ [95% CI 0.80–1.01] [36].

It is of particular interest that the ADC value of axillary lymph nodes seems to be independent of lymph node size and thus can indicate a possible malignancy [36]. The ADC value of axillary lymph nodes can thus be used as a potential additional imaging parameter to existing morphological characteristics [36, 38].

With regard to the primary tumor, it was also shown that node-positive tumors have a slightly lower ADC value than node-negative tumors and the diagnosis of axillary lymph node status could also be improved with this additional parameter [36].

DWI for predicting treatment response in the neoadjuvant setting

The assessment or even early prediction of treatment response is an important objective of oncological imaging [39]. DWI which can reflect tumor microstructure should be able to visualize tumor changes during chemotherapy even before morphological changes. Cytotoxic chemotherapy causes necrosis and cytolysis which should result in an increase in the ADC value.

However, the pretherapeutic ADC value in breast cancer does not seem to be able to reliably predict response to neoadjuvant chemotherapy [40]. In this regard, the role of the ADC value in the assessment of response to neoadjuvant chemotherapy was evaluated in a recently published meta-analysis based on

22 studies including 1827 patients. Significant overlapping of mean ADC values between patients responding to treatment ($0.98 \times 10^{-3} \text{ mm}^2/\text{s}$ (95 % CI = [0.94; 1.03])) and those not responding to treatment ($1.05 \times 10^{-3} \text{ mm}^2/\text{s}$ (95 % CI = [1.00; 1.10])) was seen. Therefore, the initial ADC value of the primary tumor cannot be used as a validated biomarker for treatment response [40].

One study based on 31 breast cancer patients showed similar results with no significant difference between the ADC values of the group with histopathologically complete treatment response compared to the group without treatment response [41]. However, in this study, parameters of morphological imaging were significant predictors of treatment response. Thus, patients with poor treatment response showed growth parallel to Cooper's ligaments and a fast washout rate on dynamic contrast-enhanced MRI [41].

In contrast, an increase in ADC value during neoadjuvant chemotherapy was seen in multiple studies as a potential biomarker for the differentiation between responders and non-responders [42, 43]. It was shown in a large multicenter study that an increase in ADC value after 12 weeks of neoadjuvant chemotherapy is the most promising parameter for predicting treatment response [43]. In patients with pathological complete response, there was an increase in ADC value of 50 % while an increase of only 36 % ($p = 0.017$) was seen in patients without pathological complete response [43]. However, the initial ADC value in breast cancer patients prior to chemotherapy was not significantly different between the groups ($p = 0.48$). Thus, treatment-associated increase in ADC value could be used in the future for predicting pathological response.

Noteworthy results were achieved in a study that was able to predict treatment response to neoadjuvant chemotherapy as well as disease-specific survival with an AUC of 0.86 and 0.92 using artificial intelligence based on multiparametric MRI scans performed before the start of treatment and after two cycles of neoadjuvant chemotherapy [44]. This multiparametric, AI-based approach could therefore have the greatest benefit in the clinical routine with regard to determining treatment response.

However, it must be stated that there is not yet any data regarding changes to neoadjuvant therapy based on DWI. This would be a clinically relevant added benefit.

For clinical practice, an increase in ADC value indicates treatment response and should be included as such in the report. However, further study data is needed to determine a possible cutoff value.

DWI for breast cancer screening without contrast

Since DWI does not require the administration of contrast, the use of this MRI sequence for non-contrast breast cancer screening has been discussed [45].

In direct comparison to mammography, T2-weighted DWI showed superior diagnostic significance for detecting breast cancer (AUC 0.73 for DWI compared to 0.64 for mammography) and was able to detect a greater number of tumors (sensitivity of 69 %

vs. 40 %) [46]. However, these data are based on 45 lesions in 42 women. A second study including 25 women also showed the superiority of DWI compared to mammography [47].

However, it must be noted that DWI is inferior to dynamic contrast-enhanced MRI in the screening setting (AUC of 0.93 and sensitivity of 86 %) [46].

In a prospective study including 50 screening participants with mammography findings suspicious for malignancy, non-contrast MRI including DWI was performed with an examination time of only 7 minutes. A very good negative predictive value of 0.92 was able to be achieved. Consequently, DWI was able to prevent unnecessary biopsies [48].

In a further retrospective study including 378 patients, a very good sensitivity of 93 % and specificity of 88 % were achieved by DWI alone [49]. For lesions with a size of less than 10 mm, DWI still achieved a sensitivity of 71 % so that even small lesions were able to be sufficiently detected in this study [49].

However, it must be noted that there is currently no recommendation for using DWI for screening. The variations in diagnostic accuracy between studies can be attributed to the highly heterogeneous image quality of DWI [50]. The EUSOBI is currently discussing the possibility of using DWI for supplementary screening in patients with a high/intermediate risk profile, but there is currently not yet a recommendation in this regard.

Advanced DWI techniques

Various DWI sequences have recently been studied to determine whether they can offer added benefit.

The diagnostic performance of the IVIM technique was evaluated in a recently published meta-analysis based on 16 studies including 1355 malignant and 362 benign lesions [14]. The key result of this analysis is that the IVIM parameters are diagnostically equal to the ADC.

A meta-analysis based on 13 studies including 867 malignant and 460 benign lesions was performed for the DKI method [15]. However, this study showed only an equivalent diagnostic performance of DKI parameters compared to the ADC value.

In a study including 85 patients, the ADC value was even able to outperform the DKI parameters in the discrimination between benign and malignant lesions [51].

Diffusion tensor imaging (DTI) was also evaluated with respect to breast diagnosis with similar results compared to conventional DWI [52].

Therefore, the clinical benefit of these novel sequences must first be evaluated in greater detail in studies. However, initial meta-analyses show that the benefits do not differ significantly from those of conventional DWI [53]. Due to the lack of standardization and undetermined additional clinical benefit, these cannot yet be recommended for the clinical routine.

Summary

The clinically relevant additional benefit of DWI is improved assessment of the status of lesions suspicious for malignancy. When the ADC value with a cutoff of $1.5 \times 10^{-3} \text{ mm}^2/\text{s}$ is used in

addition to contrast-enhanced MRI, up to 32.6% of unnecessary biopsies can be prevented. The ADC value can be used as a possible quantitative biomarker in addition to qualitative evaluation of the BI-RADS system for improved reporting. However, for structured reporting based on the BI-RADS system with the Kaiser Score, the ADC value does not seem to provide any additional benefit.

There is no evidence regarding the prediction of histological and immunohistochemical properties of breast cancer based on the ADC value.

An increase in the ADC value during neoadjuvant chemotherapy could indicate treatment response.

The ADC value could help to determine axillary lymph node status since the ADC value of affected lymph nodes is lower than that of unaffected nodes. However, further studies are needed.

Standardization of DWI in relation to image quality, image processing, and reporting is needed in order to be able to broaden the use of the ADC value in the clinical routine.

Conflict of Interest

The authors declare that they have no conflict of interest.

References

- [1] Mann RM, Balleyguier C, Baltzer PA et al. Breast MRI: EUSOBI recommendations for women's information. *Eur Radiol* 2015; 25: 3669–3678
- [2] Mann RM, Kuhl CK, Moy L. Contrast-enhanced MRI for breast cancer screening. *J Magn Reson Imaging* 2019; 50: 377–390
- [3] Baltzer P, Mann RM, Iima M et al. Diffusion-weighted imaging of the breast—a consensus and mission statement from the EUSOBI International Breast Diffusion-Weighted Imaging working group. *Eur Radiol* 2020; 30: 1436–1450
- [4] Padhani AR, Liu G, Koh DM et al. Diffusion-weighted magnetic resonance imaging as a cancer biomarker: consensus and recommendations. *Neoplasia* 2009; 11: 102–125
- [5] Surov A, Meyer HJ, Wienke A. Correlation between apparent diffusion coefficient (ADC) and cellularity is different in several tumors: a meta-analysis. *Oncotarget* 2017; 8: 59492–59499
- [6] Bailey C, Siow B, Panagiotaki E et al. Microstructural models for diffusion MRI in breast cancer and surrounding stroma: an ex vivo study. *NMR Biomed* 2017; 30: e3679
- [7] Parsian S, Giannakopoulos NV, Rahbar H et al. Diffusion-weighted imaging reflects variable cellularity and stromal density present in breast fibroadenomas. *Clin Imaging* 2016; 40: 1047–1054
- [8] Woodhams R, Kakita S, Hata H et al. Diffusion-weighted imaging of mucinous carcinoma of the breast: evaluation of apparent diffusion coefficient and signal intensity in correlation with histologic findings. *Am J Roentgenol* 2009; 193: 260–266
- [9] Jiang R, Ma Z, Dong H et al. Diffusion tensor imaging of breast lesions: evaluation of apparent diffusion coefficient and fractional anisotropy and tissue cellularity. *Br J Radiol* 2016; 89: 20160076
- [10] Onishi N, Kanao S, Kataoka M et al. Apparent diffusion coefficient as a potential surrogate marker for Ki-67 index in mucinous breast carcinoma. *J Magn Reson Imaging* 2015; 41: 610–615
- [11] Le Bihan D. What can we see with IVIM MRI? *Neuroimage* 2019; 187: 56–67
- [12] Klau M, Mayer P, Bergmann F et al. Correlation of Histological Vessel Characteristics and Diffusion-Weighted Imaging Intravoxel Incoherent Motion-Derived Parameters in Pancreatic Ductal Adenocarcinomas and Pancreatic Neuroendocrine Tumors. *Invest Radiol* 2015; 50: 792–797
- [13] Marrale M, Collura G, Brai M et al. Physics, Techniques and Review of Neuroradiological Applications of Diffusion Kurtosis Imaging (DKI). *Clin Neuroradiol* 2016; 26: 391–403
- [14] Liang J, Zeng S, Li Z et al. Intravoxel Incoherent Motion Diffusion-Weighted Imaging for Quantitative Differentiation of Breast Tumors: A Meta-Analysis. *Front Oncol* 2020; 10: 585486
- [15] Li Z, Li X, Peng C et al. The Diagnostic Performance of Diffusion Kurtosis Imaging in the Characterization of Breast Tumors: A Meta-Analysis. *Front Oncol* 2020; 10: 575272
- [16] Iima M, Honda M, Sigmund EE et al. Diffusion MRI of the breast: Current status and future directions. *J Magn Reson Imaging* 2020; 52: 70–90
- [17] Yabuuchi H, Matsuo Y, Okafuji T et al. Enhanced mass on contrast-enhanced breast MR imaging: Lesion characterization using combination of dynamic contrast-enhanced and diffusion-weighted MR images. *J Magn Reson Imaging* 2008; 28: 1157–1165
- [18] Chen X, Li WL, Zhang YL et al. Meta-analysis of quantitative diffusion-weighted MR imaging in the differential diagnosis of breast lesions. *BMC Cancer* 2010; 10: 693
- [19] Surov A, Meyer HJ, Wienke A. Can apparent diffusion coefficient (ADC) distinguish breast cancer from benign breast findings? A meta-analysis based on 13 847 lesions. *BMC Cancer* 2019; 19: 955
- [20] Rahbar H, Zhang Z, Chenevert TL et al. Utility of Diffusion-weighted Imaging to Decrease Unnecessary Biopsies Prompted by Breast MRI: A Trial of the ECOG-ACRIN Cancer Research Group (A6702). *Clin Cancer Res* 2019; 25: 1756–1765
- [21] Clauser P, Krug B, Bickel H et al. Diffusion-weighted imaging allows for downgrading MR BI-RADS 4 lesions in contrast-enhanced MRI of the breast to avoid unnecessary biopsy. *Clin Cancer Res* 2021. doi:10.1158/1078-0432.CCR-20-3037
- [22] McDonald ES, Romanoff J, Rahbar H et al. Mean Apparent Diffusion Coefficient Is a Sufficient Conventional Diffusion-weighted MRI Metric to Improve Breast MRI Diagnostic Performance: Results from the ECOG-ACRIN Cancer Research Group A6702 Diffusion Imaging Trial. *Radiology* 2021; 298: 60–70
- [23] Dietzel M, Krug B, Clauser P et al. A Multicentric Comparison of Apparent Diffusion Coefficient Mapping and the Kaiser Score in the Assessment of Breast Lesions. *Invest Radiol* 2021; 56: 274–282
- [24] Baltzer A, Dietzel M, Kaiser CG et al. Combined reading of Contrast Enhanced and Diffusion Weighted Magnetic Resonance Imaging by using a simple sum score. *Eur Radiol* 2016; 26: 884–891
- [25] Kim JY, Kim JJ, Hwangbo L et al. Diffusion-weighted Imaging of Invasive Breast Cancer: Relationship to Distant Metastasis-free Survival. *Radiology* 2019; 291: 300–307
- [26] Surov A, Meyer HJ, Wienke A. Associations between apparent diffusion coefficient (ADC) and Ki 67 in different tumors: a meta-analysis. Part 1: ADC_{mean}. *Oncotarget* 2017; 8: 75434–75444
- [27] Bonacho T, Rodrigues F, Liberal J. Immunohistochemistry for diagnosis and prognosis of breast cancer: a review. *Biotech Histochem* 2020; 95: 71–91
- [28] Shen L, Zhou G, Tong T et al. ADC at 3.0 T as a noninvasive biomarker for preoperative prediction of Ki67 expression in invasive ductal carcinoma of breast. *Clin Imaging* 2018; 52: 16–22
- [29] Mori N, Mugikura S, Takasawa C et al. Peritumoral apparent diffusion coefficients for prediction of lymphovascular invasion in clinically node-negative invasive breast cancer. *Eur Radiol* 2016; 26: 331–339
- [30] Martincich L, Deantoni V, Bertotto I et al. Correlations between diffusion-weighted imaging and breast cancer biomarkers. *Eur Radiol* 2012; 22: 1519–1528

- [31] Kim SH, Cha ES, Kim HS et al. Diffusion-weighted imaging of breast cancer: correlation of the apparent diffusion coefficient value with prognostic factors. *J Magn Reson Imaging* 2009; 30: 615–620
- [32] Surov A, Clauser P, Chang YW et al. Can diffusion-weighted imaging predict tumor grade and expression of Ki-67 in breast cancer? A multicenter analysis. *Breast Cancer Res* 2018; 20: 58
- [33] Park SH, Choi HY, Hahn SY. Correlations between apparent diffusion coefficient values of invasive ductal carcinoma and pathologic factors on diffusion-weighted MRI at 3.0 Tesla. *J Magn Reson Imaging* 2015; 41: 175–182
- [34] Meyer HJ, Wienke A, Surov A. Diffusion-weighted imaging of different breast cancer molecular subtypes. A systematic review and meta analysis. *Breast Care* 2021. doi: 10.1159/000514407
- [35] Beek MA, Verheuveel NC, Luiten EJ et al. Two decades of axillary management in breast cancer. *Br J Surg* 2015; 102: 1658–1664
- [36] Meyer HJ, Wienke A, Surov A. Diffusion-weighted imaging to predict nodal status in breast cancer. A systematic review and meta analysis. *Breast J* 2021; 27: 495–498
- [37] Fornasa F, Nesoti MV, Bovo C et al. Diffusion-weighted magnetic resonance imaging in the characterization of axillary lymph nodes in patients with breast cancer. *J Magn Reson Imaging* 2012; 36: 858–864
- [38] Rautiainen S, Könönen M, Sironen R et al. Preoperative axillary staging with 3.0-T breast MRI: clinical value of diffusion imaging and apparent diffusion coefficient. *PLoS One* 2015; 10: e0122516
- [39] Negrão EMS, Souza JA, Marques EF et al. Breast cancer phenotype influences MRI response evaluation after neoadjuvant chemotherapy. *Eur J Radiol* 2019; 120: 108701
- [40] Surov A, Wienke A, Meyer HJ. Pretreatment apparent diffusion coefficient does not predict therapy response to neoadjuvant chemotherapy in breast cancer. *Breast* 2020; 53: 59–67
- [41] Tsukada H, Tsukada J, Schrading S et al. Accuracy of multi-parametric breast MR imaging for predicting pathological complete response of operable breast cancer prior to neoadjuvant systemic therapy. *Magn Reson Imaging* 2019; 62: 242–248
- [42] Yuan L, Li JJ, Li CQ et al. Diffusion-weighted MR imaging of locally advanced breast carcinoma: the optimal time window of predicting the early response to neoadjuvant chemotherapy. *Cancer Imaging* 2018; 18: 38
- [43] Partridge SC, Zhang Z, Newitt DC et al. Diffusion-weighted MRI Findings Predict Pathologic Response in Neoadjuvant Treatment of Breast Cancer: The ACRIN 6698 Multicenter Trial. *Radiology* 2018; 289: 618–627
- [44] Tahmassebi A, Wengert GJ, Helbich TH et al. Impact of Machine Learning With Multiparametric Magnetic Resonance Imaging of the Breast for Early Prediction of Response to Neoadjuvant Chemotherapy and Survival Outcomes in Breast Cancer Patients. *Invest Radiol* 2019; 54: 110–117
- [45] Amornsiripanitch N, Bickelhaupt S, Shin HJ et al. Diffusion-weighted MRI for Unenhanced Breast Cancer Screening. *Radiology* 2019; 293: 504–520
- [46] Yabuuchi H, Matsuo Y, Sunami S et al. Detection of non-palpable breast cancer in asymptomatic women by using unenhanced diffusion-weighted and T2-weighted MR imaging: comparison with mammography and dynamic contrast-enhanced MR imaging. *Eur Radiol* 2011; 21: 11–17
- [47] Kazama T, Kuroki Y, Kikuchi M et al. Diffusion-weighted MRI as an adjunct to mammography in women under 50 years of age: an initial study. *J Magn Reson Imaging* 2012; 36: 139–144
- [48] Bickelhaupt S, Laun FB, Tesdorff J et al. Fast and Noninvasive Characterization of Suspicious Lesions Detected at Breast Cancer X-Ray Screening: Capability of Diffusion-weighted MR Imaging with MIPs. *Radiology* 2016; 278: 689–697
- [49] Rotili A, Trimboli RM, Penco S et al. Double reading of diffusion-weighted magnetic resonance imaging for breast cancer detection. *Breast Cancer Res Treat* 2020; 180: 111–120
- [50] Baltzer PAT, Kapetas P, Sodano C et al. Kontrastmittelfreie Mamma-MRT: Vorteile und potenzielle Nachteile [Contrast agent-free breast MRI: Advantages and potential disadvantages]. *Radiologe* 2019; 59: 510–516
- [51] Palm T, Wenkel E, Ohlmeyer S et al. Diffusion kurtosis imaging does not improve differentiation performance of breast lesions in a short clinical protocol. *Magn Reson Imaging* 2019; 63: 205–216
- [52] Wang K, Li Z, Wu Z et al. Diagnostic Performance of Diffusion Tensor Imaging for Characterizing Breast Tumors: A Comprehensive Meta-Analysis. *Front Oncol* 2019; 9: 1229
- [53] Baxter GC, Graves MJ, Gilbert FJ et al. A Meta-analysis of the Diagnostic Performance of Diffusion MRI for Breast Lesion Characterization. *Radiology* 2019; 291: 632–641