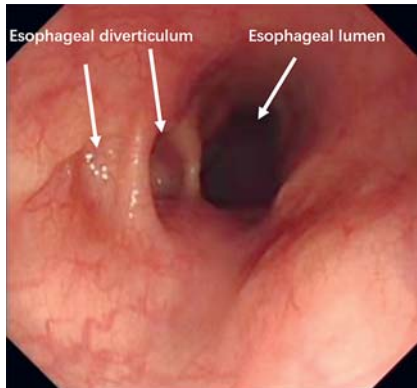
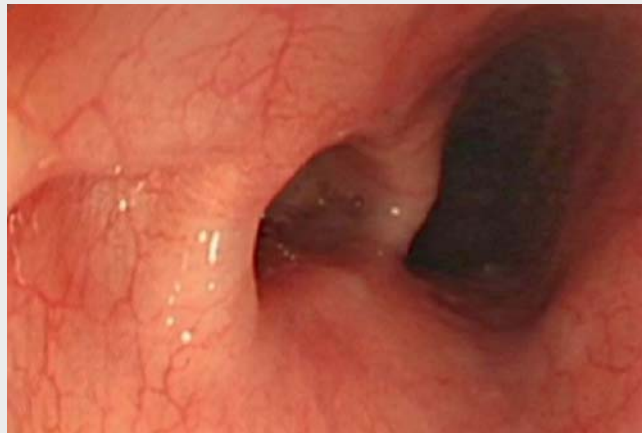


Peroral endoscopic myotomy for multiple esophageal diverticula



► **Fig. 1** Gastroscopy showed the two consecutive esophageal diverticula.



► **Video 1** Peroral endoscopic myotomy technique for the treatment of two consecutive esophageal diverticula in a 65-year-old man.

A 65-year-old man presented with persistent heartburn and acid reflux for 1 month, and was diagnosed with multiple esophageal diverticula in our department (► **Fig. 1**). Gastroscopy identified that two consecutive esophageal diverticula located 30 cm from the incisors. In recent years, endoscopic intervention was considered to be a better option for esophageal diverticulum compared with traditional surgical resection. This patient asked for treatment to alleviate symptoms. After informed consent was obtained, the esophageal diverticulum was treated using peroral endoscopic myotomy (POEM) under general anesthesia (► **Video 1**).

The POEM procedure included four steps. First, submucosal injection of saline mixed with methylene blue was performed at 3 cm above the diverticular septum, and a 2-cm longitudinal mucosal incision was made at the tunnel entry with a DualKnife (Olympus, Tokyo, Japan) (► **Fig. 2a**). A submucosal longitudinal tunnel was created between the mucosal and muscular layers. The tunneling was created at both sides of the septum for both diverticula and ended 1–2 cm distal to the bottom of the diverticulum (► **Fig. 2b**). All muscle layers of both septa were dissected down to the bottom of the diverticulum and further into the normal

esophageal muscle using a triangle-tip knife (► **Fig. 2c**). The tunnel entry was then closed with several clips (► **Fig. 2d**). The procedure was successfully performed without any adverse events, and the operation time was about 75 minutes. After the operation, a nasogastric tube was placed, and the patient was starved for 2 days followed by a semifluid diet or 1 week. The patient was discharged from hospital on Day 7 with symptoms resolved.

In 2010, POEM was first reported for treatment of achalasia [1]. So far, POEM has been applied to esophageal diverticulum [2]. It has been demonstrated that this technique is a minimally invasive, safe, and feasible approach for endoscopic myotomy of the esophageal muscle layer [3]. In the present case, we successfully treated two consecutive esophageal diverticula using POEM. Although an excellent short-term outcome was observed for treatment of multiple esophageal diverticula, further studies are still required to evaluate the long-term efficacy of POEM.

Endoscopy_UCTN_Code_CPL_1AH_2AK

Funding

National Natural Science Foundation of China
<http://dx.doi.org/10.13039/501100001809>
 81900479

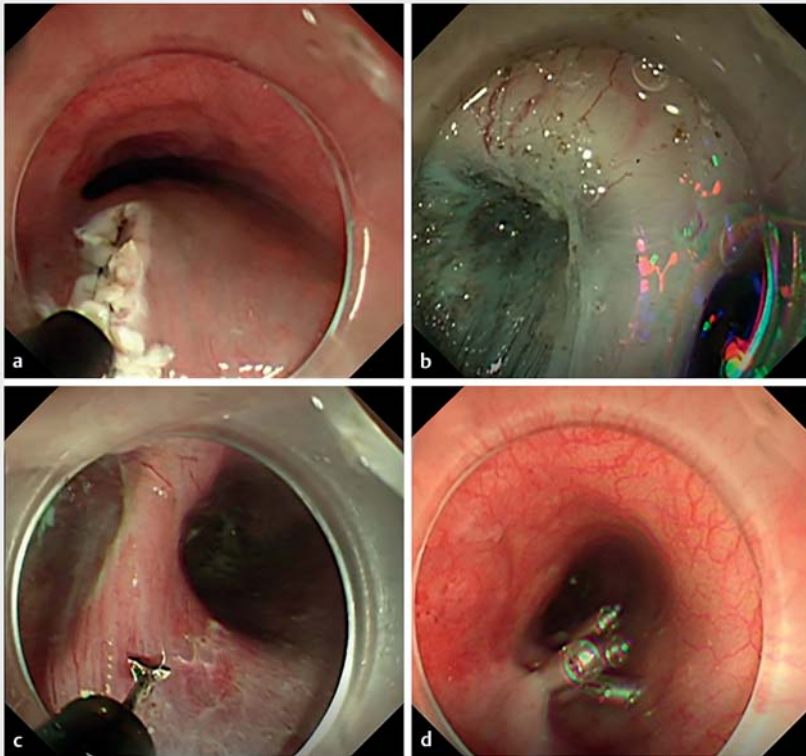
Competing interests

The authors declare that they have no conflict of interest.

The authors

Yong-Sheng Quan, **Jun Yao**, **Li-Sheng Wang**

Department of Gastroenterology, Second Clinical Medical College of Jinan University, Shenzhen People's Hospital, Shenzhen, Guangdong Province, China



► **Fig. 2** Endoscopic images of peroral endoscopic myotomy procedure in a patient with two consecutive esophageal diverticula. **a** Submucosal injection of saline mixed with methylene blue was performed at 3 cm above the diverticular septum, and a 2-cm longitudinal mucosal incision was made at the tunnel entry with a DualKnife (Olympus, Tokyo, Japan). **b** A submucosal longitudinal tunnel was created between the mucosal and muscular layers. To ensure sufficient operating space for the endoscopic myotomy, tunneling was created at both sides of the septum for both diverticula and ended 1–2 cm distal to the bottom of the diverticulum. **c** All muscle layers of the two septa were dissected down to the bottom of the diverticulum and further into the normal esophageal muscle using the triangle-tip knife. **d** The tunnel entry was then closed with several clips.

Bibliography

Endoscopy 2022; 54: E771–E772

DOI 10.1055/a-1795-7215

ISSN 0013-726X

published online 8.4.2022

© 2022. The Author(s).

This is an open access article published by Thieme under the terms of the Creative Commons Attribution-NonDerivative-NonCommercial License, permitting copying and reproduction so long as the original work is given appropriate credit. Contents may not be used for commercial purposes, or adapted, remixed, transformed or built upon. (<https://creativecommons.org/licenses/by-nc-nd/4.0/>)

Georg Thieme Verlag KG, Rüdigerstraße 14, 70469 Stuttgart, Germany



ENDOSCOPY E-VIDEOS

<https://eref.thieme.de/e-videos>



Endoscopy E-Videos is an open access online section, reporting on interesting cases and new techniques in gastroenterological endoscopy. All papers include a high quality video and all contributions are freely accessible online. Processing charges apply (currently EUR 375), discounts and waivers acc. to HINARI are available.

This section has its own submission website at

<https://mc.manuscriptcentral.com/e-videos>

Corresponding author

Li-Sheng Wang, MD

Department of Gastroenterology, Second Clinical Medical College of Jinan University, Shenzhen People's Hospital, 1017 Dongmen North Road, Shenzhen 518020, Guangdong Province, China
wangls168@163.com

References

- [1] Inoue H, Minami H, Kobayashi Y et al. Peroral endoscopic myotomy (POEM) for esophageal achalasia. *Endoscopy* 2010; 42: 265–271
- [2] Sato H, Takeuchi M, Hashimoto S et al. Esophageal diverticulum: new perspectives in the era of minimally invasive endoscopic treatment. *World J Gastroenterol* 2019; 25: 1457–1464
- [3] Yang J, Zeng X, Yuan X et al. An international study on the use of peroral endoscopic myotomy (POEM) in the management of esophageal diverticula: the first multicenter D-POEM experience. *Endoscopy* 2019; 51: 346–349