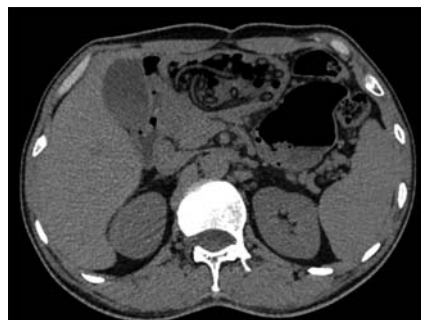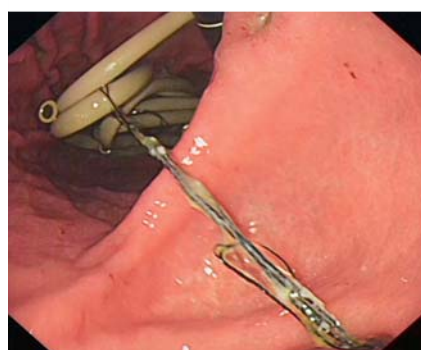


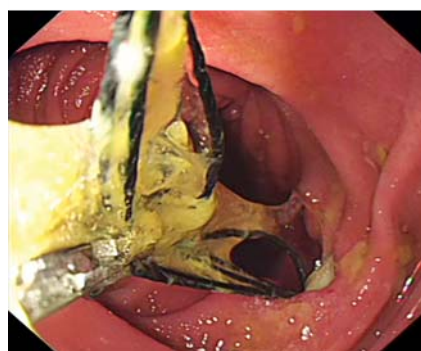Endoscopic scissors for removal of plastic tubes trapped with silk lines

OPEN
ACCESS

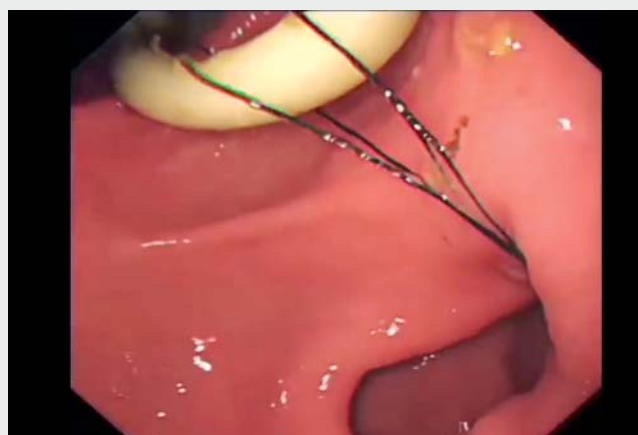► **Fig. 1** Multiple tubular objects in the stomach and duodenum on the computed tomography scan.



► **Fig. 2** Numerous yellow tubes in the stomach. One end of the silk line was tightly wound around the tubes in the stomach.



► **Fig. 3** Numerous yellow tubes in the duodenum. One end of the silk line was embedded in the duodenal ulceration. Many extraction attempts were made, but the silk line remained in the duodenum.

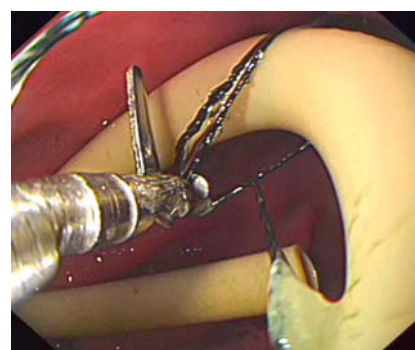


► **Video 1** Endoscopic scissors for removal of plastic tubes trapped with silk lines.

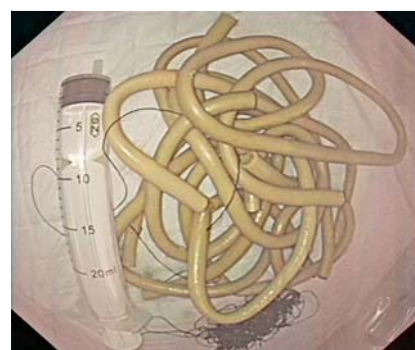


Endoscopic scissors have the advantage of preventing potential complications associated with thermal and mechanical damage to surrounding structures [1]. They can be used on insulated cores, metallic coils, fish bones, and nasogastric tubes [1–3]. However, there have been no reports of endoscopic scissors being used to cut through silk line.

A middle-aged man presented to the emergency department with abdominal pain for the past eight days. He disclosed that he had ingested a long plastic tube trapped with a silk line after drinking two years ago. Physical examination was normal, as was his routine blood test. Computed tomography scans showed multiple tubular objects in the stomach and duodenum (► **Fig. 1**). Gastroscopy revealed numerous yellow tubes in the stomach and duodenum (► **Fig. 2**, ► **Video 1**). It was observed that one end of the silk line was wedged in the duodenum wall with secondary mucosal ulceration (► **Fig. 3**), and the other end was tightly wound around the tubes in the stomach (► **Fig. 2**). Because the silk line was very flexible, the endoscopy nurse made several attempts before successfully cutting it in half while pulling silk



► **Fig. 4** Endoscopic scissors were used to successfully cut through the silk line.



► **Fig. 5** All identified foreign bodies (yellow plastic tubes and silk lines) were removed. A 20-ml syringe is pictured as a reference.

line tightly (► Fig. 4). All identified foreign bodies were removed with a rat-tooth forceps (► Fig. 5). The patient recovered well and was discharged 8 days after the procedure.

We highlight the role of endoscopic scissors in cutting through silk line in this challenging case, which prevented further surgical removal of the foreign bodies. Endoscopic scissors, originally designed for cutting the nasobiliary duct in vivo [2], were adopted to cut the silk line in half in our case. As far as we know, this is the first case of plastic tubes trapped with silk lines to be removed using endoscopic scissors.

Endoscopy_UCTN_Code_TTT_1AO_2AL

Competing interests

The authors declare that they have no conflict of interest.

The authors

Zhihui Duan  **Shengyun Zhou**
Digestive Endoscopy Center, Xingtai People's Hospital, Xingtai, China

Corresponding author

Zhihui Duan, MM
Digestive Endoscopy Center, Xingtai People's Hospital, No. 16 Hongxing Street, Xingtai 054000, China
15131988129@163.com

References

- [1] Kee WJ, Park CH, Chung KM et al. Various applications of endoscopic scissors in difficult endoscopic interventions. *Endoscopy* 2014; 46: 432–434
- [2] Su X, He Q, Zhu Y et al. Utilization of endoscopic scissors for retrieval of esophageal embedded foreign body. *Am J Gastroenterol* 2021; 116: 1976
- [3] Wilkinson MN, Jayaraman V, Watkins K et al. Newly developed flexible endoscopic scissors for removal of a nasogastric tube trapped within a gastrojejunal anastomotic staple line. *Endoscopy* 2011; 43: E234–E235

Bibliography

Endoscopy 2022; 54: E796–E797
DOI 10.1055/a-1810-6911
ISSN 0013-726X
published online 27.4.2022
© 2022. The Author(s).

This is an open access article published by Thieme under the terms of the Creative Commons Attribution License, permitting unrestricted use, distribution, and reproduction so long as the original work is properly cited. (<https://creativecommons.org/licenses/by/4.0/>)
Georg Thieme Verlag KG, Rüdigerstraße 14, 70469 Stuttgart, Germany



ENDOSCOPY E-VIDEOS
<https://eref.thieme.de/e-videos>



Endoscopy E-Videos is an open access online section, reporting on interesting cases and new techniques in gastroenterological endoscopy. All papers include a high quality video and all contributions are freely accessible online. Processing charges apply (currently EUR 375), discounts and waivers acc. to HINARI are available.

This section has its own submission website at
<https://mc.manuscriptcentral.com/e-videos>