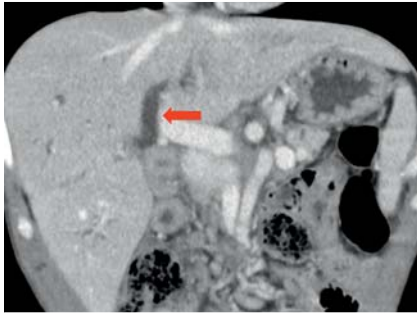
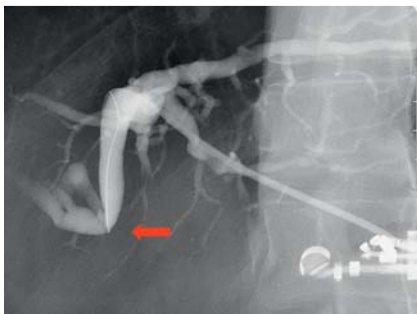

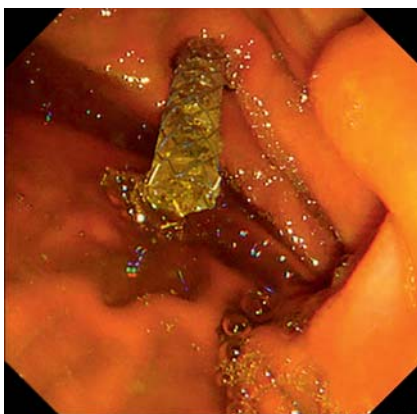
Endoscopic ultrasound (EUS)-guided antegrade intervention for a hepaticojejunostomy anastomosis obstruction under peroral cholangioscopy via an EUS-guided hepaticogastrostomy route



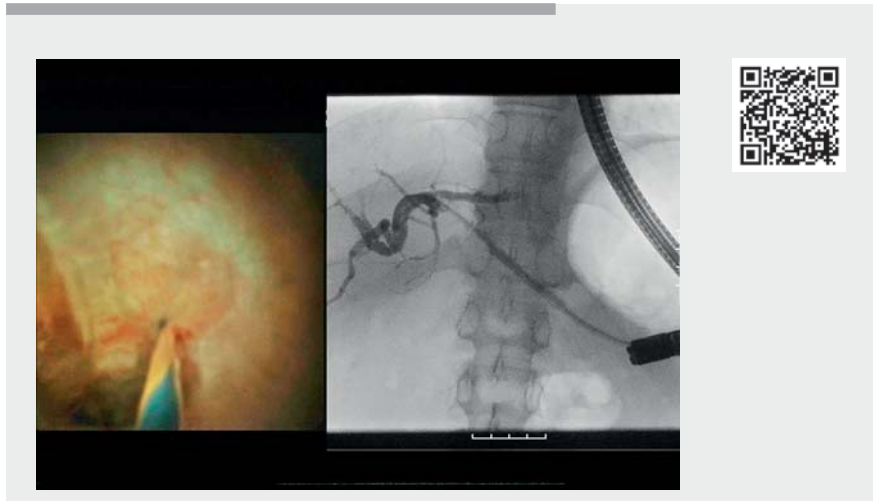
► **Fig. 1** Computed tomography image showing the dilated intrahepatic bile duct (arrow).



► **Fig. 2** During fluoroscopy, no contrast medium flowed out of the dilated bile duct (arrow).



► **Fig. 3** A 6-mm, fully covered, self-expandable metal stent was inserted across the endoscopic ultrasound-guided hepaticogastrostomy route.



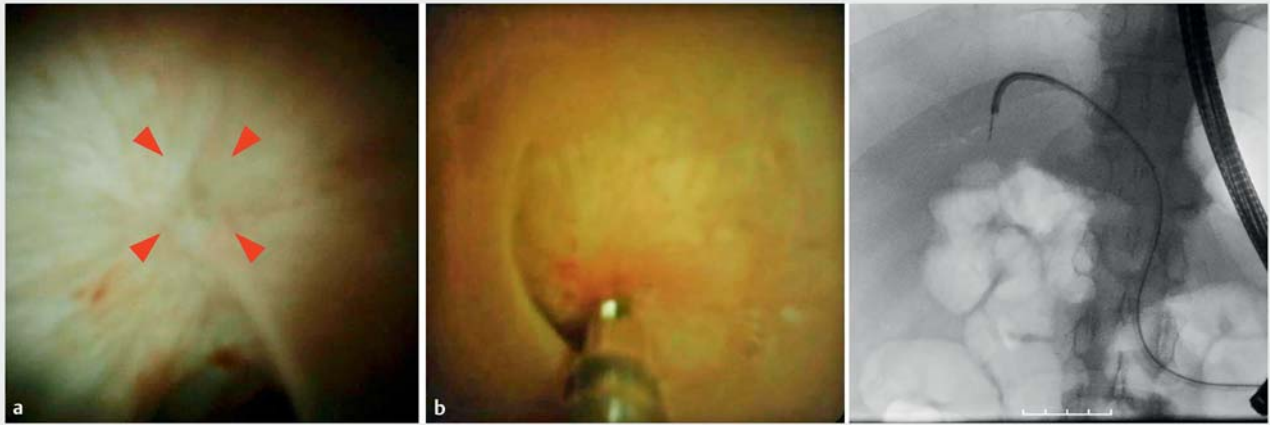► **Video 1** Endoscopic ultrasound (EUS)-guided antegrade intervention for complete obstruction of a hepaticojejunostomy anastomosis under peroral cholangioscopy via an EUS-guided hepaticogastrostomy route.

A 47-year-old man who had undergone subtotal stomach-preserving pancreaticoduodenectomy presented with recurrent cholangitis, possibly due to a hepaticojejunostomy anastomosis (HJA) stricture (► **Fig. 1**). Endoscopic retrograde cholangiopancreatography using short-type single-balloon endoscopy was planned. However, as the HJA was completely occluded by a fibrous membrane, we could not insert the cannula into the bile duct. Therefore, we performed endoscopic ultrasound-guided hepaticogastrostomy (EUS-HGS).

The dilated intrahepatic bile duct (B3) was punctured with a 19-gauge needle (EZ shot 3 plus; Olympus Co., Tokyo, Japan). However, no contrast medium flowed from the dilated bile duct to the jejunum, and a 0.025-inch guidewire could not be inserted across the anastomosis (► **Fig. 2**).

One month after EUS-HGS, a 7-Fr plastic stent was exchanged for a 6-mm, fully covered, self-expandable metal stent

(HANAROSTENT Biliary; M.I. Tech, Gyeonggi-do, Korea) across the EUS-HGS route (► **Fig. 3**). A SpyGlass DS system (Boston Scientific Corp., Marlborough, Massachusetts, USA) was used to perform cholangioscopy to visualize the anastomosis from the inside of the bile duct (► **Video 1**). We found that the duct was completely obstructed at the anastomotic site and covered with a fibrous membrane (► **Fig. 4a**). It was difficult to break through this obstruction even with cholangioscopy guidance. Repeated poking with a stiff edge of a guidewire partially broke the fibrous membrane, and a guidewire could finally be passed through the anastomosis; however, a 4-Fr catheter could not be passed through the anastomosis. We dilated the anastomosis stricture by gradually removing the fibrotic tissue using biopsy forceps (SpyBite MAX; Boston Scientific Corp.) under direct cholangioscopic observation (► **Fig. 4b**). After dilation of the anastomosis using a 7-Fr catheter and a



► **Fig. 4** Cholangioscopy and fluoroscopy images. **a** Cholangioscopic image showing the completely obstructed bile duct at the anastomotic site covered with fibrous membrane (arrowheads). **b** Biopsy forceps were used to remove the fibrotic tissue before dilation of the anastomosis under direct cholangioscopic observation.

6-mm balloon catheter, antegrade trans-anastomotic placement of a 7-Fr plastic stent across the EUS-HGS route was performed. No procedure-related adverse events were observed, and cholangitis improved after treatment.

Although EUS-guided drainage for stenosis of the HJA has been reported [1], complete obstruction makes it difficult to recanalize the anastomosis using endoscopic procedures. Recently, the usefulness of cholangioscopy through a percutaneous transhepatic or transpapillary route for postoperative biliary strictures or obstructions has been described [2,3]. EUS-guided antegrade intervention under cholangioscopy via an EUS-HGS route is an alternative treatment.

Endoscopy_UCTN_Code_TTT_1AR_2AG

Competing interests

The authors declare that they have no conflict of interest.

The authors

Keisuke Yonamine, Shinsuke Koshita,
Yoshihide Kanno, **Takahisa Ogawa**, **Hiroaki Kusunose, Toshitaka Sakai, Kei Ito**
 Department of Gastroenterology, Sendai City Medical Center, Sendai, Japan

Corresponding author

Keisuke Yonamine, MD
 Department of Gastroenterology, Sendai City Medical Center, 5-22-1 Tsurugaya, Miyagino-ku, Sendai 983-0824, Japan
 k.yonamine@openhp.or.jp

References

- [1] James TW, Fan YC, Baron TH. EUS-guided hepaticoenterostomy as a portal to allow definitive antegrade treatment of benign biliary disease in patients with surgically altered anatomy. *Gastrointest Endosc* 2018; 88: 547–554
- [2] Fujii Y, Koshita S, Ito K. Percutaneous transhepatic cholangioscopy using SpyGlass DS for an anastomotic stenosis after choledochojunostomy. *Dig Endosc* 2018; 30: 806–807
- [3] Yane K, Ihara H, Sumiyoshi T et al. Successful recanalization of complete bile duct obstruction using piercing technique under cholangioscopic guidance. *Endoscopy* 2021. doi:10.1055/a-1540-6735

Bibliography

Endoscopy 2022; 54: E788–E789
 DOI 10.1055/a-1810-7068
 ISSN 0013-726X
 published online 25.4.2022
 © 2022. The Author(s).

This is an open access article published by Thieme under the terms of the Creative Commons Attribution-NonDerivative-NonCommercial License, permitting copying and reproduction so long as the original work is given appropriate credit. Contents may not be used for commercial purposes, or adapted, remixed, transformed or built upon. (<https://creativecommons.org/licenses/by-nc-nd/4.0/>)
 Georg Thieme Verlag KG, Rüdigerstraße 14, 70469 Stuttgart, Germany



ENDOSCOPY E-VIDEOS

<https://eref.thieme.de/e-videos>



Endoscopy E-Videos is an open access online section, reporting on interesting cases and new techniques in gastroenterological endoscopy. All papers include a high quality video and all contributions are freely accessible online. Processing charges apply (currently EUR 375), discounts and wavers acc. to HINARI are available.

This section has its own submission website at
<https://mc.manuscriptcentral.com/e-videos>