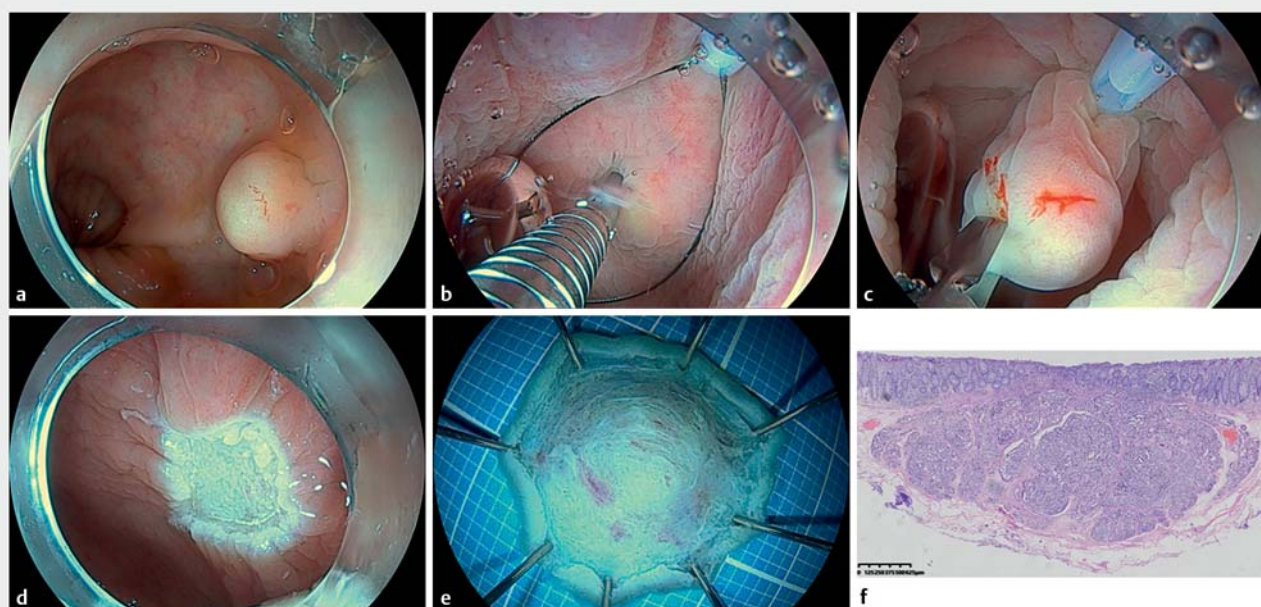


Use of a self-made additional working channel for underwater endoscopic mucosal resection of a rectal neuroendocrine tumor

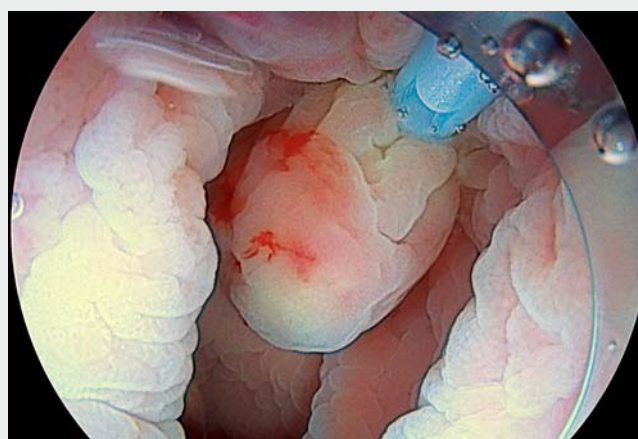
OPEN
ACCESS



► Fig. 1 The process of underwater endoscopic mucosal resection assisted by a self-made additional working channel. **a** An 8-mm neuroendocrine tumor (NET) was located in the rectum of a 39-year-old man. **b** After the snare was placed around the lesion, a reopenable clip grasped the lesion in the water. **c** The clip was pulled back in the water so the NET became an artificial protrusion for resection. **d** No residual lesion was observed in the wound, and there was no bleeding or perforation. **e** The fresh specimen was stretched and fixed. **f** The histological appearance of the resected specimen showed a grade 1 NET with negative vertical and horizontal margins.

A 39-year-old man was diagnosed with an 8-mm neuroendocrine tumor (NET) in the rectum (► **Fig. 1 a**). Endoscopic ultrasonography indicated that the lesion was confined to the submucosa. In order to get an en bloc resection, we developed an underwater endoscopic mucosal resection (EMR) technique assisted by an additional working channel (AWC) that we made ourselves.

A nasal oxygen tube about 30 cm in length was taped to the outside of the endoscope to become an AWC. The snare could move back and forth and rotate freely through the tube (► **Video 1**). After the snare was placed around the lesion through our self-made AWC, the lesion was grasped underwater with a reopenable clip (► **Fig. 1 b**). The clip was pulled back in the water and the snare was tight-



► Video 1 Underwater endoscopic mucosal resection to remove a rectal neuroendocrine tumor with the assistance of a self-made additional working channel.

tened to perform resection with an Endo-cut Q (effect 3, cut duration 2, cut interval 4) (► Fig. 1 c). The wound was clean and without bleeding or perforation (► Fig. 1 d). Finally, the fresh specimen was stretched and fixed on a foam plate with the mucosal surface facing downward (► Fig. 1 e). Histological examination showed a grade 1 NET with negative vertical and horizontal margins (► Fig. 1 f).

Edris Wedi et al. reported that a commercially available system called EMR+ was a practical method of overcoming the limitations of classical EMR [1]. We believe that our self-made AWC using a nasal oxygen tube, which is a very easily accessible thing, can achieve the same effect. Combined with the advantages of underwater EMR, this technique can be successfully and inexpensively applied to deal with gastrointestinal NETs, most of which are in the submucosa.

Endoscopy_UCTN_Code_TTT_1AQ_2AD

Competing interests

The authors declare that they have no conflict of interest.

The authors

Chao Deng¹, Suhua Wu¹, Lin Liao², Xiaodong Guo¹, Jia Li³, Zhechuan Mei¹, Song He¹

- 1 Department of Gastroenterology, The Second Affiliated Hospital of Chongqing Medical University, Chongqing, P. R. China
- 2 Department of Pharmacy, Chongqing General Hospital, Chongqing, P. R. China
- 3 Department of Pathology, The Second Affiliated Hospital of Chongqing Medical University, Chongqing, P. R. China

Corresponding author

Song He, MD

Department of Gastroenterology,
The Second Affiliated Hospital of Chongqing
Medical University, No. 76 Linjiang Road,
Yuzhong District, Chongqing 400000,
P. R. China
hedoctor65@cqmu.edu.cn

Reference

- [1] Wedi E, Knoop RF, Jung C et al. Use of an additional working channel for endoscopic mucosal resection (EMR+) of a pedunculated sessile serrated adenoma in the sigmoid colon. *Endoscopy* 2019; 51: 279–280

Bibliography

Endoscopy 2022; 54: E790–E791

DOI 10.1055/a-1814-4311

ISSN 0013-726X

published online 25.4.2022

© 2022. The Author(s).

This is an open access article published by Thieme under the terms of the Creative Commons Attribution-NonDerivative-NonCommercial License, permitting copying and reproduction so long as the original work is given appropriate credit. Contents may not be used for commercial purposes, or adapted, remixed, transformed or built upon. (<https://creativecommons.org/licenses/by-nc-nd/4.0/>)

Georg Thieme Verlag KG, Rüdigerstraße 14,
70469 Stuttgart, Germany



ENDOSCOPY E-VIDEOS

<https://eref.thieme.de/e-videos>



Endoscopy E-Videos is an open access online section, reporting on interesting cases and new techniques in gastroenterological endoscopy. All papers include a high quality video and all contributions are freely accessible online. Processing charges apply (currently EUR 375), discounts and waivers acc. to HINARI are available.

This section has its own submission website at
<https://mc.manuscriptcentral.com/e-videos>