

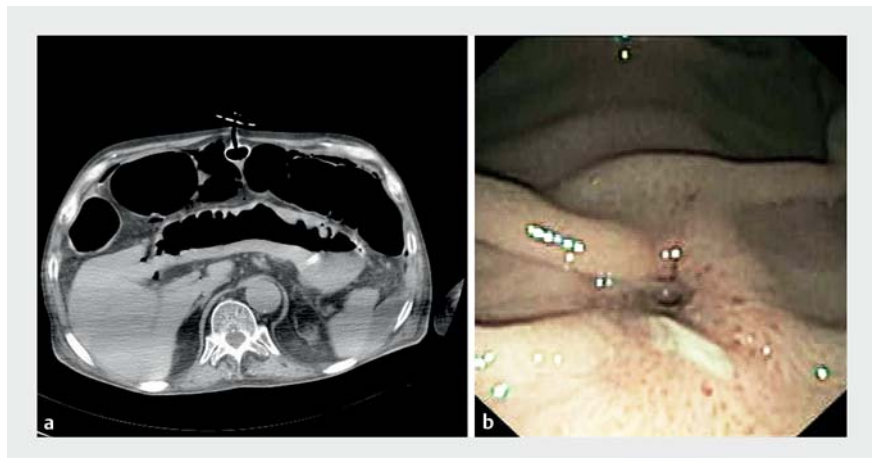
## Unusual application of an endoscopic–laparoscopic rendezvous technique to restore the percutaneous gastrostomy in buried bumper syndrome



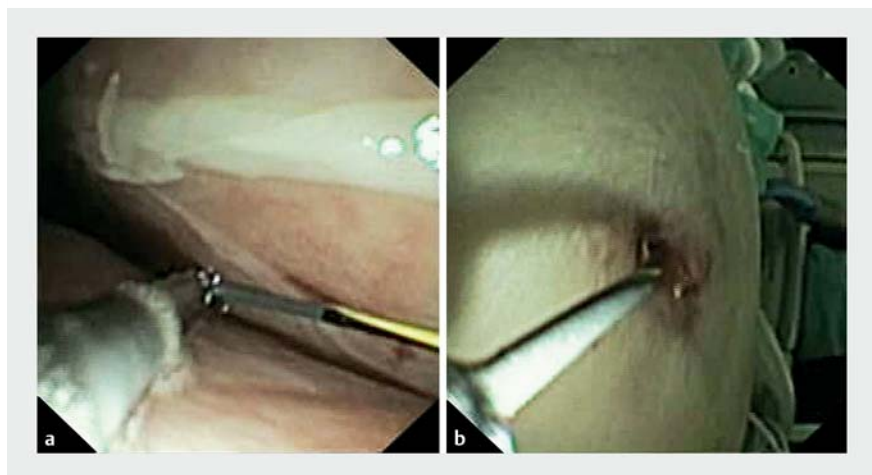
A 66-year-old man with cerebrovascular disease underwent placement of a percutaneous endoscopic gastrostomy (PEG) using a 20-Fr dome-bolstered tube. After 1-month, the patient was admitted to our institute for investigation of infusion resistance and leakage around the tube. On physical examination, the internal bumper was not rotatable or moveable, and was subcutaneously palpable. A computed tomography scan confirmed dislocation of the peritoneal bumper (► **Fig. 1 a**). Endoscopically, just a small dimple was visible in the mucosa of the anterior wall of the stomach (► **Fig. 1 b**), confirming the diagnosis of complete buried bumper syndrome. The PEG was removed with gentle external traction.

Under direct endoscopic view, a 0.035-inch guidewire was introduced through both original orifices of the PEG fistula (from the gastric cavity towards the abdominal wall and vice versa), but it was not possible to restore the connection. A pediatric gastroscope (GIF-XP160, 5.9-mm diameter), inserted percutaneously through the abdominal orifice, was used to perform an endoscopic peritoneoscopy, visualizing the peritoneal side of the gastric orifice. After multiple unsuccessful attempts to reach the stomach from the peritoneum, it was decided to change the strategy.

A guidewire was passed from the stomach through the fistulous gastric orifice reaching the peritoneal cavity. With access again via the transabdominal route, the guidewire was grasped with a forceps and pulled to the outside, restoring the fistulous tract in an endoscopic–laparoscopic rendezvous approach (► **Fig. 2**). After an over-the-wire 8-mm hydro-pneumatic dilation of the fistulous tract had been performed, a 20-Fr replacement gastrostomy tube was substituted (► **Fig. 3**; ► **Video 1**). A broad-spectrum antibiotic was continued for 7 days. The



► **Fig. 1** Evidence of internal bumper dislocation into the peritoneum near the transverse colon: **a** on computed tomography scan; **b** on endoscopic view showing a small orifice with smooth margins and erythematous mucosa and no evidence of the percutaneous endoscopic gastrostomy bumper on the anterior wall of the stomach.

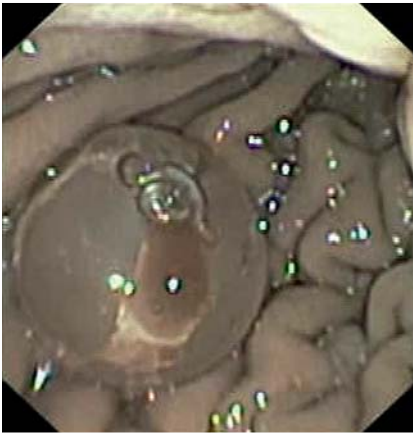


► **Fig. 2** Images during endoscopic peritoneoscopy via the percutaneous transabdominal access, which allowed the connection between the gastric and abdominal fistulous orifices to be restored in a rendezvous approach showing: **a** the guidewire grasped with a forceps in the peritoneal cavity; **b** the guidewire pulled through to the outside.

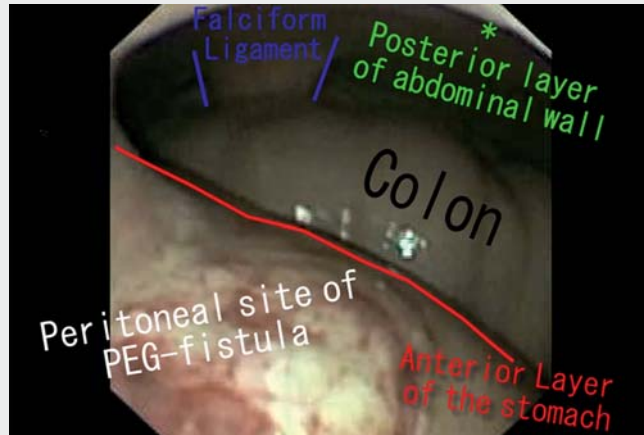
PEG was working normally at 3-month follow-up.

Buried bumper syndrome is a rare complication (1%–4%), with a possible severe evolution if underestimated [1]. Approp-

riate care and correct instruction of patients and their relatives may prevent buried bumper syndrome by reducing prolonged excessive mechanical traction of the external bolster [2, 3]. Early diag-



► **Fig. 3** Endoscopic image showing a new 20-Fr replacement gastrostomy tube, which had normal rotation and mobilization in the longitudinal axis, correctly positioned at the previous gastric site.



► **Video 1** Buried bumper syndrome after placement of a percutaneous endoscopic gastrostomy is successfully treated using a novel rendezvous approach with direct endoscopic peritoneoscopy and grasping of the guidewire.

nosis of buried bumper syndrome and appropriate expertise can allow minimally invasive and conservative resolution of this complication.

Endoscopy\_UCTN\_Code\_CPL\_1AH\_2AI

### Competing interests

The authors declare that they have no conflict of interest.

### The authors

**Roberto Di Mitri, Michele Amata**  **Ambra Bonaccorso, Filippo Mocciano**  **Elisabetta Conte, Barbara Scrivo, Daniela Scimeca**   
Gastroenterology and Endoscopy Unit, ARNAS Civico – Di Cristina – Benfratelli Hospital, Palermo, Italy

### Corresponding author

**Michele Amata, MD**  
Gastroenterology and Endoscopy Unit, ARNAS Civico – Di Cristina – Benfratelli Hospital, Piazza Nicola Leotta 4, 901200 Palermo, Italy  
michele.amata@gmail.com

### References

- [1] Gkolfakis P, Arvanitakis M, Despott EJ et al. Endoscopic management of enteral tubes in adult patients – Part 2: Peri- and post-procedural management. *European Society of Gastrointestinal Endoscopy (ESGE) Guideline. Endoscopy* 2021; 53: 178–195
- [2] Huynh G, Chan M, Huynh HQ. Buried bumper syndrome. *VideoGIE* 2020; 5: 104–106
- [3] Cyrany J, Rejchrt S, Kopacova M et al. Buried bumper syndrome: A complication of percutaneous endoscopic gastrostomy. *World J Gastroenterol* 2016; 22: 618–627

### Bibliography

*Endoscopy* 2022; 54: E826–E827  
DOI 10.1055/a-1816-7758  
ISSN 0013-726X  
**published online** 13.5.2022  
© 2022. The Author(s).

This is an open access article published by Thieme under the terms of the Creative Commons Attribution-NonDerivative-NonCommercial License, permitting copying and reproduction so long as the original work is given appropriate credit. Contents may not be used for commercial purposes, or adapted, remixed, transformed or built upon. (<https://creativecommons.org/licenses/by-nc-nd/4.0/>)  
Georg Thieme Verlag KG, Rüdigerstraße 14, 70469 Stuttgart, Germany



### ENDOSCOPY E-VIDEOS

<https://eref.thieme.de/e-videos>



*Endoscopy E-Videos* is an open access online section, reporting on interesting cases and new techniques in gastroenterological endoscopy. All papers include a high quality video and all contributions are freely accessible online. Processing charges apply (currently EUR 375), discounts and waivers acc. to HINARI are available.

This section has its own submission website at <https://mc.manuscriptcentral.com/e-videos>