

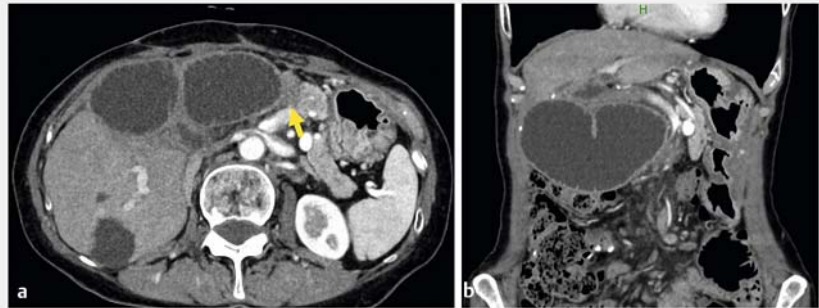
## Endoscopic ultrasound-guided intra-afferent loop entero-enterostomy using a forward-viewing echoendoscope and insertion of a metal stent

OPEN  
ACCESS

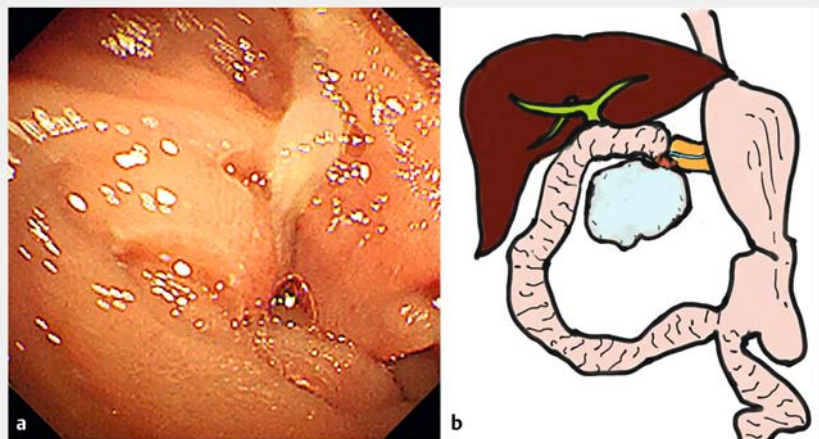
Endoscopic ultrasound-guided gastro-enterostomy (EUS-GE) is a treatment option for afferent loop syndrome [1], with the use of various stents having been reported [2–5]. However, depending on the site of the stenosis of the afferent loop, fistulization from the stomach can be difficult. We introduce an entero-enterostomy technique using a forward-viewing echoendoscope and metal stent for the treatment of afferent loop syndrome.

A 70-year-old woman presented with a chief complaint of abdominal pain, and computed tomography (CT) showed afferent loop syndrome due to recurrence of pancreatic cancer (► Fig. 1). We initially attempted transgastrointestinal stenting of the afferent loop stenosis. The endoscope was successfully inserted to the site of the stenosis, but insertion of the guidewire through the stenotic lumen was difficult (► Fig. 2).

We therefore converted to performing EUS-guided fistulization from the stomach to the afferent loop; however, intra-gastric EUS identified the presence of part of the normal intestinal tract between the stomach and dilated afferent loop (► Fig. 3). Consequently, we attempted to create a fistula, using a forward-viewing echoendoscope (TGF-UC260J; Olympus, Tokyo, Japan), from a section of the afferent loop to the dilated afferent loop (► Video 1). With this technique, it was possible to identify the dilated afferent loop by EUS without intervention (► Fig. 4 a) and it was easily punctured with a 19-gauge needle (EZ shot 3 plus; Olympus) (► Fig. 4 b). After contrast enhancement had been used to confirm penetration of the intestinal tract, a 0.025-inch guidewire (M-through; Medico's Hirata, Osaka, Japan) was advanced into the dilated afferent loop (► Fig. 4 c). A covered metal stent (Covered BileRush Advance, 10×80 mm; Piolax Medical Devices, Yokohama, Japan), with a 7-Fr delivery shaft, was placed (► Fig. 4 d). A



► Fig. 1 Computed tomography scan images showing intestinal dilatation and disseminated nodules (arrow) at the onset of the afferent loop on: a axial image; b coronal image.



► Fig. 2 The initial situation, with a sharp intestinal bend and severe stenosis preventing passage of the guidewire, is shown on: a endoscopic image of the intestinal bend; b a schema illustrating the afferent loop syndrome.

half-pigtail plastic stent was then placed within the metal stent to prevent ulceration (► Fig. 4 e, f). No complications were observed. A repeat CT scan showed improvement in the dilatation of the afferent loop (► Fig. 5).

This is the first report of this EUS-guided entero-enterostomy technique, which may be a new option for difficult intra-gastric puncture during EUS-GE.

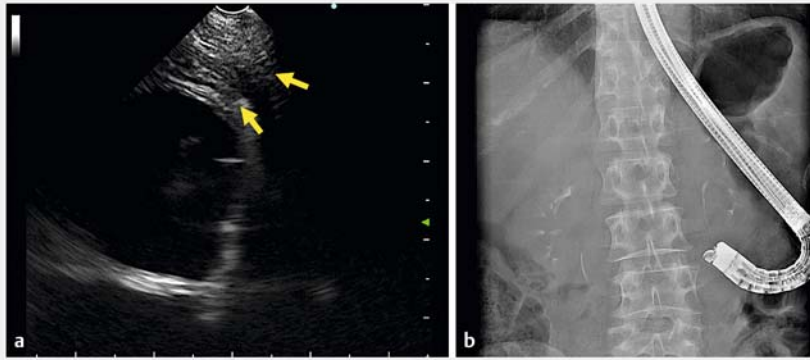
Endoscopy\_UCTN\_Code\_TTT\_1AS\_2AG FB

### Funding

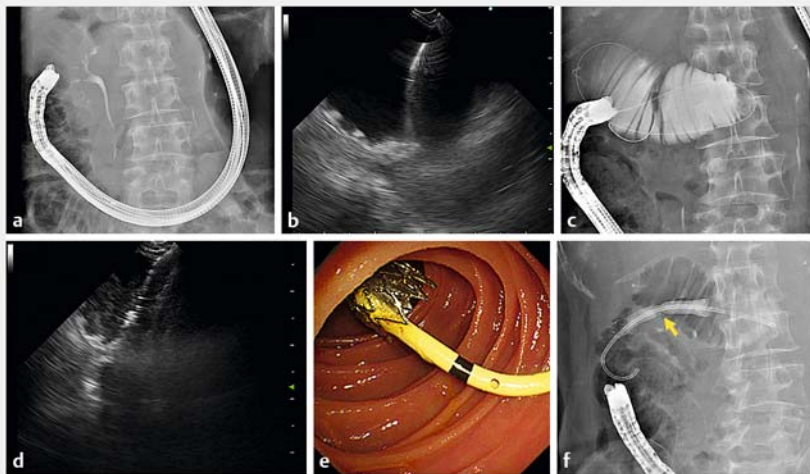
The National Cancer Center Research and Development Fund  
2022-A-16

### Competing interests

The authors declare that they have no conflict of interest.




► **Fig. 3** The afferent loop dilation was confirmed by endoscopic ultrasound (EUS) from the stomach as shown on: **a** an EUS image that revealed another segment of normal intestine between the stomach and the dilated afferent loop; **b** a radiographic image demonstrating the position of the forward-viewing echoendoscope during the intragastric scan.



► **Fig. 4** Images from the endoscopic ultrasound (EUS)-guided intra-afferent loop entero-enterostomy showing: **a** radiographically, the position of the forward-viewing echoendoscope within the afferent loop; **b** puncture of the dilated afferent loop under EUS guidance using a 19-gauge needle; **c** the guidewire being advanced into the dilated afferent loop; **d** deployment of the fully covered metal stent into the afferent loop; **e** an endoscopic image of the inside of the afferent loop immediately after stent placement; **f** a radiographic image of the final stent placement with a notch (arrow) clearly evident.

## The authors

Yuki Kawasaki<sup>1,2</sup>, Susumu Hijioka<sup>1</sup> , Kosuke Maehara<sup>1</sup>, Kiichi Tamada<sup>2</sup>, Takuji Okusaka<sup>1</sup>, Yutaka Saito<sup>3</sup>

- 1 Department of Hepatobiliary and Pancreatic Oncology, National Cancer Center Hospital, Tokyo, Japan
- 2 Department of Medicine, Division of Gastroenterology, Jichi Medical University, Tochigi, Japan
- 3 Department of Endoscopy Division, National Cancer Center Hospital, Tokyo, Japan

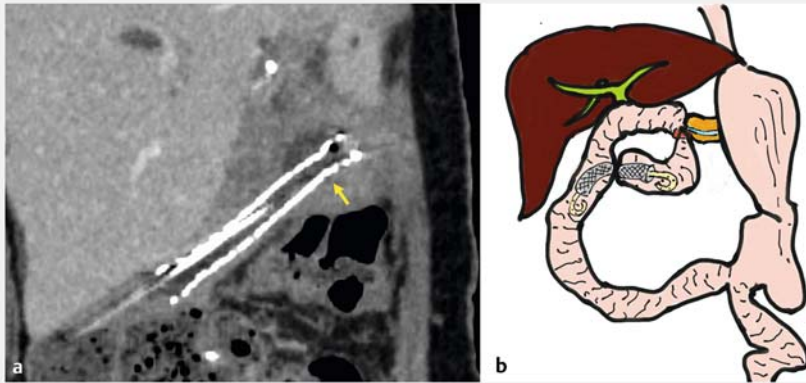
## Corresponding author

**Susumu Hijioka, MD**

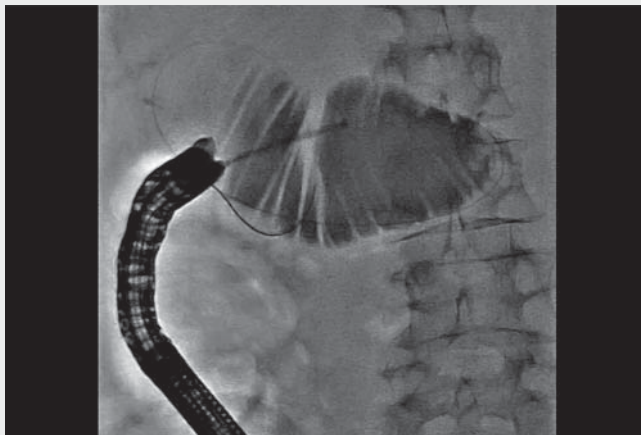
Department of Hepatobiliary and Pancreatic Oncology, National Cancer Center Hospital, 5-1-1 Tsukiji, Chuo-ku, Tokyo, Japan  
shijioka@ncc.go.jp

## References

- [1] Shimoi H, Sakai A, Nakano R et al. Endoscopic ultrasound-guided gastroenterostomy for afferent loop syndrome. *Clin Endosc* 2021; 54: 810–817
- [2] Yamamoto K, Tsuchiya T, Tanaka R et al. Afferent loop syndrome treated by endoscopic ultrasound-guided gastrojejunostomy, using a lumen-apposing metal stent with an electrocautery-enhanced delivery system. *Endoscopy* 2017; 49: E270–E272
- [3] Ikeuchi N, Itoi T, Tsuchiya T et al. One-step EUS-guided gastrojejunostomy with use of a lumen-apposing metal stent for afferent loop syndrome treatment. *Gastrointest Endosc* 2015; 82: 166
- [4] Brewer Gutierrez OI, Irani SS, Ngamruengphong S et al. Endoscopic ultrasound-guided entero-enterostomy for the treatment of afferent loop syndrome: a multicenter experience. *Endoscopy* 2018; 50: 891–895
- [5] Sakamoto Y, Hijioka S, Maruki Y et al. EUS-guided gastroenterostomy with metal stent for afferent loop syndrome. *Endoscopy* 2019; 51: E153–E155



► **Fig. 5** The outcome following the endoscopic ultrasound (EUS)-guided entero-enterostomy is shown on: **a** a computed tomography curved multiplanar reconstruction of the metal stent, with an improvement in the dilation of the afferent loop (arrow); **b** a schema illustrating procedure completion.



► **Video 1** Endoscopic stent placement in the afferent loop for malignant stenosis via endoscopic ultrasound-guided gastroenterostomy was not possible. Endoscopic ultrasound-guided intra-afferent loop entero-enterostomy is therefore performed using a forward-viewing echoendoscope and metal stent.

## Bibliography

Endoscopy 2022; 54: E815–E817

DOI 10.1055/a-1816-7943

ISSN 0013-726X

published online 6.5.2022

© 2022. The Author(s).

This is an open access article published by Thieme under the terms of the Creative Commons Attribution-NonDerivative-NonCommercial License, permitting copying and reproduction so long as the original work is given appropriate credit. Contents may not be used for commercial purposes, or adapted, remixed, transformed or built upon. (<https://creativecommons.org/licenses/by-nc-nd/4.0/>)

Georg Thieme Verlag KG, Rüdigerstraße 14, 70469 Stuttgart, Germany



## ENDOSCOPY E-VIDEOS

<https://eref.thieme.de/e-videos>



*Endoscopy E-Videos* is an open access online section, reporting on interesting cases and new techniques in gastroenterological endoscopy. All papers include a high quality video and all contributions are freely accessible online. Processing charges apply (currently EUR 375), discounts and waivers acc. to HINARI are available.

This section has its own submission website at <https://mc.manuscriptcentral.com/e-videos>