

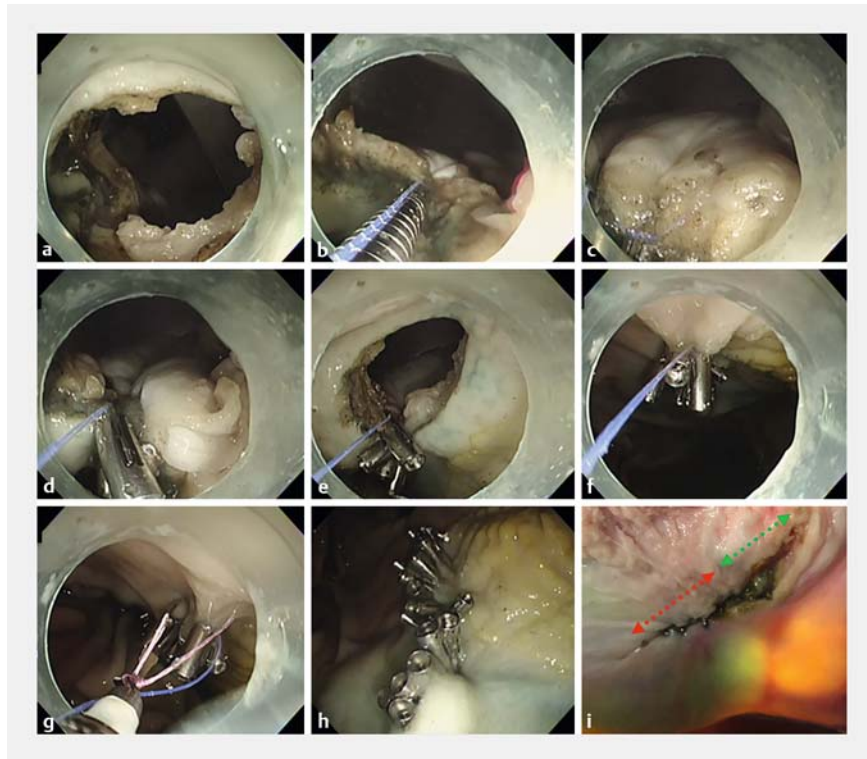
Reopenable clip over line method for the closure of full-thickness defect after gastric endoscopic full-thickness resection



In recent years, the efficacy of endoscopic full-thickness resection for submucosal tumors has been reported [1, 2]. However, a reliable closure method for large full-thickness defects in the stomach remains unclarified. We developed the reopenable clip over line method for closing the mucosal defect after endoscopic submucosal dissection using reopenable clips and a line placed at the muscle layer and edge of the mucosal defect [3–5]. We report a new method of this type of closure of a 25-mm full-thickness defect in a porcine model (► **Video 1**).

The reopenable clip over line method is a defect closure method using a reopenable clip (Sureclip, 8mm; Micro-Tech Co., Ltd., Nanjing, China) and a line (nylon line, 0.22mm).

First, a 25-mm defect was created in the middle part of a porcine stomach (► **Fig. 1**). A reopenable clip with an attached line was passed through the accessory channel and placed to grip the seromuscular layer and mucosa. Next, a line was inserted through a hole in the reopenable clip and then through the accessory channel. Thereafter, threaded a reopenable clip was placed over the line to grasp the seromuscular layer and mucosa. Additional threaded reopenable clips were repeatedly placed for the contralateral seromuscular layer and mucosa, and the defect was completely closed when the line was pulled by hand. The full-thickness defect closure time was 22 min with 20 reopenable clips. Finally, a modified locking-clip technique was used to fix the line to the normal mucosa and cut it [5]. The macroscopic view of the stomach from the serosa side revealed closure of the distal defect between the serosa and of the proximal defect between the muscular layers.



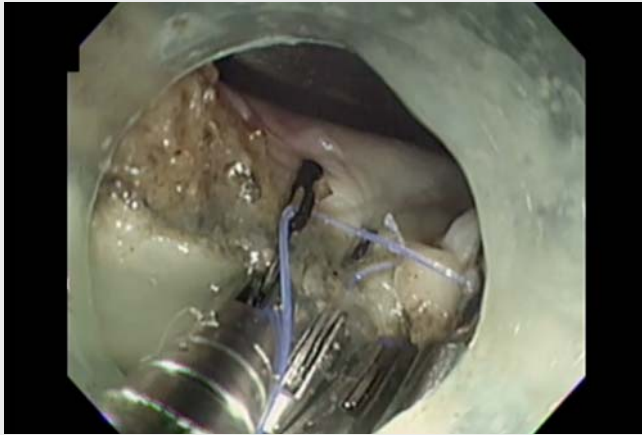
► **Fig. 1** Reopenable clip over line method for a porcine full-thickness gastric defect closure. **a** A 25-mm full-thickness defect in the stomach. **b** The first reopenable clip with line is placed to grasp the seromuscular layer and mucosa. **c** Repeated placement of reopenable clips to grasp the seromuscular layer and mucosa. **d** When the reopenable clip is placed, the gastric defect is gradually closed between the seromuscular layer and mucosa on both sides. **e** Pull the line by hand to prevent the clip from embedding in the serosal side. **f** The line remains after the full-thickness defect is completely closed. **g** Modified locking-clip technique to fix the line to the normal mucosa and cut it. **h** Full-thickness gastric defect completely closed using the reopenable clip over line method. **i** Endoscopic view from the serous side; full-thickness defect after closure (distal side (red arrow): serous layers closed together; proximal side (green arrow): muscular layer closed together).

The reopenable clip over line method can close a full-thickness gastric defect. By placing the reopenable clip from the distal side of the stomach to grasp the seromuscular layer and mucosa, partial serosa closure was possible.

Endoscopy_UCTN_Code_CPL_1AH_2AG

Competing interests

The authors declare that they have no conflict of interest.



Video 1 Reopenable clip over line method for a 25-mm full-thickness gastric defect.

Bibliography

Endoscopy 2022; 54: E808–E809

DOI 10.1055/a-1824-4919

ISSN 0013-726X

published online 6.5.2022

© 2022. The Author(s).

This is an open access article published by Thieme under the terms of the Creative Commons Attribution-NonDerivative-NonCommercial License, permitting copying and reproduction so long as the original work is given appropriate credit. Contents may not be used for commercial purposes, or adapted, remixed, transformed or built upon. (<https://creativecommons.org/licenses/by-nc-nd/4.0/>)

Georg Thieme Verlag KG, Rüdigerstraße 14, 70469 Stuttgart, Germany



The authors

Tatsuma Nomura^{1,2}, **Shinya Sugimoto**¹,
Haruka Nakamura^{1,2}, **Taishi Temma**¹, **Jun Oyamada**¹, **Keiichi Ito**², **Makoto Kobayashi**³

1 Department of Gastroenterology, Ise Red Cross Hospital, Ise, Mie, Japan

2 Department of Gastroenterology, Mie Prefectural Shima Hospital, Shima, Mie, Japan

3 Department of Gastroenterology, Yokkaichi Municipal Hospital, Yokkaichi, Mie, Japan

Corresponding author

Tatsuma Nomura, MD

Department of Gastroenterology, Ise Red Cross Hospital, Gastroenterology, 1-471-2 Funae, Ise, Mie 516-8512, Japan
Fax: +81-596-65-5304
m06076tn@icloud.com

References

- [1] Cai MY, Martin Carreras-Presas F, Zhou PH. Endoscopic full-thickness resection for gastrointestinal submucosal tumors. *Dig Endosc* 2018; 30: 17–24
- [2] Ye LP, Zhang Y, Luo DH et al. Safety of endoscopic resection for upper gastrointestinal subepithelial tumors originating from the muscularis propria layer: an analysis of 733 tumors. *Am J Gastroenterol* 2016; 111: 788–796
- [3] Nomura T, Sugimoto S, Tsuda N et al. Mucosal defect closure after duodenal endoscopic submucosal dissection using the reopenable-clip over the line method. *JGH Open* 2021; 5: 831–833
- [4] Nomura T, Sugimoto S, Temma T et al. Clip-line closure with the reopenable clip over line method for a large mucosal defect after gastric endoscopic submucosal dissection. *Endoscopy* 2022; 54: E1–E2
- [5] Nomura T, Sugimoto S, Kawabata M et al. Large colorectal mucosal defect closure post-endoscopic submucosal dissection using the reopenable clip over line method and modified locking-clip technique. *Endoscopy* 2021. doi:10.1055/a-1381-6435

ENDOSCOPY E-VIDEOS

<https://eref.thieme.de/e-videos>



Endoscopy E-Videos is an open access online section, reporting on interesting cases and new techniques in gastroenterological endoscopy. All papers include a high quality video and all contributions are freely accessible online. Processing charges apply (currently EUR 375), discounts and waivers acc. to HINARI are available.

This section has its own submission website at

<https://mc.manuscriptcentral.com/e-videos>