

A novel endoscopic technique for closure of two gastro-gastric fistulas in a single session using an endoscopic helix tacking device

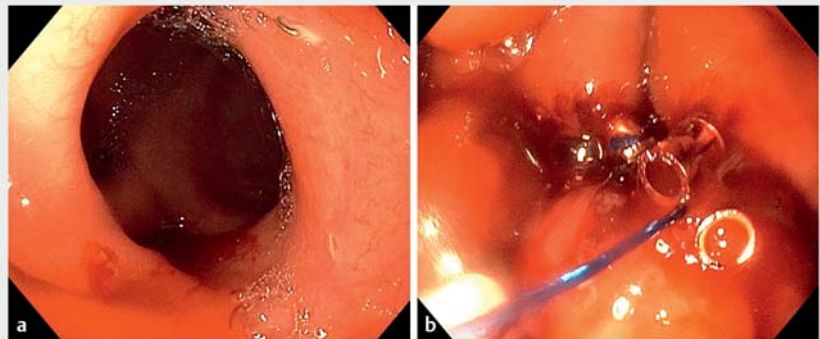
OPEN
ACCESS

A gastro-gastric fistula is a rare but well-known complication of Roux-en-Y gastric bypass surgery, which can lead to weight regain and ulceration [1]. Most commonly, surgical approaches are used to repair such defects [2]; however, endoscopic repair methods have also been used with various success rates [3]. We report the first case of the endoscopic closure of multiple gastro-gastric fistulas in a single session, using an X-Tack Endoscopic HeliX Tacking System (Apollo Endosurgery, Inc., Austin, Texas, USA).

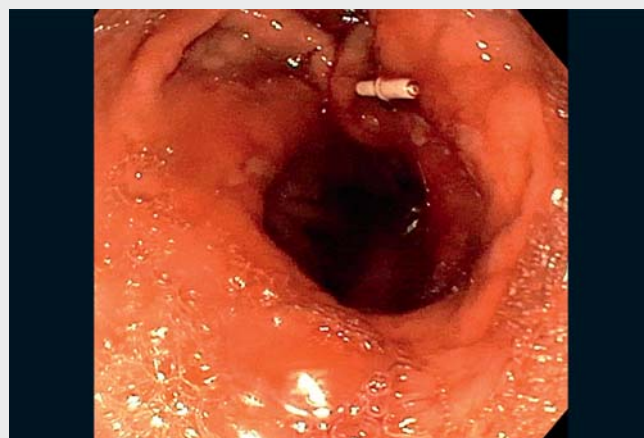A 34-year-old man presented with upper abdominal pain, accompanied by weight loss of 70 kgs during the 12 months since he had undergone bariatric surgery. The patient had a history of laparoscopic adjustable gastric band surgery, which had been converted to a mini-gastric bypass after he had regained his presurgery weight. Index endoscopy revealed a 4-cm gastric pouch, with two gastro-gastric fistulas between the gastric pouch and the excluded gastric remnant, one measuring 12 mm and the other 8 mm (► Fig. 1 a). Each fistula was cauterized using argon plasma coagulation (APC) to remove the mucosa and encourage healing fibrosis. The X-Tack Endoscopic HeliX Tacking device was then used with 12 helices, along with prolene 2-0 sutures, to close both fistulas, which were covered by a layer of normal mucosa (► Fig. 1 b). As shown in ► Video 1, no visible tract was noted at the conclusion of the procedure and a patent anastomosis was retained.

A computed tomography scan was performed 2 months later, which showed no extravasation of oral contrast material from the gastric pouch to the excluded gastric remnant, indicating durable closure of the fistulas. The patient currently remains pain free and has started to gain weight since the procedure.

Endoscopy_UCTN_Code_TTT_1AO_2AI



► **Fig. 1** Endoscopic views showing: **a** a gastro-gastric fistula between the gastric pouch and the excluded gastric remnant; **b** the fourth tack in position, with closure of the fistula having been achieved by tightening and ligation of the suture.



► **Video 1** Closure of two gastro-gastric fistulas in a single session using an endoscopic helix tacking device.

Competing interests

The authors declare that they have no conflict of interest.

The authors

Lidor Akavia¹, **Iris Dotan**^{1,2}, **Gerard Aguila**¹, **Steven Shamah**¹

¹ Rabin Medical Center, Division of Gastroenterology, Petah Tikva, Israel

² Tel Aviv University, Sackler Faculty of Medicine, Tel Aviv, Israel

Corresponding author

Lidor Akavia, MD

Division of Gastroenterology, Rabin Medical Center, Jabotinski St 39, Petah Tikva, 4941492, Israel
lidor.akavia@gmail.com

References

- [1] Capella JF, Capella RF. Gastro-gastric fistulas and marginal ulcers in gastric bypass procedures for weight reduction. *Obes Surg* 1999; 9: 22–28
- [2] Chahine E, Kassir R, Dirani M et al. Surgical management of gastrogastic fistula after Roux-en-Y gastric bypass: 10-year experience. *Obes Surg* 2018; 28: 939–944
- [3] Fernandez-Esparrach G, Lautz DB, Thompson CC. Endoscopic repair of gastrogastic fistula after Roux-en-Y gastric bypass: a less-invasive approach. *Surg Obes Relat Dis* 2010; 6: 282–288

Bibliography

Endoscopy 2022; 54: E845–E846

DOI 10.1055/a-1838-3306

ISSN 0013-726X

published online 25.5.2022

© 2022. The Author(s).

This is an open access article published by Thieme under the terms of the Creative Commons Attribution-NonDerivative-NonCommercial License, permitting copying and reproduction so long as the original work is given appropriate credit. Contents may not be used for commercial purposes, or adapted, remixed, transformed or built upon. (<https://creativecommons.org/licenses/by-nc-nd/4.0/>)

Georg Thieme Verlag KG, Rüdigerstraße 14, 70469 Stuttgart, Germany



ENDOSCOPY E-VIDEOS

<https://eref.thieme.de/e-videos>



Endoscopy E-Videos is an open access online section, reporting on interesting cases

and new techniques in gastroenterological endoscopy. All papers include a high quality video and all contributions are freely accessible online. Processing charges apply (currently EUR 375), discounts and waivers acc. to HINARI are available.

This section has its own submission website at

<https://mc.manuscriptcentral.com/e-videos>