

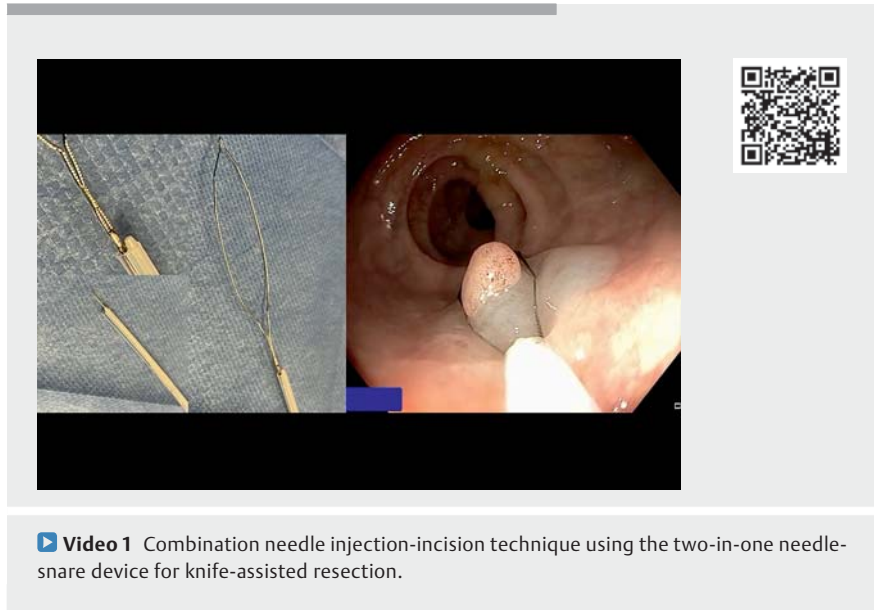
## The combination needle injection-incision technique using the two-in-one needle-snare device for knife-assisted resection



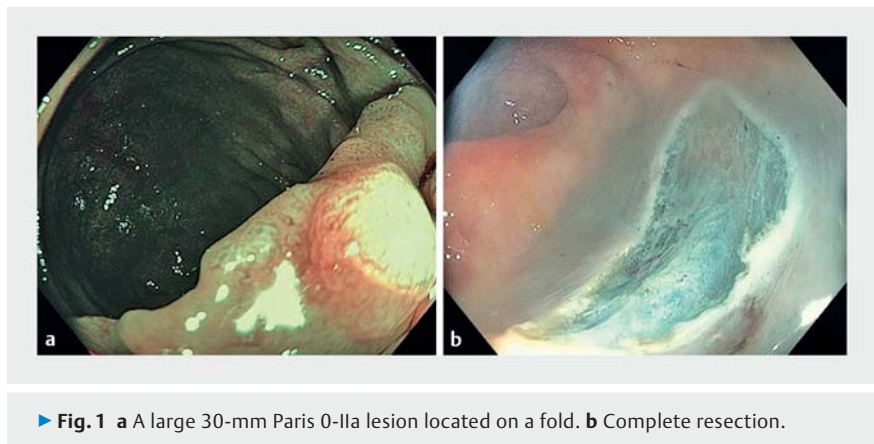
In order to perform advanced resections that require submucosal injection of substances such as endoscopic submucosal dissection (ESD) or hybrid endoscopic submucosal dissection/endoscopic mucosal resection (ESD-EMR), several instruments are required, including an injection needle, incision needle, and dissection knives and/or snaring devices [1–5]. The present report describes a novel and simple method that involves using a two-in-one device that combines a needle and a snare.

This observational, retrospective, single-arm, open label, case study included seven patients (two female, five male, mean age 59 years, age range 52–78 years) with colon polyps. The endoscopic technique relies on one device (SnareInflator, Fujifilm-medwork, Höchststadt, Germany) and four key steps (► **Video 1**): (i) creating a submucosal cushion with a needle; (ii) the initial incision with the tip of the snare; (iii) continuing the circumferential incision with the tip of the snare, which is also utilized to perform partial endoscopic submucosal dissection; and (iv) final resection with the snare (► **Fig. 1** and ► **Fig. 2**, ► **Video 1**). A total of nine lesions were resected, with a mean size of 15 mm and a range of 10 to 35 mm. The mean time of the procedure was 17 min (range 4 to 30 min). Endoscopic R0 resection was accomplished in all cases and histologic R0 achieved in 90%; one patient had questionable adenoma at the lateral margin. There were no major adverse events.

We conclude that using a single needle-and-snare device allows for successful and safe hybrid ESD-EMR in medium sized colonic polyps. This report is interesting for several reasons. First, we are not aware of any previous description of the dual needle-snare device for ESD-EMR and thus believe that it is a useful addition to the armamentarium of every endoscopist. Second, this novel method of using a single device combining a needle and



► **Video 1** Combination needle injection-incision technique using the two-in-one needle-snare device for knife-assisted resection.



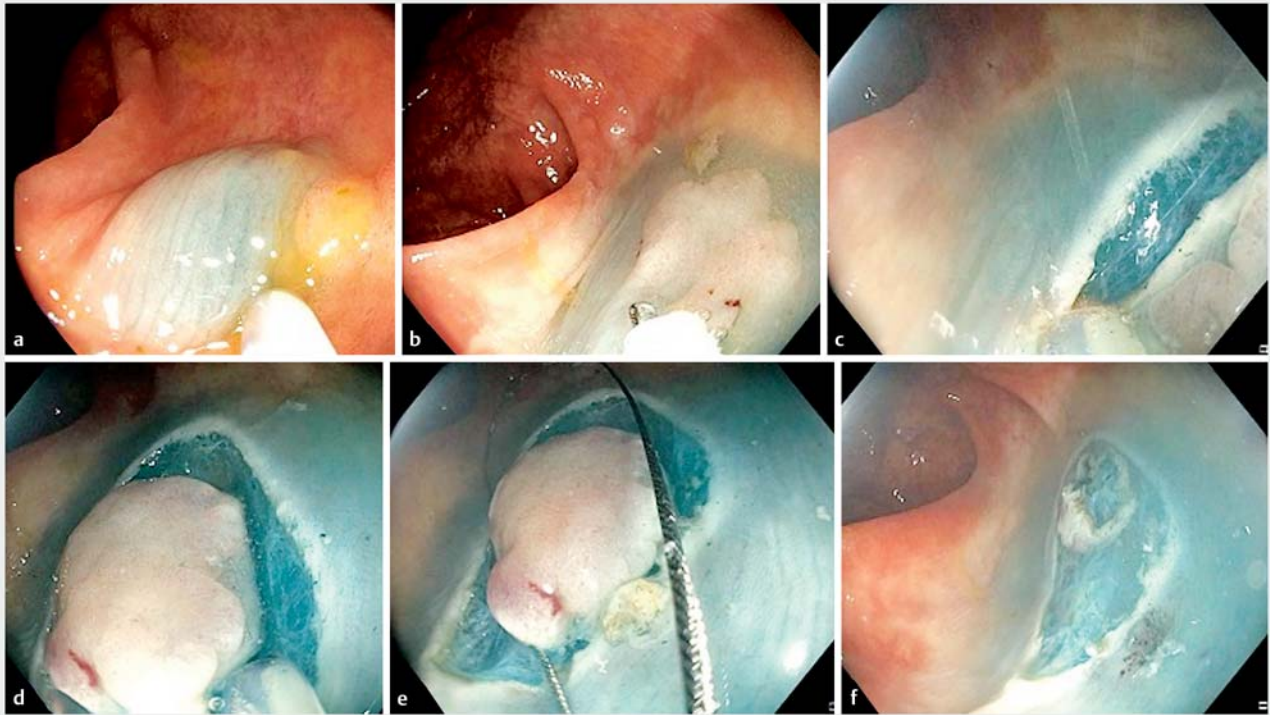
► **Fig. 1** a A large 30-mm Paris 0-IIa lesion located on a fold. b Complete resection.

snare to perform hybrid ESD-EMR should be easily reproducible by other endoscopists around the world. Third, having a combined needle-snare may decrease time and costs involved in advanced endoscopic resection procedures. Fourth, the teaching video shows all the steps to perform this technique. Future comparative studies are now warranted. Finally, such a device can reduce the amount of environmental waste generated by using a single multifunction device with only one package instead of two.

Endoscopy\_UCTN\_Code\_TTT\_1AQ\_2AD

### Competing interests

Klaus Mönkemüller has received honoraria for consulting from Ovesco, Tübingen, Germany.



► **Fig. 2** Summary of the resection technique using the combination needle-snare device. The endoscopic technique relies on a single device and four key steps. **a** The first step in creating the submucosal cushion with the needle, usually injecting a mixture of saline or hydroxymethylcellulose and indigo carmine. **b** The photo shows the exposure of the snare tip. **c** Step two is the initial incision, which is performed with the tip of the snare, barely exposed at 1–2 mm. **d** The third step or circumferential incision, also known as precutting or knife-assisted resection, is continued with the tip of the snare. In some cases the tip of the snare may also be utilized to perform partial endoscopic submucosal dissection. **e** The fourth and final step is using the fully expanded snare, which is essential to perform the final resection (i. e., the hybrid endoscopic submucosal dissection/endoscopic mucosal resection approach). **f** Complete resection accomplished, endoscopic R0.

## The authors

Brigita Petrik<sup>1</sup>, Alvaro Martínez-Alcalá<sup>2</sup>,  
Katarzyna Pawlak<sup>3</sup>, Klaus Mönkemüller<sup>1,4,5</sup>

- 1 Department of Gastroenterology, Frankwaldklinik, Kronach, Germany
- 2 Department of Gastroenterology, Hospital Universitario Infanta Leonor, Madrid, Spain
- 3 Department of Gastroenterology, Hospital of the Ministry of the Interior, Szczecin, Poland
- 4 University of Belgrade, Belgrade, Serbia
- 5 Ameos Klinikum Otto-von-Guericke University Teaching Hospital, Halberstadt, Germany

## Corresponding author

**Klaus Mönkemüller, MD**  
Division of Gastroenterology, University Teaching Hospital, Ameos Klinikum Halberstadt, Gleimstraße 5, 38820 Halberstadt, Germany  
moenkemueller@yahoo.com

## References

- [1] Yamamoto H. Endoscopic submucosal dissection-current success and future directions. *Nat Rev Gastroenterol Hepatol* 2012; 9: 519–529
- [2] Probst A, Ebigbo A, Märkl B et al. Endoscopic submucosal dissection for early rectal neoplasia: experience from a European center. *Endoscopy* 2017; 49: 222–232
- [3] Pioche M, Lépilliez V, Déprez P et al. High-pressure jet injection of viscous solutions for endoscopic submucosal dissection (ESD): first clinical experience. *Endosc Int Open* 2015; 3: E368–E372. doi:10.1055/s-0034-1391902
- [4] Jacques J, Legros R, Charissoux A et al. A combination of pocket, double-clip countertraction, and isolated HybridKnife as a quick and safe strategy for colonic endoscopic submucosal dissection. *Endoscopy* 2017; 49: E134–E135. doi:10.1055/s-0043-104522
- [5] Jacques J, Legros R, Charissoux A et al. Anchoring the snare tip by means of a small incision facilitates en bloc endoscopic mucosal resection and increases the specimen size. *Endoscopy* 2017; 49: E39–E41. doi:10.1055/s-0042-121009

## Bibliography

*Endoscopy* 2022; 54: E1060–E1061  
DOI 10.1055/a-1851-4632  
ISSN 0013-726X  
published online 25.8.2022  
© 2022. The Author(s).

This is an open access article published by Thieme under the terms of the Creative Commons Attribution-NonDerivative-NonCommercial License, permitting copying and reproduction so long as the original work is given appropriate credit. Contents may not be used for commercial purposes, or adapted, remixed, transformed or built upon. (<https://creativecommons.org/licenses/by-nc-nd/4.0/>)  
Georg Thieme Verlag KG, Rüdigerstraße 14, 70469 Stuttgart, Germany

