

Chemosaturation of the Liver – an Update

Chemosaturation der Leber – ein Update

Authors

Sebastian Ebel¹ , Manuel Florian Struck² , Florian van Boemmel³, Anne Bettina Beeskow¹, Holger Gößmann¹, Timm Denecke¹

Affiliations

- 1 Klinik und Poliklinik für diagnostische und interventionelle Radiologie, Leipzig University, Leipzig, Germany
- 2 Klinik und Poliklinik für Anästhesiologie und Intensivtherapie, Leipzig University, Leipzig, Germany
- 3 Klinik für Innere Medizin II, Sektion für Hepatologie, Leipzig University, Leipzig, Germany

Key words

abdomen, hematologic, angiography, interventional procedures

received 20.09.2021

accepted 05.05.2022

published online 17.08.2022

Bibliography

Fortschr Röntgenstr 2023; 195: 30–37

DOI 10.1055/a-1858-3418

ISSN 1438-9029

© 2022. Thieme. All rights reserved.

Georg Thieme Verlag KG, Rüdigerstraße 14, 70469 Stuttgart, Germany

Correspondence

Dr. Sebastian Ebel

Klinik und Poliklinik für diagnostische und interventionelle Radiologie, Leipzig University, Liebigstr. 20, 04103 Leipzig, Germany

Tel.: 0 34 19 71 74 24

sebastian.ebel@icloud.com

ABSTRACT

Background Percutaneous hepatic perfusion (CS-PHP) is a treatment option for primary and secondary liver neoplasms and subject of intensive research. This present article provides an overview of CS-PHP regarding patient safety, feasibility and effectiveness based on recent studies.

Method We performed a PubMed search including the search terms chemosaturation, hepatic chemosaturation, percutaneous perfusion and melphalan.

Results and conclusion CS-PHP is a promising procedure for the treatment of uveal melanoma and cholangiocellular carcinoma.

There are insufficient data regarding the effectiveness of CS-PHP with respect to other tumor entities. Since CS-PHP can be accompanied by multiple transient side effects and complications, close interdisciplinary cooperation is necessary.

Key Points:

- Chemosaturation of the liver is a safe procedure.
- CS-PHP is a potent therapy for hepatic metastatic ocular melanoma and cholangiocellular carcinoma.
- The procedure requires close interdisciplinary coordination.
- CS-PHP is a repeatable and thus long-term therapeutic option for some patients.

Citation Format

- Ebel S, Struck MF, van Boemmel F et al. Chemosaturation of the Liver – an Update. Fortschr Röntgenstr 2023; 195: 30–37

ZUSAMMENFASSUNG

Hintergrund Die Chemosaturation der Leber („percutaneous hepatic perfusion“, CS-PHP) ist eine Behandlungsoption für primäre und sekundäre Lebertumore und aktuell Gegenstand intensiver Forschung. Der vorliegende Artikel soll eine Übersicht über Patientensicherheit, Durchführung und Wirksamkeit der CS-PHP auf Basis des aktuellen Forschungsstandes geben.

Methode Es wurde eine Literaturrecherche in Pubmed mit den Stichwörtern chemosaturation, hepatic chemosaturation, percutaneous hepatic perfusion, und melphalan durchgeführt.

Ergebnisse und Schlussfolgerungen Die CS-PHP stellt ein potentes Verfahren zur Behandlung von hepatisch metastasierten okulären Melanomen und intrahepatischen cholangiozellulären Karzinomen dar. Bezüglich anderer Tumorentitäten ist die Datenlage nicht ausreichend um eine fundierte Aussage treffen zu können. Chemosaturationen können mit vielfältigen Komplikationen und Nebenwirkungen einhergehen, welche jedoch überwiegend vorübergehend bzw. interdisziplinär beherrschbar sind.

Background

Percutaneous chemosaturation of the liver with melphalan is an innovative option for the treatment of non-curable primary and secondary liver tumors. Thus, chemosaturation as a liver-directed, invasive procedure represents an advance in chemoperfusion. Catheter angiography is used to inject the chemotherapeutic agent melphalan directly into the hepatic arteries, thereby “saturating” the tissue and thus the predominantly arterially supplied tumors or metastases (there are no corresponding filter systems for other chemotherapeutic agents to date). In parallel, venous blood from the liver is aspirated via a special double balloon catheter in the inferior vena cava and extracorporeally purified of melphalan via a filter system designed specifically for that drug. The purified blood is then re-infused via jugular access. In this way, it is possible to apply very high doses of chemotherapeutic agent to the liver while keeping systemic side effects low. Melphalan is an alkylating agent that exerts its cytotoxic effect by incorporating alkyl groups into DNA. In the course of chemosaturation, up to 3 mg/kg melphalan, calculated on the idealized body weight, is administered (max. 220 mg/therapy session) [1].

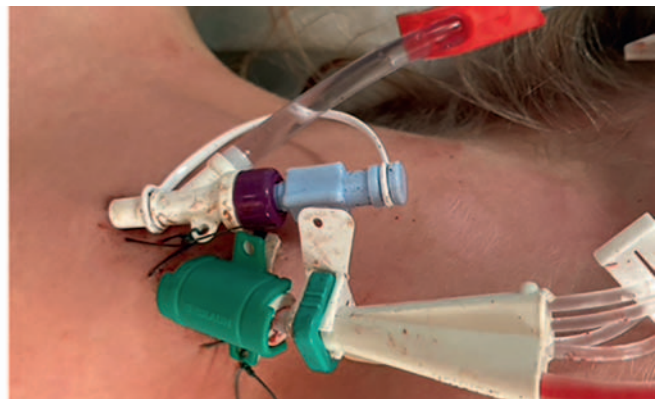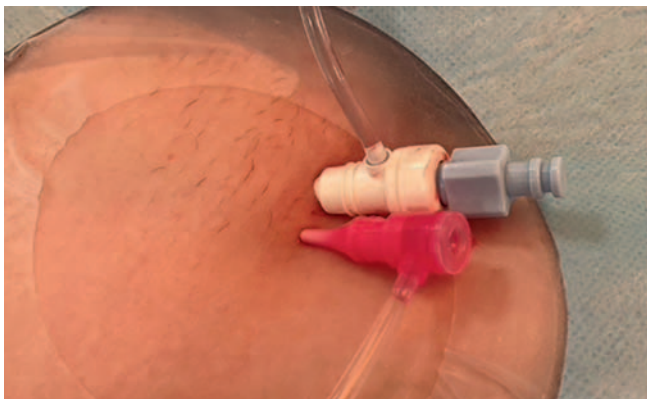Since the introduction of the currently only approved (CE certified in Germany since 2012) commercial filter system (Delcath Systems inc. NY, USA), several single- and multicenter phase I to phase III studies have been published analyzing the efficacy of chemosaturation in different tumor entities, leading in hepatic metastatic uveal melanoma. Even with the filter system of the first generation, a longer survival compared to best available care was shown in patients with hepatic metastatic uveal melanoma. Since 2012, the second-generation filter system with improved melphalan extraction rates has been available, delivering promising results with respect to patient safety [2]. Chemosaturation can currently be used in Germany as part of studies as well as an individual treatment attempt.

This review article is intended to provide an overview of recent development as well as the current status of CS-PHP with regard to patient safety and effectiveness.

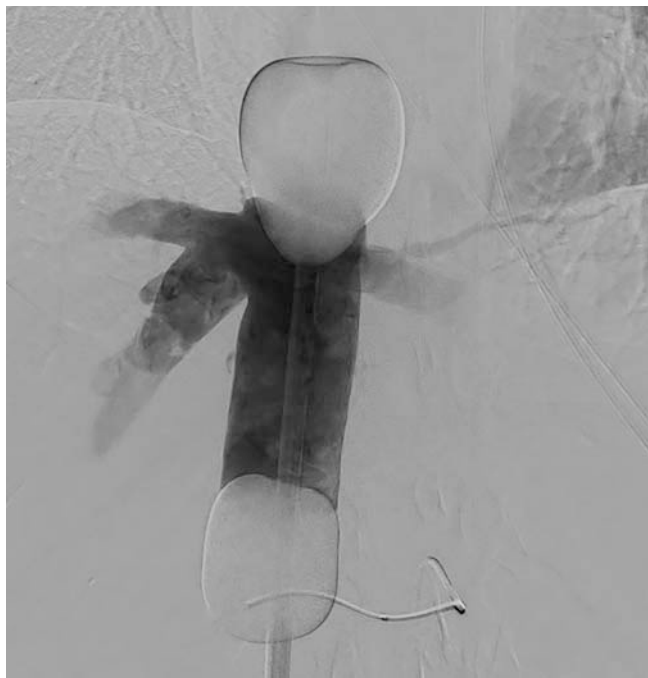Technique

Chemosaturation is performed under general anesthesia and full heparinization (300 IU/kg body weight heparin with target ACT >450 s). A heart-lung machine or, more precisely, a roller pump is required for extracorporeal filtration of the blood. Sheaths are placed in the right common femoral artery (4F), right common femoral vein (18F), and right internal jugular vein (► Fig. 1). For the melphalan injection, a 4F catheter is placed in the celiac trunk or, in the case of anatomical variants, also in the superior mesenteric artery, for example, and then a microcatheter is placed in the corresponding hepatic lobe or segmental artery. A special double balloon catheter (Delcath Systems Inc. NY, USA) is placed in the inferior vena cava to isolate the hepatic veins. First the cranial and then the caudal balloon are inflated to isolate the hepatic veins from the systemic circulation. Blood from the lower half of the body reaches the heart while the inferior vena cava is blocked (approx. 60–90 minutes) via collaterals such as the azygos and hemiazygos systems. The tightness of the balloons is verified using digital subtraction angiography (DSA), demonstrating that special post-processing tools using ROI (region of interest) to measure the contrast agent leakage between the blocking balloons, can help detect leaks [3]. These leak checks should be performed prior to initiating melphalan injection and whenever the arterial catheter is repositioned. The shape and position of the blocking balloons must be observed during the procedure in order to detect any dislocation at an early stage (► Fig. 2). After correct positioning of all catheters, the intra-arterial injection of melphalan follows, whereby the entire liver is treated; in the case of conditions after liver resections, the entire remaining liver is treated [4]. Up to 3 mg/kg melphalan, calculated on the idealized body weight, is administered (max. 220 mg/therapy session) [1].

Venous hepatic blood is then extracted via the double balloon catheter, filtered extracorporeally via a roller pump with filter system operated by a perfusionist and reinfused via the jugular line. Finally, the heparinization can be antagonized with protamine. According to the authors' experience, a therapy session lasts about 120–180 minutes apart from anesthesia induction and recovery [5]. The patient is monitored in the intensive care unit until the following day, where the sheaths are removed after the coagulation



► Fig. 1 Illustration of vascular accesses. Sheaths Right: 18F sheath (white/blue) in the right common femoral vein and 4F sheath (red) in the right common femoral artery. Left: 10F return sheath (white/blue) and central venous catheter (green) in the right internal jugular vein.



► **Fig. 2** Tightness test of the balloon occlusion of the IVC. DSA to check the tightness of the balloon occlusion of the IVC without evidence of leakage.

on has completely normalized. The patients are then usually able to return to the normal ward and can be discharged on the third to fifth post-interventional day. To prevent tumor lysis syndrome, 300 mg/d allopurinol is administered for three days postinterventionally. After discharge (outpatient) laboratory chemical controls are carried out (three times every three days). For control purposes, an MRI with liver-specific contrast agent is performed after 8 weeks. A second session is performed if control shows tumor regression or stable disease. In the authors' treatment center, up to six chemosaturations have been performed in one patient. However, up to eight sessions were reported for one patient; thus it can be concluded that this method is in principle not limited in the frequency of use if therapy is successful and liver function is preserved [4].

Financial Considerations

The cost of chemosaturation is high and is not covered by the DRG (diagnosis related group) system's designated per-case rates. According to the current German OPS catalog (as of 08/21), chemosaturation is coded as "Percutaneous closed organ perfusion with chemotherapeutic agents with external blood filter" (8–549.01). The cost of a therapy session, including material and personnel costs as well as one day's stay in the intensive care unit, is approximately €30 000. Although the procedure is established in appropriate centers and is used with increasing frequency, the costs for it are not generally covered by health insurance companies due to the lack of direct recommendations for chemosaturation in current guidelines. This problem can be addressed by applying for reimbursement prior to initiation of therapy with adequate

justification and a clear statement from an interdisciplinary tumor board explaining the lack of alternative treatment approaches. However, it should be borne in mind that, from experience, reimbursement procedures can take up to 4 weeks and, in the event of progression of the tumor disease, there is a possibility that the patient may subsequently no longer be able to undergo therapy. The steady increase in published data on chemosaturation provides reason to hope for simplification of reimbursement in the future.

Patient Safety

Range of side effects

Recent studies show promising data of CS-PHP, but this procedure can be associated with severe cardiovascular complications, life-threatening bleeding and thromboembolic events [5–7]. Related circulatory instabilities may occur intraprocedurally, requiring differential volume and catecholamine administration [8]. Due to the need for strict anticoagulation during the procedure to avoid thrombosis of the filters (activated clotting time (ACT) target >450 s), bleeding complications are reported in the literature in up to 30% of cases [2, 9]. These include hematoma at the femoral and cervical puncture sites [10, 11], femoral hemorrhages and pseudoaneurysms [12, 13], hemorrhagic gastric ulcers and mucosal hemorrhages [2, 13, 14], as well as abdominal and cerebral hemorrhages [9]. Iatrogenic complications of overinfusion and bleeding may cause swelling of the respiratory tract in rare cases, resulting in delayed extubation and prolonged need for ICU monitoring [5].

One of the most common complications caused by chemosaturation is melphalan-induced bone marrow depression, leading to anemia, thrombocytopenia and leukocytopenia [6]. With the introduction of the second generation filtration system in 2012, both the melphalan extraction rate (from 77% to 86%) was increased compared to that of the first generation, as well as the consistency of filtration performance (from 58%–95% to 71%–96%) was improved [6]. However, melphalan-induced bone marrow depression remains a clinically relevant problem despite improved filters. Thus, Dewald et al. reported clinically relevant thrombocytopenias in up to 87% of cases; grade 3/4 anemias occurred in 40% and leukocytopenia in 10% of patients. In the majority of reported cases, these myelosuppressive effects regenerated within three weeks after the procedure; however, the administration of platelet and red cell concentrates became necessary in 23% and 17% of patients, respectively [8]. Older studies report similar rates of myelosuppressive complications [6]. To counteract postinterventional neutropenia, Schoenfeld et al. implemented preinterventional administration of granulocyte colony-stimulating factor (G-CSF) but did not observe significant improvement [13].

In addition, post-interventional liver damage, which manifests as a transaminase or bilirubin increase, has been described. Thus, transaminase increases of 7% and 48% were reported [2, 14–17]. The rate of clinically relevant hyperbilirubinemia is reported to be up to 15% and appears to correlate with tumor burden [13].

A recent study showed that the side effect spectrum does not change even with repeated sessions (up to six) [5], other data show that up to eight repetitions are possible [4]. Ultimately, the majority of reported adverse events were transient in nature or manageable, and treatment-associated deaths occurred very rarely (< 1%) in the published cohorts (1–15). Accordingly, despite possible complications, both older and recent studies have concluded that chemosaturation is a safe and effective procedure when performed with proper patient selection and in the setting of a specialized center, with experienced radiologists, anesthesiologists, perfusionists (for the pump system), and intensivists (for postinterventional management) [5, 10, 11, 15, 18, 19].

It remains unclear whether high-dose melphalan injections can result in delayed liver damage or whether the hepatic arterial vascular bed suffers long-term damage. These issues should be the subject of further studies in the future.

Patient selection

Currently, chemosaturation is a last-line therapy for liver tumors that cannot be treated curatively, with hepatic metastatic ocular melanoma being of particular importance [9]. In a recent study, Schönfeld et al. provide detailed recommendations on patient selection for “salvage therapy” by chemosaturation, derived from the exclusion criteria of their study: adequate renal and hepatic function (not specified), hemoglobin > 8 g/dL, leukocytes > 2 tsd/ μ l; platelets > 50 tsd/ μ l, serum creatinine > 60 μ mol/l, bilirubin \leq 3 times the upper norm, liver cirrhosis at most Child-Pugh stage A [13]. Hughes et al used the following criteria: Bilirubin < 2.0 mg/dl, platelets > 100 000 μ l, creatinine < 1.5 mg/dl, and liver function test < 10 times normal (neither the exact test nor the parameters studied were provided) [16]. There are no systematic data regarding the management of potential bleeding sites such as old strokes or gastric ulcers. It is recommended to treat only patients with a tumor mass of < 50% of liver volume to minimize the risk of fulminant tumor decay syndrome and to ensure adequate liver reserve [19]. However, there is unanimous agreement that the decision to perform chemosaturation should be discussed individually within the framework of an interdisciplinary tumor conference.

Effectiveness

Overview

Currently, extensive efforts are underway to systematically collect data and prepare clinical studies on chemosaturation. There are multiple patient safety and feasibility studies, as well as phase I and phase II studies in the context of primary and secondary hepatic neoplasms. As of 12/2020, Europe-wide published expertise includes more than 650 chemosaturations in more than 300 patients, with the largest proportion of procedures performed for liver metastases of ocular melanoma (489 procedures in 221 patients), followed by cholangiocellular carcinoma (76 procedures in 42 patients) [20]. According to manufacturer data, over 160 procedures were performed across Europe in 2021 (personal communication from 01/2022). The following is an overview of the therapeutic efficacy of chemosaturation.

Hepatic metastatic ocular melanoma

Surgical resection is recommended for the treatment of hepatic metastatic ocular melanoma in the corresponding S3 guideline (grade B), if it is feasible as R0 resection. No recommendation on adjuvant procedures can be provided due to a lack of data [21].

The majority of published studies describe the efficacy of chemosaturation in non-resectable hepatic metastatic ocular melanoma. This disease is particularly suitable for chemosaturation because it often shows isolated liver metastases that are accessible to the liver-directed regional area of chemosaturation action and are sensitive to melphalan [22, 23] (► **Fig. 3**). In the case of liver metastasis, ocular melanomas are associated with a median overall survival (OS) of 8 months from diagnosis [24–26]; systemic therapy options are limited [27, 28]. Although immune checkpoint inhibitors have led to significantly increased 5-year overall survival rates of 34%–53% in metastatic cutaneous melanoma, they have resulted in an OS of only 10 months in metastatic ocular melanoma. Other transarterial procedures, such as selective internal radiotherapy (SIRT) or transarterial chemoembolization (TACE), are considered safe and result in a mean OS of 8–10 months and 4–9 months [29–32]. A recently published prospective phase II study provides promising data on SIRT in patients with ocular melanoma with a mean OS of 19.2 months [33]. So far, there are no comparative studies on SIRT vs. CS-PHP. The optimal frequency of CS-PHP use has not yet been defined. In this context, it is interesting to see whether regular sequential use of CS-PHP can lead to continued stabilization or remission. Here, in a case collection from our center, we showed that in the majority of patients with OM, treatment at 6–8 week intervals leads to a response [34].

In multiple phase III studies, CS-PHP with melphalan achieved median OS to 27 months and median hepatic progression-free survival (hPFS) up to 11 months [11, 15, 18]. In a prospective randomized multicenter trial, Hughes et al. found an hPFS of 7 months in the chemosaturation group and 1.6 months in the best available care (BAC) group. However, no significant differences were found with respect to OS, and the study is not informative with respect to the comparison of OS due to crossover between subgroups (► **Table 1**) [16]. Currently, a randomized phase I/II study is in progress comparing chemosaturation in combination with ipilimumab/nivolumab versus chemosaturation alone (NCT04 283 890). In addition, another phase III trial (FOCUS) of CS-PHP in ocular melanoma is under way, involving approximately 40 centers in the U.S. and Europe (NCT02 678 572).

Cholangiocellular carcinoma

Resection is the only curative treatment for intrahepatic cholangiocellular carcinoma (ICC), but the majority of ICC cases is already inoperable at diagnosis, making only 10–35% of patients eligible for resection [35–39]. As with hepatic metastatic ocular melanoma, systemic therapy options for ICC are very limited [36, 40]. According to the guideline, all inoperable patients with adequate general condition should be offered systemic therapy, in which a combination of gemcitabine and cisplatin represents the first line and FOLFOX the second line; chemosaturation may be offered if the second line fails [41]. Other transarterial forms of ther-

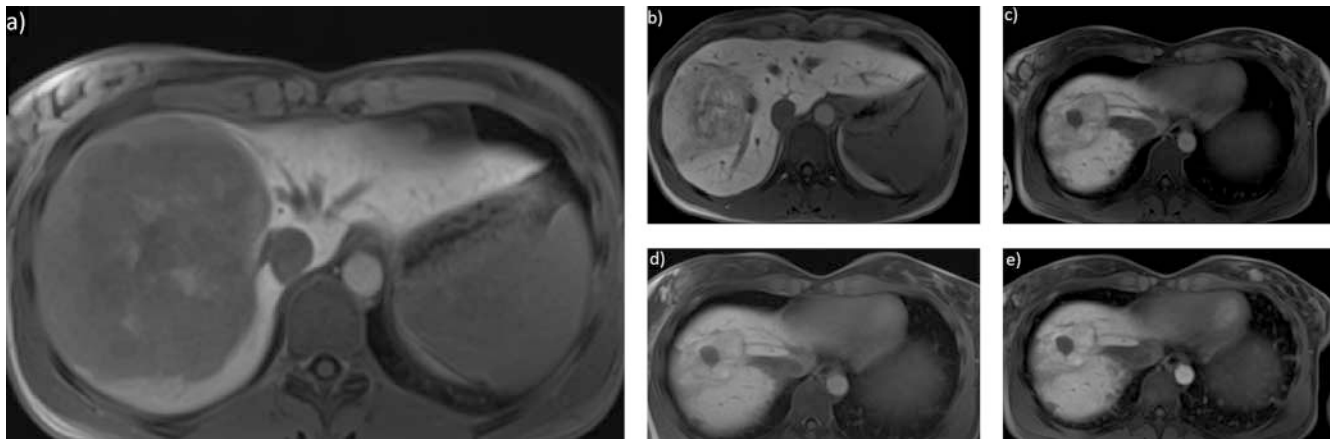


Fig. 3 Therapeutic response after chemosaturation. Image example of a patient with diffuse hepatic metastasis of ocular melanoma. The figure shows a metastasis of > 10 cm in liver segment VII/VIII, and additional disseminated metastases were present on both sides (not shown). T1 VIBE post-contrast, hepatobiliary phase. **a** status before therapy, **b** 8 weeks after first chemosaturation: reduction of tumor burden by > 50 %, **c** 10 weeks after second chemosaturation: reduction of tumor burden by 43 %, **d** and **e** respectively 10 weeks after third and fourth chemosaturation: stable disease in each case.

apy such as SIRT and TACE seem to play a potential role in neoadjuvant concepts or multimodal therapies (e. g. SIRT in combination with systemic chemotherapy) [42].

In 2017, Kirstein et al. in a retrospective analysis described five patients with ICC who were treated by chemosaturation; in these cases an OS of 8 months and hPFS of 135 days were reported [18]. In a more recent study, chemosaturations were evaluated in 15 patients with ICC; local tumor control was achieved in 53 % of cases (OS was 26.9 months after diagnosis and 7.9 months after initial chemosaturation, hPFS was 131 days). Surprisingly, patients with only liver involvement showed a poorer OS than patients with lymph node involvement (12.9 vs. 4.8 months), although the hepatic tumor volume in the groups was not provided in the study [10]. Schoenfeld et al. report on 14 ICC patients treated with chemosaturation and found a complete remission in one case; the longest OS in one patient was 3.7 years after chemosaturation, followed by 3.4 years, 2.8 years and 2.3 years. Three patients are still under therapy and observation [13]. Forty European centers are currently participating in a randomized controlled phase III study on the effectiveness, safety and pharmacokinetic aspects comparing chemosaturation after systemic therapy with cisplatin/gemcitabine versus systemic therapy with cisplatin/gemcitabine alone (NCT03 086 993).

Other tumor entities

Compared to that on ocular melanoma and ICC the data on other tumor entities is significantly limited. By 12/2020, 95 chemosaturations had been documented across Europe in 58 patients for tumors other than ocular melanoma and ICC. Of these, 24 chemosaturations were to colorectal liver metastases, 20 to hepatocellular carcinomas, 14 to liver metastases from pancreatic carcinomas, and 37 to neuroendocrine tumors, cutaneous melanomas, breast carcinomas, and other tumors [2, 9, 10, 16–18, 20, 43]. All these treatments have in common that they were performed in patients for whom other established forms of therapy had already failed; accordingly the results are very heteroge-

neous and of only limited significance. Forster and colleagues report that a partial response was achieved in a patient with hepatic metastatic sarcoma [7]. A 2014 paper describes six patients with cutaneous melanoma who achieved complete remission (n = 3) or partial response (n = 3); in addition the study described one patient with liver metastases from breast cancer and one patient with hepatic metastatic gastric cancer, both of whom achieved a partial response [14]. To date, there are no systematic analyses of patients with the above-mentioned tumor types with sufficient case numbers to make a sound statement on the efficacy of chemosaturation in this context.

Predicting effectiveness

Regarding the predictability of response to therapy, Brüning et al. showed in a recent paper that tumor volume before initiation of therapy correlates negatively with median survival, whereby a threshold of > 50 % tumor relative to liver volume is specified [12]. Estler et al. demonstrated that a tumor burden of < 25 % of liver volume is associated with significantly longer OS [44].

Summary

Liver chemosaturation with melphalan is an innovative treatment procedure for the treatment of primary and secondary liver malignancies. Although data are already available for hepatic metastatic ocular melanoma demonstrating the strong efficacy of this treatment in many patients, there is no high-level evidence yet for other tumors, but there are numerous promising case collections and anecdotal reports. Therefore, the use of this method is currently the subject of intensive research.

A solid body of data is available on patient safety and periprocedural management. Even with the second-generation filter system, intra- and postprocedural anemias, thrombopenias, and leukocytopenias are to be expected and may be the result of transient bone marrow depression due to high-dose melphalan

► Table 1 Overview of studies about CS-PHP in patients with hepatic metastasis of uveal melanoma.									
Authors	Publication year	Title	Study design	Number of patients	Mean number of chemosaturations	Mean hepatic non-progressive survival	Mean survival	Best response (Number of patients)	
Kirstein et al.	2017	Safety and efficacy of chemosaturation in patients with primary and secondary liver tumors	Retrospective, single-center	12	n.a.	117 days	n.a.	PR (4)	
Vogl et al.	2017	Percutaneous Isolated Hepatic Perfusion as a Treatment for Isolated Hepatic Metastases of Uveal Melanoma: Patient Outcome and Safety in a Multi-centre Study	Retrospective, multicenter	18	n.a.	9.6 months	12.4 months	PR (8)	
Karydis et al.	2018	Percutaneous hepatic perfusion with melphalan in uveal melanoma: A safe and effective treatment modality in an orphan disease	Retrospective, multicenter	51	n.a.	9.1 months	15.3 months	CR (3)	
Brüning et al.	2020	Unresectable Hepatic Metastasis of Uveal Melanoma: Hepatic Chemosaturation with High-Dose Melphalan—Long-Term Overall Survival Negatively Correlates with Tumor Burden	Retrospective, single-center	19	2	n.a.	16.7 months	PR (10)	
Hughes et al.	2016	Results of a Randomized Controlled Multicenter Phase III Trial of Percutaneous Hepatic Perfusion Compared with Best Available Care for Patients with Melanoma Liver Metastases	Prospective, multicenter	44	3	7 months	10.6 months	PR (16)	
Schönfeld et al.	2020	Chemosaturation with percutaneous hepatic perfusion is effective in patients with ocular melanoma and cholangiocarcinoma	Retrospective, single-center	30		6 months	12 months	PR (11)	
Veelken et al.	2021	Repeated percutaneous hepatic perfusion with melphalan can maintain long-term response in patients with liver cancers	Retrospective, single-center	13	3	326 days	n.a.	CR (3)	

application. In addition, transient liver dysfunction with transaminase elevations and hyperbilirubinemia may occur. Despite the possible complications, chemosaturations is a safe and effective procedure when performed with appropriate patient selection in specialized institutions. It can be stated that chemosaturations represents a promising procedure for the treatment of unresectable liver metastases of ocular melanomas and of cholangiocellular carcinomas, which requires close interdisciplinary collaboration. Patients with a diffuse hepatic involvement with a tumor mass of > 50% of the liver volume seem to benefit from the therapy. Multiple studies have shown that chemosaturations in this setting can significantly prolong median survival as well as median progression-free survival. Promising data exist to some extent on other hepatic neoplasms, but there are few systematic analyses. Studies are currently underway that shed light on the benefits of chemosaturations in combination with systemic therapies.

Conflict of Interest

The authors declare that they have no conflict of interest.

References

- [1] Inc D Hepatic Delivery System Instructions for Use.
- [2] Meijer TS, Burgmans MC, Fiocco M et al. Safety of Percutaneous Hepatic Perfusion with Melphalan in Patients with Unresectable Liver Metastases from Ocular Melanoma Using the Delcath Systems' Second-Generation Hemofiltration System: A Prospective Non-randomized Phase II Trial. *Cardiovasc Intervent Radiol* 2019; 42: 841–852. doi:10.1007/s00270-019-02177-x
- [3] Dewald CLA, Meine TC, Winther HMB et al. Chemosaturations Percutaneous Hepatic Perfusion (CS-PHP) with Melphalan: Evaluation of 2D-Perfusion Angiography (2D-PA) for Leakage Detection of the Venous Double-Balloon Catheter. *Cardiovasc Intervent Radiol* 2019; 42: 1441–1448. doi:10.1007/s00270-019-02243-4
- [4] Dewald CLA, Becker LS, Maschke SK et al. Percutaneous isolated hepatic perfusion (chemosaturations) with melphalan following right hemihepatectomy in patients with cholangiocarcinoma and metastatic uveal melanoma: peri- and post-interventional adverse events and therapy response compared to a matched group without prior liver surgery. *Clin Exp Metastasis* 2020; 37: 683–692. doi:10.1007/s10585-020-10057-9
- [5] Struck MF, Kliem P, Ebel S et al. Percutaneous hepatic melphalan perfusion: Single center experience of procedural characteristics, hemodynamic response, complications, and postoperative recovery. *PLoS One* 2021; 16. doi:10.1371/journal.pone.0254817
- [6] de Leede EM, Burgmans MC, Meijer TS et al. Prospective Clinical and Pharmacological Evaluation of the Delcath System's Second-Generation (GEN2) Hemofiltration System in Patients Undergoing Percutaneous Hepatic Perfusion with Melphalan. *Cardiovasc Intervent Radiol* 2017; 40: 1196–1205. doi:10.1007/s00270-017-1630-4
- [7] Forster MR, Rashid OM, Perez MC et al. Chemosaturations with percutaneous hepatic perfusion for unresectable metastatic melanoma or sarcoma to the liver: A single institution experience. *J Surg Oncol* 2014; 109: 434–439. doi:10.1002/jso.23501
- [8] Dewald CLA, Hinrichs JB, Becker LS et al. Chemosaturations with Percutaneous Hepatic Perfusion: Outcome and Safety in Patients with Metastatic Uveal Melanoma. *RöFo – Fortschritte auf dem Gebiet der Röntgenstrahlen und der Bildgeb Verfahren* 2021; 193: 928–936. doi:10.1055/a-1348-1932
- [9] Karydis I, Gangi A, Wheeler MJ et al. Percutaneous hepatic perfusion with melphalan in uveal melanoma: A safe and effective treatment modality in an orphan disease. *J Surg Oncol* 2018; 117: 1170–1178. doi:10.1002/jso.24956
- [10] Marquardt S, Kirstein MM, Brüning R et al. Percutaneous hepatic perfusion (chemosaturations) with melphalan in patients with intrahepatic cholangiocarcinoma: European multicentre study on safety, short-term effects and survival. *Eur Radiol* 2019; 29: 1882–1892. doi:10.1007/s00330-018-5729-z
- [11] Vogl TJ, Koch SA, Lotz G et al. Percutaneous Isolated Hepatic Perfusion as a Treatment for Isolated Hepatic Metastases of Uveal Melanoma: Patient Outcome and Safety in a Multi-centre Study. *Cardiovasc Intervent Radiol* 2017; 40: 864–872. doi:10.1007/s00270-017-1588-2
- [12] Brüning R, Tiede M, Schneider M et al. Unresectable Hepatic Metastasis of Uveal Melanoma: Hepatic Chemosaturations with High-Dose Melphalan – Long-Term Overall Survival Negatively Correlates with Tumor Burden. *Radiol Res Pract* 2020; 2020: 1–7. doi:10.1155/2020/5672048
- [13] Schönfeld L, Hinrichs JB, Marquardt S et al. Chemosaturations with percutaneous hepatic perfusion is effective in patients with ocular melanoma and cholangiocarcinoma. *J Cancer Res Clin Oncol* 2020; 146: 3003–3012. doi:10.1007/s00432-020-03289-5
- [14] Vogl TJ, Zangos S, Scholtz JE et al. Chemosaturations with percutaneous hepatic perfusions of melphalan for hepatic metastases: experience from two European centers. *Rofo* 2014; 186: 937–944. doi:10.1055/s-0034-1366081
- [15] Artzner C, Mossakowski O, Hefferman G et al. Chemosaturations with percutaneous hepatic perfusion of melphalan for liver-dominant metastatic uveal melanoma: A single center experience. *Cancer Imaging* 2019; 19: 1–8. doi:10.1186/s40644-019-0218-4
- [16] Hughes MS, Zager J, Faries M et al. Results of a Randomized Controlled Multicenter Phase III Trial of Percutaneous Hepatic Perfusion Compared with Best Available Care for Patients with Melanoma Liver Metastases. *Ann Surg Oncol* 2016; 23: 1309–1319. doi:10.1245/s10434-015-4968-3
- [17] Pingpank JF, Libutti SK, Chang R et al. Phase I Study of Hepatic Arterial Melphalan Infusion and Hepatic Venous Hemofiltration Using Percutaneously Placed Catheters in Patients With Unresectable Hepatic Malignancies. *J Clin Oncol* 2008; 23: 3465–3474. doi:10.1021/nn2045246. Multifunctional
- [18] Kirstein MM, Marquardt S, Jedicke N et al. Safety and efficacy of chemosaturations in patients with primary and secondary liver tumors. *J Cancer Res Clin Oncol* 2017; 143: 2113–2121. doi:10.1007/s00432-017-2461-z
- [19] Carr MJ, Sun J, Cohen JB et al. Over 12 Years Single Institutional Experience Performing Percutaneous Hepatic Perfusion for Unresectable Liver Metastases. *Cancer Control* 2020; 27: 1–9. doi:10.1177/1073274820983019
- [20] Ferrucci PF, Cocorocchio E, Bonomo G et al. A New Option for the Treatment of Intrahepatic Cholangiocarcinoma: Percutaneous Hepatic Perfusion with CHEMOSAT Delivery System. *Cells* 2021; 10. doi:10.3390/cells10010070
- [21] Onkologie L. S3-Leitlinie Früherkennung, Therapie und Nachsorge des Melanomes. 2020: 1–400
- [22] Feldman ED, Pingpank JF, Alexander HR. Regional treatment options for patients with ocular melanoma metastatic to the liver. *Ann Surg Oncol* 2004; 11: 290–297. doi:10.1245/ASO.2004.07.004
- [23] Jovanovic P, Mihajlovic M, Djordjevic-Jocic J et al. Ocular melanoma: An overview of the current status. *Int J Clin Exp Pathol* 2013; 6: 1230–1244
- [24] Gragoudas ES, Egan KM, Seddon JM et al. Survival of Patients with Metastases from Uveal Melanoma. *Ophthalmology* 1991; 98: 383–390. doi:10.1016/S0161-6420(91)32285-1
- [25] Carvajal RD, Schwartz GK, Tezel T et al. Metastatic disease from uveal melanoma: Treatment options and future prospects. *Br J Ophthalmol* 2017; 101: 38–44. doi:10.1136/bjophthalmol-2016-309034

- [26] Hawkins BS. The COMS randomized trial of iodine 125 brachytherapy for choroidal melanoma: V. Twelve-year mortality rates and prognostic factors: COMS report No. 28. *Arch Ophthalmol* 2006; 124: 1684–1693
- [27] Triozzi PL, Singh AD. Adjuvant Therapy of Uveal Melanoma: Current Status. *Ocul Oncol Pathol* 2015; 1: 54–62. doi:10.1159/000367715
- [28] Khoja L, Atenafu EG, Joshua AM. Meta-analysis of phase II trials in metastatic uveal melanoma (MUM) to determine progression-free (PFS) and overall survival (OS) benchmarks for future phase II trials: An irco-ocular melanoma initiative. *J Clin Oncol* 2016; 34: 9567. doi:10.1200/JCO.2016.34.15_suppl.9567
- [29] Xing M, Prajapati HJ, Dhanasekaran R et al. Selective internal yttrium-90 radioembolization therapy (90Y-SIRT) versus best supportive care in patients with unresectable metastatic melanoma to the liver refractory to systemic therapy. *Am J Clin Oncol* 2017; 40: 27–34
- [30] Memon K, Kuzel TM, Vouche M et al. Hepatic yttrium-90 radioembolization for metastatic melanoma: A single-center experience. *Melanoma Res* 2014; 24: 244–251. doi:10.1097/CMR.0000000000000051
- [31] Gupta S, Bedikian AY, Ahrar J et al. Hepatic artery chemoembolization in patients with ocular melanoma metastatic to the liver: Response, survival, and prognostic factors. *Am J Clin Oncol Cancer Clin Trials* 2010; 33: 474–480. doi:10.1097/COC.0b013e3181b4b065
- [32] Ahrar J, Gupta S, Ensor J et al. Response, survival, and prognostic factors after hepatic arterial chemoembolization in patients with liver metastases from cutaneous melanoma. *Cancer Invest* 2011; 29: 49–55
- [33] Gonsalves CF, Eschelmann DJ, Adamo RD et al. A prospective Phase II trial of radioembolization for treatment of uveal melanoma hepatic metastasis. *Radiology* 2019; 293: 223–231. doi:10.1148/radiol.2019190199
- [34] Veelken R, Maiwald B, Strocka S et al. Repeated percutaneous hepatic perfusion with melphalan can maintain long-term response in patients with liver cancers. *Cardiovasc Intervent Radiol In Press* 2021
- [35] Khan SA, Tavorali S, Brandi G. Cholangiocarcinoma: Epidemiology and risk factors. *Liver Int* 2019; 39: 19–31. doi:10.1111/liv.14095
- [36] Benson AB, D'Angelica MI, Abbott DE et al. Hepatobiliary cancers, Version 2.2021. *JNCCN J Natl Compr Cancer Netw* 2021; 19: 541–565. doi:10.6004/jnccn.2021.0022
- [37] Rizvi S, Khan SA, Hallemeier CL et al. Cholangiocarcinoma – evolving concepts and therapeutic strategies. *Nat Rev Clin Oncol* 2018; 15: 95–111. doi:10.1038/nrclinonc.2017.157
- [38] Weber SM, Jarnagin WR, Klimstra D et al. Intrahepatic Cholangiocarcinoma: resectability, recurrence pattern, and outcomes 1 1No competing interests declared. *J Am Coll Surg* 2001; 193: 384–391. doi:10.1016/S1072-7515(01)01016-X
- [39] Jarnagin WR, Fong Y, DeMatteo RP et al. Staging, resectability, and outcome in 225 patients with hilar cholangiocarcinoma. *Ann Surg* 2001; 234: 507–519. doi:10.1097/00000658-200110000-00010
- [40] Bridgewater J, Galle PR, Khan SA et al. Guidelines for the diagnosis and management of intrahepatic cholangiocarcinoma. *J Hepatol* 2014; 60: 1268–1289. doi:10.1016/j.jhep.2014.01.021
- [41] Onkologie L. Konsultationsfassung Diagnostik und Therapie des Hepatozellulären Karzinoms und biliärer Karzinome Wesentliche Neuerungen in der Leitlinie zur Diagnostik und Therapie des hepatozellulären Karzinoms. 2021: 1–205
- [42] Akateh C, Ejaz AM, Pawlik TM et al. Neoadjuvant treatment strategies for intrahepatic cholangiocarcinoma. *World J Hepatol* 2020; 12: 693–708. doi:10.4254/wjh.v12.i10.693
- [43] Pingpank JF, Hughes MS, Alexander HR et al. A phase III random assignment trial comparing percutaneous hepatic perfusion with melphalan (PHP-mel) to standard of care for patients with hepatic metastases from metastatic ocular or cutaneous melanoma. *J Clin Oncol* 2010; 28: LBA8512–LBA8512. doi:10.1200/jco.2010.28.18_suppl.lba8512
- [44] Estler A, Artzner C, Nikolaou K et al. Vorhersage des Tumoransprechens und Gesamtüberleben nach Chemosaturation bei hepatisch metastasiertem Aderhautmelanom. *RöFo – Fortschritte auf dem Gebiet der Röntgenstrahlen und der Bildgeb Verfahren* 2021; 1: 10