

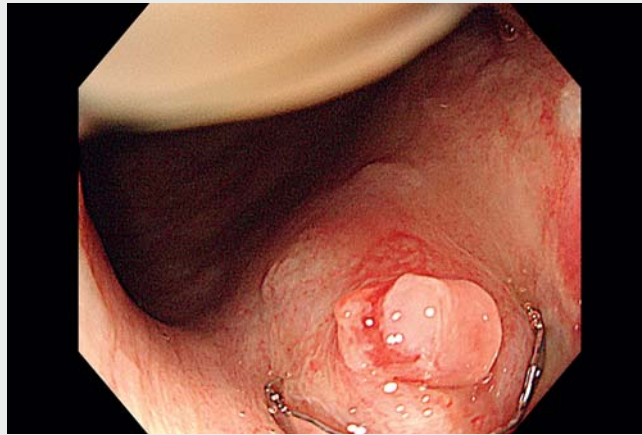
Delayed-onset bleeding after transrectal prostate biopsy presenting as a rectal Dieulafoy's lesion

OPEN
ACCESS

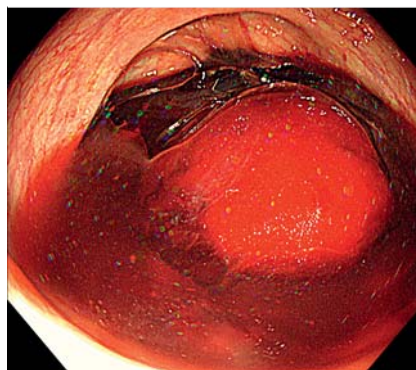
Rectal bleeding is a well-known adverse event related to transrectal prostate biopsy, with a frequency ranging from 0% to 37% [1]. Most bleeding is mild and resolves with conservative management. Severe bleeding, affecting up to 1% of patients undergoing transrectal prostate biopsy, is uncommon but can be life-threatening [2]. Rectal bleeding typically occurs immediately after the biopsy. Delayed-onset bleeding is rare although several cases have been reported [3,4]. Herein, we present a case of delayed-onset severe bleeding after transrectal prostate biopsy, which was successfully treated with endoscopic clipping (▶ **Video 1**).

A 77-year-old man with a high prostate-specific antigen level underwent transrectal prostate biopsy. The patient developed hematochezia and hemorrhagic shock 5 days after the biopsy. The blood test revealed a drop in the hemoglobin level from 13.6 to 8.2 g/dL. The patient was referred to our department because digital compression did not achieve hemostasis. Emergency colonoscopy revealed a massive fresh clot in the rectum (▶ **Fig. 1**), and we identified a pulsatile large-caliber vessel on the anterior wall of the rectum (▶ **Fig. 2**). The vessel was surrounded by normal mucosa, which confirmed the diagnosis of Dieulafoy's lesion (▶ **Fig. 3**). We performed endoscopic hemostasis with clipping (▶ **Fig. 4**). Active bleeding was observed when we placed the first clip; however, a total of three clips achieved hemostasis. The patient had no further bleeding and was discharged without additional interventions.

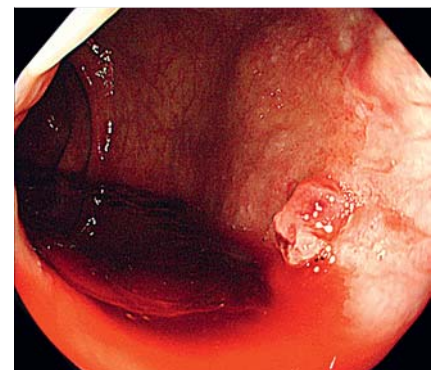
Interestingly, in this case, delayed-onset bleeding presented as Dieulafoy's lesion. The mucosal defect created by the biopsy needle might have caused the exposure of the underlying submucosal artery to the rectal lumen. A recent case-based systematic review reported the efficacy of endoscopic therapy for severe bleed-



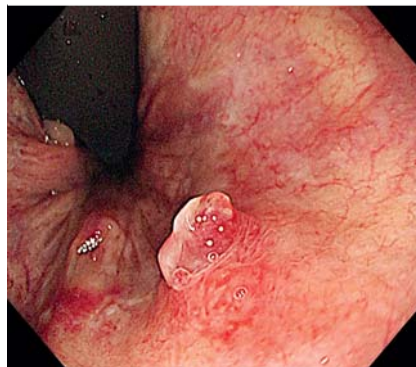
▶ **Video 1** Endoscopic diagnosis and treatment for delayed-onset rectal bleeding after transrectal prostate biopsy presenting as a rectal Dieulafoy's lesion.



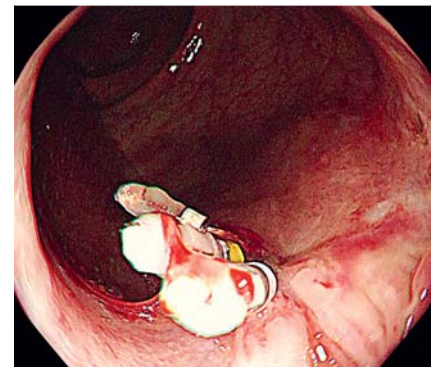
▶ **Fig. 1** Massive fresh clot in the rectum.



▶ **Fig. 2** Forward view of a pulsatile, large-caliber vessel on the anterior wall of the rectum.



▶ **Fig. 3** Retroflex view of the protruding vessel surrounded by normal mucosa.



▶ **Fig. 4** Endoscopic image after endoscopic clipping for hemostasis.

ing after transrectal prostate biopsy [5]. In addition, this case highlights the importance of early endoscopic intervention to improve the patient's outcome in such cases.

Endoscopy_UCTN_Code_TTT_1AQ_2AZ

Acknowledgment

We would like to thank Editage (www.editage.jp) for English language editing.

Funding

This study was supported in part by Grant-in-Aid for Young Investigators from Japan Society for Promotion of Science JSPS KAKENHI 22K16001

Competing interests

The authors declare that they have no conflict of interest.

The authors

Mitsunobu Saito¹, Gota Sudo^{1,2}, Hiroyuki Inoue¹, Yumemi Takada¹, Katsuyoshi Miura¹, Atsushi Yawata¹, Hiroshi Nakase²

- 1 Department of Gastroenterology and Hepatology, Hakodate Goryoukaku Hospital, Hakodate, Japan
- 2 Department of Gastroenterology and Hepatology, Sapporo Medical University School of Medicine, Sapporo, Japan

Corresponding author

Gota Sudo, MD

Department of Gastroenterology and Hepatology, Hakodate Goryoukaku Hospital, 3-38, Goryoukaku-cho, Hakodate 040-8611, Japan
gotasudo@gmail.com

References

- [1] Quinlan MR, Bolton D, Casey RG. The management of rectal bleeding following transrectal prostate biopsy: a review of the current literature. *Can Urol Assoc J* 2018; 12: E146–E153
- [2] Brullet E, Guevara MC, Campo R et al. Massive rectal bleeding following transrectal ultrasound-guided prostate biopsy. *Endoscopy* 2000; 32: 792–795
- [3] Ustündağ Y, Yeşilli C, Aydemir S et al. A life-threatening hematochesia after transrectal ultrasound-guided prostate needle biopsy in a prostate cancer case presenting with lymphedema. *Int Urol Nephrol* 2004; 36: 397–400
- [4] Ando T, Watanabe K, Mizusawa T et al. Late-onset rectal bleeding with hemorrhagic shock after transrectal prostate needle biopsy. *Urol Case Rep* 2018; 21: 41–43
- [5] Malik A, Ishtiaq R, Goraya MHN et al. Endoscopic therapy in the management of patients with severe rectal bleeding following transrectal ultrasound-guided prostate biopsy: a case-based systematic review. *J Investig Med High Impact Case Rep* 2021; 9: 23247096211013206. doi:10.1177/23247096211013206

Bibliography

Endoscopy 2022; 54: E873–E874

DOI 10.1055/a-1858-4893

ISSN 0013-726X

published online 24.6.2022

© 2022. The Author(s).

This is an open access article published by Thieme under the terms of the Creative Commons Attribution-NonDerivative-NonCommercial License, permitting copying and reproduction so long as the original work is given appropriate credit. Contents may not be used for commercial purposes, or adapted, remixed, transformed or built upon. (<https://creativecommons.org/licenses/by-nc-nd/4.0/>)

Georg Thieme Verlag KG, Rüdigerstraße 14, 70469 Stuttgart, Germany



ENDOSCOPY E-VIDEOS

<https://eref.thieme.de/e-videos>



Endoscopy E-Videos is an open access online section, reporting on interesting cases

and new techniques in gastroenterological endoscopy. All papers include a high quality video and all contributions are freely accessible online. Processing charges apply (currently EUR 375), discounts and wavers acc. to HINARI are available.

This section has its own submission website at

<https://mc.manuscriptcentral.com/e-videos>