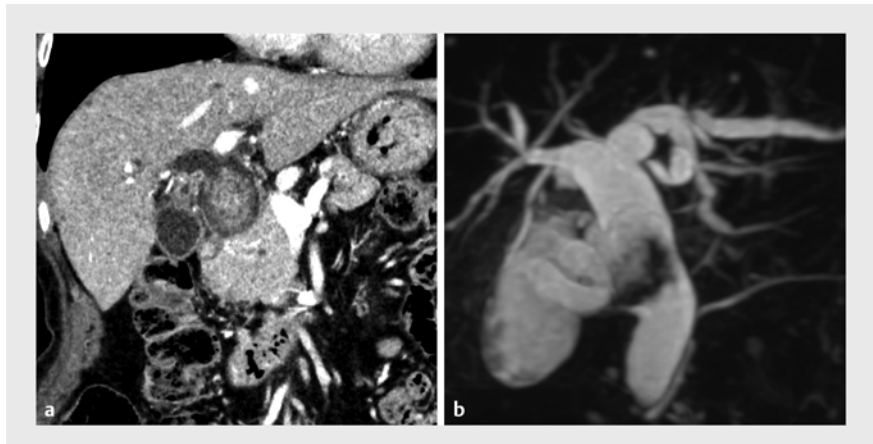


Electrohydraulic lithotripsy using peroral cholangioscopy for impaction stone complex around biliary plastic stent

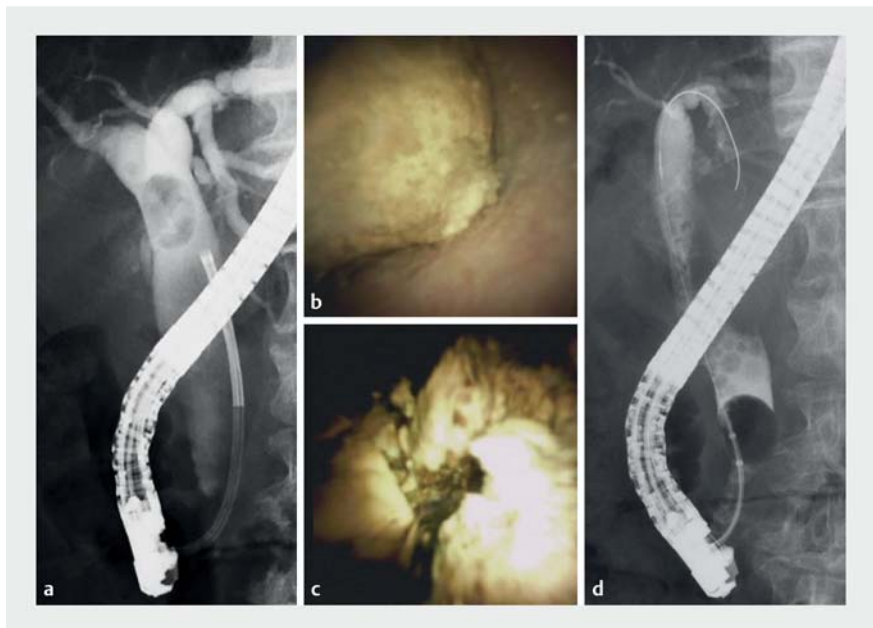
OPEN
ACCESS

A stent-stone complex is a rare complication of long-term placement of biliary plastic stents [1, 2]. Stones form around the proximal end of the stent, making endoscopic removal of the stent difficult. Herein we report a case of successful endoscopic removal of a stent-stone complex using peroral cholangioscopy-guided electrohydraulic lithotripsy (EHL). An 80-year-old woman was referred to our hospital for treatment of large bile duct stones (35 mm) (► Fig. 1). Peroral cholangioscopy-guided EHL was performed; however, stones could not be completely removed, and a plastic stent was placed (► Fig. 2). Two months after peroral cholangioscopy-guided EHL, a 30-mm stent-stone complex formed (► Fig. 3 a). We attempted to remove the stent-stone complex with grasping forceps; however, it could not be moved, and the plastic stent broke off at the grasping site (► Fig. 3 b). We performed EHL again under peroral cholangioscopy (SpyScope DS II; Boston Scientific, Tokyo, Japan) for stent-stone complex extraction (► Video 1). A stent-stone complex resembling a lollipop was observed in the distal bile duct (► Fig. 3 c). The stone was fixed by the stent; this allowed the shock waves to be applied efficiently. The time taken to crush the stones around the plastic stent was approximately 10 min. The stones were then removed using a balloon catheter (► Fig. 3 d). Balloon cholangiography after stone evacuation confirmed complete removal of the stones (► Fig. 3 e). The patient recovered without cholangitis or bile duct stone recurrence.

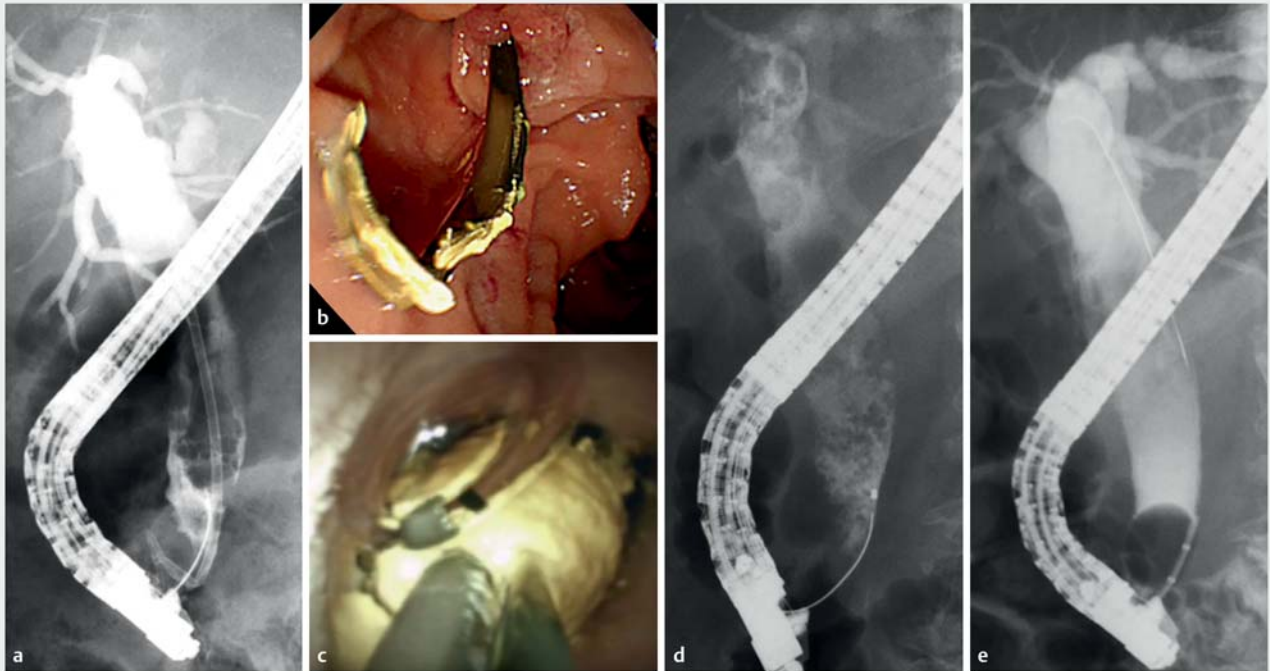
Endoscopic removal of a stent-stone complex is difficult, and forcible extraction of a large stent-stone complex can cause papillary injury or biliary perforation. Further, surgery for a stent-stone



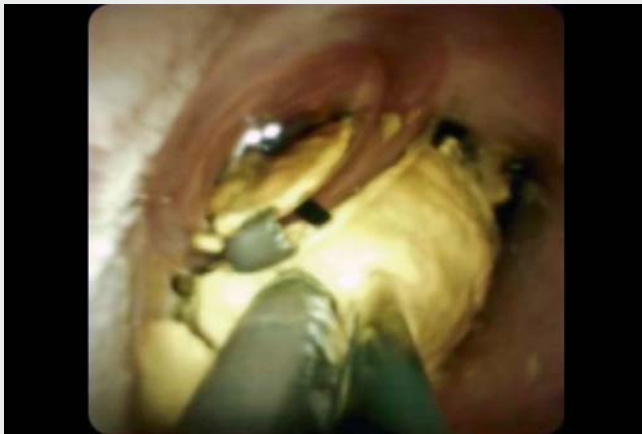► Fig. 1 Computed tomography (CT) and magnetic resonance cholangiopancreatography (MRCP) images before the procedures. **a** Coronal view on CT showed a large stone in the common bile duct. **b** MRCP showed a defect suggestive of a 32-mm stone at the junction of the cystic duct and the common bile duct.



► Fig. 2 The first electrohydraulic lithotripsy (EHL) under endoscopic retrograde cholangiopancreatography (ERCP). **a** ERCP showed a huge translucent filling defect in the common bile duct. **b, c** The presence of a yellow stone was confirmed by cholangioscopy and EHL was performed. **d** After EHL, the stones were removed with a balloon catheter; however, it was difficult to remove them completely.



► **Fig. 3** The second electrohydraulic lithotripsy (EHL) under endoscopic retrograde cholangiopancreatography (ERCP) for removal of the stent-stone complex. **a** The stent-stone complex was formed. **b** The stent was broken off during removal. **c** EHL was performed for stent-stone complex removal. **d** The stones were crushed for only approximately 10 minutes. **e** The stones were removed with a balloon catheter, and cholangiography confirmed that there were no residual stones.



► **Video 1** The procedure of electrohydraulic lithotripsy using peroral cholangioscopy for removal of a stent-stone complex.

complex [3,4] is highly invasive. In this case, EHL under peroral cholangioscopy efficiently crushed the stent-stone complex because the plastic stent served as an anchor. We believe that peroral chol-

angioscopy-guided EHL is an extremely useful method for stent-stone complex removal.

Endoscopy_UCTN_Code_TTT_1AR_2AH

Competing interests

The authors declare that they have no conflict of interest.

The authors

Yuta Tanimoto, Shota Harai, Mitsuharu Fukasawa, Ei Takahashi, Shinichi Takano, Nobuyuki Enomoto

First Department of Internal Medicine, Faculty of Medicine Graduate School of Medicine, University of Yamanashi, Chuo City, Japan

Corresponding author

Mitsuharu Fukasawa, MD

University of Yamanashi, Faculty of Medicine Graduate School of Medicine, First Department of Internal medicine, 1110 Shimokato, Chuo City, Yamanashi, Japan
 Fax: +81-55-273-7108
 fmitsu@yamanashi.ac.jp

References

- [1] Tang SJ, Armstrong L, Lara LF et al. De novo stent-stone complex after long-term biliary stent placement: pathogenesis, diagnosis, and endotherapy. *Gastrointest Endosc* 2007; 66: 193–200
- [2] Morimachi M, Ogawa M, Yokota M et al. Successful endoscopic removal of a biliary stent with stent-stone complex after long-term migration. *Case Rep Gastroenterol* 2019; 13: 113–117
- [3] Barai V, Hedawoo J, Changole S. Forgotten CBD stent (102 months) with stone-stent complex: a case report. *Int J Surg Case Rep* 2017; 30: 162–164
- [4] Upwanshi MH, Shaikh ST, Ghetla SR et al. De novo choledocholithiasis in retained common bile duct stent. *J Clin Diagn Res* 2015; 9: PD17–PD18

Bibliography

Endoscopy 2022; 54: E920–E922

DOI 10.1055/a-1858-5028

ISSN 0013-726X

published online 5.7.2022

© 2022. The Author(s).

This is an open access article published by Thieme under the terms of the Creative Commons Attribution-NonDerivative-NonCommercial License, permitting copying and reproduction so long as the original work is given appropriate credit. Contents may not be used for commercial purposes, or adapted, remixed, transformed or built upon. (<https://creativecommons.org/licenses/by-nc-nd/4.0/>)

Georg Thieme Verlag KG, Rüdigerstraße 14,
70469 Stuttgart, Germany



ENDOSCOPY E-VIDEOS

<https://eref.thieme.de/e-videos>



Endoscopy E-Videos is an open access online section, reporting on interesting cases and new techniques in gastroenterological endoscopy. All papers include a high quality video and all contributions are freely accessible online. Processing charges apply (currently EUR 375), discounts and waivers acc. to HINARI are available.

This section has its own submission website at <https://mc.manuscriptcentral.com/e-videos>