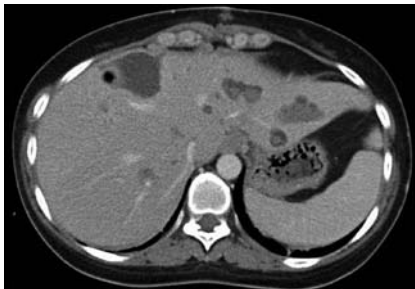
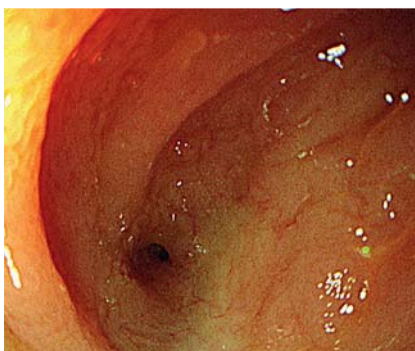
Direct large flow of venous gas into right atrium and ventricle during endoscopic biliary treatment

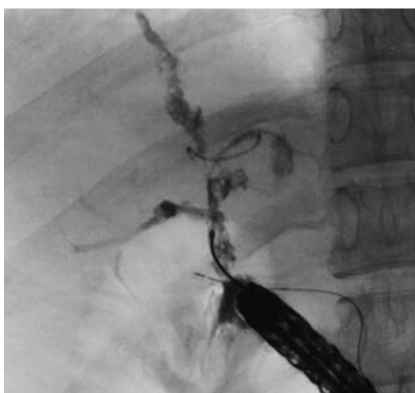OPEN
ACCESS



► **Fig. 1** Many intrahepatic stones were removed during surgery, but numerous stones remained.

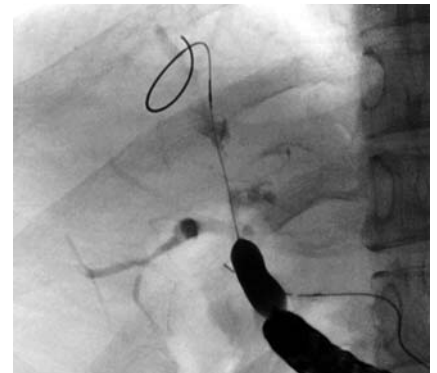


► **Fig. 2** Biliary-jejunal fistula was stenotic.



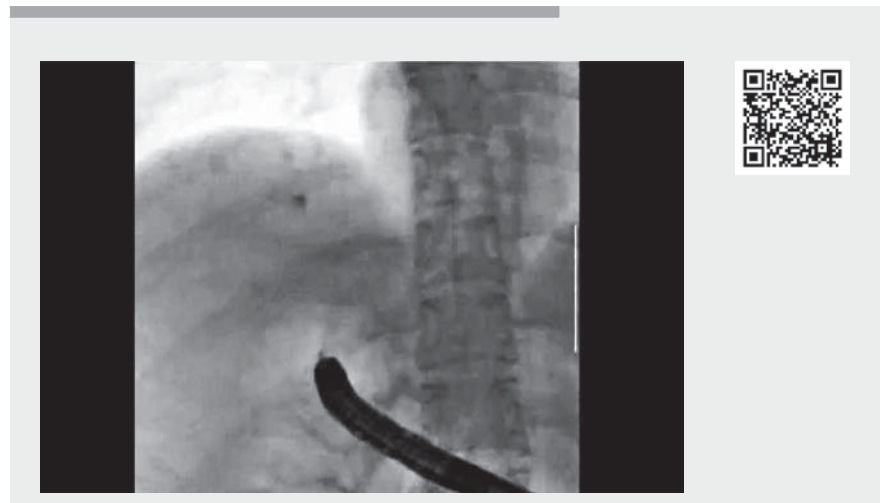
► **Fig. 3** Endoscopic cholangiography showed multiple biliary strictures with small stones.

The patient, a 32-year-old woman, had undergone partial resection of the left lobe of the liver and extrahepatic bile duct with choledochojejunostomy for numerous intrahepatic biliary stones due to primary sclerosing cholangitis (► **Fig. 1**). An afferent loop of jejunum–cutaneous fistula had also been surgically created for additional endoscopic treatment. Three months after surgery, we attempted endoscopic removal of the remaining stones using the jejunocutaneous fistula. An endoscope was inserted through the fistula to reach the biliary–jejunal fistula (► **Fig. 2**). Cholangiography showed multiple biliary strictures (► **Fig. 3**). Several strictures were dilated with 1-mm to 8-mm balloons inflated using carbon dioxide (► **Fig. 4**). When the balloon dilator was deflated and removed, fluoroscopy showed gas entering the right ventricle. No abnormal bleeding occurred from the bile duct. The endoscope was immediate-



► **Fig. 4** A stenotic part of the bile duct being dilated with an 8-mm balloon dilator.

ly removed from the jejunal–cutaneous fistula. Fluoroscopic investigation revealed no continuous leakage of gas into the ventricle (► **Video 1**). Fortunately, computed tomography showed no sign of gas embolism in the various organs.



► **Video 1** During an attempt at endoscopic removal of stones from a stenotic intrahepatic bile duct, the duct was sought using a guidewire. Several strictures were dilated, but when the balloon dilator was deflated and removed, fluoroscopy showed gas entering the right ventricle.


In this case, we speculate that, during the search using the guidewire, the guidewire had broken through from the bile duct into the hepatic vein. A large amount of gas then flowed into the bile duct from the intestinal tract and leaked into the hepatic vein because of dilation between the intrahepatic bile duct and intrahepatic vein. When a large amount of air enters the right atrium and ventricle, it is known to move to the left atrium and ventricle without being absorbed in the lungs, leading to air embolism in the brain [1]. It was fortunate in this case that carbon dioxide was used for the gas supply [2]. Awareness of the possibility of the event presented in this video may help clinicians to spot its occurrence early and manage the situation before it deteriorates further.

Endoscopy_UCTN_Code_TTT_1AR_2AK

Competing interests

The authors declare that they have no conflict of interest.

The authors

Koki Hoshi , **Keiichi Tominaga**, **Naoya Izawa**, **Akira Yamamiya**, **Kazunori Nagashima**, **Takahito Minaguchi**, **Atsushi Irisawa**

Department of Gastroenterology, Dokkyo Medical University School of Medicine, Mibu, Tochigi, Japan

Corresponding author

Keiichi Tominaga, MD, PhD

Department of Gastroenterology, Dokkyo Medical University School of Medicine, 880, Kitakobayashi, Mibu, Shimotsuga, Tochigi 321-0293, Japan
tominaga@dokkyomed.ac.jp

References

- [1] Bisceglia M, Simeone A, Forlano R et al. Fatal systemic venous air embolism during endoscopic retrograde cholangiopancreatography. *Adv Anat Pathol* 2009; 16: 255–262
- [2] Wong JC, Yau KK, Cheung HY et al. Towards painless colonoscopy: a randomized controlled trial on carbon dioxide-insufflating colonoscopy. *ANZ J Surg* 2008; 78: 871–874

Bibliography

Endoscopy 2022; 54: E877–E878

DOI 10.1055/a-1860-1354

ISSN 0013-726X

published online 24.6.2022

© 2022. The Author(s).

This is an open access article published by Thieme under the terms of the Creative Commons Attribution-NonDerivative-NonCommercial License, permitting copying and reproduction so long as the original work is given appropriate credit. Contents may not be used for commercial purposes, or adapted, remixed, transformed or built upon. (<https://creativecommons.org/licenses/by-nc-nd/4.0/>)

Georg Thieme Verlag KG, Rüdigerstraße 14, 70469 Stuttgart, Germany



ENDOSCOPY E-VIDEOS

<https://eref.thieme.de/e-videos>



Endoscopy E-Videos is an open access online section, reporting on interesting cases

and new techniques in gastroenterological endoscopy. All papers include a high quality video and all contributions are freely accessible online. Processing charges apply (currently EUR 375), discounts and wavers acc. to HINARI are available.

This section has its own submission website at

<https://mc.manuscriptcentral.com/e-videos>