

## Complete closure of a large mucosal defect (100 mm) after gastric endoscopic submucosal dissection, using the "accordion fold" method

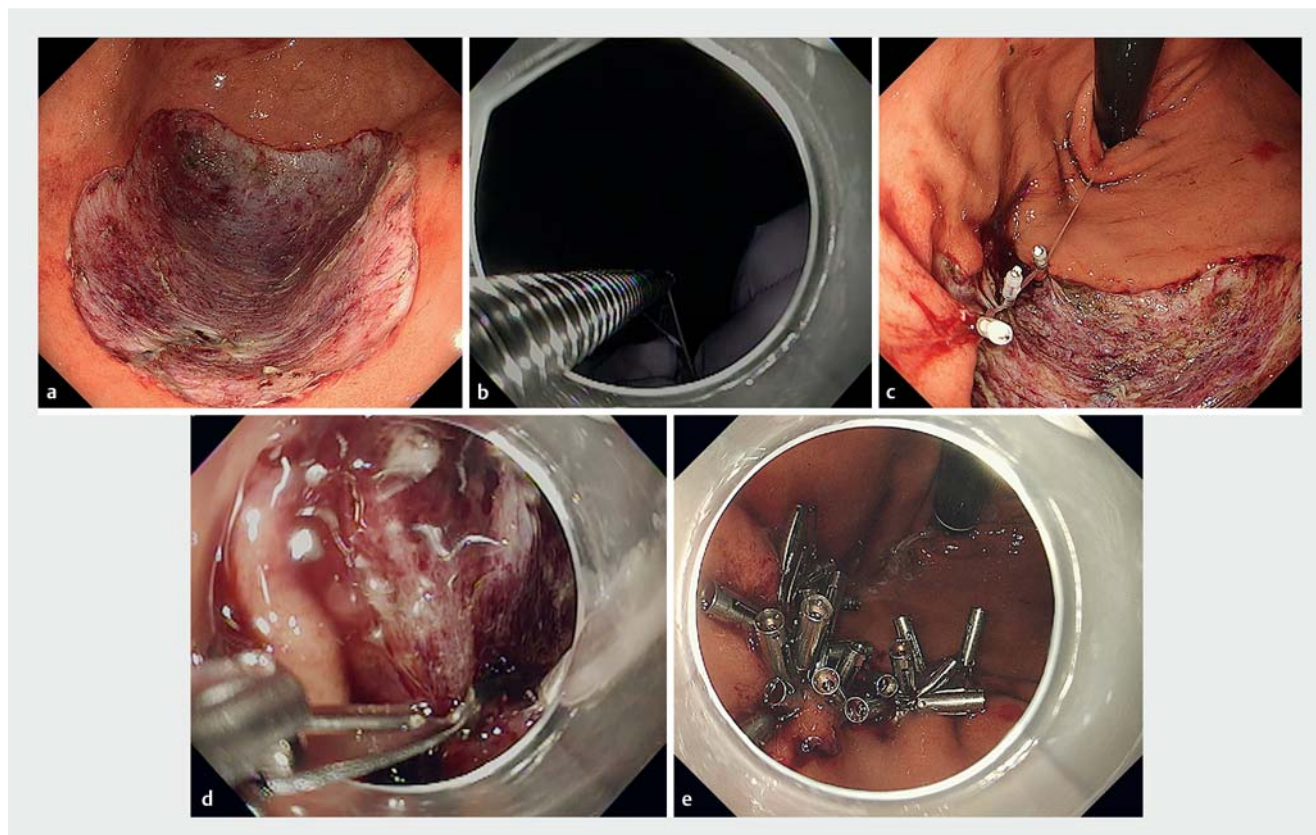


Closure of defects after gastric endoscopic submucosal dissection (ESD) can reduce the risk of complications [1]. Although various endoscopic closure methods are proposed, mainly for the duodenum and colon [2–4], closure of gastric mucosal defects is difficult because of the thick and hard wall [5], which is one reason why a standard closure method has not yet been established. We performed complete closure of an extremely large defect after gastric ESD using the “accordion fold” method, a combination of dental floss-assisted and mucosal–submucosal clipping (► **Video 1**).

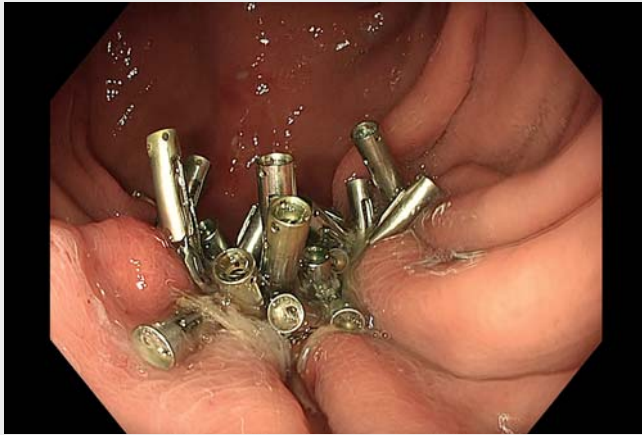A 45-year-old woman underwent gastric ESD for a large mucosal lesion (80 mm) in the gastric fornix. A mucosal defect of approximately 100 mm remained after gastric ESD (► **Fig. 1 a**). We sutured the defect using dental floss (Johnson & Johnson K.K., Tokyo, Japan) and clips (EZ clip, HX-610-090, Olympus Medical, Tokyo, Japan; SureClip, MC Medical, Tokyo, Japan).

First, we attached dental floss to a clip (► **Fig. 1 b**). It was then deployed on the anal edge of the defect. To prevent the formation of a cavity, we placed a second clip on the submucosa in the center of the defect, and a third clip on the oral edge, in

such a way that the dental floss line was also threaded through these two clips. The two sides of the defect were gathered together by pulling the dental floss line perorally (► **Fig. 1 c**). Since the lesion was large, another clip with another dental floss line, was used to bring the oral and anal edges closer together. Next, to reduce the size of the defect, the two arms of additional clips were used to grip the mucosa and submucosa, and we sutured the defect in the direction of the short axis (► **Fig. 1 d**). After repeating the procedure several times, we clipped together mucosa from the anal and oral sides of the defect, and finally we cut the dental



► **Fig. 1** Endoscopic images showing steps for the “accordion fold” method. **a** Large mucosal defect (100 mm) immediately following gastric endoscopic submucosal dissection (ESD). **b** A line of dental floss was attached to a clip. **c** The sides of the defect were brought closer by pulling the dental floss line that was threaded through the clips. **d** Clips were used to suture the mucosa and submucosa. **e** Complete closure of the post gastric ESD defect by combined dental floss-assisted and mucosal–submucosal clipping.



**Video 1** Complete closure for a large defect after gastric endoscopic submucosal dissection, using the “accordion fold” method.

floss. We achieved complete closure that remained after 3 days (► **Fig. 1 e**).

The “accordion fold” method can easily and completely close large defects after gastric ESD and allow them to remain closed without dehiscence.

Endoscopy\_UCTN\_Code\_TTT\_1AS\_2AZ

### Competing interests

The authors declare that they have no conflict of interest.

### The authors

**Yohei Ikenoyama** , **Masaki Katsurahara**, **Kyosuke Tanaka** , **Misaki Nakamura**, **Yasuhiko Hamada** , **Noriyuki Horiki**, **Hayato Nakagawa**

Department of Gastroenterology and Hepatology, Mie University Hospital, Tsu, Japan

### Corresponding author

**Yohei Ikenoyama, MD, PhD**

Department of Gastroenterology and Hepatology, Mie University Hospital, 2-174 Edobashi, Tsu, Mie, 514-8507 Japan  
Fax: +81-59-2315200  
307006yohei@gmail.com

### References

- [1] Goto O, Oyama T, Ono H et al. Endoscopic hand-suturing is feasible, safe, and may reduce bleeding risk after gastric endoscopic submucosal dissection: a multicenter pilot study (with video). *Gastrointest Endosc* 2020; 91: 1195–1202
- [2] Yamasaki Y, Takeuchi Y, Uedo N et al. Line-assisted complete closure of duodenal mucosal defects after underwater endoscopic mucosal resection. *Endoscopy* 2017; 49: E37–E38
- [3] Tashima T, Ohata K, Sakai E et al. Efficacy of an over-the-scope clip for preventing adverse events after duodenal endoscopic submucosal dissection: a prospective interventional study. *Endoscopy* 2018; 50: 487–496
- [4] Abe S, Saito Y, Tanaka Y et al. A novel endoscopic hand-suturing technique for defect closure after colorectal endoscopic submucosal dissection: a pilot study. *Endoscopy* 2020; 52: 780–785
- [5] Akimoto T, Goto O, Nishizawa T et al. Endoscopic closure after intraluminal surgery. *Dig Endosc* 2017; 29: 547–558

### Bibliography

*Endoscopy* 2022; 54: E892–E893

DOI 10.1055/a-1860-1528

ISSN 0013-726X

published online 24.6.2022

© 2022. The Author(s).

This is an open access article published by Thieme under the terms of the Creative Commons Attribution-NonDerivative-NonCommercial License, permitting copying and reproduction so long as the original work is given appropriate credit. Contents may not be used for commercial purposes, or adapted, remixed, transformed or built upon. (<https://creativecommons.org/licenses/by-nc-nd/4.0/>)

Georg Thieme Verlag KG, Rüdigerstraße 14, 70469 Stuttgart, Germany



### ENDOSCOPY E-VIDEOS

<https://eref.thieme.de/e-videos>



*Endoscopy E-Videos* is an open access online section, reporting on interesting cases and new techniques in gastroenterological endoscopy. All papers include a high quality video and all contributions are freely accessible online. Processing charges apply (currently EUR 375), discounts and waivers acc. to HINARI are available.

This section has its own submission website at <https://mc.manuscriptcentral.com/e-videos>