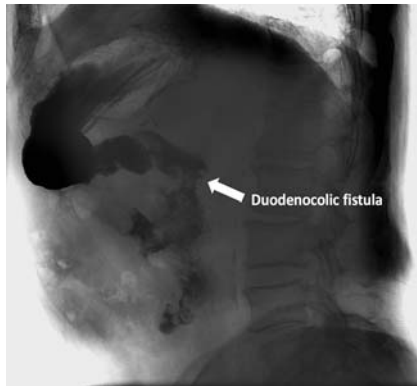
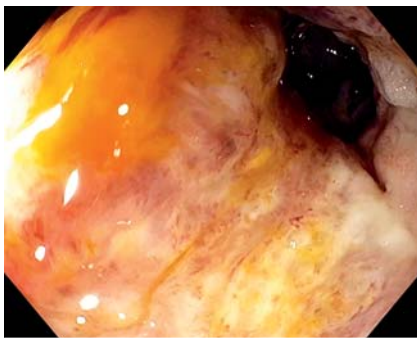


Malignant duodenocolic fistula successfully treated with self-expandable partially covered metal stent and endoscopic suturing

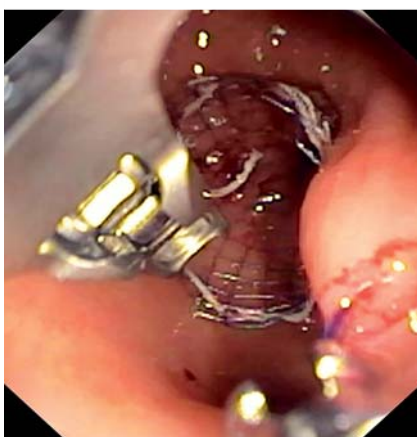OPEN
ACCESS



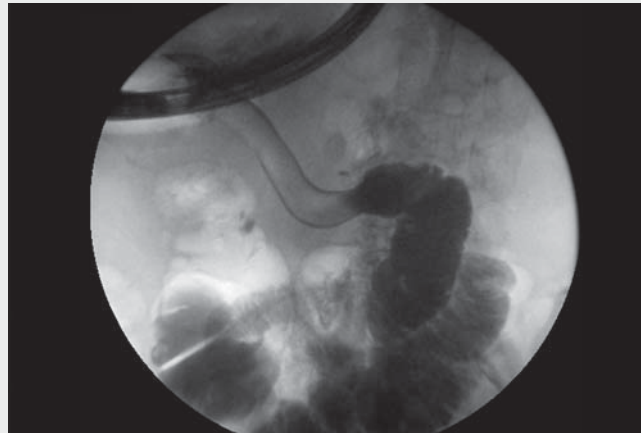► **Fig. 1** Malignant duodenocolic fistula in an 83-year-old man. Fluoroscopic contrast study showing the passage of contrast medium from duodenum to ascending colon.



► **Fig. 2** Endoscopic appearance of the duodenocolic fistula.



► **Fig. 3** Stent deployed and sutured to the gastric wall.



► **Video 1** Single-session treatment of a malignant duodenocolic fistula with stent deployment and endoscopic suturing.

Duodenocolic fistula is a rare complication of right-sided colon cancer and its management can be challenging because of surgery-related morbidity, especially in fragile patients in a palliative care setting [1]. Endoscopic treatment with self-expandable metal stents (SEMSs) is still a feasible and safe option in patients with poor performance status, but the risk of stent migration is not negligible [2].

We describe a case of an 83-year-old man affected by incurable colon cancer, who presented with weight loss, abdominal pain and diarrhea. Computed tomography (CT) and a subsequent fluoroscopic contrast study showed passage of contrast medium from the duodenum directly to the hepatic flexure of the colon (► **Fig. 1**). Upper endoscopy revealed a large infiltrating, non-stenosing lesion in the wall of the proximal duodenum, fistulizing with the ascending colon (► **Fig. 2**). We decided upon an endoscopic treatment: a through-the-scope clip was placed in the distal duodenum as a radioopaque marker, and a partially covered SEMS, 120 mm in length, was deployed



(► **Video 1**). We then placed an overtube to safely introduce the suturing device (OverStitch; Apollo Endosurgery, Austin, Texas, US) attached to the tip of a double-channel endoscope (GIF-2TH180, Olympus, Tokyo, Japan), in order to fix the proximal side of the stent to the gastric wall (► **Fig. 3**). The procedure was uncomplicated and the patient resumed a soft diet after 24 hours. After 3 days the patient was discharged, and a regular oral intake was maintained until he died 4 months later because of disease progression.

In patients with malignant fistula, a covered SEMS is mandatory in order to restore the integrity of gastrointestinal wall, but the migration rate is still high, ranging from 6.5% to 32.3% [3]. The risk of migration is even greater when a fistula develops without a significant stricture. Endoscopic suturing devices can thus represent a useful tool, reducing the risk of stent migration and related complications within a single-session procedure [4, 5].

Competing interests

The authors declare that they have no conflict of interest.

The authors

Marco Sacco , **Marcantonio Gesualdo**, **Federica Fimiano**, **Anna Mauriello**, **Fabio Castellano** , **Stefania Caronna**, **Claudio De Angelis**

Gastroenterology Unit, AOU Città della Salute e della Scienza di Torino, Turin, Italy

Corresponding author

Marco Sacco, MD

Gastroenterology Unit, AOU Città della Salute e della Scienza di Torino, Corso Bramante 88, 10126 Turin, Italy
Fax: +39-011-6336752
marco.sacco10@gmail.com

References

- [1] Gupta V, Kurdia KC, Kumar P et al. Malignant colo-duodenal fistula: management based on proposed classification. *Updates Surg* 2018; 70: 449–458
- [2] Jue TL, Storm AC. ASGE Standards of Practice Committee. et al. ASGE guideline on the role of endoscopy in the management of benign and malignant gastroduodenal obstruction. *Gastrointest Endosc* 2021; 93: 309–322
- [3] Hori Y, Hayashi K, Naitoh I et al. A pilot study of novel duodenal covered self-expandable metal stent fixation. *Sci Rep* 2021; 11: 19708
- [4] Granata A, Martino A, Ligresti D et al. Closure techniques in exposed endoscopic full-thickness resection: overview and future perspectives in the endoscopic suturing era. *World J Gastrointest Surg* 2021; 13: 645–654
- [5] Ngamruengphong S, Sharaiha RZ, Sethi A et al. Endoscopic suturing for the prevention of stent migration in benign upper gastrointestinal conditions: a comparative multicenter study. *Endoscopy* 2016; 48: 802–808

Bibliography

Endoscopy 2022; 54: E902–E903
DOI 10.1055/a-1860-1712
ISSN 0013-726X
published online 1.7.2022
© 2022. The Author(s).

This is an open access article published by Thieme under the terms of the Creative Commons Attribution-NonDerivative-NonCommercial License, permitting copying and reproduction so long as the original work is given appropriate credit. Contents may not be used for commercial purposes, or adapted, remixed, transformed or built upon. (<https://creativecommons.org/licenses/by-nc-nd/4.0/>)
Georg Thieme Verlag KG, Rüdigerstraße 14, 70469 Stuttgart, Germany



ENDOSCOPY E-VIDEOS <https://eref.thieme.de/e-videos>



Endoscopy E-Videos is an open access online section, reporting on interesting cases and new techniques in gastroenterological endoscopy. All papers include a high quality video and all contributions are freely accessible online. Processing charges apply (currently EUR 375), discounts and waivers acc. to HINARI are available.

This section has its own submission website at <https://mc.manuscriptcentral.com/e-videos>