

Reopenable-clip band-assisted underwater endoscopic mucosal resection to obtain a large specimen

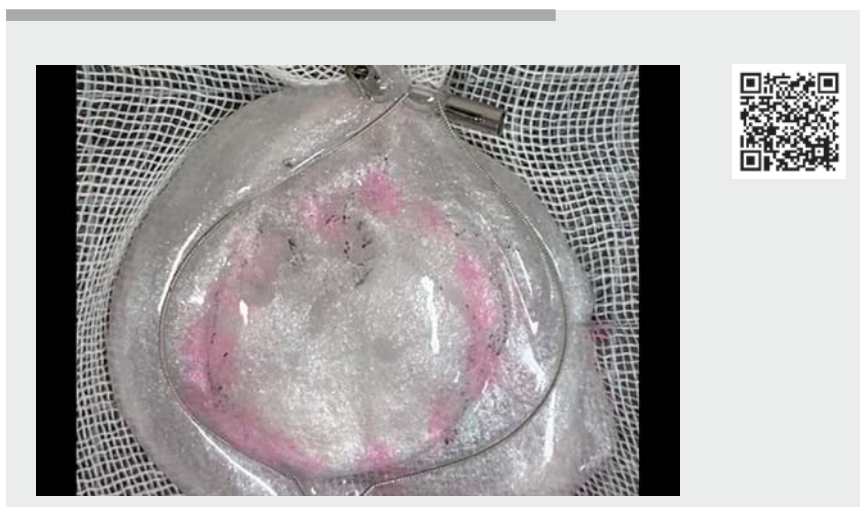OPEN
ACCESS

Although en bloc resection of colorectal tumors larger than 20 mm is challenging for snare resection [1,2], it should be pursued because piecemeal resection causes local recurrence afterward. Even when a large snare is used, the entire lesion is not captured when the snare tip slips forward and the snare does not open wide. Although some methods for fixing a snare tip at the proximal mucosa have been reported, they are not always effective [3,4]. We devised a reopenable-clip band-assisted technique for underwater endoscopic mucosal resection (RB-UEMR) using a 35-mm snare to fix the snare tip to enable removal of a tumor as a large single specimen.

Our patient had a 40-mm sessile serrated lesion (SSL) in the ascending colon. We used RB-UEMR to fix the snare tip and resected the lesion. A reopenable-clip band (Sterile Elastic Traction Device; Micro-Tech Co. Ltd., Nan Jing, China), which is a reopenable clip holding a double-ring band and another reopenable clip (► Fig. 1, ► Video 1), is used for this method. The reopenable-clip band was placed at the normal mucosa beyond the tumor, while the other end of the band was connected to the mucosa next to the first clip to make a trap to hold the snare tip (► Fig. 2). The tip of a rotatable snare (Rotasnare 35 mm; Medi-Globe GmbH, Achenmühle, Germany) was placed in the trap, and the snare was expanded to its widest. The entire lesion was then captured. However, since the snaring of this large mucosal area caused the lesion to bend, a small amount of the lesion was left behind. Additional snaring enabled complete resection of the residual lesion. The mucosal defect was completely closed using the reopenable-clip-over-the-line method [5]. The largest specimen of the lesion had a longest diameter of 46 mm and a shortest diameter of 36 mm, and the histopathological analysis revealed SSL.



► **Fig. 1** Schematic illustration of reopenable-clip band-assisted underwater endoscopic mucosal resection (RB-UEMR). **a** The reopenable-clip band is placed at the normal mucosa beyond the tumor. **b, c** The other end of the band is also connected to the mucosa, next to the first clip, to make a trap to hold a snare tip. **d, e** The tip of a rotatable snare is placed in the trap, and the snare is expanded to its widest. **f** The entire lesion is captured.

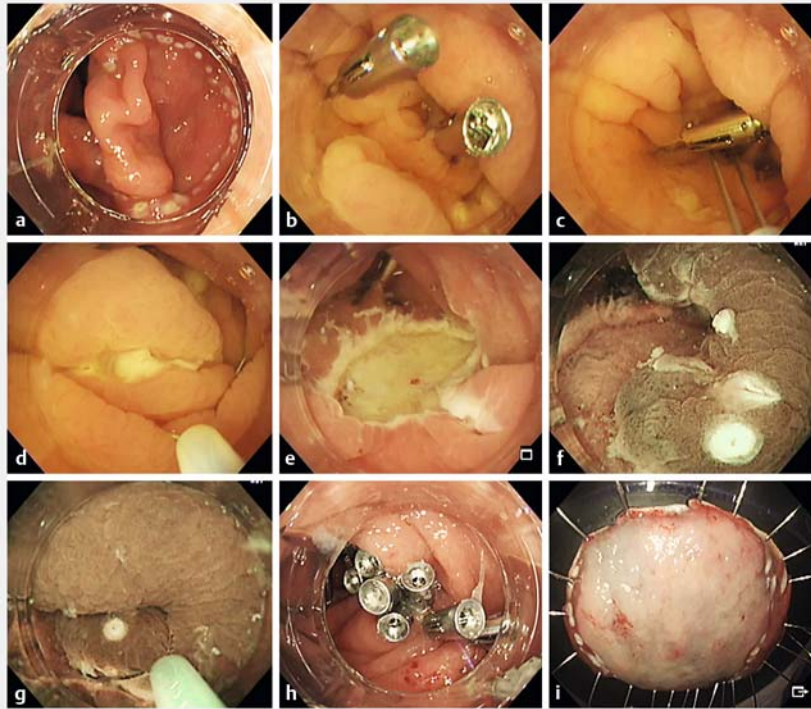


► **Video 1** Schematic demonstration and an actual case of resection of a 40-mm sessile serrated lesion using reopenable-clip band-assisted underwater endoscopic mucosal resection.

Endoscopy_UCTN_Code_TTT_1AQ_2AD

Competing interests

The authors declare that they have no conflict of interest.



► **Fig. 2** Resection of a 40-mm sessile serrated lesion (SSL) in the ascending colon using the RB-UEMR technique. **a** A 40-mm SSL in the ascending colon. **b** A reopenable-clip band is fixed on the oral side of the marking, and the band is fixed with an additional reopenable clip. **c** The tip of the snare is placed in the band, and the snare is expanded. **d** Ensuring that the markings lie within the snare, the snare is tightened. **e** The first snare resection creates a mucosal defect. **f** A small piece of SSL is observed; it could not be resected because mucosal distortion caused the lesion to bend. **g** Additional UEMR was performed. **h** The mucosal defect has been completely closed. **i** Specimen, 46 × 36 mm in size, resected using RB-UEMR.

The authors

Tatsuma Nomura^{1,2,3} , Haruka Nakamura^{1,2}, Shinya Sugimoto¹, Jun Oyamada¹, Keiichi Ito², Akira Kamei¹, Yoshikazu Hayashi³ 

- 1 Department of Gastroenterology, Ise Red Cross Hospital, Ise, Mie, Japan
- 2 Department of Gastroenterology, Mie Prefectural Shima Hospital, Shima, Mie, Japan
- 3 Department of Medicine, Division of Gastroenterology, Jichi Medical University, Shimotsuke, Japan

Corresponding author

Tatsuma Nomura, MD

Department of Gastroenterology,
Ise Red Cross Hospital, 1-471-2 Funae,
Ise, Mie 516-8512, Japan
m06076tn@icloud.com

References

- [1] Chandan S, Khan SR, Kumar A et al. Efficacy and histologic accuracy of underwater versus conventional endoscopic mucosal resection for large (>20 mm) colorectal polyps: a comparative review and meta-analysis. *Gastrointest Endosc* 2021; 94: 471–482.e9
- [2] Binmoeller KF, Hamerski CM, Shah JN et al. Attempted underwater en bloc resection for large (2–4 cm) colorectal laterally spreading tumors (with video). *Gastrointest Endosc* 2015; 81: 713–718
- [3] Jacques J, Legros R, Chrissoux A et al. Anchoring the snare tip by means of a small incision facilitates en bloc endoscopic mucosal resection and increases the specimen size. *Endoscopy* 2017; 49: E39–E41
- [4] Mori H, Kobara H, Rafiq K et al. Preclipping fixation EMR to achieve sufficient surgical margin and negative resection. *Gastrointest Endosc* 2015; 81: 1025–1026

- [5] Nomura T, Sugimoto S, Kawabata M et al. Large colorectal mucosal defect closure post-endoscopic submucosal dissection using the reopenable clip over line method and modified locking-clip technique. *Endoscopy* 2022; 54: E63–E64

Bibliography

Endoscopy 2022; 54: E916–E917

DOI 10.1055/a-1860-1856

ISSN 0013-726X

published online 1.7.2022

© 2022. The Author(s).

This is an open access article published by Thieme under the terms of the Creative Commons Attribution-NonDerivative-NonCommercial License, permitting copying and reproduction so long as the original work is given appropriate credit. Contents may not be used for commercial purposes, or adapted, remixed, transformed or built upon. (<https://creativecommons.org/licenses/by-nc-nd/4.0/>)

Georg Thieme Verlag KG, Rüdigerstraße 14,
70469 Stuttgart, Germany



ENDOSCOPY E-VIDEOS

<https://eref.thieme.de/e-videos>



Endoscopy E-Videos is an open access online section, reporting on interesting cases

and new techniques in gastroenterological endoscopy. All papers include a high quality video and all contributions are freely accessible online. Processing charges apply (currently EUR 375), discounts and waivers acc. to HINARI are available.

This section has its own submission website at

<https://mc.manuscriptcentral.com/e-videos>