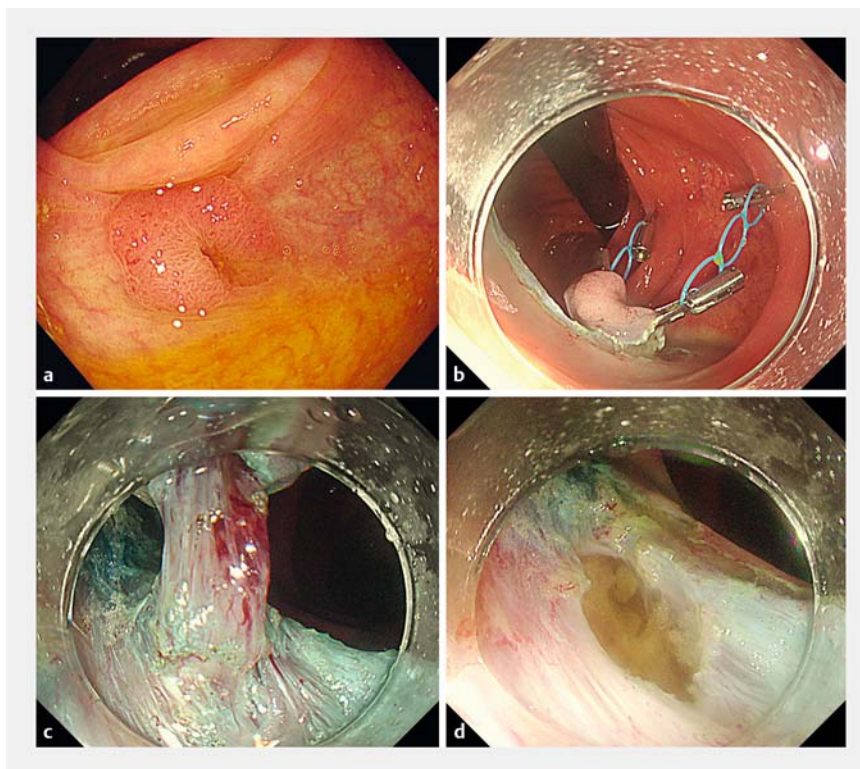


Endoscopic submucosal dissection for complete removal of a residual colorectal tumor involving a diverticulum



A 74-year-old man underwent endoscopic mucosal resection (EMR) for treatment of a 20-mm polyp close to a diverticulum in the ascending colon. Surveillance colonoscopy at 12 months showed a 10-mm polyp involving a diverticulum and surrounded by scars in the ascending colon (► **Fig. 1 a**). Because the lesion was completely involving a diverticulum and water immersion could not show the “floating” effect on the tumor associated with the diverticulum [1], underwater EMR (UEMR) was discontinued. In addition, submucosal injection showed the nonlifting sign [2].

We therefore decided to perform endoscopic submucosal dissection (ESD) (► **Video 1**). After a circumferential mucosal incision had been made, two multiloop traction devices (Boston Scientific, Tokyo, Japan) were attached at the anal and oral edges of the lesion using SureClips (MC Medical, Tokyo, Japan) to obtain countertraction (► **Fig. 1 b**). Multi-traction allowed us to dissect the submucosal layer easily and to visualize the central part of the lesion, where the mucosal layer dropped into the muscular layer with fibrosis. Because the fibrosis made identification of the submucosal layer difficult (► **Fig. 1 c**), we performed partial muscular dissection. En bloc resection was successfully achieved (► **Fig. 1 d**), and the muscle layer defect was immediately closed with SureClips. The patient was discharged from our hospital, without experiencing any adverse events. Histopathology revealed a high grade adenoma with negative margins (► **Fig. 2**). ESD for colorectal tumors involving a diverticulum and residual tumors is technically challenging [3,4]. Traction devices have been reported to help with colonic ESD for lesions involving a diverticulum [5]. In our case, the residual lesion involved a diverticulum and showed submucosal fibrosis, which made the identi-



► **Fig. 1** Colonoscopic views showing: **a** a 10-mm polyp involving a diverticulum and surrounded by scars in the ascending colon of a 74-year-old man; **b** two multiloop traction devices attached using clips at the anal and oral edges of the lesion after circumferential mucosal incision; **c** the mucosal layer dropping into a muscular layer, with fibrosis also present, in the central part of the lesion; **d** the defect after en bloc resection had been achieved following partial muscular dissection.

fication and dissection of the submucosal layer at the diverticulum difficult. The use of multiple traction devices enabled us to perform selective muscular dissection and minimize the muscle layer defect, resulting in efficient closure after complete resection of the lesion.

Endoscopy_UCTN_Code_TTT_1AQ_2AD

Acknowledgments

We gratefully acknowledge the work of past and present members of our institution.

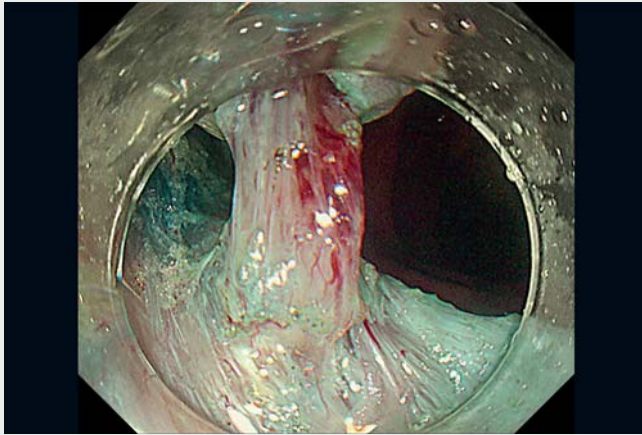
Competing interests

The authors declare that they have no conflict of interest.

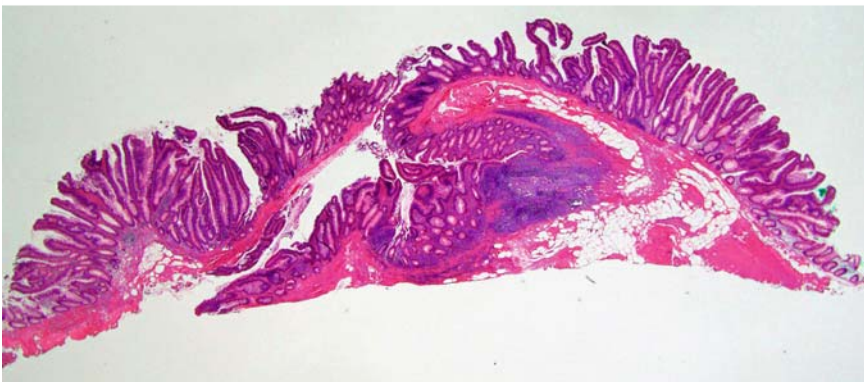
The authors

Kazuya Hosotani¹ Yohei Yabuuchi¹
Daisuke Yamashita², Shigeo Hara², Tetsuro Inokuma¹

- 1 Department of Gastroenterology, Kobe City Medical Center General Hospital, Kobe, Japan
- 2 Department of Clinical Pathology, Kobe City Medical Center General Hospital, Kobe, Japan



▶ Video 1 A residual tumor involving a diverticulum is completely removed by endoscopic submucosal dissection assisted by multiple traction devices, the use of which aids visualization and dissection of the submucosal layer.



▶ Fig. 2 Microscopic view of the resected lesion, which showed a high grade adenoma completely involving a diverticulum, with negative margins.

Bibliography

Endoscopy 2022; 54: E908–E909

DOI 10.1055/a-1864-9146

ISSN 0013-726X

published online 1.7.2022

© 2022. The Author(s).

This is an open access article published by Thieme under the terms of the Creative Commons Attribution-NonDerivative-NonCommercial License, permitting copying and reproduction so long as the original work is given appropriate credit. Contents may not be used for commercial purposes, or adapted, remixed, transformed or built upon. (<https://creativecommons.org/licenses/by-nc-nd/4.0/>)

Georg Thieme Verlag KG, Rüdigerstraße 14, 70469 Stuttgart, Germany



ENDOSCOPY E-VIDEOS

<https://eref.thieme.de/e-videos>



Endoscopy E-Videos is an open access online section, reporting on interesting cases and new techniques in gastroenterological endoscopy. All papers include a high quality video and all contributions are freely accessible online. Processing charges apply (currently EUR 375), discounts and waivers acc. to HINARI are available.

This section has its own submission website at <https://mc.manuscriptcentral.com/e-videos>

Corresponding author

Kazuya Hosotani, MD

2-1-1 Minatojima-minamimachi, Chuo-ku, Kobe, Hyogo, 650-0047, Japan
kzyhosotani@gmail.com

References

- [1] Hosotani K, Imai K, Hotta K et al. Underwater endoscopic mucosal resection for complete R0 removal residual adenoma at a perforated scar in patient with colostomy. *Endoscopy* 2017; 49: E121–E122
- [2] Uno Y, Munakata A. The non-lifting sign of invasive colon cancer. *Gastrointest Endosc* 1994; 40: 485–489
- [3] Kato M, Uraoka T, Wada M et al. Laterally spreading tumor involving a colon diverticulum successfully resected by endoscopic submucosal dissection. *Gastrointest Endosc* 2016; 84: 191–192
- [4] Imai K, Hotta K, Yamaguchi Y et al. Preoperative indicators of failure of en bloc resection or perforation in colorectal endoscopic submucosal dissection: implications for lesion stratification by technical difficulties during stepwise training. *Gastrointest Endosc* 2016; 83: 954–962
- [5] Shichijo S, Yamasaki Y, Takeuchi Y. Case of colonic adenoma involving a diverticulum resected by a traction-assisted endoscopic submucosal dissection technique. *Dig Endosc* 2017; 29: 729–730