

## Gastric bypass was performed with a novel through-the-scope twin clip under endoscopy

OPEN  
ACCESS

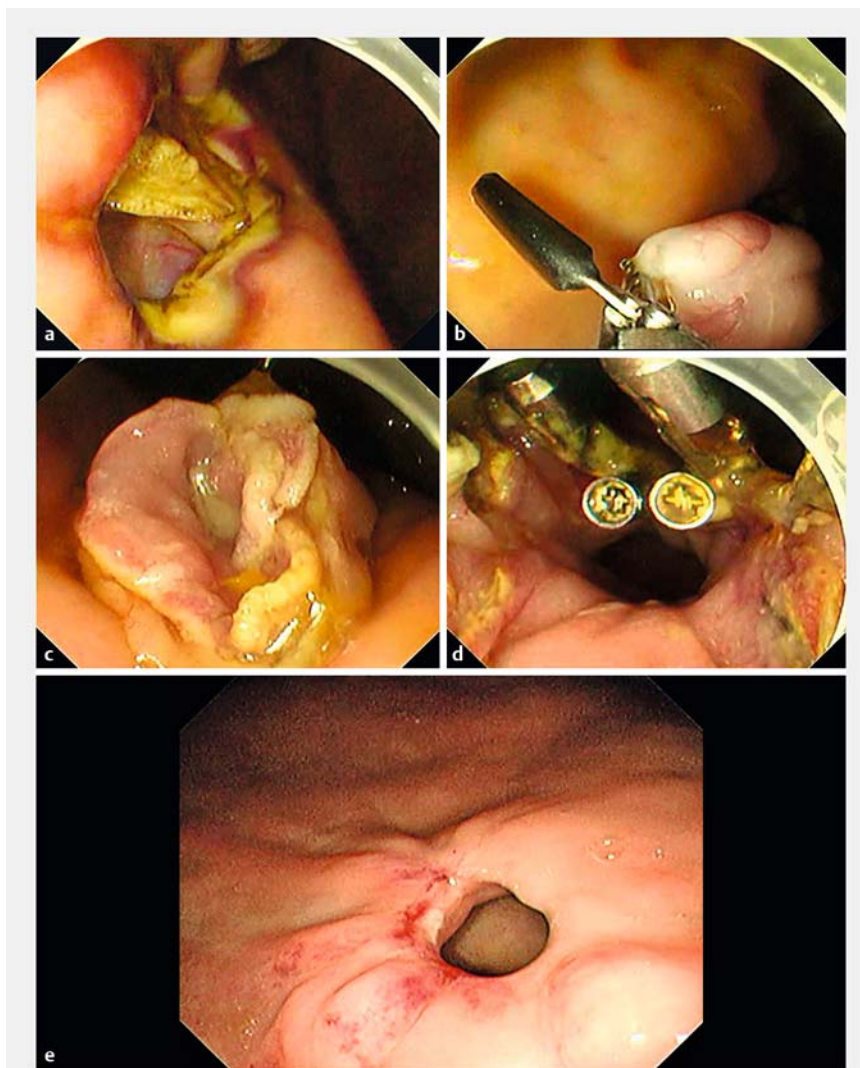
A novel through-the-scope twin clip (TTS-TC) (Micro-Tech Co. Ltd., Nanjing, China) was first reported by us [1,2]. The TTS-TC is composed of a middle column and two clips on both sides. Here, we initially explored gastric bypass with the TTS-TCs under endoscopy in a live pig.

The operation steps were as follows (► **Video 1**, ► **Fig. 1**): 1) A full-thickness defect of about 1.0cm was made in the lower part of gastric body (► **Fig. 1 a**). 2)

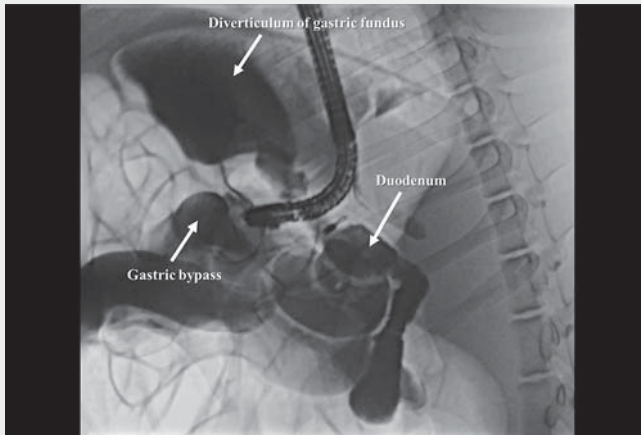
The small intestine near the defect was found in the abdominal cavity. 3) A TTS-TC was passed through the working channel of endoscope, and then one clip of the TTS-TC was opened to clamp the intestine. Then, the clamped intestine was pulled into the gastric cavity, and the other clip was opened to clamp the gastric mucosa to anchor the clamped intestine in the gastric cavity (► **Fig. 1 b**). 4) After the intestine was firmly anchored, it was incised with a hook knife (► **Fig. 1 c**). Then, the incised intestine wall was clamped by one clip of a TTS-TC, was pulled toward the gastric defect, and then the mucosa near the gastric defect was clamped by the other clip to close the two together (► **Fig. 1 d**). By this means, a total of seven TTS-TCs were used to close the gastrointestinal anastomosis wound, and then three traditional through-the-scope clips were used to close the wound. The total time spent in the formation of the gastric bypass was 96 minutes, in which the time of closing the wound was 51 minutes.

At the 2-month follow-up, no perforation, bleeding or death had occurred, the wound had healed, and the TTS-TCs had spontaneously fallen off. A gastric bypass had been successfully constructed (► **Fig. 1 e**). However, further exploration is needed to optimize the procedure and evaluate its safety and feasibility.

Endoscopy\_UCTN\_Code\_TTT\_1AQ\_2AI



► **Fig. 1** Construction of gastric bypass with a novel through-the-scope twin clip under endoscopy. **a** An opening into the abdominal cavity was made in the lower part of gastric body under endoscopy by endoscopic full thickness resection. **b** The intestine was clamped by one side of a TTS-TC, the clamped intestine was pulled into the stomach, and then was anchored in the gastric mucosa by the other clip of the TTS-TC. The anchoring position was separated by a certain distance to the opening, which kept the anchored intestine from being retracted into the abdominal cavity from the opening. **c** The anchored intestine was incised with a hook knife to form an opening. **d** The two openings were sutured together with the TTS-TCs combined with the through-the-scope clips, which achieved the gastrointestinal anastomosis. **e** The wound healed and the clips spontaneously fell off.



**Video 1** Endoscopic gastric bypass was successfully constructed with a novel through-the-scope twin clip in a live pig.

## Competing interests

The authors declare that they have no conflict of interest.

## The authors

**Qiang Zhang**, **Zhen Wang**, **Side Liu**  
Guangdong Provincial Key Laboratory of Gastroenterology, Department of Gastroenterology, Nanfang Hospital, Southern Medical University, Guangzhou, Guangdong Province, China

## Corresponding author

**Side Liu, MD**  
Guangdong Provincial Key Laboratory of Gastroenterology, Department of Gastroenterology, Nanfang Hospital, Southern Medical University, Guangzhou, Guangdong Province, China  
Fax: +86-020-87280770  
liuside2011@163.com

## References

- [1] Zhang Q, Wang Z, Bai Y. A novel through-the-scope twin endoclip for a large mucosal closure in a live pig model. *Endoscopy* 2019; 51: E372–E373
- [2] Zhang Q, Jin H-Y, Shen Z-H et al. A novel through-the-scope twin clip for the closure of gastrointestinal wounds: the first experimental survival study in pigs (with videos). *Gastrointest Endosc* 2021; 94: 850–858

## Bibliography

*Endoscopy* 2022; 54: E962–E963  
DOI 10.1055/a-1866-3582  
ISSN 0013-726X  
published online 21.7.2022  
© 2022. The Author(s).

This is an open access article published by Thieme under the terms of the Creative Commons Attribution-NonDerivative-NonCommercial License, permitting copying and reproduction so long as the original work is given appropriate credit. Contents may not be used for commercial purposes, or adapted, remixed, transformed or built upon. (<https://creativecommons.org/licenses/by-nc-nd/4.0/>)

Georg Thieme Verlag KG, Rüdigerstraße 14,  
70469 Stuttgart, Germany



## ENDOSCOPY E-VIDEOS

<https://eref.thieme.de/e-videos>



*Endoscopy E-Videos* is an open access online section, reporting on interesting cases and new techniques in gastroenterological endoscopy. All papers include a high quality video and all contributions are freely accessible online. Processing charges apply (currently EUR 375), discounts and waivers acc. to HINARI are available.

This section has its own submission website at  
<https://mc.manuscriptcentral.com/e-videos>