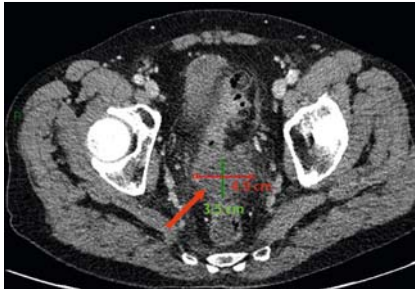

## Freehand endoscopic ultrasound-guided transrectal drainage of diverticulitis-associated abscess with electrocautery-enhanced lumen-apposing metal stent under spinal anesthesia

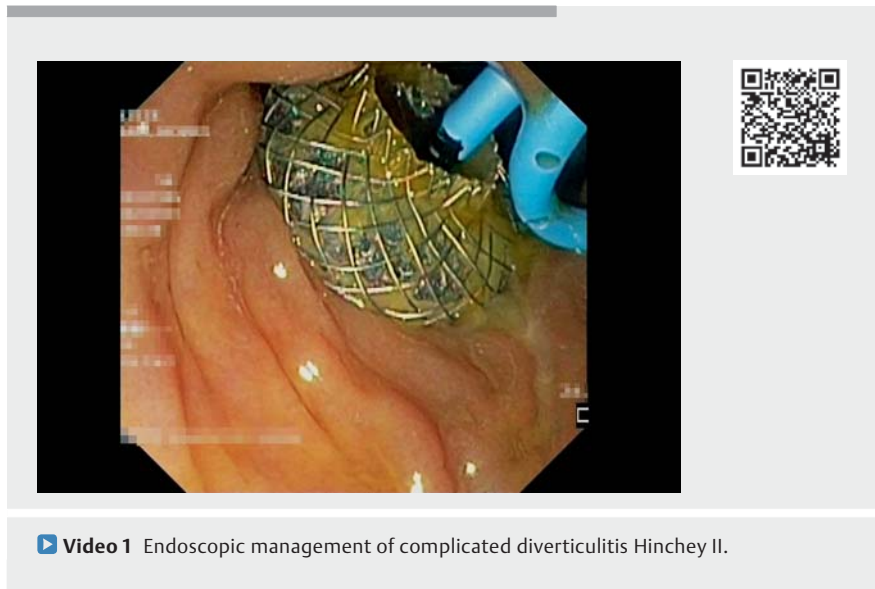

► **Fig. 1** Computed tomography scan showing complicated diverticulitis Hinchey II with an abscess (red arrow).

Complicated diverticulitis occurs in 12% of all diverticulitis cases [1]. Radiological drainage is the first-line therapy in cases of large diverticulitis-associated abscess [2]. However, the pelvic location renders the radiological access challenging. Lower endoscopic ultrasound (EUS)-guided drainage, using an electrocautery-enhanced lumen-apposing metal stent (LAMS), is a feasible and safe alternative method for drainage of pelvic collections [3–5]. We present a case of a diverticulitis-associated abscess successfully treated using EUS-guided LAMS.

A 57-year-old man presented to the emergency room with abdominal pain and fever. His medical history revealed chronic obstructive pulmonary disease Gold IV. On admission, computed tomography (CT) scan showed a complicated acute diverticulitis Hinchey II with a pelvic abscess of 5 cm (► **Fig. 1**). The pelvic location of the abscess did not allow for radiological drainage and general anesthesia was contraindicated due to the patient's pulmonary disease. EUS-guided drainage of the pelvic abscess was performed under spinal anesthesia (► **Video 1**).

The diverticulitis-associated abscess was punctured freehand (► **Fig. 2a**) using the electrocautery-enhanced LAMS (10 × 10 mm; pure cut mode, effect 4). After



► **Video 1** Endoscopic management of complicated diverticulitis Hinchey II.

deployment of the proximal flange (► **Fig. 2b**), a 0.035-inch guidewire was introduced through the LAMS into the abscess (► **Fig. 2c**). Then, the LAMS was deployed to drain the abscess into the lumen of the colon. Finally a double-pig-tail stent was inserted through the LAMS to avoid LAMS obstruction (► **Fig. 2d**). No adverse events were reported.

Follow-up CT scan 2 weeks later showed complete resolution of the abscess. The LAMS was removed and the residual fistula was closed using clips. Follow-up CT scan and endoscopy at 2 months showed complete resolution of the abscess without fistula.

This case highlights the advantage of LAMS for drainage of a diverticulitis-associated abscess and its successful outcome without recurrence. Moreover, in patients with contraindication for general anesthesia, this procedure can be performed under spinal anesthesia. Prospective studies are needed to determine the role of EUS-guided drainage of diverticulitis-associated abscess using LAMS.

Endoscopy\_UCTN\_Code\_TTT\_1AS\_2AZ

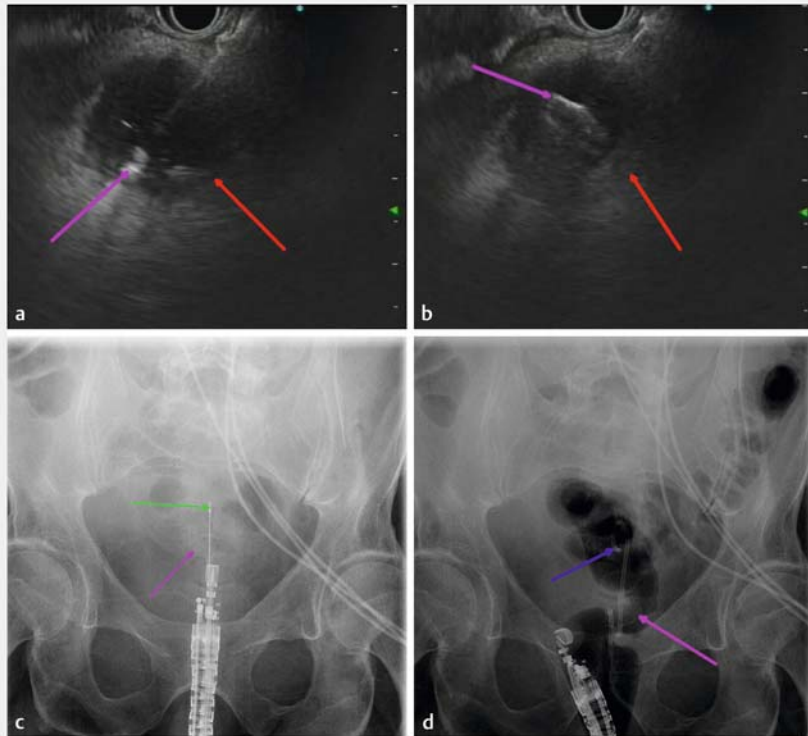
### Competing interests

The authors declare that they have no conflict of interest.

### The authors

Laurent Monino<sup>1</sup>, Philippe Pendeville<sup>2</sup>, Christophe Remue<sup>3</sup>, Tom G. Moreels<sup>1</sup>

- 1 Department of Gastroenterology and Hepatology, Université catholique de Louvain, Cliniques universitaires Saint-Luc, Brussels, Belgium
- 2 Department of Anesthesiology, Université catholique de Louvain, Cliniques universitaires Saint-Luc, Brussels, Belgium
- 3 Department of Digestive Surgery, Université catholique de Louvain, Cliniques universitaires Saint-Luc, Brussels, Belgium



► **Fig. 2** Endoscopic ultrasound (EUS)-guided drainage of diverticulitis-associated abscess using an electrocautery-enhanced lumen-apposing metal stent (LAMS). **a** Direct puncture with the electrocautery-enhanced LAMS (purple arrow) into the pelvic abscess (red arrow) under EUS control. **b** Deployment of the proximal flange of the LAMS (purple arrow) into the abscess lumen (red arrow) under EUS control. **c** Introduction of a guidewire (green arrow) through the LAMS (pink arrow) into the abscess. **d** A double-pigtail stent (blue arrow) was inserted through the LAMS (pink arrow).

## Corresponding author

### Laurent Monino, MD

Department of Gastroenterology and Hepatology, Cliniques universitaires Saint-Luc, UC Louvain, Ave Hippocrate 10, 1200 Brussels, Belgium  
 laurent.monino@saintluc.uclouvain.be  
 monino.laurent@hotmail.fr

## References

- [1] Strate LL, Morris AM. Epidemiology, pathophysiology, and treatment of diverticulitis. *Gastroenterology* 2019; 156: 1282–1298
- [2] Schultz JK, Azhar N, Binda GA et al. European Society of Coloproctology: guidelines for the management of diverticular disease of the colon. *Colorectal Dis* 2020; 22 (Suppl. 02): 5–28
- [3] Poincloux L, Caillol F, Allimant C et al. Long-term outcome of endoscopic ultrasound-guided pelvic abscess drainage: a two-center series. *Endoscopy* 2017; 49: 484–490

- [4] Dhindsa BS, Naga Y, Saghir SM et al. EUS-guided pelvic drainage: a systematic review and meta-analysis. *Endosc Ultrasound* 2021; 10: 185–190
- [5] Guingand M, Gasmi M, Serrero M et al. Endoscopic ultra-sound (EUS) guided management of symptomatic pelvic collections: puncture-aspiration or drainage? Results from mono-centric retrospective experience with therapeutic algorithm. *Scand J Gastroenterol* 2022; 57: 112–118

## Bibliography

*Endoscopy* 2022; 54: E884–E885

DOI 10.1055/a-1866-3628

ISSN 0013-726X

published online 24.6.2022

© 2022. The Author(s).

This is an open access article published by Thieme under the terms of the Creative Commons Attribution-NonCommercial License, permitting copying and reproduction so long as the original work is given appropriate credit. Contents may not be used for commercial purposes, or adapted, remixed, transformed or built upon. (<https://creativecommons.org/licenses/by-nc-nd/4.0/>)

Georg Thieme Verlag KG, Rüdigerstraße 14, 70469 Stuttgart, Germany



## ENDOSCOPY E-VIDEOS

<https://eref.thieme.de/e-videos>



*Endoscopy E-Videos* is an open access online section, reporting on interesting cases and new techniques in gastroenterological endoscopy. All papers include a high quality video and all contributions are freely accessible online. Processing charges apply (currently EUR 375), discounts and waivers acc. to HINARI are available.

This section has its own submission website at <https://mc.manuscriptcentral.com/e-videos>